

Evaluation of cell proliferation rate in non-dysplastic leukoplakias

Laura-de Campos Hildebrand, Vinicius-Coelho Carrard, Isabel-da Silva Lauxen, Onofre-Francisco de Quadros, Anna-Cecilia-Moraes Chaves, Manoel Sant'Ana-Filho

Oral Pathology, School of Dentistry, Universidade Federal do Rio Grande do Sul. Porto Alegre-RS-Brazil

Correspondence:

Rua Ramiro Barcelos 2492/503
Porto Alegre-RS
Brazil CEP:90035-003
manoel@ufrgs.br

Hildebrand L, Carrard V, Lauxen I, Quadros O, Chaves A, Sant'Ana-Filho M. Evaluation of cell proliferation rate in non-dysplastic leukoplakias. Med Oral Patol Oral Cir Bucal. 2010 Mar 1;15 (2):e328-34. <http://www.medicinaoral.com/medoralfree01/v15i2/medoralv15i2p328.pdf>

Received: 27/12/2008
Accepted: 30/07/2009

Article Number: 2640 <http://www.medicinaoral.com/>
© Medicina Oral S. L. C.I.F. B 96689336 - pISSN 1698-4447 - eISSN: 1698-6946
eMail: medicina@medicinaoral.com

Indexed in:

- SCI EXPANDED
- JOURNAL CITATION REPORTS
- Index Medicus / MEDLINE / PubMed
- EMBASE, Excerpta Medica
- SCOPUS
- Indice Médico Español

Abstract

Objective: Analyze whether the most frequent cases of non-dysplastic leukoplakias, hyperkeratosis (H), acanthosis (A), and hyperkeratosis with acanthosis (HA) have similar cell proliferation rates and to compare them with epithelial dysplastic (ED) leukoplakias and normal oral epithelium (NOE). **Study design:** The sample comprised 10 cases of normal oral epithelium, 10 cases of hyperkeratosis, 10 cases of acanthosis, 10 cases of hyperkeratosis with acanthosis and 10 cases of epithelial dysplasia. The mean number of AgNORs per nucleus (mAgNOR) and the mean percentage of cells with 1, 2, 3 and 4 or more AgNORs per nucleus (pAgNOR) were recorded. **Results:** The results of mAgNOR showed differences between disorders in the evaluation of the basal layer, of the parabasal layer, and in the overall evaluation. mAgNOR and pAgNOR=2 increased progressively from normal oral epithelium to hyperkeratosis with acanthosis, hyperkeratosis, acanthosis and epithelial dysplasia ($p < 0.05$). Cell proliferation rate was different between different subtypes of non-dysplastic leukoplakias and this group presented a higher proliferative behavior when compared to normal oral epithelium. **Conclusion:** It may be suggested that non-dysplastic leukoplakias had different characteristics regarding cell proliferation rates and sometimes showed a proliferative behavior similar to that found in epithelial dysplasia. More studies should be conducted to increase knowledge about the biological profile of non-dysplastic leukoplakias, especially as it pertains to acanthosis.

Key words: Leukoplakia, epithelial dysplasia, acanthosis, hyperkeratosis, AgNOR, cell proliferation.

Introduction

Leukoplakia, a common lesion of the oral mucosa, is defined as any white patch or plaque not clinically or histologically characterized as any other disease (1). It is a diagnosis made by exclusion of any other known disease or disorder. Microscopically, this lesion may be characterized by a range of disorders in epithelial renewal and maturation, such as hyperkeratosis, acanthosis or epithelial dysplasia (1-3). Waldron and Shafer

(2) after a microscopic analysis of 3,256 leukoplakias, detected that 80.1% showed different matches of hyperorthokeratosis, hyperparakeratosis and acanthosis.

According to van der Waal (3), the term leukoplakia can be used at different levels of certainty, as a clinical term only or as a clinicopathological term. The clinical term is based on evidence obtained by a negative result of elimination of suspected etiologic factors, during a follow-up period of 2-4 weeks or in the absence of any sus-

pected etiologic factors. The clinicopathological term is based on a clinical definitive diagnosis complemented by incisional biopsy or excision and pathological examination of the resected specimen (definitive histopathological diagnosis).

Nucleolar organizer regions (NORs) are DNA segments that encode ribosomal RNA (4,5). During transcription, these regions bind to argyrophilic nucleolar organizer regions (AgNOR) proteins. A high number of AgNOR dots are observed in proliferating cells (4,6,7). The number of AgNOR dots provides information about the velocity of cell proliferation during the cell cycle (cell proliferation rate), differently from most proliferation markers, which only indicate whether cells are or are not undergoing division (cell growth fraction) (6). Some studies found a progressive increase in the mean number of AgNOR counts as the oral epithelium undergoes maturation and reaches malignant transformation (8,9). According to Pich et al. (10), it is the rate of cell proliferation, rather than the proliferative activity per se, that affects neoplastic progression.

Most studies classify all non-dysplastic leukoplakias into one single group, although different epithelial disorders may be observed. Carcinomatous transformation may also take place in non-dysplastic leukoplakia (11) and genetic changes, particularly, at chromosome 3, have been demonstrated in the majority of keratotic and non-dysplastic lesions (12).

This study evaluated the cell proliferation rates in the most frequent cases of non-dysplastic leukoplakias, hyperkeratosis (H), acanthosis (A), and hyperkeratosis with acanthosis (HA). The aim of this study was to analyze whether these three non-dysplastic leukoplakias had similar cell proliferation rates and to compare them with epithelial dysplastic (ED) leukoplakias and normal oral epithelium (NOE).

Material and Methods

The sample comprised 10 gingival specimens of NOE and 40 cases of oral leukoplakia, whose patients were submitted to biopsies at the Dentistry School of the Universidade Federal do Rio Grande do Sul. The average age of patients diagnosed with oral leukoplakia was 50.3 years old. The sample was composed of 19 males and 21 females. All patients included in this study presented clinically solitary, homogenous and non-ulcerative leukoplakia, and absence of *Candida albicans*. The patients were followed-up for a period of 3 to 5 years and presented no recurrence, new leukoplakia lesion or progression to oral squamous cell carcinoma. All lesions were submitted to excisional biopsies, as they did not exceed 2cm. The most common anatomic site of the leukoplakias was in gingiva (n=15) followed by tongue (n=9), buccal mucosa (n=7), lip (=6), palate (n=2) and floor of the mouth (n=1). The race of the subjects was

scored as "white" (n=37) or "non-white" (n=3), since the study group included only a small percentage of other ethnic groups.

Based on a previous study our group (unpublished), in the macroscopic analysis, the fragment was sectioned longitudinally at the central portion, and in the preparation of paraffin blocks, the two fragments were positioned so that the histological sections could show the whole extension of the epithelium in the center of the lesion.

All 40 specimens with clinical leukoplakia diagnoses presented the following microscopic diagnoses: acanthosis (n=10), hyperkeratosis (hyperparakeratosis and hyperorthokeratosis) (n=10), hyperkeratosis with acanthosis (n=10) and epithelial dysplasia (n=10).

Hyperkeratosis was defined as an increase in the thickness of the keratin layer; and acanthosis, as an increase in the number of cells in the prickle layer with preserved epithelial stratification and no cellular atypia. When these two disorders were found together, specimens were classified as having hyperkeratosis with acanthosis. These diagnoses always contemplated the peculiarities of the anatomic site where the lesion occurs. Epithelial dysplasia was defined as at least two architectural and two cytological abnormalities, classified according to the World Health Organization criteria (3).

Architectural abnormalities were: irregular epithelial stratification, loss of polarity of basal cells, drop-shaped rete ridges, increased number of mitotic figures, abnormally superficial mitoses, dyskeratosis, and keratin pearls within rete ridges. Cytological disorders were: abnormal variation in nuclear size and shape and in cell size, cellular pleomorphism, increased nuclear-cytoplasmic ratio, atypical mitotic figures, increased number and size of nucleoli, and hyperchromasia (3).

There is a substantial interobserver and intraobserver variation in the histopathological assessment of the presence and severity of epithelial dysplasia (3). It was suggested that a binary system to assess dysplasia (no/questionable/mild-low risk; moderate/severe-high risk) may increase the likelihood of agreement between pathologists (13). Our option in this study was to classify epithelial dysplasia as absent or present, mainly because our focus was to analyze non-dysplastic leukoplakias and use dysplasia just as a positive control of a potentially malignant disorder.

Two 3- μ m sections were obtained from each paraffin block; one was stained with haematoxylin-eosin (HE) for morphological analysis and adjustment between the two examiners (M.S.F. and L.C.H.); and the other one was stained for visualization of AgNORs and evaluation of epithelial proliferation rate according to the method described by Ploton et al. (14). Silver staining was performed at 25° C for 25 minutes. Typical microscopic fields from each disorder were selected on the HE-stained slides (Fig.1. A, B, C and D). Correspond-

ing images of the silver-stained slides were captured using a video camera (JVC™, 1 CCD, TK-C 620, color: JVC, Yokohama, Japan) coupled to a binocular microscope (CH 30, Olympus Optical Co. Ltd., Tokyo, Japan) at 400x magnification. The images were recorded at a 440 x 330 pixel resolution using Microsoft VidCap for Windows 95 (Microsoft Corp., Redmond, WA, USA) installed on an Aquanta DX computer (Unisys, Blue Bell, Pennsylvania, USA).

Images were transferred to the Imagelab™ 2.3 software (Sistema de Processamento e Análise de Imagens, Softium-Sistemas de Informática, São Paulo, Brazil). AgNOR counts were obtained using the software’s manual count tool.

The basal layer had cells with at least one contact surface with the basement membrane. The parabasal layer was more superficial than the basal layer and was found within two layers above the basement membrane and next to the basal layer (15). However, the shape of parabasal layer cells was not flattened, which is typical of superficial layer cells. Microscopic fields with subepithelial inflammatory infiltrate, overlapping cells, and areas of artifact were excluded. On each slide, 100 to 150 nuclei per layer were assessed.

AgNOR counts were recorded as mean AgNOR number per nucleus (mAgNOR) and percentage of cells with 1, 2, 3 and 4 or more AgNOR counts per nucleus (pAgNOR). Dots that could not be distinguished from each other were counted as a single dot, following the standardized counting method described by Crocker et al. (16).

Examiners were trained by an advising professor to standardize counting criteria. Intraobserver adjustment for AgNOR counting was conducted by recounting one out of every six images. The readings obtained in the first and second counts were compared using Student’s t test for paired samples ($p>0.6$). An examiner who was unaware of which group the slides belonged to performed the analysis.

Analysis of variance (ANOVA) was used to compare the means between groups since the data followed normal distribution, as verified by Kolmogorov Smirnov test. Statistical significance was considered when $p<0.05$. Tukey test was performed for multiple comparison. The data were processed and analyzed using the Statistical Package for the Social Sciences (SPSS) version 10.0.

This study was approved by the Research and Ethics Committee of the School of Dentistry, Universidade Federal do Rio Grande do Sul (no. 90/02).

Results

AgNORs were seen as black dots in the yellow nucleus of epithelial cells in all groups (Fig.1. E, F, G and H). The results of mAgNOR showed differences between disorders in the evaluation of the basal layer, of the parabasal layer, and in the overall evaluation. Overall results showed that proliferation rate was higher in A and ED than in NOE. The values of mAgNOR increased progressively from NOE to HA, H, A and ED. The NOE group showed significantly lower mAgNOR values in the basal layer than the ED group. In A, ED and H, mAgNOR in the parabasal layer was significantly higher than in NOE. In groups A and ED, pAgNOR=1 was lower and mAgNOR was statistically greater than in NOE (Tables 1 and 2). When pAgNOR was compared between groups, cells with 1 AgNOR count per nucleus were predominant (Table 2). The NOE group had the highest percentage of cells with 1 AgNOR count. Statistically significant differences in pAgNOR=2 were detected between A, ED and NOE. The behavior of this parameter was similar to that of mAgNOR, with the number of AgNOR counts per nucleus increasing progressively from NOE to HA, H, A and ED. None of the two AgNOR counting methods was capable to distinguish between the different types of epithelial disorders.

Table 1. Proliferative activity evaluation by means of mAgNOR distribution in normal oral epithelium and in oral epithelial disturbances.

	n	Basal Layer		Parabasal Layer		Overall	
		Mean (SD)	p	Mean (SD)	p	Mean (SD)	p
Normal oral epithelium	10	1.49 (0.26) ^B	0.014*	1.39 (0.16) ^B	0.01*	1.43 (0.17) ^A	0.01*
Hyperkeratosis	10	1.78 (0.29) ^{AB}		1.96 (0.51) ^A		1.87 (0.39) ^{AB}	
Hyperkeratosis with acanthosis	10	1.74 (0.48) ^{AB}		1.83 (0.42) ^{AB}		1.84 (0.52) ^{AB}	
Acanthosis	10	1.89 (0.30) ^{AB}		1.98 (0.43) ^A		1.94 (0.35) ^B	
Epithelial Dysplasia	10	2.12 (0.71) ^A		2.01 (0.28) ^A		2.02 (0.32) ^B	

Means (with standard deviation in parentheses) followed by the same letter are not significantly different from each other (ANOVA $p>0.05$).

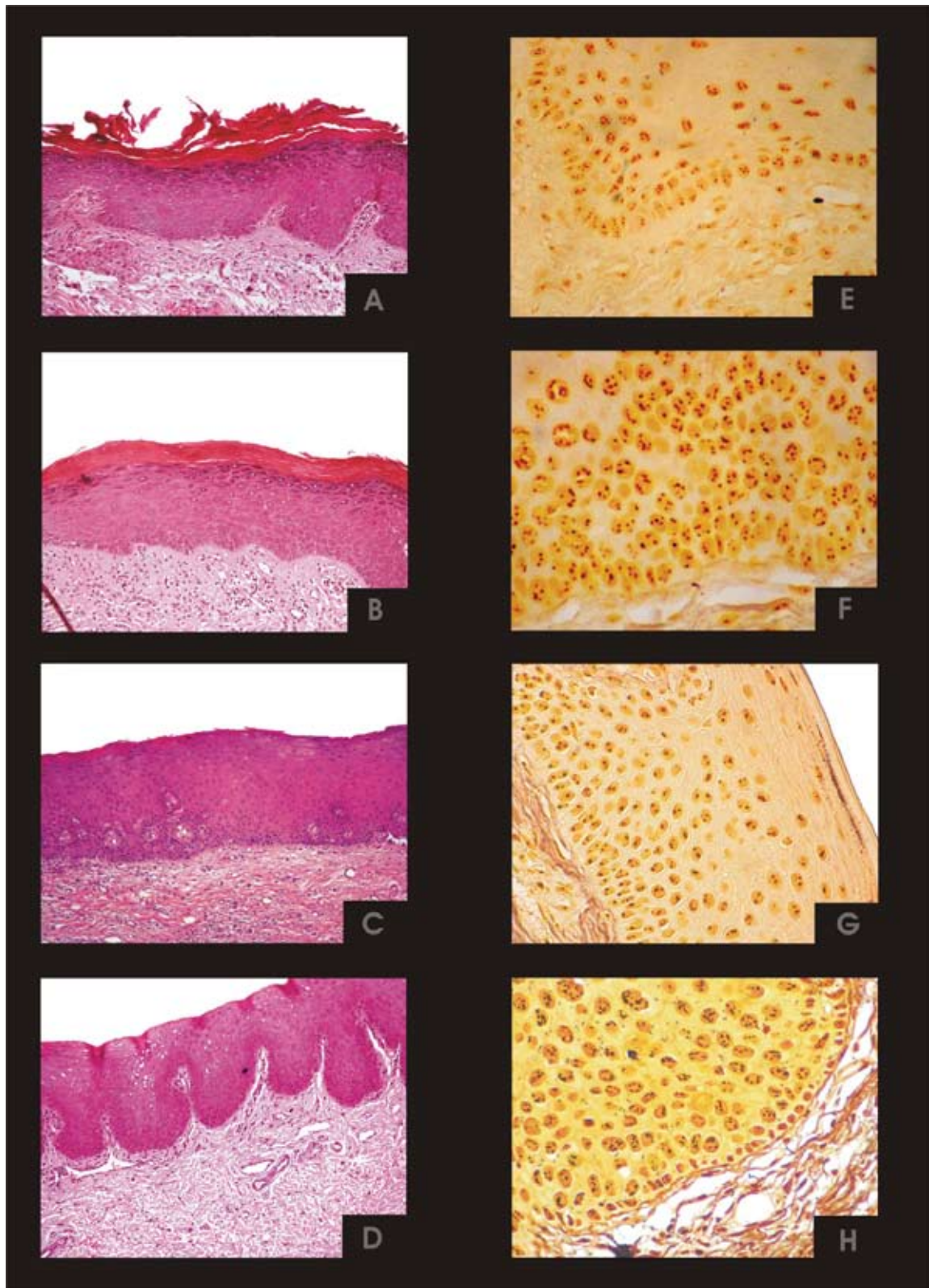


Fig. 1. Photomicrograph of HA (a: HE-stained; e: AgNOR-stained) H (b: HE-stained; f: AgNOR-stained), A (c: HE-stained; g: AgNOR-stained) and ED (d: HE-stained; h: AgNOR-stained). Original magnification 200x (HE) and 400x (AgNOR).

Table 2. Proliferative activity evaluation by means of pAgNOR distribution in normal oral epithelium and in oral epithelial disturbances.

Overall Layers	n	p AgNOR=1		p AgNOR=2		p AgNOR=3		p AgNOR≥4	
		Means (SD)	p	Means (SD)	p	Means± SD	p	Means (SD)	p
Normal oral epithelium	10	65.07 (12.19) ^A	0.01*	27.27 (7.85) ^A	0.01*	6.45 (4.46) ^A	0.02*	1.21(1.16)	0.12
Hyperkeratosis	10	45.13±13.84 ^B		32.88(2.54) ^{AB}		15.62 (8.88) ^{AB}		6.37(7.22)	
Hyperkeratosis with acanthosis	10	46.41 (20.16) ^B		32.04 (5,96) ^{AB}		15.06 (10.05) ^{AB}		6.60 (10.31)	
Acanthosis	10	39.33 (11.53) ^B		37.33 (4.87) ^B		16.31(7.77) ^{AB}		7.02(6.58)	
Epithelial Dysplasia	10	37.25 (9.66) ^B		34.77 (5.30) ^B		18.15 (7.26) ^B		9.84(7.01)	

Means (with standard deviation in parentheses) followed by the same letter are not significantly different from each other (ANOVA p>0.05).

Discussion

Oral leukoplakia has been extensively studied in the literature, and most studies have compared dysplastic with non-dysplastic leukoplakias classified into a single group. This study assessed the differences in cell proliferation rates between three non-dysplastic lesions and compared them with normal oral epithelium and epithelial dysplasia. Studies of epithelial disorders in leukoplakias showed that epithelial dysplasia was frequently associated with an increased risk of malignant transformation. However, several studies showed that malignant transformation might occur even when epithelial dysplasia was absent (11,13,17).

The border of the tongue and the floor of the mouth have been considered as high-risk sites in cancer development (11). At the same time, leukoplakia can affect any site of the oral cavity (3). Johann et al. (18) in a study of metallothionein immunoexpression in oral leukoplakia, showed no significant difference between regions of high and low risk of malignant change. In this study, the inclusion criteria were targeted at standardizing some aspects of the sample, such as clinical aspect and lesion size. In addition, we were careful to consider the morphological characteristics of the anatomic site of lesions in the histopathological analysis.

In a previous study (unpublished), in which lesions with histopathological diagnosis of hyperkeratosis with acanthosis, hyperkeratosis and dysplasias were examined in three or more step sections distributed throughout the specimen; and in which the number of step sections depended on the size of the specimens, 23.5% of the cases of hyperkeratosis and hyperkeratosis with acanthosis showed areas of dysplasia. Based on these results, we adopted the excisional biopsy protocol for leukoplakias with a single lesion measuring around 2cm. In the macroscopic analysis, these specimens were sectioned longitudinally at the central portion and embedded in paraffin blocks in such a way that the histological slide could show the whole extension of the epithelium of

both halves. We thus believe that the histopathological diagnosis reflects the true nature of the lesion. Holmstrup et al. (19), in a retrospective study to learn whether an incisional biopsy of oral premalignant lesions, leukoplakia and erythroplakia, showed histopathological findings representative of the whole surgically removed lesion, observed underdiagnosis in 35% of the incisional biopsies, and stepwise sectioning revealed seven unexpected carcinomas (7%).

Although the biological significance of AgNOR counts has not been fully explained so far, the association between AgNOR counts and cell cycle kinetics has been demonstrated in many studies. The link between cell proliferation, cancer and nucleolar activity has been well established during the past several decades (5). It was shown that AgNOR counts may be associated with other proliferation markers, such as PCNA and Ki-67 (20), and that their counts may be reliable proliferation markers. We believe that AgNOR counts should not be directly compared with other usual proliferation markers. AgNOR counts provide information about the rate at which cells are dividing, whereas usual immunohistochemical markers indicate only whether cells are or are not undergoing division. Kaplan, Engelberg, and Dayan (21) found strong evidence of AgNOR sensitivity in the early detection of intranuclear changes. Chattopadhyay and Ray (22) suggested the use of a 2.3 cutoff point to distinguish between mild and moderate dysplastic leukoplakias. Although such measurements are important, comparisons between studies are difficult because of the use of different AgNOR protocols and counting methods.

Xie et al. (4) used mAgNOR counts and found that proliferation rates increased from normal epithelium to leukoplakia and to carcinoma, but were not able to distinguish dysplastic from non-dysplastic leukoplakias. Our findings are in agreement with their results: we were also unable to detect significantly different proliferation rates between H, HA, A and ED, and this may

be due to the limited number of samples collected for this study. However, Warnakulasuriya and Johnson (9) found lower mAgNOR values in hyperkeratosis than in dysplasia and squamous cell carcinoma.

According to Xie et al. (4), the evaluation of pAgNOR is easier and less cumbersome to perform than the conventional mAgNOR technique, and it does not need sophisticated equipment as is required for area measurement. In our opinion, pAgNOR provides a more complete evaluation of epithelial renewal than mAgNOR and measures the number of cells that are proliferating faster in the tissue under study. Our study showed that ED had a higher number of pAgNOR=3 and pAgNOR \geq 4 than NOE (Table 2), which indicates that ED had more cells proliferating fast than NOE. A and ED had significantly higher numbers of pAgNOR=2 than NOE, a finding similar to that observed for mAgNOR. This was expected because A had an increased proliferative activity in the prickle cell layer, and at least part of it was analyzed in the parabasal layer. The most reliable parameter was pAgNOR because it detected the highest cell proliferation rate in A. Our results showed that the proliferative behavior of A is similar to that of ED. Further studies should investigate other features of acanthosis, such as cell adhesion and collagen degradation, to improve our knowledge about this disorder.

Previous studies demonstrated the role of the parabasal layer in the increase of cell proliferation to maintain tissue homeostasis against exogenous stimuli (15). We believe that progressive enlargement of proliferative compartments may be a sign of the progression of the malignant process. Shin et al. (23) found a gradual increase in PCNA labeling index in basal, parabasal and superficial layers, and that this index reached its highest value in dysplastic epithelium. We agree with Liu et al. (8), who suggested that the analysis of superficial and basal layers is the most useful tool to distinguish between normal and abnormal epithelium. Differences may be more difficult to detect in the basal layer because it is constantly undergoing physiological division. Therefore, our results suggest that the most useful layer for the detection of cell proliferation disorders is the parabasal layer, which is in agreement with the findings by Liu et al. (8) and Oliver et al. (15). In the oral epithelium, asymmetrical cell division in epithelial stem cells located in the basal layer may produce transient amplifying cells located in the parabasal layer. In addition, loss of asymmetrical cell division may lead to increasing numbers of stem cells in the parabasal layer, as shown by the increase in p63 positive cells (24). It is well established that the loss of basal cell polarity is a histological criterion and a hallmark of cellular atypia in epithelial dysplasia.

In summary, our results showed that these three non-dysplastic leukoplakias had some differences in cell

proliferation rates among them and that some results were similar to those found in ED. These results suggest that more detailed studies of non-dysplastic leukoplakias biological profiles are needed due to the different results of each cell proliferation rate, in particular acanthosis.

References

1. Kramer IR, Lucas RB, Pindborg JJ, Sobin LH. Definition of leukoplakia and related lesions: an aid to studies on oral precancer. *Oral Surg Oral Med Oral Pathol.* 1978;46:518-39.
2. Waldron CA, Shafer WG. Leukoplakia revisited. A clinicopathologic study 3256 oral leukoplakias. *Cancer.* 1975;36:1386-92.
3. Van der Waal I. Potentially malignant disorders of the oral and oropharyngeal mucosa; terminology, classification and present concepts of management. *Oral Oncol.* 2009;45:317-23.
4. Xie X, Clausen OP, Sudbø J, Boysen M. Diagnostic and prognostic value of nucleolar organizer regions in normal epithelium, dysplasia, and squamous cell carcinoma of the oral cavity. *Cancer.* 1997;79:2200-8.
5. Sirri V, Urcuqui-Inchima S, Roussel P, Hernandez-Verdun D. Nucleolus: the fascinating nuclear body. *Histochem Cell Biol.* 2008;129:13-31.
6. Derenzini M, Trerè D, Pession A, Govoni M, Sirri V, Chieco P. Nucleolar size indicates the rapidity of cell proliferation in cancer tissues. *J Pathol.* 2000;191:181-6.
7. Chimenos-Küstner E, Font-Costa I, López-López J. Oral cancer risk and molecular markers. *Med Oral Patol Oral Cir Bucal.* 2004;9:381-4; 377-80.
8. Liu SC, Sauter ER, Clapper ML, Feldman RS, Levin L, Chen SY, et al. Markers of cell proliferation in normal epithelia and dysplastic leukoplakias of the oral cavity. *Cancer Epidemiol Biomarkers Prev.* 1998;7:597-603.
9. Warnakulasuriya KA, Johnson NW. Nucleolar organizer region (NOR) distribution as a diagnostic marker in oral keratosis, dysplasia and squamous cell carcinoma. *J Oral Pathol Med.* 1993;22:77-81.
10. Pich A, Chiusa L, Margaria E. Prognostic relevance of AgNORs in tumor pathology. *Micron.* 2000;31:133-41.
11. Holmstrup P, Vedtofte P, Reibel J, Stoltze K. Long-term treatment outcome of oral premalignant lesions. *Oral Oncol.* 2006;42:461-74.
12. Schwarz S, Bier J, Driemel O, Reichert TE, Hauke S, Hartmann A, et al. Losses of 3p14 and 9p21 as shown by fluorescence in situ hybridization are early events in tumorigenesis of oral squamous cell carcinoma and already occur in simple keratosis. *Cytometry A.* 2008;73:305-11.
13. Warnakulasuriya S, Reibel J, Bouquot J, Dabelsteen E. Oral epithelial dysplasia classification systems: predictive value, utility, weaknesses and scope for improvement. *J Oral Pathol Med.* 2008;37:127-33.
14. Ploton D, Menager M, Jeannesson P, Himer G, Pigeon F, Adnet JJ. Improvement in the staining and in the visualization of the argyrophilic proteins of the nucleolar organizer region at the optical level. *Histochem J.* 1986;18:5-14.
15. Oliver RJ, MacDonald DG, Felix DH. Aspects of cell proliferation in oral epithelial dysplastic lesions. *J Oral Pathol Med.* 2000;29:49-55.
16. Crocker J, Boldy DA, Egan MJ. How should we count AgNORS? Proposals for a standardized approach. *J Pathol.* 1989;158:185-8.
17. Hsue SS, Wang WC, Chen CH, Lin CC, Chen YK, Lin LM. Malignant transformation in 1458 patients with potentially malignant oral mucosal disorders: a follow-up study based in a Taiwanese hospital. *J Oral Pathol Med.* 2007;36:25-9.
18. Johann AC, Da Silveira-Júnior JB, Souto GR, Horta MC, Aguiar MC, Mesquita RA. Metallothionein immunorexpression in oral leukoplakia. *Med Oral Patol Oral Cir Bucal.* 2008;13:E156-60.
19. Holmstrup P, Vedtofte P, Reibel J, Stoltze K. Oral premalignant

- lesions: is a biopsy reliable? *J Oral Pathol Med.* 2007;36:262-6.
20. Migaldi M, Criscuolo M, Zunarelli E, Lo Bianco L, Martinelli AM, Barbolini G. p120 and AgNOR nucleolar protein expression: a comparison with nuclear proliferation markers in oral pathology. *Oral Surg Oral Med Oral Pathol Oral Radiol Endod.* 1998;85:189-96.
21. Kaplan I, Engelberg J, Dayan D. The effect of desalivation on 4-nitroquinoline-1-oxide-induced tongue carcinogenesis: a morphometric study of nucleolar organizer regions. *J Oral Pathol Med.* 2001;30:48-52.
22. Chattopadhyay A, Ray JG. AgNOR cut-point to distinguish mild and moderate epithelial dysplasia. *J Oral Pathol Med.* 2008;37:78-82.
23. Shin DM, Kim J, Ro JY, Hittelman J, Roth JA, Hong WK, et al. Activation of p53 gene expression in premalignant lesions during head and neck tumorigenesis. *Cancer Res.* 1994;54:321-6.
24. Glickman JN, Yang A, Shahsafaei A, McKeon F, Odze RD. Expression of p53-related protein p63 in the gastrointestinal tract and in esophageal metaplastic and neoplastic disorders. *Hum Pathol.* 2001;32:1157-65.