

Journal section: Oral Surgery
 Publication Types: Research

doi:10.4317/medoral.15.e483

A comparative study of platelet-rich plasma, hydroxyapatite, demineralized bone matrix and autologous bone to promote bone regeneration after mandibular impacted third molar extraction

Jorge Arenaz-Búa ¹, Ramón Luaces-Rey ², Sheila Sironvalle-Soliva ¹, Beatriz Patiño-Seijas ², Álvaro García-Rozado ², Roberto Martín-Sastre ², José Ferreras-Granados ², Fernanda Lorenzo-Franco ², Inés Vázquez-Mahía ², José-Luis López-Cedrún ³

¹ Resident. Department of Oral and Maxillofacial Surgery, Complejo Hospitalario Universitario de A Coruña

² Staff. Department of Oral and Maxillofacial Surgery, Complejo Hospitalario Universitario de A Coruña

³ Head of Department Department of Oral and Maxillofacial Surgery, Complejo Hospitalario Universitario de A Coruña

Correspondence:

Travesía de Cordelería N°1 4° Izq
 15003 La Coruña (La Coruña), Spain
jorgearenaz@gmail.com

Arenaz-Búa J, Luaces-Rey R, Sironvalle-Soliva S, Patiño-Seijas B, García-Rozado A, Martín-Sastre R, Ferreras-Granados J, Lorenzo-Franco F, Vázquez-Mahía I, López-Cedrún JL. A comparative study of platelet-rich plasma, hydroxyapatite, demineralized bone matrix and autologous bone to promote bone regeneration after mandibular impacted third molar extraction. Med Oral Patol Oral Cir Bucal. 2010 May 1;15 (3):e483-9. <http://www.medicinaoral.com/medoralfree01/v15i3/medoralv15i3p483.pdf>

Received: 25/02/2009
 Accepted: 12/09/2009

Article Number: 2721 <http://www.medicinaoral.com/>
 © Medicina Oral S. L. C.I.F. B 96689336 - pISSN 1698-4447 - eISSN: 1698-6946
 eMail: medicina@medicinaoral.com
Indexed in:
 -SCI EXPANDED
 -JOURNAL CITATION REPORTS
 -Index Medicus / MEDLINE / PubMed
 -EMBASE, Excerpta Medica
 -SCOPUS
 -Indice Médico Español

Abstract

Objectives: 1) to compare mandibular bone regeneration by applying autologous bone, platelet-rich plasma and two biomaterials (synthetic calcium hydroxyapatite, and demineralized bone matrix), and thus establish the potential benefits of these biomaterials in the regeneration of postextraction alveolar bone, 2) to identify which of them accelerates more bone regeneration and 3) to determine whether there are differences in the postoperative period (pain, swelling, trismus, infection) depending on the material used.

Study Design: It consists in a prospective, controlled (with a split-mouth design) and double blinded study. We use as a model an easily reproducible non-critical bone defect: the defect that remains after extraction of mandibular impacted third molar. The study design is based on the extraction of two mandibular impacted third molars in a patient during the same surgical procedure by the same surgeon. We assessed postoperative clinical data, and short, medium and long term neoformation of alveolar bone after extraction. We compared the two sockets (right and left), which had been grafted in a different way with the various elements mentioned above. In addition, we compared the postoperative inflammatory symptoms between groups.

Results: The highest acceleration in bone formation was observed in groups in which we used autologous bone and demineralized bone matrix. There were no statistically significant differences between groups regarding pain, swelling, trismus and infection throughout the postoperative period.

Conclusions: According to the results of our study, autologous bone persists as the gold standard material for bone regeneration. Among the assessed biomaterials, demineralized bone matrix has yielded the best results obtained. No significant differences in the postoperative (pain, swelling, trismus and infectious events) were observed, depending on the type of material used as a graft.

Key words: Platelet-rich plasma, third molar, demineralized bone matrix, bone regeneration, calcium hydroxyapatite.

Introduction

The study of materials to promote bone regeneration is a key issue in oral surgery. The autologous bone is still considered as the gold standard (1-10). Autologous bone grafts have a number of advantages such as their potential osteogenic, osteoinductive and osteoconductor properties, the absence of rejection and disease transmission. Furthermore, autologous bone grafts do not require sophisticated and expensive techniques to obtain them (6). However a number of disadvantages were described: morbidity in the donor site, the need for general anesthesia or sedation, as well as the occasional need for more than one surgical field. In addition, graft survival is unpredictable, its resorption cannot be foretold and availability is limited (6).

It is for the reason that in recent years several biocompatible materials have emerged as substitutes of autologous bone. These can be classified into two major groups: organic and synthetic. Biological biomaterials can be allogeneic or homologous (human cortical bone and demineralised bone matrix or demineralized freeze-dried), heterologous, or xenogeneic (organic bovine, porcine, caprine, coral-derived hydroxyapatite) and replicating (morphogenetic proteins). Among synthetic biomaterials we can find artificial or synthetic hydroxyapatite, the bioglass and bioceramics (6).

In addition, over the last 20 years a large number of publications advocating the use of platelet-rich plasma (PRP) in oral surgery have been published. There is evidence and consensus on its utility in the regeneration of soft and periodontal tissues (1-4, 11-13). On the other hand, there are plenty of publications that show that there is not enough scientific evidence to support the use of PRP in accelerating bone healing.

Therefore there are many biomaterials available for the oral surgeon's use to promote bone healing. But the exact indication of each of them remains controversial. There is no therapeutic consensus algorithm, and there are few clinical trials with sufficient statistical power (6,14).

Our hypothesis is that the PRP and other biomaterials such as calcium hidroxipatita synthetic and demineralized bone matrix can replace autologous grafts in promoting bone regeneration in mandibular bone defects.

Objectives

To determine the role and usefulness of the PRP and other biomaterials (synthetic calcium hydroxyapatite and allogenic, demineralized bone matrix) in mandibular bone regeneration compared with autologous bone (gold standard). We use as a model an easily reproducible non-critical bone defect: the defect that remains after extraction of mandibular impacted third molar.

Therefore, the aim of this study was to try to answer the following questions:

- Are there differences in the rate of bone formation

in the postextraction socket among those grafted with PRP and controls (not grafted)?

- Are there differences in the neoformation of bone between the two different procedures to obtain platelet-rich plasma (PRP)?
- Which biomaterial accelerates more bone regeneration in non-critical mandibular bone defect ?
- Are there significant differences between them with each other and with respect to autologous bone in the acceleration of bone neoformation?
- Are there differences in the clinical inflammatory and postoperative (postoperative pain, intraoral-extraoral swelling, trismus) and infectious events observed depending on the material used to graft the socket?

Material and Methods

The study was carried out between the years 2003 and 2006 in the Department of Oral and Maxillofacial Surgery of the Complejo Universitario de A Coruña. This is a prospective, randomized, controlled (through a split-mouth desing), and double blinded study. This study was approved by the bioethics committee of the Juan Canalejo Hospital on January 25th 2003 and has been subsidized by the General Directorate of R & D of the Xunta de Galicia and the Galician Health Service (2005, code PGIDIT 5SAN59PR).

Inclusion criteria. To carry out this study we selected 82 patients with bilateral impacted mandibular third molars, taking into account the following inclusion criteria:

- Aged between 18 and 50 years old.
- Impacted mandibular third molar 3.8. and 4.8, with a similar anatomical position, and similar surgical difficulty.
- The patient signed the informed consent to carry out the intervention and for inclusion in the study.
- No allergies to medicines prescribed in the postoperative period.
- To follow the same postoperative treatment: Amoxicillin 500 mg every 8 hours during 7 days, deflazacort 30 mg every 12 hours for 5 days and metamizol 575 mg every 8 hours to demand.

Study groups. The patients were divided into 5 groups (Table 1). In two groups (groups 1 and 2) we compared the control socket (no biomaterial) with the study socket (platelet-rich plasma). These two groups differ in the methodology used in obtaining the PRP (methods 1 and 2 respectively). In groups 3, 4 and 5, we administered PRP obtained by the same method (Method 1) on the control side, compared with the study side in which we administered a combination of PRP with another product:

- Autologous bone obtained from aspiration and filtering during the osteotomy (group 3).
- A synthetic material based on synthetic calcium hydroxyapatite (Novabone ® Porex Surgical Inc, MTF, USA) (group 4).

Table 1. Study groups. ("PRP Method 1" and "PRP Method 2": platelet-rich plasma obtained by two different procedures, respectively called 1 and 2 "ANY MATERIAL": there is no material in the postextraction socket).

	CONTROL SOCKET	STUDY SOCKET	FREQUENCY	PERCENTAGE
GROUP 1	ANY MATERIAL	PRP METHOD 1	19	23,2%
GROUP 2	ANY MATERIAL	PRP METHOD 2	15	18,3%
GROUP 3	PRP METHOD 1	AUTOLOGOUS BONE + PRP 1	19	23,2%
GROUP 4	PRP METHOD 1	PRP METHOD 1+NOVABONE [®]	15	18,3%
GROUP 5	PRP METHOD 1	PRP METHOD 1+ DBX [®]	14	17,1%

• Allogeneic demineralized bone matrix (DBX[®], Synthes, USA) (group 5).
Surgery. Extractions of both mandibular third molars was performed under local anesthesia. All extractions were performed by the same surgeon. Both post-extraction

sockets were grafted with different biomaterials, according to the distribution of the study groups (Fig. 1). All patients received the same antibiotic, anti-inflammatory and analgesic postoperative treatment.
Monitoring and variables. (Fig. 2). The studied pre-

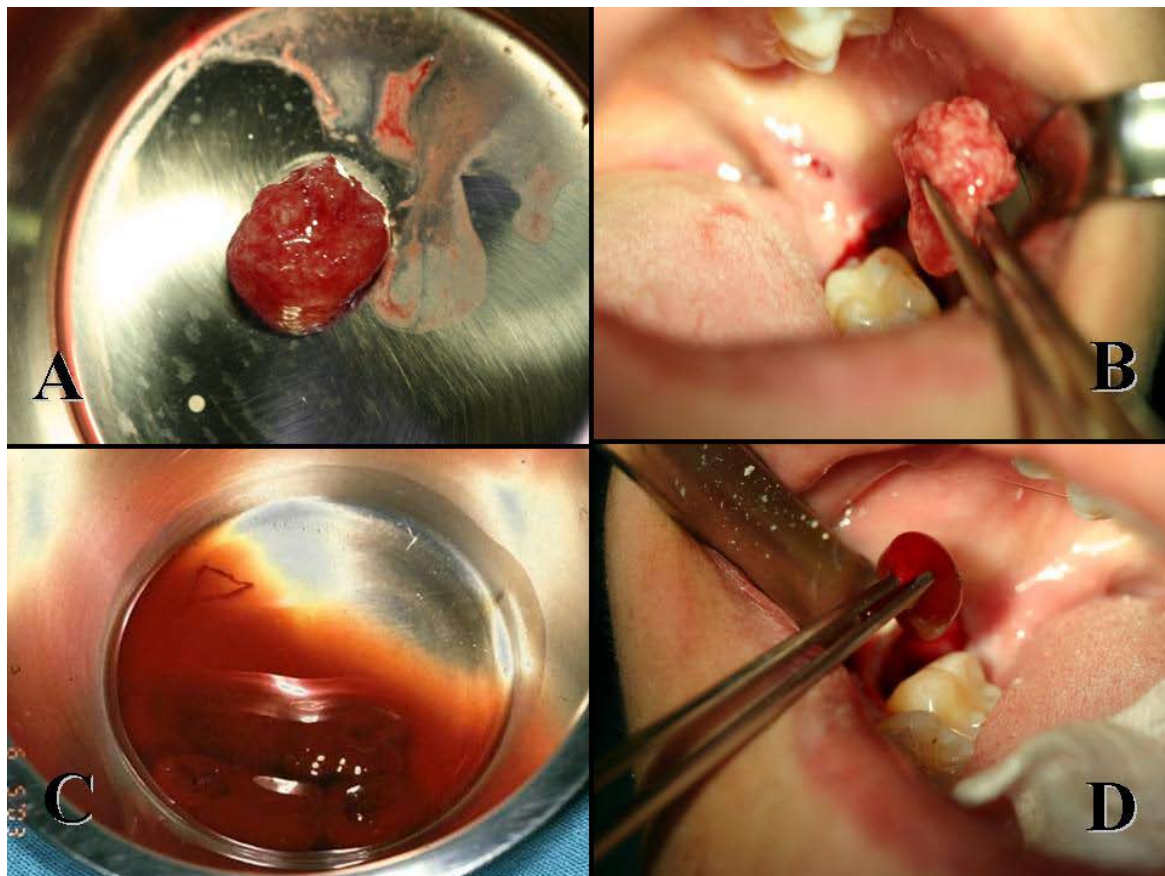


Fig. 1. Group 3: a mixture of autologous bone collected by filtration during the osteotomy and platelet-rich plasma is obtained (A) and applied in the postextraction socket (B). Note that PRP facilitates the manipulation of the particulate bone graft. The rest of the platelet-rich plasma obtained by the same method as above (C) is applied alone in the socket of the control side (D).

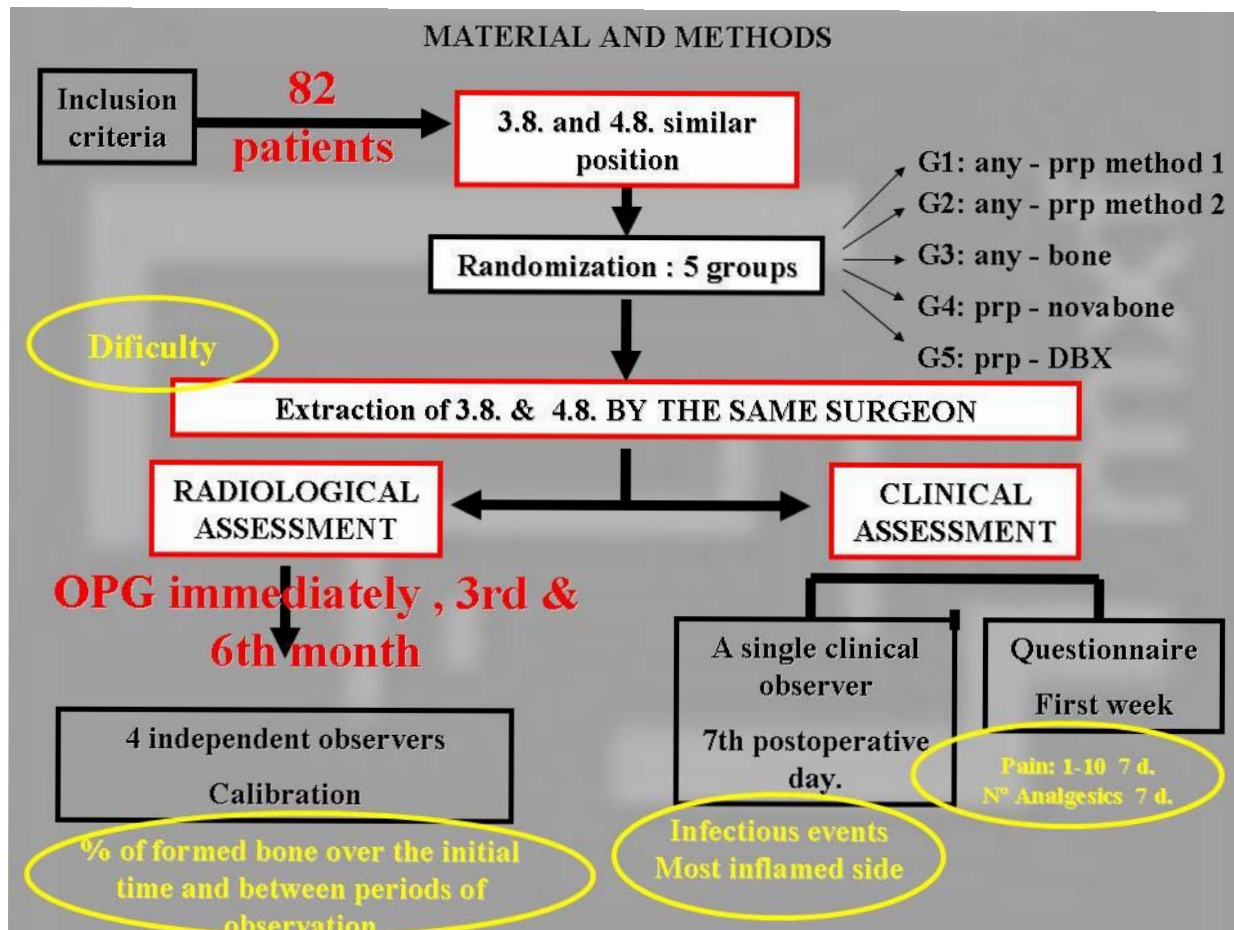


Fig. 2. Schematic summary of material and methods. (PRP: platelet-rich plasma, G1, G2, G3, G4, G5: groups 1, 2, 3, 4 and 5 respectively; DBX: demineralized bone matrix; OPG: orthopantomography).

dictor variables were age, sex of the patient, difficulty of intervention (easy, intermediate or high difficulty, assessed in terms of surgical time by an experienced surgeon), and type of material used in the filling of the postextraction socket.

We assessed several response variables on the postoperative evolution in two ways. On the one hand, through a clinical questionnaire that each patient completed daily throughout the first postoperative week. This questionnaire assessed pain (using two methods: an analog pain scale from 1 to 10 points, and the number of analgesics to control pain consumed on each of the first 7 postoperative days) as well as the number of days that passed until the restart of a normal diet. On the other hand, a single clinical observer performed a clinical assessment in the 7th postoperative day. This observer assessed the most inflamed side, decreased mouth opening measured in mm compared to that observed at the time of the intervention, and the occurrence of infectious events. This clinical observer was blinded for whether or not socket grafting was performed, and the type of grafted material. In this appointment, the questionnaire mentioned above was collected.

In addition we compared the bone formation on both sides using digital panoramic obtained in the immediate postoperative period, at the 3 and in 6 months after the surgery. The measurement of bone neoformation was performed subjectively but blindly, recording the score in a radiopaque increasing scale (1, minimal or radiopaque bone formation 5, maximum or radiopaque bone formation) by 4 blinded observers, who were staff surgeons of the research team. A process of calibration between the different observers took place before to assess the degree of concordance. The observers were blinded as to the type of material used for grafting the postextraction socket. Although this material is partially radiopaque (such as calcium hydroxyapatite), this radiopacity is not considered formed bone. For an expert observer (as the ones in the study) it is not difficult to differentiate between the neoformation of bone and the radiopacity produced by the existence of a biomaterial. In addition, due to resorption of the grafted material, there is no possibility of bias in the assessment at 6 and 3 months. CT and bone biopsy were excluded for economic and ethical reasons.

The data obtained were statistically analyzed with the SPSS 16.0 for Windows (SPSS Inc. 2006).

Platelet-rich plasma. PRP was obtained in two different services of Hematology: the Hematology Service of the Hospital Universitario de A Coruña (Method 1), and the Hematology Service of the Hospital “Arquitecto Marcide” Ferrol (method 2). Both methods use a double-spin system, but with different parameters and different methods for extracting the supernatant (using a laminar flow hood and another by pipetting).

Results

Of the 82 patients included in the study 37 were males and 45 were females. The median age of patients in our study is 23 years, with a minimum of 18 years and maximum of 45 years (mean: 24.16; typical dev: 5.76).

The distribution of study groups according to the material used is as shown in (Table 1). We observed a greater degree of surgical difficulty in the extraction in group 3 (autologous bone) and 5 (DBX®) on the control side as well as on the study side. In what refers to the pain recorded by patients on the pain analogue scale from 1 to 10, we observed more pain on the study side, although no significant differences between groups were found. However, it an increased use of analgesics in groups 1, 2 and 3 (PRP and bone) compared to groups 4 and 5 (Novabone® and DBX®) with no statistically significant differences between groups was observed. The study groups with more days of dysphagia were 4 and 3 (Novabone® and bone).

Concerning the clinical variables observed on the 7th postoperative day by a blinded clinical observer, we can say that in most cases, both the control and study sides were equally swollen, although there is a greater tendency to inflammation in the study side. There were no statistically significant differences between the studied groups. There is also no statistically significant differences in the incidence of infectious events among the study side and the control side. Intraoral inflammation observed on the 7th postoperative day was higher in group 3 (bone) and 5 (DBX®), although both groups have the greater surgical difficulty, wich could cause a bias. On 7th postoperative day, the greatest percentage of patients with extraoral inflammation belong to group 3 (bone) and 2 (PRP 2). We considered trismus as an oral opening less than 35 mm. The greater percentage of patients with trismus on 7th postoperative day was observed in the gropus 3 (bone) and 4 (Novabone®). The groups with less patient with trismus were the groups 5 (DBX®) and 1 (PRP method 1).

In what regards bone formation, bone gain observed at 3rd postoperative month compared to the immediate postoperative period was higher in groups 1, 2 and 3 (PRP and autologous bone) and lower in groups 4 and 5 (DBX® and Novabone®). Bone formation observed at

6th postoperative month, with respect to 3rd postoperative month is higher in groups 3 (autologous bone) and 5 (DBX®) (p=0,049). The lowest increment was found in groups Novabone® and PRP groups. There is a progressive ossification of the surgical site in all study groups except Novabone® (p=0.0045). The greatest bone formation at 6th postoperative month is observed in group 3 (autologous bone), followed by group 5 (DBX®). The greatest bone gain at 6 months compared to the immediate postoperative period was observed in group 3 (autologous bone) followed by group 5 (DBX®) (Fig. 3).

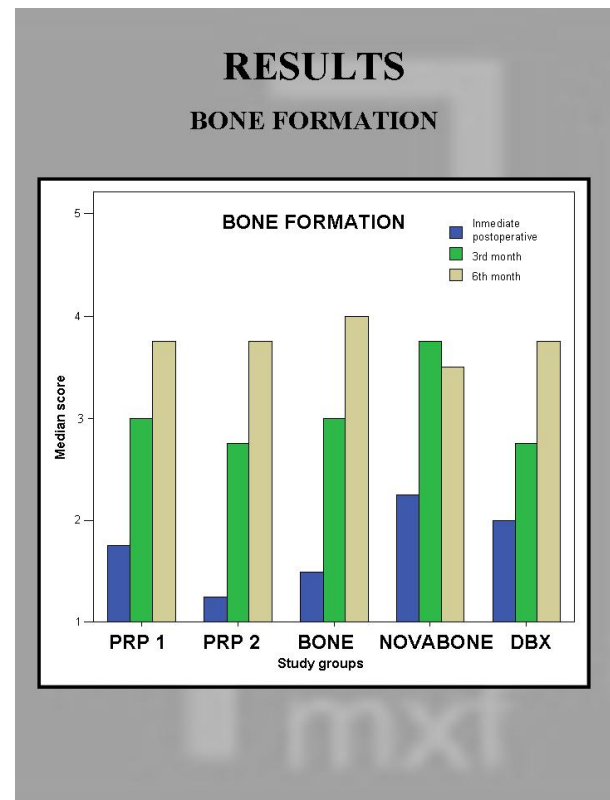


Fig. 3. Schematic summary of results. A diagram shows the median score in the study socket on each moment of follow up. The greater bone formation at 6 months was observed in the group of autologous bone (group 3) followed by DBX® (group 5).

Discussion

The platelet-rich plasma (PRP) is defined as a high concentration of autologous platelets in a small volume of autologous plasma (1,2). These intact platelets contained in this concentrate of autologous plasma would release their alpha granules in the first minutes after their activation. These alpha granules contain molecules such as PDGF, TGFB, IGF, and other angiogenic factors that stimulate proliferation, chemotaxis and differentiation of cells essential to osteogenesis. These molecules could accelerate a process that occurs by itself (it does not cre-

ate a new process). Throughout the past 20 years, PRP has been widely used in many medical applications (to speed up the healing process of burns, chronic ulcers, in the repair knee ligaments, as an hemostatic, to promote retinal neurogenesis, etc.). There are many randomized clinical trials that have established PRP usefulness in the field of soft tissue regeneration. The first article that quotes the use of PRP in oral surgery was published in 1997 by Whitman et al. (3) It states that through the activation of platelets in the platelet gel, and the subsequent release of growth factors, we could expect the acceleration of surgical wound healing (3). Perhaps the most outstanding paper in what refers to platelet-rich plasma in the field of oral and maxillofacial surgery was published by Marx in 1998 (4), who performed 88 autologous bone grafts in human jaws, to half of which these authors added PRP. Marx et al. (4) gathered both radiographic and histomorphometric studies showed greater maturation and bone density, statistically significant compared to the control group. There are several publications for the use of PRP in oral surgery. There is evidence and consensus on its utility in the regeneration of soft tissue and periodontal defects (1-4, 11,12,14). On the contrary there are also plenty of publications that show that nowadays there is not enough scientific evidence to support the use of PRP in accelerating bone healing, and insist that the oral surgeon must take a critical and analytical attitude (5-10, 15) Esposito et al. (6) in a meta-analysis published in 2006 state that there is no reliable evidence to support the effectiveness of any active molecules such as platelet-rich plasma as promoters of bone formation in the treatment of dental implants. Boyapati et al. (7) concluded in his review article of June 2006 "at present, because of limited scientific evidence, the adjunctive use of PRP in sinus augmentation cannot be recommended". Sanchez et al. (10) indicate that there is a clear lack of scientific evidence to support the use of PRP in combination with other graft bone augmentation procedures, even if the grafted material is autologous bone. Besides emphasizing the need for well designed, controlled and randomized studies, before recommending this procedure routinely. Recently, Plachokova et al. (8) found evidence of beneficial effects of PRP in the treatment of periodontal defects but the evidence of beneficial effects in sinus lift seems to be weak. They concluded that considering the literature review in their article conclusions about other applications of PRP in dentistry cannot be drawn.

In our study we didn't observe further acceleration in bone formation at 6 months, either in cases in which PRP was used alone nor in those cases where PRP was mixed with autologous bone or other biomaterials. We didn't find differences between the two different methods of obtaining PRP. Like Thor et al. (9) we found that PRP facilitates and accelerates bone formation in the begin-

ning of the bone healing (the three first months in the postoperative period). This effect is not already observed at the 6th month. So like other authors, we can not support the indication of the use of PRP in this type of bone defect because there is no acceleration of bone healing. We agree with other authors that there is a better healing of soft tissue and increased handling of the graft.

Demineralised bone matrix (DBX®, Synthes, USA) is a suitable substitute for cancellous bone. It presents osteoinductive and osteoconductive properties. These properties are known experimentally since the work of Urist in the 70s (16-19). DBX consists in demineralised bone to which an organic carrier is added (sodium hyaluronate). It is extracted from human cortical bone, by removing the mineral phase and preserving the collagen and morphogenetic proteins (BMPs). Removing the mineral phase enhances the bioavailability of these morphogenetic proteins, which would promote the bone neoformation (17). There is a lot of literature supporting its use as an accelerator of the bone healing. This biomaterial presents multiple applications in oral and craniomaxillofacial surgery (16-19). We have noticed that demineralised bone matrix accelerates significantly bone formation in the studied defect.

Synthetic calcium hydroxyapatite (Novabone granules, Porex Surgical, Inc, MTF, USA) is a synthetic, particulate and inorganic bone. It is biocompatible and resorbable in 6 months (bioglass) and it also presents osteoconductive activity (13,20). We have not observed any benefit in its use to accelerate bone formation in the post-extraction socket.

Conclusions

The faster bone formation occurred in the groups where we used autologous bone and demineralized bone matrix, respectively. Autologous bone remains as the gold standard of materials used to optimize the mandibular bone regeneration. Among the biomaterials compared in the study, demineralized bone matrix is the second most effective in bone neoformation.

We have not observed in our study that the platelet-rich plasma accelerates bone formation in post-extraction sockets. Platelet-rich plasma mixed with other biomaterials facilitates the manipulation of the graft (made of hydroxyapatite, for example) and therefore could be useful as a biological carrier in mandibular bone reconstruction due to its low cost and ready availability.

There were no statistically significant differences between groups in postoperative follow up. Finally, it is important to emphasize the difficulty observed in selecting an appropriate method to objectively quantify bone formation. Further studies, with larger number of cases and controls, are necessary to assess bone neoformation with biomaterials used in this study (as well as other biomaterials) to establish conclusive results.

References

1. Marx RE. Platelet-rich plasma: evidence to support its use. *J Oral Maxillofac Surg.* 2004;62:489-96.
2. Marx RE. Platelet-rich plasma (PRP): what is PRP and what is not PRP?. *Implant Dent.* 2001;10:225-8.
3. Whitman DH, Berry RL, Green DM. Platelet gel: an autologous alternative to fibrin glue with applications in oral and maxillofacial surgery. *J Oral Maxillofac Surg.* 1997;55:1294-9.
4. Marx RE, Carlson ER, Eichstaedt RM, Schimmele SR, Strauss JE, Georgeff KR. Platelet-rich plasma: Growth factor enhancement for bone grafts. *Oral Surg Oral Med Oral Pathol Oral Radiol Endod.* 1998;85:638-46.
5. Freymiller EG, Aghaloo TL. Platelet-rich plasma: ready or not? *J Oral Maxillofac Surg.* 2004;62:484-8.
6. Esposito M, Grusovin MG, Coulthard P, Worthington HV. The efficacy of various bone augmentation procedures for dental implants: a Cochrane systematic review of randomized controlled clinical trials. *Int J Oral Maxillofac Implants.* 2006;21:696-710.
7. Boyapati L, Wang HL. The role of platelet-rich plasma in sinus augmentation: a critical review. *Implant Dent.* 2006;15:160-70.
8. Plachokova AS, Nikolidakis D, Mulder J, Jansen JA, Creugers NH. Effect of platelet-rich plasma on bone regeneration in dentistry: a systematic review. *Clin Oral Implants Res.* 2008;19:539-45.
9. Thor A, Franke-Stenport V, Johansson CB, Rasmusson L. Early bone formation in human bone grafts treated with platelet-rich plasma: preliminary histomorphometric results. *Int J Oral Maxillofac Surg.* 2007;36:1164-71.
10. Sánchez AR, Sheridan PJ, Kupp LI. Is platelet-rich plasma the perfect enhancement factor?. A current review. *Int J Oral Maxillofac Implants.* 2003;18:93-103.
11. Sammartino G, Tia M, Marenzi G, di Lauro AE, D'Agostino E, Claudio PP. Use of autologous platelet-rich plasma (PRP) in periodontal defect treatment after extraction of impacted mandibular third molars. *J Oral Maxillofac Surg.* 2005;63:766-70.
12. Kanno T, Takahashi T, Tsujisawa T, Ariyoshi W, Nishihara T. Platelet-rich plasma enhances human osteoblast-like cell proliferation and differentiation. *J Oral Maxillofac Surg.* 2005;63:362-9.
13. Gerard D, Carlson ER, Gotcher JE, Jacobs M. Effects of platelet-rich plasma on the healing of autologous bone grafted mandibular defects in dogs. *J Oral Maxillofac Surg.* 2006;64:443-51.
14. Plachokova AS, van den Dolder J, Stoeltinga PJ, Jansen JA. The bone regenerative effect of platelet-rich plasma in combination with an osteoconductive material in rat cranial defects. *Clin Oral Implants Res.* 2006;17:305-11.
15. Aaboe M, Pinholt EM, Hjørting-Hansen E. Healing of experimentally created defects: a review. *Br J Oral Maxillofac Surg.* 1995;33:312-8.
16. Acarturk TO, Hollinger JO. Commercially available demineralized bone matrix compositions to regenerate calvarial critical-sized bone defects. *Plast Reconstr Surg.* 2006;118:862-73.
17. Dodson TB. Is there a role for reconstructive techniques to prevent periodontal defects after third molar surgery? *J Oral Maxillofac Surg.* 2005;63:891-6.
18. Schwartz Z, Goldstein M, Raviv E, Hirsch A, Ranly DM, Boyan BD. Clinical evaluation of demineralized bone allograft in a hyaluronic acid carrier for sinus lift augmentation in humans: a computed tomography and histomorphometric study. *Clin Oral Implants Res.* 2007;18:204-11.
19. Bender SA, Rogalski JB, Mills MP, Arnold RM, Cochran DL, Mellonig JT. Evaluation of demineralized bone matrix paste and putty in periodontal intraosseous defects. *J Periodontol.* 2005;76:768-77.
20. Neigel JM, Ruzicka PO. Use of demineralized bone implants in orbital and craniofacial reconstruction and a review of the literature. *Ophthalm Plast Reconstr Surg.* 1996;12:108-20.