

Journal section: Oral Surgery  
Publication Types: Case Report

doi:10.4317/medoral.15.e895

## Pathological mandibular fracture after simple molar extraction in a patient with osteogenesis imperfecta treated with alendronate

Lorena Gallego <sup>1</sup>, Luis Junquera <sup>2</sup>, Alejandro Pelaz <sup>3</sup>, Serafín Costilla <sup>4</sup>

<sup>1</sup> Staff Surgeon, Department of Oral and Maxillofacial Surgery, Cabueñes Hospital, Gijón, Spain

<sup>2</sup> Associate Professor, University of Oviedo Dental School, Spain. Staff Surgeon, Department of Oral and Maxillofacial Surgery, Central University Hospital, Oviedo, Spain

<sup>3</sup> Attending, Department of Oral and Maxillofacial Surgery, Central University Hospital, Oviedo, Spain

<sup>4</sup> Associate Professor, University of Oviedo, Spain. Chief Section, Department of Radiology, Central University Hospital, Oviedo, Spain

Correspondence:  
School of Dentistry,  
University of Oviedo,  
Catedrático José Serrano s/n.  
33009 Oviedo, Spain.  
[Junquera@uniovi.es](mailto:Junquera@uniovi.es)

Gallego L, Junquera L, Pelaz A, Costilla S. Pathological mandibular fracture after simple molar extraction in a patient with osteogenesis imperfecta treated with alendronate. Med Oral Patol Oral Cir Bucal. 2010 Nov 1;15 (6):e895-7.

<http://www.medicinaoral.com/medoralfree01/v15i6/medoralv15i6p895.pdf>

Received: 03/12/2009  
Accepted: 06/03/2010

Article Number: 16949 <http://www.medicinaoral.com/>  
© Medicina Oral S. L. C.I.F. B 96689336 - pISSN 1698-4447 - eISSN: 1698-6946  
eMail: [medicina@medicinaoral.com](mailto:medicina@medicinaoral.com)

**Indexed in:**

- SCI EXPANDED
- JOURNAL CITATION REPORTS
- Index Medicus / MEDLINE / PubMed
- EMBASE, Excerpta Medica
- SCOPUS
- Índice Médico Español

### Abstract

Osteogenesis imperfecta (OI), is a heterogeneous group of inherited disorders of connective tissue characterized by bone fragility. Patients with this disease frequently suffer fractures, over 80% of the extremities due to the more intensive mechanical load. Fractures of the facial bones occur very infrequently. Several studies have proved that bisphosphonate therapy may be effective in reducing fracture risk in OI patients. We report here an unusual case of pathological mandibular fracture following simple molar extraction in an adult patient with OI type I and oral alendronic acid treatment. Extraction was atraumatic and without bone removal. Fracture was treated by internal fixation by plate osteosynthesis and additional mandibulomaxillary fixation (MMF). Bone healing after fracture treatment was completely normal and no clinical signs of osteonecrosis were observed. To the best of our knowledge, this is an unusual complication even in this type of patients. Particular care is necessary in these patients during oral surgery, even when they have been treated and controlled.

**Key words:** *Osteogenesis imperfecta, pathological fracture, oral bisphosphonates, mandibular fracture.*

### Introduction

Osteogenesis imperfecta (OI), also known as “brittle bone” disease, is a heterogeneous group of both dominantly and recessively inherited disorders of connective tissue characterized by bone fragility (1). Due in most cases to a mutation in the genes responsible for the production of procollagen, the osteoblast produces

an abnormal matrix that does not respond adequately to mechanical loads (2). Its overall incidence is approximately one in 10,000 births (1,2). Patients with OI frequently suffer fractures, either caused by relatively mild trauma or occurring spontaneously. This is encountered in up to over 80% of the extremities due to the more intensive mechanical load. Fractures of the facial bones occur very infrequently (3).

There is currently no cure for OI and treatment strategies are essentially palliative and designed to improve quality of life. Over the past decade several studies have shown that bisphosphonate therapy is effective in reducing fracture risk and decreasing bone pain in OI patients (4-6). The hypothesis initially underlying their use in an osteoblast disorder such as OI was that a decrease in bone-resorbing activity might compensate for the weakness of the bone-forming cells and reduce the osteoporosis induced by lack of use (6).

We report a case of pathological mandibular fracture following simple molar extraction in an adult patient with OI type I and oral bisphosphonate treatment. To the best of our knowledge, this is an unusual complication even in this type of patients. Bone healing after fracture treatment was completely normal and no clinical signs of osteonecrosis were observed.

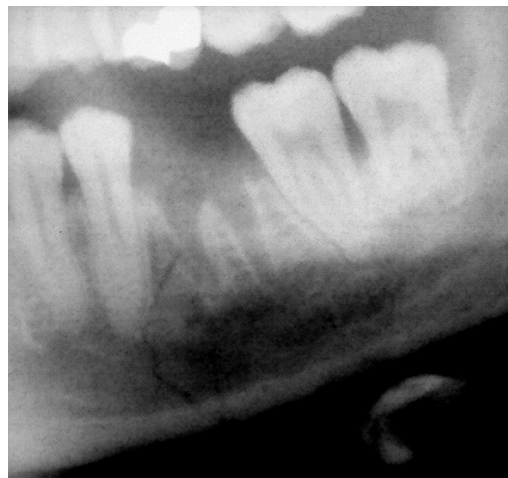### Case Report

In November 2008, a 31-year-old man was referred by his dentist to the Department of Oral and Maxillofacial Surgery at the University Central Hospital (Oviedo, Spain) because of severe pain and swelling of the left mandibular body after left first molar extraction one day earlier. Medical history revealed that the patient had been diagnosed with type I OI according to the Silience et al. (7) classification. The diagnosis was based on the history of lower and upper extremity fractures, blue sclera and low bone density.

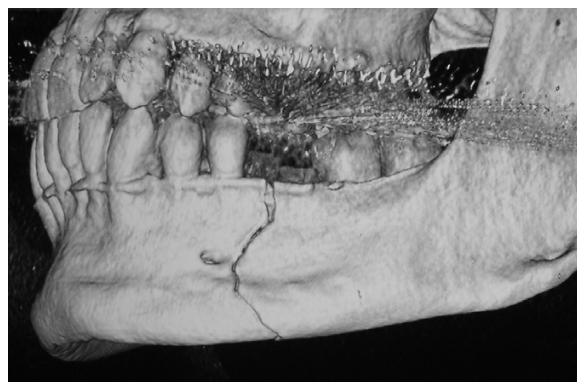The patient had undergone weekly therapy with 70 mg of oral alendronic acid from March 2000 to August 2006. In February 2008, bisphosphonate therapy was reintroduced due to a decreased bone mineral density (BMD). Lumbar spine and femoral neck BMDs before dental extraction were 0.724 and 0.959 gr/cm<sup>2</sup>, respectively. C-terminal telopeptide (CTX) value was 50 pg/mL.

As referred by the patient, extraction was atraumatic and without bone removal. A cracking noise associated with a sudden painful sensation was noted intraoperatively. Clinical examination showed extraoral swelling of the left mandibular area. A panoramic radiograph (Fig. 1) and computed tomography (CT) revealed a fracture with atypical angular course in the left body of the mandible, not dislocated (Fig. 2 and 3). A pathological fracture was diagnosed.

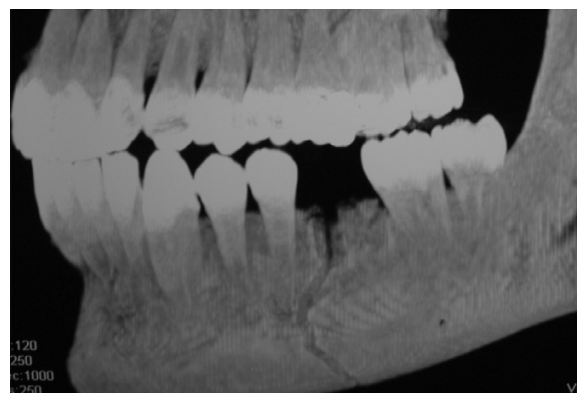
An open reduction, internal fixation by plate osteosynthesis and additional mandibulomaxillary fixation (MMF) were performed under general anaesthesia. On postoperative day 15, MMF was released. Soft diet was prescribed for one month. The patient showed uneventful bone healing following treatment. No signs of osteonecrosis or nonunion were observed after seven months of follow-up.



**Fig. 1.** A.- Panoramic radiograph showing an atypical angular course of the pathological mandibular fracture.



**Fig. 2.** 3D reconstruction of the CT confirmed the presence of a non dislocated fracture in the left body of the mandible.



**Fig. 3.** CT image revealing a pathological fracture in relation with the left first molar alveolar socket.

## Discussion

OI, a heritable disorder of bone formation, is characterized by bone fragility and low bone mass. The most common classification of this pathology was presented by Silience et al. (7) and subdivides patients into four types based on disease severity and progression. Type I OI, the most common form of the disease, is non-deforming and results in patients attaining close to a normal height. Fractures are rarely observed at birth, but begin with ambulation and subsequent falls during juvenile development, then commonly decrease following puberty. Vertebral and long bones fractures are common, but mandibular or facial fractures are rarely described (1,2,7).

Physiotherapy, rehabilitation and orthopaedic surgery are the mainstay of treatment in OI (8). Several medical therapies such as the use of calcitonin, sodium fluoride, growth hormone, cortisone and vitamins C and D have proven ineffective (2). However, cyclical intravenous treatment with pamidronate has a beneficial effect in children and adolescents with severe OI, and is now used worldwide to treat children and adolescents with moderate to severe forms of OI (4). Bisphosphonates appear to interfere with osteoclast activity through several mechanisms such as preventing osteoclast formation, inhibiting osteoclast activity, and causing early osteoclast apoptosis (9). The decreased osteoclast activity results in the therapeutic benefit of a reduction in bone pain, increased cortical bone thickness, and increased bone strength (10). In 2003, an observational trial demonstrated that oral alendronate increased lumbar spine BMD and a decreased number of fractures in 15 children with OI (10). It is currently unknown significant differences between oral and intravenous bisphosphonate therapy in OI patients (11).

In recent years, bisphosphonate-related osteonecrosis of the jaws (BRONJ) was reported in a wide number of patients receiving bisphosphonates (12,13). Otherwise, so far there has not been any report of BRONJ in patients affected by OI with high exposition to bisphosphonates, even after oral surgery (14,15). This factor may place this group of patients at a lower risk of developing bone osteonecrosis. However, until more information is collected, it is recommended that before the start and during bisphosphonate therapy the patients be referred to a dentist for examination and follow-up.

A pathological mandibular fracture following simple molar removal is a rare complication. Pathologic fractures are complex to treat because of their diverse aetiologies and the impact these will have in relation to normal bone healing. A patient with OI may simply experience increased fracture risk when exposed to sufficient trauma (1,2). In comparison with healthy patients, fractures heal more rapidly but the newly formed bone is of the same inferior quality as the original one. More-

over, some reports suggest that there is no influence of bisphosphonate treatment on fracture healing, whereas others show a delay of fracture healing in animal models (16).

In conclusion, particular care is necessary in these patients during oral surgery, even when they have been treated and controlled. Bisphosphonate treatment improves BMD, but risk of BRONJ and complications in fracture healing are present in these patients.

## References

- Glorieux FH. Osteogenesis imperfecta. *Best Pract Res Clin Rheumatol.* 2008;22:85-100.
- Huber MA. Osteogenesis imperfecta. *Oral Surg Oral Med Oral Pathol Oral Radiol Endod.* 2007;103:314-20.
- Feifel H. The surgical treatment of mandibular fractures in a child with osteogenesis imperfecta. *Int J Oral Maxillofac Surg.* 1996;25:360-2.
- Glorieux FH, Bishop NJ, Plotkin H, Chabot G, Lanoue G, Travers R. Cyclic administration of pamidronate in children with severe osteogenesis imperfecta. *N Engl J Med.* 1998;339:947-52.
- Rauch F, Glorieux FH. Bisphosphonate treatment in osteogenesis imperfecta: which drug, for whom, for how long? *Ann Med.* 2005;37:295-302.
- Devogelaer JP, Malghem J, Maldague B, Nagant de Deuxchaisnes C. Radiological manifestations of bisphosphonate treatment with APD in a child suffering from osteogenesis imperfecta. *Skeletal Radiol.* 1987;16:360-3.
- Silience DO, Senn A, Danks DM. Genetic heterogeneity in osteogenesis imperfecta. *J Med Genet.* 1979;16:101-16.
- Engelbert RH, Pruijs HE, Beemer FA, Helden PJ. Osteogenesis imperfecta in childhood: treatment strategies. *Arch Phys Med Rehabil.* 1998;79:1590-4.
- Siddiqi A, Payne AG, Zafar S. Bisphosphonate-induced osteonecrosis of the jaw: a medical enigma? *Oral Surg Oral Med Oral Pathol Oral Radiol Endod.* 2009;108:e1-8.
- Maasalu K, Haviko T, Märtson A. Treatment of children with Osteogenesis imperfecta in Estonia. *Acta Paediatr.* 2003;92:452-5.
- DiMeglio LA, Peacock M. Two-year clinical trial of oral alendronate versus intravenous pamidronate in children with osteogenesis imperfecta. *J Bone Miner Res.* 2006;21:132-40.
- Marx RE. Pamidronate (Aredia) and zoledronate (Zometa) induced avascular necrosis of the jaws: a growing epidemic. *J Oral Maxillofac Surg.* 2003;61:1115-7.
- Lazarovici TS, Yahalom R, Taicher S, Elad S, Hardan I, Yarom N. Bisphosphonate-related osteonecrosis of the jaws: a single-center study of 101 patients. *J Oral Maxillofac Surg.* 2009;67:850-5.
- Malmgren B, Aström E, Söderhäll S. No osteonecrosis in jaws of young patients with osteogenesis imperfecta treated with bisphosphonates. *J Oral Pathol Med.* 2008;37:196-200.
- Schwartz S, Joseph C, Iera D, Vu DD. Bisphosphonates, osteonecrosis, osteogenesis imperfecta and dental extractions: a case series. *J Can Dent Assoc.* 2008;74:537-42.
- Pizones J, Plotkin H, Parra-Garcia JI, Alvarez P, Gutierrez P, Bueno A, et al. Bone healing in children with osteogenesis imperfecta treated with bisphosphonates. *J Pediatr Orthop.* 2005;25:332-5.