

Journal section: Oral Medicine and Pathology  
Publication Types: Research

doi:10.4317/medoral.15.e839

## Proliferative verrucous leukoplakia: A proposal for diagnostic criteria

Rocio Cerero-Lapiedra <sup>1</sup>, David Baladé-Martínez <sup>1</sup>, Luis-Alberto Moreno-López <sup>1</sup>, Germán Esparza-Gómez <sup>1</sup>, José V. Bagán <sup>2</sup>

<sup>1</sup> Department of Medicine and Buccofacial Surgery, Faculty of Dentistry, Complutense University of Madrid, Spain

<sup>2</sup> Stomatology Service at the Hospital General Universitario of Valencia, University of Valencia, Spain

### Correspondence:

Department of Medicine and Buccofacial Surgery  
Faculty of Dentistry,  
Complutense University of Madrid,  
Spain,  
[rcerero@odon.ucm.es](mailto:rcerero@odon.ucm.es)

Cerero-Lapiedra R, Baladé-Martínez D, Moreno-López LA, Esparza-Gómez G, Bagán JV. Proliferative verrucous leukoplakia: a proposal for diagnostic criteria. Med Oral Patol Oral Cir Bucal. 2010 Nov 1;15 (6):e839-45.

<http://www.medicinaoral.com/medoralfree01/v15i6/medoralv15i6p839.pdf>

Received: 05/07/2009  
Accepted: 21/02/2010

Article Number: 3501 <http://www.medicinaoral.com/>  
© Medicina Oral S. L. C.I.F. B 96689336 - pISSN 1698-4447 - eISSN: 1698-6946  
eMail: [medicina@medicinaoral.com](mailto:medicina@medicinaoral.com)

### Indexed in:

- SCI EXPANDED
- JOURNAL CITATION REPORTS
- Index Medicus / MEDLINE / PubMed
- EMBASE, Excerpta Medica
- SCOPUS
- Índice Médico Español

### Abstract

Proliferative verrucous leukoplakia (PVL) is a rare form of oral leukoplakia, which was first described in 1985 by Hansen et al. Since then, various published case series have presented PVL as a disease with aggressive biological behaviour due to its high probability of recurrence and a high rate of malignant transformation, usually higher than 70%. PVL is a long-term progressive condition, which is observed more frequently in women and elderly patients over 60 years at the time of diagnosis. Eventually, PVL tends to become multifocal with a progressive deterioration of the lesions, making it more and more difficult to control. Tobacco use does not seem to have a significant influence on the appearance or progression of PVL. These lesions may occur both in smokers and non-smokers. Nevertheless, at present, the aetiology of PVL remains unclear as well as its management and diagnosis, which is still retrospective, late and poorly defined, lacking consensus criteria.

Therefore, the aim of this study is to propose a set of diagnostic criteria to allow for the early and objective identification of PVL cases, and thereby conduct an adequate management. The proposal includes five major criteria and four minor criteria, as well as specific combinations among them in order to establish a correct and objective diagnosis of proliferative verrucous leukoplakia.

**Key words:** Proliferative verrucous leukoplakia, oral, cancer.

## Introduction

White lesions are relatively frequent in the oral cavity with a prevalence of approximately 24.8%, according to Axéll (1). Among them is oral leukoplakia with a prevalence rate of 0.2 to 3.6% (1-5). Petti reported an estimated world leukoplakia prevalence of 2% (6), while for van der Waal a rate of 0.5% or lower is more realistic given geographical variations (7).

Leukoplakia was described by the World Health Organization as a "Precancerous Lesion" (8). However, more recently it has been suggested that the terms "pre-malignant" and "precancerous" should be substituted for "potentially malignant", and that all precancerous lesions and conditions should be grouped under the common name of "potentially malignant disorders" (9). Following the latest Workshop on oral precancer organized in 2005 by the World Health Organization Collaborating Centre for Oral Cancer, oral leukoplakia should be defined as "a white plaque of questionable risk having excluded (other) known diseases or disorders that carry no increased risk for cancer" (7,9). Despite these modifications in its nomenclature and classification, oral leukoplakia remains the most frequent potentially malignant disorder in the oral cavity. Its malignant transformation rate varies from 0.13 to 17.5%, according to the published data (10-12), with a reported annual malignant transformation rate of approximately 1% for all types of oral leukoplakia (7,13).

Barely a few decades ago, a rare form of oral leukoplakia known as proliferative verrucous leukoplakia (PVL) was first reported. It presents specific characteristics, mainly a more aggressive biological behaviour than other forms of leukoplakia expressed by: a tendency towards multifocality; a high probability of recurrence; and a high rate of malignant transformation, which can range between 40 and 100% in a follow-up period of 4.4 to 11.6 years (14-20).

PVL was first described in 1985 by Hansen et al. as a long-term progressive condition (sometimes more than 20 years) which develops initially as a white plaque of hyperkeratosis that eventually becomes a multifocal disease with confluent, exophytic and proliferative features. The lesions are slow-growing yet persistent, as well as irreversible and resistant to all forms of treatment with a high recurrence rate. Throughout its development, it is common to find erythematous and/or verrucous areas that occasionally progress to verrucous carcinoma or squamous cell carcinoma (SCC), and frequently to several of them (14).

As reported in previous case series regarding PVL, women (21) are affected more often than men. There is probably no racial preference (22). The mean age at the time of diagnosis is over 60 years. Tobacco use does not seem to have a significant influence on the disease given that PVL occurs both in smokers and non-smokers (23).

At present, the aetiology of PVL is unknown without widely accepted diagnostic and treatment criteria (23,24). This hinders the correct treatment of PVL patients as well as the advance in the knowledge about the disease, given that researchers do not use equivalent criteria and the studies are, thus, hardly comparable (23,24). Generally, diagnosis is made according to Hansen's first definition of PVL in 1985, not taking into account the latter ones. This creates doubt about whether all published PVL cases are indeed PVL, as has been stated by several authors (22-24).

As a result of this, we find it necessary to elaborate specific diagnostic criteria for PVL.

## Material and Method

A reference search was carried out for PVL studies published between 1985 and 2009. Keywords, both in Spanish and English, included: proliferative verrucous leukoplakia, multifocal leukoplakia, multiple leukoplakia and verrucous leukoplakia.

Only those studies which complied with at least one of the following criteria were selected:

- PVL case series, with a minimum of 7 cases for each series, involving at least seven of the following items: number of patients, age, gender distribution, tobacco consumption, follow-up period, lesion sites, treatments, recurrence rate, and malignant transformation rate.
- Literature reviews examining proliferative verrucous leukoplakia, as well as studies regarding its histopathology, malignant transformation and diagnosis.

Analysing the published cases of PVL, the most frequently observed clinical and histopathological data were identified, as well as those which were highly relevant. These study data were then divided into major and minor diagnostic criteria, and later combined in different ways in order to find those that would facilitate a more objective and correct diagnosis of PVL.

## Results

A total of 8 case series studies that complied with the aforementioned criteria were selected; as well as 5 literature reviews and 1 study on oral squamous cell carcinoma cases that developed from PVL lesions: Bagán et al. (25).

The results of the various case series are shown in table 1. Among the found series, the authors of the study by Ghazali et al. (22) were not able to confirm that their cases could be diagnosed as PVL. Therefore, this series was not included in the table. Thus, solely the results of 7 case series are shown in it.

After analysing the published cases, 5 major and 4 minor criteria were proposed, as well as various combinations among them, to allow for a definitive diagnosis of PVL.

**Table 1.** PVL case series that complied with our selection criteria and on which we based our diagnostic criteria proposal.

STUDY	N	Mean age	Gender F/M	Smokers n (%)	Follow-up Years	Site	Treatment	Recurrence n	Malignant transformation (% years)
Hansen et al. 1985 Ref 14	30	59,6	24 / 6	18 (62)	6,1	23 BM, 18 SP, 16 AR, 15 T, 8 FM, 4 L	18 RT/17 C, 6 CH/4 La, 2 Ret/2 Other, 5 Ex b	-	87/6,1
Zabrzewska et al. 1996 Ref 15	10	63,5	5 / 5	7 (70)	6,6	8 G, 8 BM, 6 T, 2 L, 2 HP, 2 FAUCES, 1 SP	7 La, 6 C, 5 PT, 1 RT, 1 CH	8,2	100/ 6,6
Silverman et al. 1997 Ref. 16	54	62	43 / 11	17 (31)	11,6	31 BM, 29 G, 29 T, 22 FM, 19 HP, 9 L	42 C, 11 C+RT	-	70,3/ 11,6
Haya et al. 1998 Ref 17	7	74,7	5 / 2	3 (43)	2,3	6 AR, 3 HP, 2 BM, 2 T, 1 G, 1 FM	7 La, 5 C	1,8	57,14/ 2,3
Fetting et al. 2000 Ref 18	10	65	4 / 6	3 (30)	4,4	10 G, 1 FM	15 La, 13 Ex, 3Rs, 2 Max, 1 Max p/1 Stp	2,4	60/ 4,4
Bagan et al. 2003 Ref 19	30	70,97	24 / 6	7 (23)	4,7	49 G, 34 BM, 25 T, 15 HP, 15 L, 4 SP	24 C, 18 La	26	90/ 4,7
Gandolfo et al. 2009 Ref 20	47	65,9	37 / 10	17 (37)	6,89	41 AR, 33 BM, 22 G, 8 FM, 6 L	-	-	40,4/ 6,89
<b>TOTALS</b>	<b>188</b>	<b>&gt; 66</b>	<b>142 / 46</b>	<b>&gt; 42 %</b>	<b>6,08</b>	<b>FIGURE 1</b>	<b>-</b>	<b>-</b>	<b>74,62/ 6,08</b>

Site: BM (buccal mucosa), G (gingiva), T (tongue) HP (hard palate) L (lip) SP (soft palate), AR (alveolar ridge), FM (floor of mouth).

Treatment: RT (radiotherapy), CH (chemotherapy), C (conventional surgery) La (laser), Ret (retinoids), Ex b (excisional biopsy), PT (photodynamic therapy), Rs (resection), Ex (excision), Max (maxillectomy), Max p (partial maxillectomy), Stp (stripping).

*Major Criteria (MC):*

- A. A leukoplakia lesion with more than two different oral sites, which is most frequently found in the gingiva, alveolar processes and palate.
- B. The existence of a verrucous area.
- C. That the lesions have spread or engrossed during development of the disease.
- D. That there has been a recurrence in a previously treated area.
- E. Histopathologically, there can be from simple epithelial hyperkeratosis to verrucous hyperplasia, verrucous carcinoma or oral squamous cell carcinoma, whether in situ or infiltrating.

*Minor Criteria (mc):*

- a. An oral leukoplakia lesion that occupies at least 3 cm when adding all the affected areas.
  - b. That the patient be female.
  - c. That the patient (male or female) be a non-smoker.
  - d. A disease evolution higher than 5 years.
- In order to make the diagnosis of PVL, it was suggested that one of the two following combinations of the criteria mentioned before were met.
- 1. Three major criteria ( being E among them) or
  - 2. Two major criteria (being E among them) + two minor criteria.

## Discussion

According to the latest WHO nomenclature, proliferative verrucous leukoplakia conforms to the new terminology of “potentially malignant disorders” given that it is neither a delimited lesion nor a condition (13). PVL is known for its aggressive pathology, given its multifocal involvement, tendency to recur after removal, and high rate of malignant transformation, which can be higher than 70%, reaching 100% in some cases (14-16). 74.62% of the published cases report a mean malignant transformation rate of 6.08 years (14-20). Therefore, the early diagnosis of PVL can be beneficial in the prognosis of these patients. Nevertheless, at present, there is no criterion that will allow for the early diagnosis of the disease.

In previously published series, diagnosis of PVL was made according to Hansen's et al. definition (14). Among the cases reported by different authors, certain characteristics tend to recur: a distinct female predilection; a mean age at the time of diagnosis of over 60 years; the growth and macroscopic changes of lesions; the masticatory mucosa, gingiva, palate and alveolar ridge as the most common sites; a high probability of recurrence and a high rate of malignant transformation. Therefore, there are several characteristics of the disease which recur or prove to be increasingly more relevant. However, no author has systematized these features in the form of diagnostic criteria yet. There are only two studies, one by Ghazali et al. (22) and another by Gandolfo et al. (20), which apply a set of diagnostic criteria to their respective cases, although these are just a transcription of Hansen's definition. Thus, Ghazali et al. (22) establish the following criteria:

1. The lesion starts as homogenous leukoplakia without evidence of dysplasia at the first visit.
2. With time, some areas of leukoplakia become verrucous.
3. The disease progresses to the development of multiple isolated or confluent lesions at the same or different site.
4. With time, the disease progresses through the different histopathological stages reported by Hansen et al. (14) (1985).
5. The appearance of new lesions after treatment.
6. A follow-up period of no less than one year.

Ghazali et al. consider that all their proposed criteria should be met without exclusion. From their series, only three cases were considered doubtful. Yet, all cases failed given that the first criterion was not met, since the authors had no previous data regarding the appearance of early lesions (22).

On the other hand Gandolfo et al. establish the following criteria (20):

- 1.- An initially innocuous lesion characterized by a homogenous plaque that progresses over time to an exo-

phytic, diffuse, usually multifocal, lesion with a verrucous epithelial growth pattern.

2.- Histopathologically, PVL changes gradually from a simple plaque of hyperkeratosis without dysplasia to verrucous hyperplasia, verrucous carcinoma or OSSC. These attempts at establishing a set of criteria are a step in the right direction. However, we believe they are insufficient as they don't take into account the rest of the published studies. Although Hansen et al. (14) established a comprehensive definition of the disease that has served as a starting point, it has not been updated in the last two decades. On this basis, the present study proposes a set of criteria based not only in Hansen's definition but in the various findings reported in the latter published cases of PVL. We have, therefore, identified and systematized these findings, or PVL characteristics, into major and minor criteria.

On the other hand, in cases of advanced and well-localized PVL, the diagnosis might not be problematic. But there are many other situations in which the diagnosis is doubtful. With this proposed criteria we aim at helping the clinician to establish the earliest possible doubtful diagnosis of PVL, as well as to allow for an adequate follow-up. We shall comment on the proposed criteria below.

### *Major Criteria.*

*Major Criterion A:* “A leukoplakia lesion with more than two different oral sites, which is most frequently found in the gingiva, alveolar processes and palate” is itself a comprehensive criterion as it refers to the multifocality of the lesions on one hand, as well as shows the most common site for PVL lesions to date. If we gather all the lesions from the different case series, we can observe that the buccal mucosa is still the most frequently involved site (Fig. 1). Nevertheless, the latest published case series have reported an increased tendency towards PVL lesions settling in keratinized mucosa: gingiva, alveolar ridge and hard palate (18-20) (Fig. 2, 3 and 4).

It has been reported that OSCC cases associated to PVL develop commonly in these sites (Fig. 5), which are infrequent sites for lesions if compared to those of conventional OSCC cases in Western populations: tongue, floor of mouth and buccal mucosa (16,18-20,25-28). The presence of this criterion makes the diagnosis of PVL highly doubtful. It is also the criterion that most clinically differentiates this leukoplakia from conventional leukoplakia.

*Major Criteria B, C, and D:* Also constitute essential characteristics of PVL that are cited in most publications from Hansen et al. (14) to Gandolfo et al. (20). In them, we can see how PVL always progresses towards multifocality; the lesion growth; the development of verrucous areas, (Fig. 6); and a recurrence rate higher than 85%. Given the frequency with which these characteristics occur, we strongly believe they should be considered as major criteria (14-20).

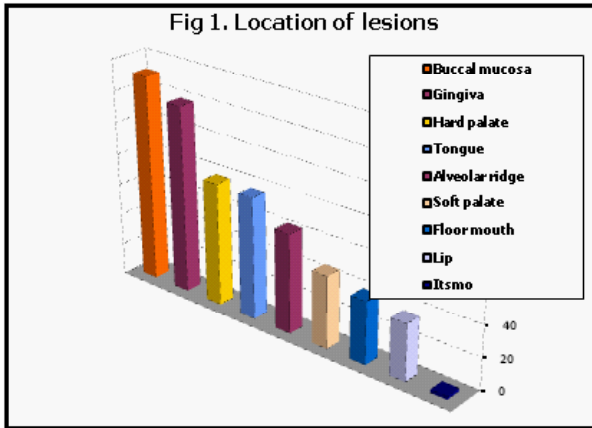


Fig. 1. Location of lesions.

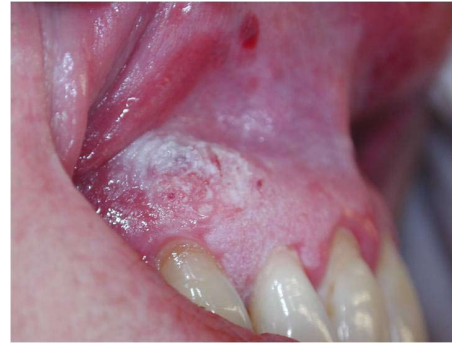

Fig. 5. Wide lesion with a confirmed diagnosis of squamous cell carcinoma.

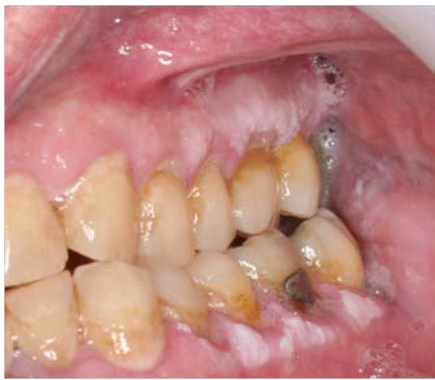

Fig. 2. PVL lesions on keratinized mucosa.

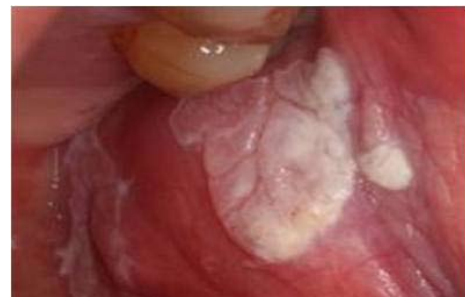

Fig. 6. Verrucous aspect of a large lesion which is not alone.

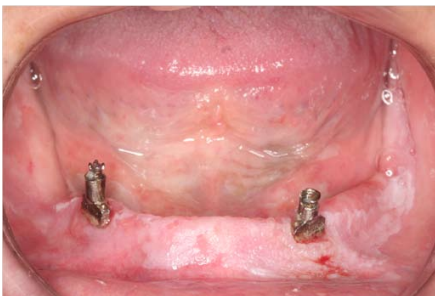

Fig. 3. Multiple lesions at different stages of evolution.

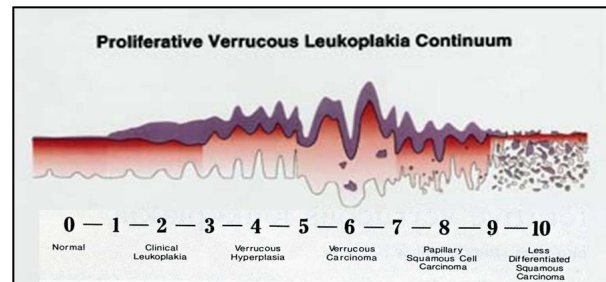


Fig. 7. Diagram showing the natural evolution and the various stages of the disease (Modified by Greer et al., J Calif Dent Assoc 1999).

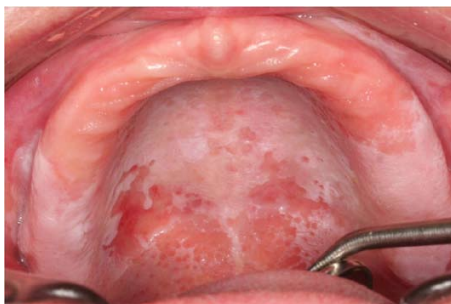

Fig. 4. Multiple white lesions next to erythematized lesions on the masticatory mucosa.

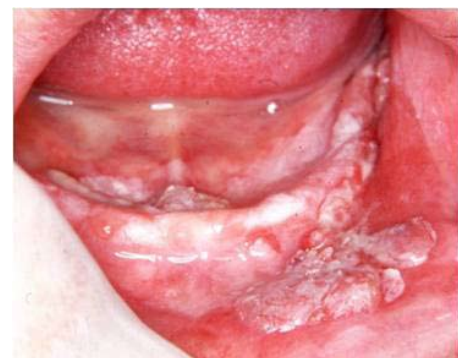

Fig. 8. Note the coexistence of lesions at various stages of evolution in the same PVL case.

**Major Criterion E:** Histologically, there can be from simple epithelial hyperkeratosis to verrucous hyperplasia, verrucous carcinoma or oral squamous cell carcinoma, whether in situ or infiltrating. This criterion is essential in order to confirm PVL diagnosis. It has the peculiarity of being quite broad given that, from a histological point of view, shows the diverse natural evolution of the disease while also being restrictive: it prevents other white or red lesions with a tendency to spread inside the oral cavity, such as oral lichen planus, from being diagnosed as PVL. In 1985 (14), Hansen explained a histological diagram (Fig. 7) with 10 degrees of severity for evaluating the disease (14). Subsequently, Batsakis reduced Hansen's proposal to four stages, eliminating the papillary squamous cell carcinoma, which he considered to be independent of PVL, even of the oral cavity where it is rarely found, being the oropharynx a more frequent site (29).

Therefore, histopathologically, PVL starts as simple hyperkeratosis, which can progress to verrucous hyperplasia, verrucous carcinoma, and even oral squamous cell carcinoma, whether in situ or infiltrating (14,29). It should be noted that in cases of multifocality, not all lesions are at the same stage of evolution. While one lesion may be simple hyperkeratosis, another one located elsewhere may already have developed into a carcinoma (21,30) (Fig. 8). Thus, various authors suggest a more thorough follow-up for these patients, looking out for changes in shape, size, colour, as well as the appearance of new lesions, carrying out as many biopsies as may be needed. (22,23,25,30,31).

#### *Minor criteria.*

**Minor criterion a:** An oral leukoplakia lesion that occupies at least 3 cm when adding all the affected areas. In PVL, we consider that the presence of multiple lesions in different sites or the macroscopic alterations is more relevant than the size of the lesion itself. Therefore, we regard this characteristic as a minor criterion. Nonetheless, according to van der Waal and Schepman's proposal for a modified staging system for oral leukoplakia (OLEP), a size larger than 3 cm would be considered an eligibility criterion, corresponding to stage II in the aforementioned system (32-34).

**Minor criterion b:** That the patient be female. Most PVL studies report a greater female predilection. In fact, if we group all the patients of the different case series, we find that women comprise 75.53% (14-20) (Table 1), with a ratio of 4:1 (21). As a result, we believe that this epidemiological datum should also be regarded as a relevant but minor criterion, given that the disease may also be present in men.

**Minor criterion c:** That the patient (male or female) be a non-smoker. Like in the aforementioned criterion, this is a recurrent finding in the different series of published cases. As seen from table 1, only the studies by

Hansen et al. (14) and Zakrzewska et al. (15) reported more smokers than non-smokers, while in the rest of the published studies the majority of patients did not smoke (14-20). However, the disease is also present in smokers. If we group all the patients of the different studies, we find that, in fact, there is no significant difference between smokers and non-smokers, given that approximately 42% smoked (14-20) (Table 1). Therefore, since the etiopathogenic role of tobacco in PVL remains unclear (16,19,23) and there is no significant difference in the occurrence of PVL between smokers and non-smokers, we believe this datum should be regarded as a minor criterion.

**Minor criterion d:** A disease evolution higher than 5 years. It is considered minor criteria given that in many cases the exact development time cannot be determined. Nevertheless, we have established it at a 'time period higher than 5 years', as the average period of the various staging systems of PVL case series is around 6 years (14-20) (Table 1).

## Conclusions

Proliferative verrucous leukoplakia is a rare but highly aggressive form of oral leukoplakia, which requires special awareness on the part of the clinician. Therefore, it is recommended to have the earliest possible diagnosis, as well as consensus on diagnostic criteria to achieve uniformity. To this effect, the present study proposes a set of criteria, which we believe should be applied to case series in order to verify its efficacy.

## References

1. Axéll T. Occurrence of leukoplakia and some other oral white lesions among 20,333 adult Swedish people. *Community Dent Oral Epidemiol.* 1987;15:46-51.
2. Bouquot JE, Gorlin RJ. Leukoplakia, lichen planus, and other oral keratoses in 23,616 white Americans over the age of 35 years. *Oral Surg Oral Med Oral Pathol.* 1986;61:373-81.
3. Ikeda N, Ishii T, Iida S, Kawai T. Epidemiological study of oral leukoplakia based on mass screening for oral mucosal diseases in a selected Japanese population. *Community Dent Oral Epidemiol.* 1991;19:160-3.
4. Bánóczy J, Rigó O. Prevalence study of oral precancerous lesions within a complex screening system in Hungary. *Community Dent Oral Epidemiol.* 1991;19:265-7.
5. Schepman KP, Van der Meij EH, Smeele LE, Van der Waal I. Prevalence study of oral white lesions with special reference to a new definition of oral leukoplakia. *Eur J Cancer B Oral Oncol.* 1996;32B:416-9.
6. Petti S. Pooled estimate of world leukoplakia prevalence: a systematic review. *Oral Oncol.* 2003;39:770-80.
7. Van der Waal I. Potentially malignant disorders of the oral and oropharyngeal mucosa; terminology, classification and present concepts of management. *Oral Oncol.* 2009;45:317-23.
8. Kramer IR, Lucas RB, Pindborg JJ, Sobin LH. Definition of leukoplakia and related lesions: an aid to studies on oral precancer. *Oral Surg Oral Med Oral Pathol.* 1978;46:518-39.
9. Warnakulasuriya S, Johnson NW, Van der Waal I. Nomenclature and classification of potentially malignant disorders of the oral mucosa. *J Oral Pathol Med.* 2007;36:575-80.

10. Silverman S Jr, Gorsky M, Lozada F. Oral leukoplakia and malignant transformation. A follow-up study of 257 patients. *Cancer*. 1984 ;53:563-8.
11. Lind PO. Malignant transformation in oral leukoplakia. *Scand J Dent Res*. 1987;95:449-55.
12. Scheifele C, Reichart PA, Dietrich T. Low prevalence of oral leukoplakia in a representative sample of the US population. *Oral Oncol*. 2003;39:619-25.
13. Scheifele C, Reichart PA. Is there a natural limit of the transformation rate of oral leukoplakia? *Oral Oncol*. 2003;39:470-5.
14. Hansen LS, Olson JA, Silverman S Jr. Proliferative verrucous leukoplakia. A long-term study of thirty patients. *Oral Surg Oral Med Oral Pathol*. 1985;60:285-98.
15. Zakrzewska JM, Lopes V, Speight P, Hopper C. Proliferative verrucous leukoplakia: a report of ten cases. *Oral Surg Oral Med Oral Pathol Oral Radiol Endod*. 1996;82:396-401.
16. Silverman S Jr, Gorsky M. Proliferative verrucous leukoplakia: a follow-up study of 54 cases. *Oral Surg Oral Med Oral Pathol Oral Radiol Endod*. 1997;84:154-7.
17. Haya Fernández MC, Bagán Sebastián JV, LLoria de Miguel E, Jiménez Soriano Y, Pérez Vallés A. Leucoplasia verrucosa proliferativa. Presentación de siete casos clínicos. *Rev Eur Odon Estomatol* 1998;10:363-70.
18. Fettig A, Pogrel MA, Silverman S Jr, Bramanti TE, Da Costa M, Regezi JA. Proliferative verrucous leukoplakia of the gingiva. *Oral Surg Oral Med Oral Pathol Oral Radiol Endod*. 2000;90:723-30.
19. Bagan JV, Jimenez Y, Sanchis JM, Poveda R, Milian MA, Murillo J, et al. Proliferative verrucous leukoplakia: high incidence of gingival squamous cell carcinoma. *J Oral Pathol Med*. 2003;32:379-82.
20. Gandolfo S, Castellani R, Pentenero M. Proliferative verrucous leukoplakia: a potentially malignant disorder involving periodontal sites. *J Periodontol*. 2009;80:274-81.
21. Cabay RJ, Morton TH Jr, Epstein JB. Proliferative verrucous leukoplakia and its progression to oral carcinoma: a review of the literature. *J Oral Pathol Med*. 2007;36:255-61.
22. Ghazali N, Bakri MM, Zain RB. Aggressive, multifocal oral verrucous leukoplakia: proliferative verrucous leukoplakia or not? *J Oral Pathol Med*. 2003;32:383-92.
23. Van der Waal I, Reichart PA. Oral proliferative verrucous leukoplakia revisited. *Oral Oncol*. 2008;44:719-21.
24. Bishen KA, Sethi A. Proliferative Verrucous Leukoplakia--diagnostic pitfalls and suggestions. *Med Oral Patol Oral Cir Bucal*. 2009;14:E263-4.
25. Bagán JV, Murillo J, Poveda R, Gavaldá C, Jiménez Y, Scully C. Proliferative verrucous leukoplakia: unusual locations of oral squamous cell carcinomas, and field cancerization as shown by the appearance of multiple OSCCs. *Oral Oncol*. 2004;40:440-3.
26. Sasaki T, Moles DR, Imai Y, Speight PM. Clinico-pathological features of squamous cell carcinoma of the oral cavity in patients <40 years of age. *J Oral Pathol Med*. 2005;34:129-33.
27. Garzino-Demo P, Dell'Acqua A, Dalmaso P, Fasolis M, La Terra Maggiore GM, Ramieri G, et al. Clinicopathological parameters and outcome of 245 patients operated for oral squamous cell carcinoma. *J Craniomaxillofac Surg*. 2006;34:344-50.
28. Liu L, Kumar SK, Sedghizadeh PP, Jayakar AN, Shuler CF. Oral squamous cell carcinoma incidence by subsite among diverse racial and ethnic populations in California. *Oral Surg Oral Med Oral Pathol Oral Radiol Endod*. 2008;105:470-80.
29. Batsakis JG, Suarez P, el-Naggar AK. Proliferative verrucous leukoplakia and its related lesions. *Oral Oncol*. 1999;35:354-9.
30. Greer RO, McDowell JD, Hoernig G. Proliferative verrucous leukoplakia: report of two cases and a discussion of clinicopathology. *J Calif Dent Assoc*. 1999;27:300-5, 308-9.
31. Thomson PJ, Hamadah O. Cancerisation within the oral cavity: the use of 'field mapping biopsies' in clinical management. *Oral Oncol*. 2007;43:20-6.
32. Van der Waal I, Axéll T. Oral leukoplakia: a proposal for uniform reporting. *Oral Oncol*. 2002;38:521-6.
33. Schepman KP, Van der Waal I. A proposal for a classification and staging system for oral leukoplakia: a preliminary study. *Eur J Cancer B Oral Oncol*. 1995;31B:396-8.
34. Van der Waal I, Schepman KP, Van der Meij EH. A modified classification and staging system for oral leukoplakia. *Oral Oncol*. 2000;36:264-6.