

Journal section: *Biomaterials and Bioengineering in Dentistry*
 Publication Types: *Research*

doi:10.4317/medoral.16.e124
<http://dx.doi.org/doi:10.4317/medoral.16.e124>

Identification of the nuclear factor kappa-beta (NF-kB) in cortical of mice Wistar using Technovit 7200 VCR®

Marcos B. Salles^{1,3}, Bruno König Jr¹, Sergio Allegrini Jr², Marcelo Yoshimoto^{3,4}, Marília T. Martins⁵, Paulo G. Coelho⁶

¹ Department of Anatomy, Institute of Biomedical Sciences (ICB), Universidade de São Paulo- Brazil

² Department of Maxillofacial Orthopedics, Ernst-Moritz-Arndt-University, Greifswald, Germany

³ Department of Oral Surgery Oral Implantology at Unicastedo Universidade, São Paulo - Brazil

⁴ Institute of Nuclear Energy Research (IPEN), Science and Technology Materials Center (CCTM), São Paulo- Brazil

⁵ Department of Oral Pathology, School of Dentistry, Universidade de São Paulo- Brazil

⁶ Department of Biomaterials and Biomimetics, School of Dentistry, New York University- USA

Correspondence:

345 24th street room 804s
 New York, NY 10010
pgcoelho@nyu.edu

Salles MB, König Jr B, Allegrini Jr S, Yoshimoto M, Martins MT, Coelho PG. Identification of the nuclear factor kappa-beta (NF-kB) in cortical of mice Wistar using Technovit 7200 VCR(R). *Med Oral Patol Oral Cir Bucal*. 2011 Jan 1;16 (1):e124-31.

<http://www.medicinaoral.com/medoralfree01/v16i1/medoralv16i1p124.pdf>

Received: 17/11/2009
 Accepted: 21/02/2010

Article Number: 3307 <http://www.medicinaoral.com/>
 © Medicina Oral S. L. C.I.F. B 96689336 - pISSN 1698-4447 - eISSN: 1698-6946
 eMail: medicina@medicinaoral.com

Indexed in:

Science Citation Index Expanded
 Journal Citation Reports
 Index Medicus, MEDLINE, PubMed
 Scopus, Embase and Emcare
 Índice Médico Español

Abstract

Objective: this study aimed to develop a nondecalcified bone sample processing technique enabling immunohistochemical labeling of proteins by kappa-beta nuclear factor (NF-kB) utilizing the Technovit 7200 VCR® in adult male Wistar rats.

Study Method: A 1.8 mm diameter defect was performed 0.5mm from the femur proximal joint by means of a round bur. Experimental groups were divided according to fixing solution prior to histologic processing: Group 1- ethanol 70%; Group 2-10% buffered formalin; and Group 3- Glycerol diluted in 70% ethanol at a 70/30 ratio + 10% buffered formalin. The post-surgical periods ranged from 01 to 24 hours. Control groups included a non-surgical procedure group (NSPG) and surgical procedures where bone exposure was performed (SPBE) without drilling. Prostate carcinoma was the positive control (PC) and samples subjected to incomplete immunohistochemistry protocol were the negative control (NC). Following euthanization, all samples were kept at 4°C for 7 days, and were dehydrated in a series of alcohols at -20°C. The polymer embedding procedure was performed at ethanol/polymer ratios of 70%-30%, 50%-50%, 30%-70%, 100%, and 100% for 72 hours at -20°C. Polymerization followed the manufacturer's recommendation. The samples were grounded and polished to 10-15µm thickness, and were deacrylated. The sections were rehydrated and were submitted to the primary polyclonal antibody anti-NF-kB on a 1:75 dilution for 12 hours at room temperature.

Results: Microscopy showed that the Group 2 presented positive reaction to NF-kB, diffuse reactions for NSPG and SPBE, and no reaction for the NC group.

Conclusion: The results obtained support the feasibility of the developed immunohistochemistry technique.

Key words: *Immunohistochemistry, nondecalcified sections, Technovit 7200, NF-kB, Wistar Rats.*

Introduction

Due to the hard nature of bone tissue, its appropriate sectioning and preparation for varied types of microscopy and immunohistochemistry is significantly more laborious compared to other tissues. While several techniques have been constantly utilized for soft tissue evaluation, bone tissue has been analyzed throughout the years by only three established techniques, which include bone decalcification for histologic evaluation, scanning electron microscopy (SEM), typically utilized for analyses of the interface between bone and biomaterials, and plastic embedding following tissue preparation to allow specimen sectioning in the non-decalcified state that is often times used for tissue morphology and bone-biomaterial interactions.

These three techniques have inherent limitations that further complicate appropriate data collection, thereby increasing the level of speculation with respect to the information collected during the study. For example, bone decalcification through a series of chelating and/or acid solutions for the purpose of removing Ca^{++} or apatite content may result in poor mineralization front detection (1). Another disadvantage of currently established techniques is the impossibility of decalcifying and sectioning bone samples containing implantable materials due to significant differences in materials hardness.

In an attempt to overcome the limitations encountered in decalcified samples, plastic embedding bone and biomaterial containing bone samples have been developed (2,3). This technique comprises steps such as embedding bone or biomaterial containing bone sample in acrylic polymer, thin-sectioning the sample, and subsequently grinding and polishing the sample, enabling observation of new bone regions around biomaterials and the short- and long-term interaction between bone and biomaterials through appropriate staining and labeling procedures (1). Thus, following the development of nondecalcified bone and biomaterial containing bone samples sectioning techniques, significant advances in understanding bone tissue and its interaction with biomaterials were accomplished. However, despite significant improvements in bone morphology and dynamics in samples containing or not containing biomaterials, plastic embedding techniques did not enable protein labeling through immunohistochemistry. This impossibility was due to the fact that the polymer did not allow the diffusion of antibodies to the inner layers of the hard tissue. Therefore, while immunologic reactions could be traced in decalcified samples, biomaterial containing bone samples immunohistochemical analyses have been attempted through several nondecalcified sample preparation techniques (4-6).

Chappard et al. (6), showed positive immune reactions in nondecalcified samples through a low temperature (4°C) technique. However, attempts to reproduce this

technique were not successful (7). It has been speculated that one of the major difficulties in maintaining bone tissue protein integrity is due to the coefficient of thermal expansion of methacrylate-based polymer, which may cause protein denaturation, and thus interfering with the sample antigenic identification (4).

Recently, Yang et al. (1), utilized a MMA-based polymer (Technovit 9100®) and were able to label bone proteins such as alkaline phosphatase (ALP), osteocalcin (OC), osteonectin (ON), and bone sialoprotein (BSP). The authors concluded that the success in labeling these proteins was due to the new embedding compound utilized (Technovit 9100®).

The purpose of this study was to develop a nondecalcified bone sample processing technique enabling immunohistochemical labeling of proteins by kappa-beta nuclear factor (NF- κ B) utilizing the 2-Hydroxyethylmetacrylate Technovit 7200 VCR®. The rationale for utilizing such compound was due to its large-scale utilization for embedding and sectioning biomaterial containing bone samples. The selection of NF- κ B was related to the role of this endonuclease in the immunologic and inflammatory bone responses, since reports have shown that NF- κ B is related to various physiologic and physiopathologic bone responses to stress stimuli through pro-inflammatory cytokines that may lead to cell differentiation, multiplication, apoptosis, or death (8-16).

Materials and Methods

Animal Model and Surgical Procedure

The animals utilized in this investigation were male Wistar rats weighing approximately 350g. This research was conducted following approval of the bioethics committee for animal experimentation of the University of Sao Paulo.

Experimental Groups

For all experimental groups (n=130) the surgical site was the proximal femurs of the animals. The initial procedure consisted in shaving with a sharp blade for skin exposure, followed by the application of an antiseptic solution. The incision was made in the animal's skin in the proximal-distal direction, and the soft tissue was manipulated for bone exposure. The exposed bone was then perforated by means of a 1.8 mm round bur without saline irrigation, approximately 0.5 cm from the proximal joint. The soft tissues were then closed by standard layered suture techniques. All surgical procedures were performed under anesthesia. Each animal was subjected to sedation, analgesia, and muscle relaxation by means of an intramuscular injection (2-2-xylidine)-5,6-dihydro-4H-1,3-thiazyn Chlorate (Rompum, Bayer, São Paulo, SP, Brazil) (5.0mg/kg), acepromazine (Acepran®1% Univet, São Paulo, SP, Brazil) (0.75mg/kg). For general anesthesia, IM ketamine (Ketamina®, Agener, União Química Farmacêutica Nacional SA, São Paulo, SP, Brazil) (35mg/Kg) was administered. Throughout the

whole procedure, the animals were maintained at deep anesthesia for 60 to 90 minutes.

The experimental groups were then divided according to fixing solution following euthanization as follows: Group 1- ethanol 70% (n=35); Group 2- 10% buffered formalin (n=35); and Group 3- Glycerol diluted in 70% ethanol at a 70/30 ratio + 10% buffered formalin (90% glycerol-ethanol + 10% buffered formalin) (n=35). The euthanization was performed by guillotine decapitation after post-surgical procedure periods from 01, 02, 04, 06, 08, 12, and 24 hours. A total of five animals were utilized per euthanization time per group.

Control Groups

The control animals were divided into four groups. The first control group comprised the Non-Surgical Procedure Group (NSPG, n=5), where no surgery was performed. The second control group comprised animals subjected to Surgical Procedures where Bone Exposure was performed (SPBE or Shan, n=20) without surgical drilling. The third control group comprised the prostate carcinoma group (positive control- PC) (as recommended by the antibody manufacturer, Zymed). A single group of five animals comprised the NSPG group, and the SPBE group animals were euthanized after 0, 1, 2, 4, and 6 hours after the surgical procedure (n=5 per time). The fourth group where only the primary antibody of the antigen-antibody protocol was not utilized (negative control- NC; the immune reaction employed is described in detail below). The NC group was utilized for the purpose of identifying any non-specific reaction in the specimens, and was comprised by randomly selecting a nondecalcified section from each experimental and control groups.

Sample Preparation

Following animal euthanization, the femurs were retrieved by sharp dissection and were immediately stored in three different media as follows: 70% ethanol (Group 1) (1), 10% buffered formalin 0.1M/7.4 pH (Group 2) (17), and glycerol diluted in 70% ethanol at a 70/30 ratio + 10% buffered formalin (Group 3) (18). All control groups but the prostate carcinoma group were formalin fixed and paraffin embedded (19). All samples were maintained under a temperature of 4°C for a period of 7 days irrespective of storage media.

The samples were then washed in running water for a period of 12 hours at room temperature, and a series of alcohols were utilized to dehydrate the samples. The series comprised 70%, 80%, 90%, 95%, 100% ethanol at a -20 °C for 72 hours each step. Following dehydration, the samples were subjected to two xylene baths at -20 °C for 24 hours each (the rationale for this procedure was to decrease the amount of fat tissue in the samples, facilitating the subsequent penetration of the Technovit 7200 VLC® polymer).

The polymer embedding procedure was performed through

a series of Ethanol/Technovit7200 VLC® at 70%-30%, 50%-50%, 30%-70%, 100%, and 100% ratios for 72 hours each step at -20 °C. It should be noted that with the exception of the first step of the dehydration process, where the samples were washed for 12 hours and then placed in 70% ethanol, all other steps were carried out at -20°C.

Following polymer embedding, the samples were placed in polyethylene cups and the polymer was dispensed until fully covering the specimens. Polymer polymerization was carried through light (9 hours in white light followed by 90 hours in blue light). It should be noted that the polymer was at -20°C at the time of bone specimens' final coverage prior to polymerization.

Grinding and Polishing

The samples embedded in Technovit7200 VLC® polymer were thin sectioned (Exakt Apparatebau, Norderstedt, Germany) along the femur long axis aiming the center of the drilling site according to previously published work by Donath and Breuner 1982 (20). The thin sections were attached to acrylic plates by means of a cyanoacrylate cement (Superbond, Loctite), and were grounded and polished (1200 grit SiC paper) in a metallographic polishing wheel (Panambra Tecnica, Sao Paulo, Brazil). The sections were performed along the long axis of the femurs for all groups, and through the drilling site along the femur long axis was included in the experimental groups. The nondecalcified section final thickness was approximately 10 to 15 µm. Samples' cutting, grinding, and polishing was performed under constant irrigation.

Deacrylation

This step is crucial for appropriate immunohistochemical labeling of hard tissue utilizing the Technovit7200 VLC®, since the thorough removal of the embedding material from within the bone tissue will assure the antibody penetration, thereby allowing the antigen-antibody reaction. Failure in embedding material removal prevents this reaction to occur and would characterize processing failure (1).

For the deacrylation purpose, a chemical solvent 2-(methoxyethyl) acetate, recommended by the polymer manufacturer (Technovit 7200VLC®- EXAKT) was utilized. The mounted plates with nondecalcified tissue were immersed into the solvent at 4°C for 48 hours. The final removal of the embedding material was then accomplished by means of a brush, and the samples were washed in acetone twice for 15 minutes. The samples were then mounted in 20% silanized plates, and placed in a furnace for 4 hours at 37°C to assure the sample fixation to the plates prior to analysis.

The samples were then rehydrated in a 100%, 100%, 95%, and 85% ethanol series for 5 minutes each step, and were then immersed in a 100% ethanol + 10% ammonia hydroxide for 10 minutes and rinsed in water for 10 minutes.

The quenching of the endogen peroxidase procedure was performed in the samples, which were immersed in 95% methanol + 20% hydrogen peroxide at a 1:1 pro-

portion. Finally, the samples were rinsed in distilled water for 10 minutes.

Imunohistochemistry/NF-kB.

The prepared and rehydrated sections were submitted to the primary polyclonal antibody anti-NF-kB (rabbit anti human NFKappaB, Zymed Laboratories, South San Francisco, CA, USA) on a 1:75 dilution for a 12 hour period at room temperature. This step was followed by incubation with biotinylated swine-anti-mouse, rabbit, and goat antibody (DAKO - LSAB Kit, Peroxidase K0690, DAKO Corporation, Carpinteria, CA, USA) and with streptavidin-biotin peroxidase conjugate (DAKO - LSAB Kit, Peroxidase K0690, DAKO Corporation, Carpinteria, CA, USA), both for 30 minutes at room temperature. Antibody complexes were visualized after the addition of a buffered diaminobenzidine (DAB) (Dako Liquid DAB plus K3468, DAKO Corporation, Carpinteria, CA, USA) substrate for 10 minutes. The sections were then counterstained with Mayer's hematoxylin for 10 minutes, de-hydrated in ethanol, and were diaphanized with xylene and protected with coverslips.

Sample Imaging and Analysis

For imaging and subsequent evaluation of immunoreaction at the periosteal, endosteal, and at the center of the cortical plate regions at the surgical drilling region, micrographs were acquired by means of a transmitted light optical microscope (Nikon, Eclipse E-1000) at various magnifications. The micrographs were evaluated by means of computer software Image-Proplus 4.1 for Windows (Media. Cybernetics, Silver Spring, MD).

Results

The groups which the bones were stored in 70% ethanol (Group 1), and glycerol diluted in 70% ethanol at a 70/30 ratio + 10% buffered formalin (90% glycerol-ethanol + 10% buffered formalin) (Group 3) did not present immunoreactivity to the NF-kB antibody (Fig. 1). On the other hand, the experimental group which samples

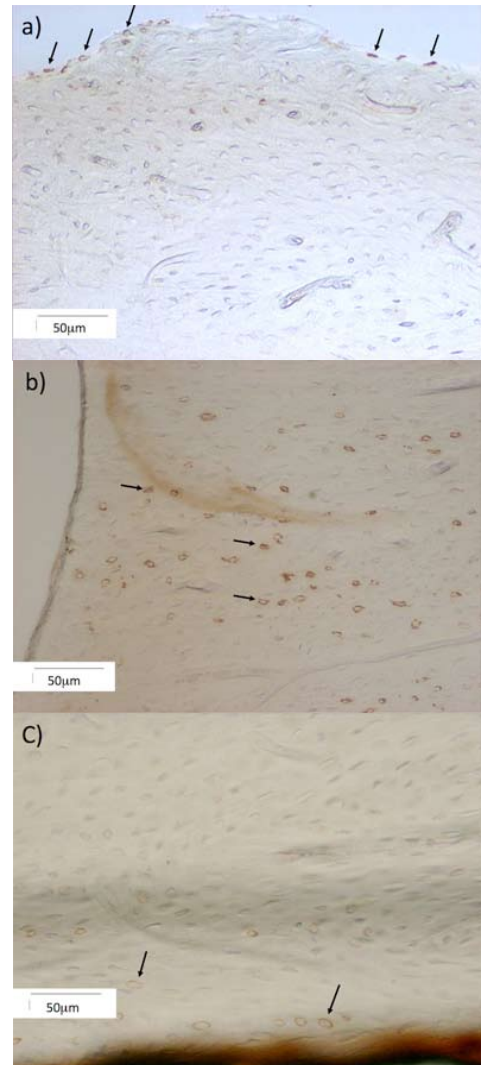


Fig. 2. A positive immunoreaction was observed for the experimental samples stored at 10% buffered formalin (Group 2) at (a) periosteal regions, (b) central in proximity to the drilling site, and (c) endosteal regions. This specimen represents animals euthanized 4 hours after the surgical procedure. NF-kB immunoreaction, original mag 100X.




Fig. 1. Optical micrographs showing that no immunereaction to NF-kB were observed for the bone samples stored in (A) 70% ethanol and (B) glycerol diluted in 70% ethanol at a 70/30 ratio + 10% buffered formaline. The labeling observed in these samples are artifacts, where deposition into the haversian system occurred (arrows). NF-kB immunoreaction, original mag 50X.

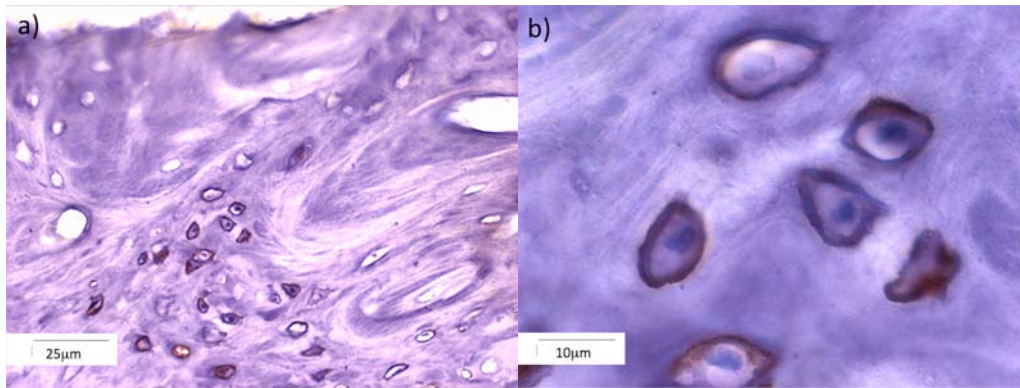


Fig. 3. (a) Mayer's Hematoxylin counter staining showed revealed positive osteocyte immunoreaction (arrow). At higher magnifications (b), it was possible to observe the preferential reaction at peripheral regions of the cytoplasm. Original mag 200X.

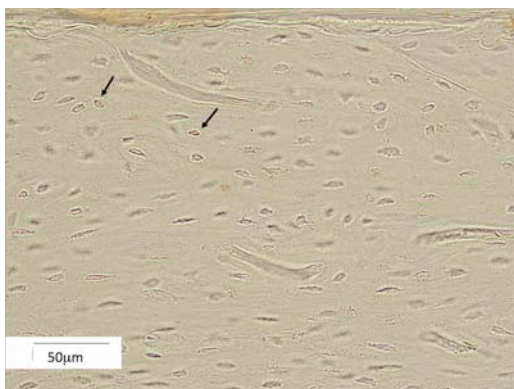


Fig. 4. Mild NF-kB reactivity for the Shan group at the periosteal (P) region (arrows). No immunoreactivity was observed at the endosteal regions. NF-kB immunoreaction, original mag 100X.




Fig. 5. A subtle, dispersed reaction to the NF-kB was observed for the surgical procedure where bone exposure was performed (SPBE) group (arrow). This result showed a physiologic activation of the NF-kB in the Wistar rat cortical. NF-kB immunoreaction, original mag 50X.

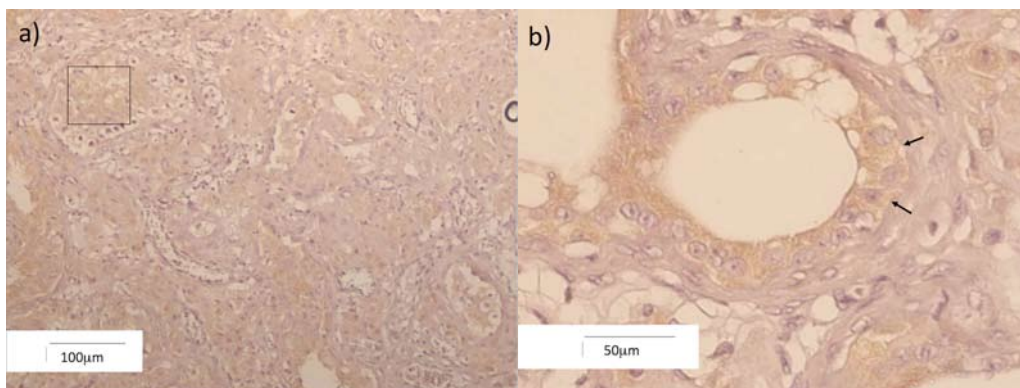


Fig. 6. (A) Low (original mag. 50X) and (B) high magnification of the prostate carcinoma positive control group, where widespread immunoreactivity to NK-kB was observed. The high magnification micrograph (original mag 100X) (b) depicts the preferential labeling presented at the prostate gland duct epithelial cells (arrow). NF-kB immunoreaction.




Fig. 7. No immunoreactivity to the NF-kB was observed for the NC group, indicating that the no secondary and tertiary antibody reaction or DAB reactions resulted in reactivity artifacts. The arrows depict sample artifacts due to deposition in the bone haversian system, as presented in Figures 1 and 2. NF-kB immunoreaction, original mag. 50X.

were immersed in 10% buffered formalin (Group 2 and controls) presented immunoreaction to the NF-kB antibody at the periosteal, central (in proximity to the drilling site) (Fig. 2). Counter staining with the Group 2 samples with Mayer's hematoxylin showed positive osteocyte immunoreaction (Fig. 3a). Higher magnifications showed preferential reactivity at the cytoplasm peripheral regions (Fig. 3b)

The NSPG Group presented reactivity to the NF-kB antibody in the periosteal region only (Fig. 4). However, a subtle and dispersed reaction to the NF-kB was observed at the central and endosteal regions of the SPBE group (Fig. 5). The positive prostate carcinoma group (PC) showed widespread cellular NF-kB labeling, especially at locations surrounding the gland ducts (Fig. 6). No immunoreactivity was observed for the NC group, indicating that no secondary and tertiary antibody reaction or DAB reactions resulted in reactivity artifacts (Fig. 7).

Discussion

The preparation of hard tissue for both microstructural and ultrastructural histomorphologic and histomorphometric analysis has been subject of interest for decades. Due to its hard nature and complex morphology, specific methodologies are required for its study and especially investigation of bone-synthetic materials interactions. Even though embedding, sectioning, and polishing techniques has been described and are widely utilized for the study of bone and bone-biomaterial interactions, such techniques require extensive sample processing and often result in the loss of the tissue ability to react to specific labeling techniques, especially antigen-antibody reactions (1). This lack of reactivity in immunohistochemistry protocols likely results from the series

of chemicals and temperature changes employed during standard nondecalcified section protocols, and has hindered thorough cell specific investigation of bone tissue under physiologic and pathologic conditions (1,5,6,8). The work described in the present manuscript describes a technique utilized to identify the immunoreaction between Wistar rat bone osteocytes and the NF-kB endonuclease. While a detailed description of the NF-kB's role in bone metabolism is beyond the scope of this manuscript, a brief description of its importance will highlight the utilization of the nondecalcified sample processing described for immunohistochemistry protocols for different antigen-antibodies.

Bone tissue is regulated by a series of interrelated mechanisms that include local (tissue level) interactions along with systemic hormonal homeostasis. Recent studies have shown that bone tissue homeostasis is also mediated by the immune system (14,15). The NF-kB endonuclease can signal the cell nucleus and result in a series of events leading to the production of pro-inflammatory cytokines such as the interleukin 1 (IL-1), which may result in osteoclastic activation due to their high specificity to the IL-1 (14,15). This series of events may result then in bone resorption through the RANK/RANKL system, and have significant impact in bone temporal homeostasis (15). Thus, the utilization of this particular antigen-antibody reaction can be applied in studies of diverse pathologic conditions and may result in a better understanding of bone tissue behavior.

This lack of reactivity in immunohistochemistry protocols likely results from the series of chemical and temperature changes employed during standard nondecalcified section protocols, and have hindered thorough cell specific investigation of bone tissue under physiologic and pathologic conditions (4-6). The Technovit 7200 VLC® is a polymer that is widely utilized for the fabrication of bone and bone-biomaterial thin section for histomorphologic and histomorphometric studies following the nondecalcified technique described by Donath and Breuner 1982 (20).

The rationale for modifying the standard technique recommended by the Technovit 7200 VLC® manufacturer was to maintain the protein content of the bone tissue viable. For this purpose, we utilized the temperature of 4C during fixation/immersion in different solutions, as recommended by Yang et al. (1), who utilized the MMA-based polymer Technovit 9100®. Our results showed that only groups where positive results occurred was the one where bone samples were fixed in 10% buffered formalin under a 4C temperature for a period of 7 days (Fig. 2). The samples which were immersed in 70% ethanol (1) and glycerol diluted in 70% ethanol at a 70/30 ratio + 10% buffered formalin (90% glycerol-ethanol + 10% buffered formalin) (18), did not show the positive antigen-antibody reactions (Fig. 1) previously shown in

other polymer protocols (1,18). The marginal response to the NF- κ B endonuclease observed for the NSPG and NPBE groups (Fig. 3 and 4), along with the positive and negative response observed for the PC and NC groups, respectively, showed that no false positive results were introduced by the technique developed.

In addition to the 7 day period under a temperature of 4°C that resulted in positive reactions observed for the 10% buffered formalin solution, our sample dehydration series was performed under a temperature of -20°C. Once again, this procedure was carried out in an attempt to maximize the integrity of the bone tissue protein content. Despite the low temperature employed during the 7 day immersion period in different solutions and during the dehydration series, negative results were obtained for the samples immersed in 70% ethanol (Group 1) and glycerol diluted in 70% ethanol at a 70/30 ratio + 10% buffered formalin (Group 2) (Fig. 1). We speculate that these negative results originated from the lack of protein content preservation, since after 24 hours in solution protein interaction with other biomolecules may difficult immune reactions.

In contrast to the polymerization technique under a temperature of -20°C through a benzoyl peroxide catalyst described by Yang et al. (1), for a MMA-based resin (Technovit 9100®), we utilized room temperature (~25°C) as the Technovit7200 VLC® utilizes a light curing mechanism. Thus, our positive results showed that low temperature processing of the samples must be observed prior to the polymerization, but the ambient temperature light curing was not detrimental to the protein content integrity. On the other hand, should the benzoyl peroxide catalyzed reaction not be carried under low temperatures, protein denaturation and negative antigen-antibody reactions will result due to the high exothermal characteristic of this reaction (1).

While protein maintenance has been achieved by the use of a MMA-based polymer and by the technique here described, an important aspect is the removal of the polymerized polymer from the sample for appropriate antigen-antibody reaction (1,6). The utilization of MEA(1-acetoxy-2-methoxy-ethane) as a solvent of the MMA-based resin Technovit 9100® (1), and 2-(methoxyethyl) acetate as solvent for the Technovit7200 VLC® were not detrimental for the achievement of the antigen-antibody reaction. These observations suggest that the appropriate conservation of the samples during fixation, dehydration, and polymerization for both Technovit7200 VLC® and 9100 are the key for successful immunohistochemistry experimentation of nondecalcified bone sections.

Conclusion

In order to develop a technique to locate the antigen-antibody reaction through the activation of the NF- κ B endonuclease in a Wistar rat model, a modification of

the widespread standard technique utilized for the Technovit7200 VLC® polymer was developed. The rationale for the low temperature processing was to maintain the bone protein content viable throughout the process. Our methodology showed positive immunohistochemistry results for Wistar rat femurs, and resulted in no false positive results. The application of our methodology in different animal models and bone-biomaterial thin sections is the subject of current investigations.

References

References with links to Crossref - DOI

1. Yang R, Davies CM, Archer CW, Richards RG. Immunohistochemistry of matrix markers in Technovit 9100 New®-embedded undecalcified bone sections. *Eur Cell & Materials*. 2003;31:57-71.
2. Schenk R. On the histological processing of undecalcified bone. *Acta Anat (Basel)*. 1965;60:3-19.
3. Burkhardt R. [Preparatory conditions for clinical histology of human bone marrow. 2. A new procedure for histological preparation of bone and bone marrow biopsies]. *Blut*. 1966;14:30-46.
4. Ruddell CL. Hydroxyethyl methacrylate combined with polyethylene glycol 400 and water; and embedding medium for routine 1-2 micron sectioning. *Stain Technol*. 1967;42:119-23.
5. Westen H, Mück KF, Post L. Enzyme histochemistry on bone marrow sections after embedding in methacrylate at low temperature. *Histochemistry*. 1981;70:95-105.
6. Chappard D, Palle S, Alexandre C, Vico L, Riffat G. Bone embedding in pure methyl methacrylate at low temperature preserves enzyme activities. *Acta Histochem*. 1987;81:183-90.
7. Sanderson C. Entering the realm of mineralized bone processing: a review of the literature and techniques. *J Histotechnol* 1997;20:259-266.
8. Haddad JJ, Land SC, Tarnow-Mordi WO, Zembala M, Kowalczyk D, Lauterbach R. Immunopharmacological potential of selective phosphodiesterase inhibition. II. Evidence for the involvement of an inhibitory-kappaB/nuclear factor-kappaB-sensitive pathway in alveolar epithelial cells. *J Pharmacol Exp Ther*. 2002;300:567-76.
9. Li X, Stark GR. NF-kappaB-dependent signaling pathways. *Exp Hematol*. 2002;30:285-96.
10. Dolcet X, Llobet D, Pallares J, Matias-Guiu X. NF-kB in development and progression of human cancer. *Virchows Arch*. 2005;446:475-82.
11. Moynagh PN. The NF-kappaB pathway. *J Cell Sci*. 2005;118:4589-92.
12. Yamamoto Y, Gaynor RB. I-kappaB kinases: key regulators of the NF-kappaB pathway. *Trends Biochem Sci*. 2004;29:72-9.
13. Kumar A, Takada Y, Boriek AM, Aggarwal BB. Nuclear factor-kappaB: its role in health and disease. *J Mol Med*. 2004;82:434-48.
14. Aggarwal BB. Nuclear factor-kappaB: the enemy within. *Cancer Cell*. 2004;6:203-8.
15. Perkins ND. NF-kappaB: tumor promoter or suppressor? *Trends Cell Biol*. 2004;14:64-9.
16. Ravi R, Bedi A. NF-kappaB in cancer--a friend turned foe. *Drug Resist Updat*. 2004;7:53-67.
17. Zaharieva B, Simon R, Ruiz C, Oeggerli M, Mihatsch MJ, Gasser T, et al. High-throughput tissue microarray analysis of CMYC amplification in urinary bladder cancer. *Int J Cancer*. 2005;117:952-6.
18. Bourque WT, Gross M, Hall BK. A histological processing technique that preserves the integrity of calcified tissues (bone, enamel), yolk amphibian embryos, and growth factor antigens in skeletal tissue. *J Histochem Cytochem*. 1993;41:1429-34.
19. Junqueira, U. L. C. & Junqueira, S. M. M. L. *Técnicas Básicas de Citologia e Histologia*. Ed. Santos. 1ª Edição, 1984.
20. Donath K, Breuner G. A method for the study of undecalcified bones and teeth with attached soft tissues. The Säge-Schliff (sawing and grinding) technique. *J Oral Pathol*. 1982;11:318-26.

Acknowledgements

The authors express their gratitude to Edna Tonai from the Dept. of Pathology at the university of Sao Paulo. We would also like to express our gratitude to Dr. Maria Inês Nogueira from the Lab. of Neurosciences ICB/USP during the data collection of this experiment.