

Journal section: Oral Surgery
 Publication Types: Case Report

doi:10.4317/medoral.16.e79
<http://dx.doi.org/doi:10.4317/medoral.16.e79>

A novel trephine design for sinus lift lateral approach. Case report

Núria Farré-Pagès¹, Maria-Luisa Augé-Castro², Fernando Alaejos-Algarra³, Javier Mareque-Bueno⁴, Eduard Ferrés-Padró⁵, Federico Hernández-Alfaro⁶

- ¹ DDS, Master in Oral Implantology, PhD student
² MD, DDS, Master in Oral Implantology, A. Professor
³ MD, DDS, PhD Master in Oral Implantology, A. Professor
⁴ MD, DDS, PhD OMFS, A. Professor
⁵ MD, DDS, PhD OMFS, Prof. and Head of Department
⁶ MD, DDS, PhD OMFS, Prof. and Director Master in Oral Implantology

Correspondence:

Medicine, Surgery and Oral Implantology Department.
 Dental School. Universitat Internacional de Catalunya
 Josep Trueta, s/n
 08195 Sant Cugat del Vallès
 Barcelona, Spain
nuriafarrepages@telefonica.net

Farré-Pagès N, Augé-Castro ML, Alaejos-Algarra F, Mareque-Bueno J, Ferrés-Padró E, Hernández-Alfaro F. A novel trephine design for sinus lift lateral approach. Case report. Med Oral Patol Oral Cir Bucal. 2011 Jan 1;16 (1):e79-82.
<http://www.medicinaoral.com/medoralfree01/v16i1/medoralv16i1p79.pdf>

Received: 12-01-2010
 Accepted: 23-04-2010

Article Number: 17016 <http://www.medicinaoral.com/>
 © Medicina Oral S. L. C.I.F. B 96689336 - pISSN 1698-4447 - eISSN: 1698-6946
 eMail: medicina@medicinaoral.com
Indexed in:
 Science Citation Index Expanded
 Journal Citation Reports
 Index Medicus, MEDLINE, PubMed
 Scopus, Embase and Emcare
 Índice Médico Español

Abstract

Various techniques are described in the literature, either by crestal or lateral approach. Sinus augmentation has a high percentage of success, but presents a number of intraoperative and postoperative complications. The most frequent complication is the Schneiderian membrane perforation with a percentage of perforations between 11% and 56% according to authors. The aim of this study is to describe another membrane approach technique for the sinus lateral wall osteotomy that minimizes the risk of Schneiderian membrane perforation. We present a case of a 50 year old patient attended the University Dental Clinic (UDC) of International University of Catalonia for implant and crown treatment due to the loss of a right maxillary first molar. To insert an implant in position 1.6 a computerized tomography (CT) was requested to determine with greater accuracy the quantity of residual crestal bone. It showed a height of 5 mm and width of 8 mm. The lateral osteotomy was performed with a (SLA KIT® -Neobiotech) trephine mounted in the same implant handpiece with which the field for the implant and the implant itself were prepared. It can be concluded that in the case described, the use of trephine drills of the SLA system mounted in a handpiece allows better access to lateral approach due to its perpendicular position relative to the sinus wall minimizing the membrane perforation risk.

Key words: Sinus lift, lateral approach, membrane perforation, trephine drills, dental implant.

Introduction

The sinus lift technique was introduced by Tatum in 1975 and published by Boyne & James in 1980 (1). This pre-prosthetic surgery allows bone augmentation in the posterior zone of atrophic maxilla in pneumatized sinus cases for implant surgery at the same time as, or after osseointegration of sinusal graft material.

Various techniques are described in the literature, either by crestal or lateral approach. The lateral approach is to perform an osteotomy in the lateral sinus wall opening a bone window that allows access to lift the Schneiderian membrane and to place the graft material. Sinus augmentation has a high percentage of success, but presents a number of intraoperative complications (membrane perforation, fracture of the residual alveolar ridge, obstruction of the maxillary ostium, hemorrhage, and damage to adjacent dentition), early postoperative complications (hemorrhage, wound dehiscences, acute infection, exposure of barrier membrane, graft infection, graft loss and dental implants failure) and late postoperative complications (graft loss, implant loss or failure, implant migration, oroantral fistula, chronic pain, chronic sinus disease, chronic infection) (2,3). The most frequent complication is the Schneiderian membrane perforation with a percentage of perforations between 11% and 56% according to authors. The Schneiderian membrane is composed of periosteum covered by respiratory epithelium, which is thin, friable and easy to perforate. The window design, the presence of maxillary sinus septa, sinus floor irregularities and a residual ridge of 3 mm or less, increase the risk of perforation (4,5). Wallace et al. (6) describe that in most cases, perforation occurs during the use of rotary instruments for sinus wall osteotomy, before lifting the membrane. His study, showed 30% perforations with the use of rotary instruments and a drill, while with the use of piezoelectrics there were only 7% perforations. According to results, Stübinger et al. (7) who compare the ultrasonic bone cutting with burs for surgical approach for sinus lift and bone blocks graft, conclude that ultrasonic use preserves adjacent soft tissues structures. Later, Blus et al. (8) in 2008 refers to 3.8% perforations, 2 out of 53 membranes that were perforated during the sinus approach with the application of ultrasonics. The membrane perforation can lead to graft material loss, graft material dispersion leading to bacterial contamination and postoperative infection (9).

The aim of this study is to describe another membrane approach technique for the sinus lateral wall osteotomy that minimizes the risk of Schneiderian membrane perforation using the surgical instruments from a SLA KIT –Yield® (Neobiotech) mounted in a dental implant handpiece, and to assess the advantages and disadvantages offered by the system.

Clinical Case

We present a case of a 50 year old patient attended the University Dental Clinic (UDC) of International University of Catalonia for implant and crown treatment due to the loss of a right maxillary first molar. A clinical history was completed, an intraoral examination made, and extraoral and intraoral registers (study cast, frontal and lateral pictures in maxim intercuspitation, excursive movements and panoramic radiography) were performed at the first visit. The patient did not have any medical nor surgical contraindication to maxillary sub-antral augmentation. In a radiographic test we observed a right maxillary sinus pneumatized with a low bone height. To insert an implant in position 1.6 a computerized tomography (CT) was requested to determine with greater accuracy the quantity of residual crestal bone. It showed a height of 5 mm and width of 8 mm (Fig. 1).

We carried out a sinus lift and the implant insertion in position 1.6 at the same time to minimize the number of operations on the patient.

Access to the membrane approach was effected using the SLA KIT –Yield® (Neobiotech) for sinus lift lateral approach access. This kit has a guide drill to start the window design and obtain the correct position so avoiding slips, then the SL Reamer and/or C Reamer drills are used. The drills have diameters of 4.5 mm, 5.5 mm and 6.5 mm. The LS Reamer drills have a height of 2 mm and 3.5 mm and the C Reamer drills have heights of 1.5 mm and 3 mm. After setting the position with a guide drill the LS Reamer drill is used to collect bone chips during osteotomy of the lateral window of the sinus or the C Reamer drill that allows the safe osteotomy of the lateral window. The drill diameter and height is determined depending on each case. The contact surface of the reamer drill allows the osteotomy without the risk of perforating the Schneiderian membrane sinus.

A sterile surgical area was prepared. Surgical procedure was under a local anesthetic nerve block in the right upper maxilla, and infiltrative anesthesia in palatal zone at palatal foramen level. A crestal incision was made and a distal vertical discharge. A mucoperiosteal flap was lifted and a maxillary alveolar process was revealed. The osteotomy was performed at a height of 7 mm above the crestal margin with a trephine mounted in the same implant handpiece with which the field for the implant and the implant itself were prepared. Osteotomy milling was at 2000 rpm with external irrigation, perpendicular to the sinus wall up to the sinusal membrane. The contact area of trephine drill permits contact with the membrane without causing perforation (Fig. 2).

The lateral bone window was removed with a periosteal elevator and the membrane lifted with lift instruments from the SLA KIT. After the insertion of the sinus graft and implant in 1.6 position, the lateral window wall was repositioned and the surgical incision area was sutured

with a monofilament suture 4/0. To prevent early postoperative complications of sinus augmentation, antibiotics and analgesics were prescribed and the patient was given information on postoperative care. The suture was removed one week after surgery. After 7 months a panoramic radiography image was obtained (Fig. 3).

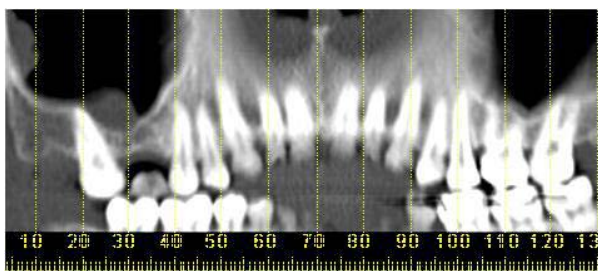


Fig. 1. Panoramic projection in the CT of surgical zone.

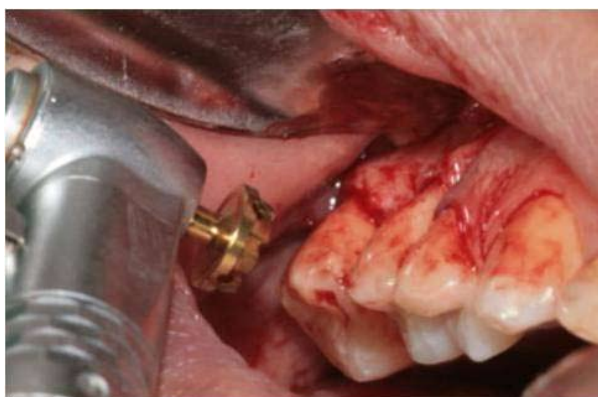


Fig. 2. Lateral osteotomy.

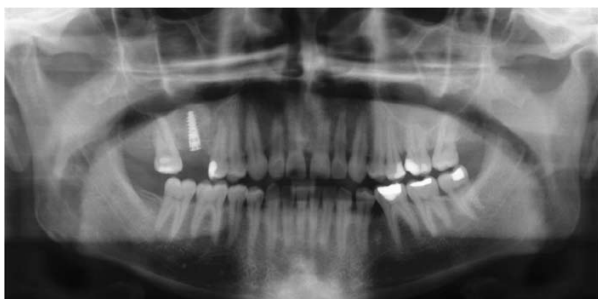

Fig. 3. Panoramic radiography before second stage.

Discussion

As the membrane integrity is important it is essential to produce a cavity which will limit the amount of sinus graft material inserted into the zone so improving implant survival and reducing complications.

Ardekian et al. (4) assess the incidence of membrane perforations, complications, and successful treatment. They did not find significant differences between implant survival for implants inserted in a grafted sinus where there was a membrane perforation and sinus with the membrane intact. However, Proussaefs et al. (9) found fewer implant survivals for implants installed in a grafted sinus with membrane perforation. Subsequently agreeing with this author, Hernández-Alfaro et al. (10) studied the prevalence of surgical complications and described an action protocol relating to the perforation size. These authors describe in their results a lower implant survival rate for implants installed in grafted sinus when there was a membrane perforation influenced also by perforation size. These results coincided with the results reported by Viña-Almunia et al. (11) who concluded that the survival of implants diminishes when they are placed in sinus lifts with a perforated membrane.

There are different options described in the literature for preparing the lateral window, such as conventional osteotomy using rotating instruments (round burs), trephines, piezosurgery and/or lasers.

Romanos (12) describes a different technique for window preparation for sinus lift procedure. A round burr is used to prepare the osteotomy with continuous saline solution irrigation. Before the sinus mucosa is visible through the maxillary bone at the osteotomy site, a mallet and a dental mirror holder is used to tap in one blow in a perpendicular direction to the lateral bony wall, in the middle of the window. The author was not able to observe any perforation of the sinus floor mucosa using this technique in the 56 cases described. However, Sohn et al. (13) published a study where erbium, chromium, yttrium–scandium–gallium–garnet (Er, Cr:YSGG) laser and various laser systems were used for 12 sinus bone grafts in ten patients. The efficiency of the laser was evaluated according to the osteotomy time and the rate of sinus membrane perforation. The author describes a perforation ratio of 33.3% and all the implants placed immediately were successful.

In 2002, Emtiaz et al. (14) published the same surgical procedure using trephines (Implant Innovations®, Inc., Ibérica, SL, Barcelona, Spain) although reference is made to the need for caution during the lateral osteotomy due to the membrane perforation risk using a trephine.

The trephine used in this situation (SLA KIT –Yield® Neobiotech), presents differences from conventional trephine used. The contact surface of the new trephine has a curved periphery and a bone-maintaining area

contacting surface. The bone maintaining area includes a first inside wall oriented in a drilling direction higher than a second inside wall with a drilling surface exposed in the drilling direction preventing sinus membrane damage when the head of drill contacts the membrane. The described technique in this article presents a number of advantages such as reduced surgical time, a small and accurate access for sinus lift for a single implant and lower risk of perforation of the sinus membrane. Due to the technique of performing osteotomy with a trephine mounted in the same handpiece used later for implant surgery, the use of auxiliary different handpieces or piezoelectric equipment was eliminated, so reducing the surgical cost.

It can be concluded that in the case described, the use of trephine drills of the SLA system mounted in a handpiece allows better access to lateral approach due to its perpendicular position relative to the sinus wall. The shape of the contact area of the drills minimizes the sinus membrane perforation risk during osteotomy. Lateral approach for sinus lifts by this technique did not present any complications in the documented case. This method provides greater confidence and security for the clinician at the time of the lateral osteotomy, and reduces the surgical time of this phase.

References

References with links to Crossref - DOI

1. Chanavaz M. Maxillary sinus: anatomy, physiology, surgery, and bone grafting related to implantology--eleven years of surgical experience (1979-1990). *J Oral Implantol.* 1990;16:199-209.
2. Zijdeveld SA, Van den Bergh JP, Schulten EA, Ten Bruggenkate CM. Anatomical and surgical findings and complications in 100 consecutive maxillary sinus floor elevation procedures. *J Oral Maxillofac Surg.* 2008;66:1426-38.
3. Raghoobar GM, Batenburg RH, Timmenga NM, Vissink A, Reintsema H. Morbidity and complications of bone grafting of the floor of the maxillary sinus for the placement of endosseous implants. *Mund Kiefer Gesichtschir.* 1999;3Suppl 1:S65-9.
4. Ardekian L, Oved-Peleg E, Mactei EE, Peled M. The clinical significance of sinus membrane perforation during augmentation of the maxillary sinus. *J Oral Maxillofac Surg.* 2006;64:277-82.
5. Pikos MA. Maxillary sinus membrane repair: report of a technique for large perforations. *Implant Dent.* 1999;8:29-34.
6. Wallace SS, Mazor Z, Froum SJ, Cho SC, Tarnow DP. Schneiderian membrane perforation rate during sinus elevation using piezosurgery: clinical results of 100 consecutive cases. *Int J Periodontics Restorative Dent.* 2007;27:413-9.
7. Stübinger S, Landes C, Seitz O, Zeilhofer HF, Sader R. [Ultrasonic bone cutting in oral surgery: a review of 60 cases]. *Ultraschall Med.* 2008;29:66-71.
8. Blus C, Szmukler-Moncler S, Salama M, Salama H, Garber D. Sinus bone grafting procedures using ultrasonic bone surgery: 5-year experience. *Int J Periodontics Restorative Dent.* 2008;28:221-9.
9. Proussaefs P, Lozada J, Kim J, Rohrer MD. Repair of the perforated sinus membrane with a resorbable collagen membrane: a human study. *Int J Oral Maxillofac Implants.* 2004;19:413-20.
10. Hernández-Alfaro F, Torradeflot MM, Marti C. Prevalence and management of Schneiderian membrane perforations during sinus-lift procedures. *Clin Oral Implants Res.* 2008;19:91-8.
11. Viña-Almunia J, Peñarrocha-Diago M, Peñarrocha-Diago M. Influence of perforation of the sinus membrane on the survival rate of implants placed after direct sinus lift. Literature update. *Med Oral Patol Oral Cir Bucal.* 2009;14:E133-6.
12. Romanos GE. Window preparation for sinus lift procedures: a simplified technique. *Implant Dent.* 2008;17:377-81.
13. Sohn DS, Lee JS, An KM, Romanos GE. Erbium, chromium:yttrium-scandium-gallium-garnet laser-assisted sinus graft procedure. *Lasers Med Sci.* 2009;24:673-7.
14. Emtiaz S, Caramês JM, Pragosa A. An alternative sinus floor elevation procedure: trephine osteotomy. *Implant Dent.* 2006;15:171-7.