

Journal section: Oral Surgery  
 Publication Types: Research

doi:10.4317/medoral.16.e522  
<http://dx.doi.org/doi:10.4317/medoral.16.e522>

## Non-syndromic supernumerary premolars

Göksel-Şimşek Kaya <sup>1</sup>, Günay Yapıcı <sup>2</sup>, Mehmet-Melih Ömezli <sup>2</sup>, Ertunç Dayı <sup>3</sup>

<sup>1</sup> Assistant Professor, Department of Oral and Maxillofacial Surgery, Faculty of Dentistry, Atatürk University

<sup>2</sup> Research Assistant, Department of Oral and Maxillofacial Surgery, Faculty of Dentistry, Atatürk University

<sup>3</sup> Professor, Department of Oral and Maxillofacial Surgery, Faculty of Dentistry, Atatürk University

Correspondence:  
 Atatürk University  
 25240, Erzurum (Turkey)  
[gokselimsek@yahoo.com](mailto:gokselimsek@yahoo.com)

Kaya GS, Yapici G, Ömezli MM, Dayı E. Non-syndromic supernumerary premolars. Med Oral Patol Oral Cir Bucal. 2011 Jul 1;16 (4):e522-5.  
<http://www.medicinaoral.com/medoralfree01/v16i4/medoralv16i4p522.pdf>

Received: 25/02/2010  
 Accepted: 07/04/2010

Article Number: 16872 <http://www.medicinaoral.com/>  
 © Medicina Oral S. L. C.I.F. B 96689336 - pISSN 1698-4447 - eISSN: 1698-6946  
 eMail: [medicina@medicinaoral.com](mailto:medicina@medicinaoral.com)

Indexed in:  
 Science Citation Index Expanded  
 Journal Citation Reports  
 Index Medicus, MEDLINE, PubMed  
 Scopus, Embase and Emcare  
 Índice Médico Español

### Abstract

**Objective:** The objective of this study was to estimate the incidence of non-syndromic supernumerary premolars, to classify them and to identify the complications related to them.

**Study Design:** This retrospective cohort study was composed of 8400 panoramic radiographs of patients who presented at our Oral and Maxillofacial Surgery Services from January 1998 to May 2008. The number of supernumerary premolars, their localization, the ages and the sex of the patients, any associated complications and treatment methods were estimated.

**Results and Conclusion:** A total of 20 supernumerary premolar teeth were found in 10 of the 8400 patients (0.24%) with 7 of those being females and three males. Three patients had pain localized to the mental foramen and one patient had resorption in the root of the adjacent tooth. In these series, 18 supernumerary premolar teeth were extracted. In contrast with previous studies, this study suggested that this phenomenon is more frequently encountered in females than in males. The presence of complications associated with the supernumerary premolars in 4 patients necessitated consideration of surgical intervention as a treatment choice for these teeth. Otherwise, they should be kept under observation.

**Key words:** Supernumerary tooth, impacted supernumerary premolar, syndrome, surgical treatment consideration.

### Introduction

Extra teeth in dentition are termed "Supernumerary teeth" and are a very well known dental phenomenon (1-9). The prevalence of these teeth for permanent and primary dentition in various populations is between 0.5-5.3% and 0.2-0.8% (4, 6-8). It has been reported that the prevalence of the supernumerary premolars (SP) in permanent dentition is between 0.075-0.26% and that supernumerary premolars account for only 10% of all the supernumerary cases (10). The difference of these

teeth from the other supernumeraries is that they more commonly occur in the mandible (11-13). The number of supernumerary premolar teeth is usually one. Single supernumeraries occur in 76-86% of cases, double supernumeraries occur in 12-23% of the cases and multiple supernumerary teeth in less than 1% of cases (2).

This study aimed to investigate the prevalence of the non-syndromic supernumerary premolar teeth in a Turkish subpopulation.

### Materials and Methods

We designed a retrospective observational study comprising 8400 panoramic radiographs that was taken on patients who presented at our Oral and Maxillofacial Surgery Services between January 1998 and May 2008. Patients who had maxillofacial anomalies such as cleft lip and palate and diseases associated with systemic conditions and syndromes such as cleidocranial dysplasia and Gardner syndrome were not included in this study. The number of supernumerary premolars, their localization, the ages and sex of the patients, any other associated complications and treatment methods were recorded. Two or more supernumerary teeth found in a single patient were termed “multiple supernumerary teeth”. One group of researchers examined the radiographs at the same time on standard light boxes to determine the number and localization of these teeth and the presence of associated pathologies.

### Results

A total of 20 supernumerary premolar teeth were found in 10 of the 8400 patients (0.24%) with 7 of those patients being females (ages 14–39 years) and 3 males (ages 16–24 years) (Table 1, 2). Only one of the supernumerary premolars was partially impacted whereas all the rest were fully impacted. Eighteen of the supernumerary premolar teeth were in a supplemental form and the other 2 were in a rudimentary form. Thirteen of the supernumerary premolars were positioned mesiangularly, 5 were positioned vertically, 1 was positioned disioangularly and 1 was positioned in a horizontal fashion (Fig. 1). Three of the patients had pain in the foramen mental region (Fig. 2) and resorption was estimated in the root of an adjacent tooth in one patient (Fig. 3). In this series, 18 supernumerary premolar teeth were extracted.

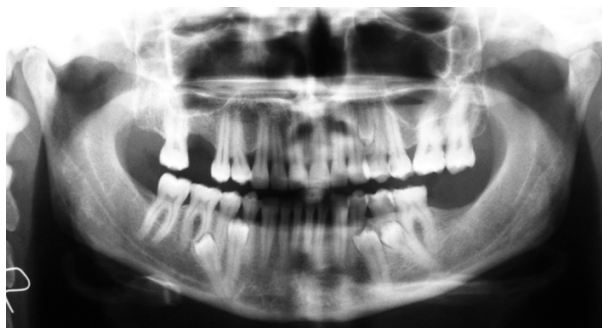**Table 1.** Prevalence, Age, Gender Ratio for Patients with One or More Supernumerary Premolars.

	Cases	Prevalence %	Female	Male	Gender ratio	Mean age	Age range (Years)
<b>1 Supernumerary premolar</b>	3	0.04	3			18	14–21
<b>2 Supernumerary premolars</b>	6	0.07	3	3	1: 1	21.6	16–26
<b>5 Supernumerary premolars</b>	1	0.01	1			39	39

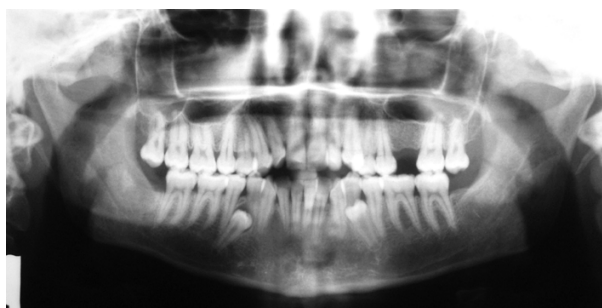
**Table 2.** Clinical and Radiographic Features of Supernumerary Premolars.

Patient	Age (Y)	Sex	Maxilla R	Maxilla L	Mandibula R	Mandibula L	ES	Uni/Bi	Associated pathology	Treatment protocol
1	24	F			1	1	I	Bi	Pain (right site)	Extraction
2	21	F			1		I	U	Pain	Extraction
3	19	F			1		I	U	None	Orthodontic Extraction
4	22	F			1	1	I	Bi	None	Extraction
5	14	F			1		I	U	Pain	Extraction
6	16	M			1	1	I	Bi	None	Observation
7	24	M			1	1	I	Bi	None	Extraction
8	39	F		1	2	2	I	Bi	None	Extraction
9	26	F			1	1	I	Bi	None	Extraction
10	18	M			1	1	I	Bi	RS (right site)	Extraction

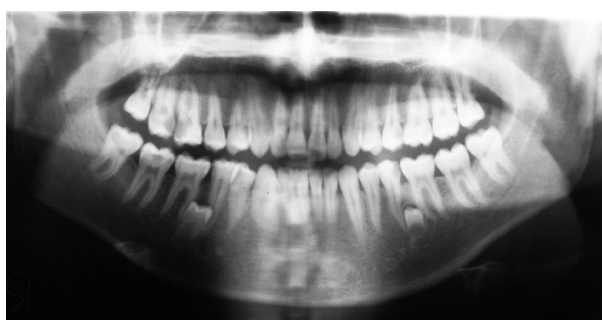Y, years; F, female; M, male R, right; L, left; ES, eruption status; Uni/Bi, unilateral/bilateral; I, impact; SP, supernumerary premolar; RS, root resorption.



**Fig. 1.** Panoramic radiograph of patient aged 39 years. This patient has four supernumerary premolars in the mandible and one in the maxilla.



**Fig. 2.** Panoramic radiograph of patient aged 24 years. This patient was complained of pain that was due to supernumerary premolar in the lower right premolar region.



**Fig. 3.** Panoramic radiograph of patient aged 18 years. All permanent teeth are present plus early crown formation of two supernumerary teeth in the lower premolar region bilaterally. The supernumerary premolar that was found on the right lower jaw in this patient, has led to the root resorption of the lower right second premolar.

## Discussion

The prevalence of supernumerary premolars has been reported differently in various studies due to the differences in patient population samples, age groups, ethnicity and applied radiographic techniques (1). In a study conducted in Mexico on 2241 patients, Salcido-García et al. (14) reported the prevalence of the premolars to be

1.7% whereas another study from USA, in which 1100 orthodontic patients were included, found the prevalence of supernumerary premolars to be 0.64% (12). In a study of 2599 Turkish children, Esenlik et al. (15) reported the prevalence of the maxillary supernumerary premolars to be 0.2% and mandibular supernumerary premolars to be 0.5%. Nevertheless, in our study the prevalence of maxillary and mandibular supernumerary premolars were found to be 0.01% and 0.2%, respectively. Although according to the literature the supernumerary premolars are more frequent in males than females (2,4,10), in our study, the male to female ratio was 1:2.3. This difference may be due to ethnic factors as well as to the fact that the patients who presented to our surgery clinic were mostly women.

Supernumerary teeth may occur with or without more than 20 syndromes and developmental conditions, however, non-syndromic multiple supernumerary teeth are rarely encountered (7,9,14,16). The prevalence of the multiple supernumerary premolars in this study was 0.08%. This constitutes a higher ratio when compared with the study by Hyun et al. (10).

Although there are some supported theories, the exact etiology for hyperodontia is not yet well known. Some of the theories for the formation of supernumerary teeth include atavism, splitting of the tooth bud and a combination of genetic and environmental factors (1,3,6-10,13). However, the most accepted theory is regards hyperactivity of the dental lamina (7). According to Gardiner (17), who is one of the supporters of this theory, late developing (postpermanent) supernumerary teeth develop from the proliferation of the dental lamina after the permanent dentition is completed. In this study, case 5 was 14 years old and had supernumerary teeth in the lower right premolar region; and case 10 was 18 years old and had supernumerary teeth in the lower premolar region bilaterally with the crowns being newly developed.

Supernumerary premolars are usually asymptomatic and most cases are diagnosed by chance during inspection of radiographs prior to the commencement of orthodontic treatment (1,6,7). Bodin et al. (16) have reported that only 2% of the supernumerary premolars are likely to undergo pathological changes. Nevertheless, the most commonly encountered complications with these teeth are dentigerous cyst and root resorption at the adjacent tooth (1). In our study, the supernumerary premolar that was found on the right lower jaw in case 10 had led to the root resorption of the lower right second premolar. Although it has not yet been reported, compression of the supernumerary premolars on the adjacent teeth and their closeness to the mental and inferior dental nerves may lead to pain. In our study, 3 patients presented to our clinic complaining of pain that was due to supernumerary premolars.

In planning treatment alternatives for impacted supernumerary premolars, the potential risks of leaving them in situ and the hazards of surgical removal of these teeth especially around the lower premolar region, where the teeth are close proximity to the inferior dental and mental nerves, should be assessed judiciously (3,8,13). According to many clinicians, surgical removal of these teeth is the only method of treatment (1,9,10). When there is potential for complications according to the radiographic and clinical assessment or a complication has been experienced, surgical removal of the teeth should be considered (1). King et al. (18) have reported that the supplemental teeth may erupt into the dental arch if left in situ and hence they should be periodically controlled for a pathological outcome. If the fact that 75% of supernumerary premolars become impacted is taken into consideration (1,10), radiographic evaluation is a necessity. On the other hand, as the sensitivity of the community towards radiation increases and professional attitudes have been altered in conjunction with the delineated hazards of radiation, the number of radiographs taken is significantly decreased in current practice (1).

The timing of surgical removal of supernumerary premolars is as much debated among clinicians as are the treatment methods (1). Whenever these teeth are associated with any pathological formation or when they hinder the eruption of, or give rise to a malpositioning of the permanent teeth, they should be removed as soon as possible (2,15). Furthermore, early diagnosis and treatment of these teeth will contribute to an interceptive orthodontic approach and correction of arch crowding. In parallel with this point of view, some authors recommend the removal of the supernumerary teeth before the commencement of any orthodontic treatment procedure (1). Nevertheless, many clinicians recommend leaving asymptomatic supernumerary premolar teeth in situ until development of the adjacent anatomic structures and root development of the adjacent teeth has been completed at the end of the permanent dentition (1,13,19). Some surgeons have recommended removal of the supernumerary premolars at the same time in cases having an indication for the extraction of the third molars would be a more conservative approach (13,19). If we bear in mind that it takes supernumerary premolars more time to complete development compared to normal teeth (1), it can be said that it would be more advisable to save the surgical intervention until the end of the permanent dentition.

## Conclusion

In contrast to previous studies, we found that this phenomenon is seen more frequently in females than males. Revealing complications related to supernumerary premolars in 4 patients, we can deduce that surgical in-

tervention in the treatment of these teeth is an appropriate method. Nevertheless, patients who are reluctant to accept the proposed therapy should be educated about the potential risks and complications of this phenomenon and they should be kept under observation.

## References

*References with links to Crossref - DOI*

1. Solares R, Romero MI. Supernumerary premolars: a literature review. *Pediatr Dent*. 2004;26:450-8.
2. Rajab LD, Hamdan MA. Supernumerary teeth: review of the literature and a survey of 152 cases. *Int J Paediatr Dent*. 2002;12:244-54.
3. Moore SR, Wilson DF, Kibble J. Sequential development of multiple supernumerary teeth in the mandibular premolar region -- a radiographic case report. *Int J Paediatr Dent*. 2002;12:143-5.
4. Sasaki H, Funao J, Morinaga H, Nakano K, Ooshima T. Multiple supernumerary teeth in the maxillary canine and mandibular premolar regions: a case in the postpermanent dentition. *Int J Paediatr Dent*. 2007;17:304-8.
5. Gündüz K, Muğlali M. Non-syndrome multiple supernumerary teeth: A case report. *J Contemp Dent Pract*. 2007;8:81-7.
6. Yagüe-García J, Berini-Aytés L, Gay-Escoda C. Multiple supernumerary teeth not associated with complex syndromes: a retrospective study. *Med Oral Patol Oral Cir Bucal*. 2009;14:E331-6.
7. Ferrés-Padró E, Prats-Armengol J, Ferrés-Amat E. A descriptive study of 113 unerupted supernumerary teeth in 79 pediatric patients in Barcelona. *Med Oral Patol Oral Cir Bucal*. 2009;14:E146-52.
8. Díaz A, Orozco J, Fonseca M. Multiple hyperodontia: report of a case with 17 supernumerary teeth with non syndromic association. *Med Oral Patol Oral Cir Bucal*. 2009;14:E229-31.
9. Anegundi RT, Tavargeri A, Indushekar KR, Sudha P. Sequential development of multiple supplemental premolars. Four-year follow-up report. *N Y State Dent J*. 2008;74:46-9.
10. Hyun HK, Lee SJ, Ahn BD, Lee ZH, Heo MS, Seo BM, et al. Nonsyndromic multiple mandibular supernumerary premolars. *J Oral Maxillofac Surg*. 2008;66:1366-9.
11. Yusof WZ. Non-syndrome multiple supernumerary teeth: literature review. *J Can Dent Assoc*. 1990;56:147-9.
12. Rubenstein LK, Lindauer SJ, Isaacson RJ, Germane N. Development of supernumerary premolars in an orthodontic population. *Oral Surg Oral Med Oral Pathol*. 1991;71:392-5.
13. Scanlan PJ, Hodges SJ. Supernumerary premolar teeth in siblings. *Br J Orthod*. 1997;24:297-300.
14. Salcido-García JF, Ledesma-Montes C, Hernández-Flores F, Pérez D, Garcés-Ortiz M. Frequency of supernumerary teeth in Mexican population. *Med Oral Patol Oral Cir Bucal*. 2004;9:407-9; 403-6.
15. Esenlik E, Sayin MO, Atilla AO, Ozen T, Altun C, Başak F. Supernumerary teeth in a Turkish population. *Am J Orthod Dentofacial Orthop*. 2009;136:848-52.
16. Bodin I, Julin P, Thomsson M. Hyperodontia. I. Frequency and distribution of supernumerary teeth among 21,609 patients. *Dentomaxillofac Radiol*. 1978;7:15-7.
17. Gardiner JH. Supernumerary teeth. *Dent Pract*. 1961;12:63-73.
18. King NM, Lee AM, Wan PK. Multiple supernumerary premolars: their occurrence in three patients. *Aust Dent J*. 1993;38:11-6.
19. Breckon JJ, Jones SP. Late forming supernumeraries in the mandibular premolar region. *Br J Orthod*. 1991;18:329-31.

## Conflict of Interest

All authors disclose any financial or personal relationship with other people or organisations that might have inappropriately influenced the present work.