

Journal section: Oral Surgery
Publication Types: Research

doi:10.4317/medoral.17066
<http://dx.doi.org/doi:10.4317/medoral.17066>

Immediate temporary restoration of single-tooth implants: Prospective clinical study

Luis-Antonio Aguirre-Zorzano ¹, Carlos Rodríguez-Andrés ², Ruth Estefanía-Fresco ³, Aitziber Fernández-Jiménez ³

¹ Degree in Medicine and Surgery. PhD in Medicine. Professor of Periodontology at the University of the Basque Country – Euskal Herriko Unibertsitatea

² Degree in Medicine and Surgery. PhD in Medicine. Professor of Preventive Medicine and Public Health at the University of the Basque Country – Euskal Herriko Unibertsitatea

³ Degree in Dentistry. Post-graduate student of Periodontology at the University of the Basque Country – Euskal Herriko Unibertsitatea

Correspondence:
Licenciado Poza, 23, 1º,
48011 Bilbao (Bizkaia)
laazperio@euskalnet.net

Aguirre-Zorzano LA, Rodríguez-Andrés C, Estefanía-Fresco R, Fernández-Jiménez A. Immediate temporary restoration of single-tooth implants: Prospective clinical study. Med Oral Patol Oral Cir Bucal. 2011 Sep 1;16 (6):e794-9.
<http://www.medicinaoral.com/medoralfree01/v16i6/medoralv16i6p794.pdf>

Received: 20/04/2010
Accepted: 26/08/2010

Article Number: 17066 <http://www.medicinaoral.com/>
© Medicina Oral S. L. C.I.F. B 96689336 - pISSN 1698-4447 - eISSN: 1698-6946
eMail: medicina@medicinaoral.com

Indexed in:

Science Citation Index Expanded
Journal Citation Reports
Index Medicus, MEDLINE, PubMed
Scopus, Embase and Emcare
Índice Médico Español

Abstract

Purpose: The goal of this study is to assess the survival, marginal bone loss and complications around single-tooth implants on which immediate provisionalization was carried out.

Patients and Methods: 78 implants were placed in 57 patients: 56 after extraction and 22 in healed sockets. Immediately after surgery provisional crowns were delivered without contacts in both centric and excursive jaw movements. The final crowns were inserted between 3 to 6 months later. During the study there were 3 x-rays taken per patient. The marginal bone loss was measured and complications were recorded. The statistical analysis of the data was carried out with the STATA 10[®] software.

Results: The mean duration of the study was 92 weeks. Survival rate was 98.7% (1 failure out of 78 implants). The mean mesial bone loss was 0.2±0.4 mm and the mean distal bone loss was 0.2±0.4 mm. No statistically significant differences were found between immediate or delayed implants. 67 implants showed a bone loss less than 1 mm, and 36 did not show any bone loss at all.

The main complications were the uncementing of the crowns (11 crowns), the presence of cement remnants (10 crowns) and the development of apical lesions around implants (6 implants).

Conclusion: With the limitations of this study, it can be concluded by saying that immediate restoration with single-tooth implants and provisional crowns may be considered as a predictable technique.

Key words: Single-tooth implants, post-extraction implants, immediate provisionalization, bone loss, implant based aesthetics.

Introduction

The loss of a single tooth, mainly in the aesthetic zone, and its replacement by implants has been a challenge in recent decades. There have been two main hurdles to overcome: the final aesthetic result and the long waiting periods required by conventional implant protocols.

In the early days of implant dentistry, encapsulation by fibrous connective tissue was reported when implants were immediately loaded, while a period of stress-free healing would allow for direct bone-to-implant contact: osseointegration (1,2). Therefore the recommended waiting time, according to the original Brånemark protocol, was at least three months in the mandible and six months in the maxilla (3).

However, during the past three decades, technological developments and continuous clinical research have provided us with improved protocols in an attempt to meet the expectations of a shorter treatment period, improved aesthetics and more convenience for the patient (4,5).

In order to satisfy the demand, modified immediate or early loading protocols have been designed and a concept of immediate function has emerged that includes the achievement of an immediate aesthetic result with or without immediate loading (6).

“Immediate loading” has been defined as that situation where the superstructure is connected to implants within a period not longer than 72 hours after surgery and where there is occlusion with the teeth of the opposite jaw (7). However, the terms “non-functional immediate loading”, “immediate restoration” or “immediate provisionalization” are used when the prosthesis is placed on implants at some point within the first 72 hours without full occlusal contact with the teeth of the opposite jaw (8).

One-stage surgical procedures and immediate loading of implants at the time of their placement have shown promising clinical results. Immediate loading procedures have been implemented successfully for the rehabilitation of edentulous mandibles, and results were even better when implants were splinted (9).

Nonetheless, theoretically, the immediate loading of non-splinted single-tooth implants, essentially in the

maxilla, could be related to an increased failure rate since they could undergo noxious forces that might give rise to micro-movements jeopardizing their osseointegration (10).

Keeping the provisional restoration out of occlusion has to do with the idea of controlling the load on a single tooth (10). Several studies have reported a high success rate on single-tooth implants placed post-extraction which received an immediate provisional crown (11,12).

The goal of this prospective clinical study was to assess the survival rate and bone changes around Astra Tech® (Astra Tech Dental, Möndal, Sweden) single-tooth implants placed following the system’s protocol and on which immediate provisional restoration with previously manufactured crowns was carried out.

Patients and Methods

This study was designed as a prospective clinical study (Fig. 1). A total of 78 Astra Tech® (Astra Tech Dental, Möndal, Sweden) single-tooth implants were placed in 57 patients who required the replacement of one tooth, between January 2004 and December 2007. All the cases were treated by the same surgeon at a private periodontal clinic.

The inclusion criteria for the patients were: a) enough bone height so that it would be possible to place implants of at least 11 mm in length, b) the tooth to be replaced should be located in the region between the second pre-molars, c) a minimum insertion torque for the implant of 30 N/cm², at the time of the surgery.

The exclusion criteria were: a) the presence of an active infection around the tooth to be extracted, b) the impossibility of achieving the required primary stability, or c) a medical record advising against the procedure.

Surgical procedure

All the patients were explored clinically and x-rayed and informed about the procedure they were about to undergo. They were asked to sign an informed consent form. Surgical guides were prepared to set up the proper position of the implants.

Once local anaesthesia had been performed on the patient, there were two different situations: the first one

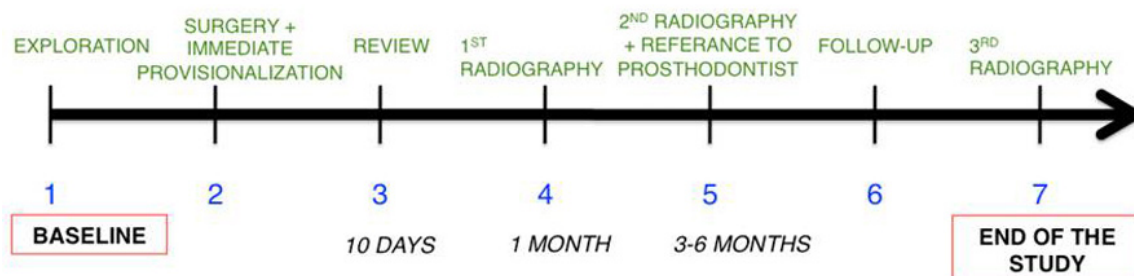


Fig. 1. Chronogram showing the study design.

where the tooth was extracted and immediately replaced by an implant (II) and the second one where the extraction had already been performed and the socket was already healed (DI). In the former (II), luxation of the tooth was carried out with a syndesmotome and subsequently, and very carefully, the tooth was extracted with a forceps, trying at all times to preserve the integrity of the socket walls and not injure them. If a buccal plate defect were found after the extraction, a small full thickness flap was raised.

In those cases where the socket was already healed (ID), a full thickness flap was raised in order to get to the bone crest. In either case, the procedure used to prepare the bone site for the implants was carried out following the implant system protocol (Astra Tech Dental, Möndal, Sweden).

A connective tissue graft was made or the principle of Guided Bone Regeneration (GBR) was implemented in those cases where it was thought that this might improve the final aesthetic result or the lasting stability of the achieved aesthetic outcome.

Once implant placement had been completed, prosthetic abutments were placed (Direct Abutment™, Astra Tech Dental), and over these a previously manufactured polycarboxylate crown (Direct Crowns, Svenska Dental Instrument, Upplands Väsby, Sweden) was relined by means of a self-curing resin (Tab 2000® Kerr Europe AG, Basel, Switzerland). Once the resin was cured, the restoration was finely adjusted extra-orally on an abutment replica using a fluid composite (Tetric Evoflow, Ivoclar Vivadent AG, Schaan, Liechtenstein). The restoration was then cemented (Fleck's, Mizzy, Inc. Clifton Forge, VA24422, U.S.A.) and the occlusion checked, paying special attention to leaving it free from load in centric occlusion and in excursive movements.

Antibiotics (amoxicillin 500 mg, three times a day, for 7 days), and analgesics (ibuprofen 600 mg, three times a day, for 2-4 days) were prescribed. Patients were asked to use a mouth rinse with 0.12% chlorhexidine digluconate (three times a day, for 6 weeks) and they were also asked to avoid "excessive loading" on that area.

Patients were then seen: 1) ten days after the procedure, 2) one month later, when the first x-ray was taken (Xr_1), and 3) 3-6 months later, when the second x-ray was taken (Xr_2), after which they were referred to their usual dentist for the final crown. Each patient went through several follow-up appointments and a last x-ray was taken (Xr_3) at the end of the study (Fig. 3b).

X-ray analysis

The x-rays were scanned and magnified x 7 to be subsequently analyzed by the Dental Studio NX 9.0 programme (Nemotec, Madrid, Spain). In each of the three x-rays the distance in millimetres was measured between the implant shoulder and the most coronal bone-to-implant contact. For each implant and for each x-ray,

two measurements of that distance were taken, a mesial and a distal one.

Statistical Analysis

Two random response variables were created with the following names: "mesial bone loss" and "distal bone loss", as the difference between the distal and the mesial distances found on the x-rays taken at one month (Xr_1) and at the end of the patient's follow up (Xr_3). The random variable of "mean bone loss" was also estimated, as the sum of both the mesial and distal bone loss for each implant divided by two. In addition, and for each individual implant, the type of placement was recorded (immediate or delayed) as well as any complication that arose during the entire follow-up. The statistical analysis of the data was carried out with the STATA 10® software, which implements the appropriate procedures (Student's T test) to check the hypothesis that the mean bone loss is the same regardless of the placement technique being used (immediate or delayed). The potential associations between bone loss and the patients' gender or age were also studied, as well as with the complications during the follow-up.

Results

78 Astra Tech® (Astra Tech Dental, Möndal, Sweden) implants were placed in 56 patients; 19 males and 37 females with a mean age of 48.5 years (26 to 78 years old). 49 implants were placed in women and the remaining 29 in men.

The most frequently used implant diameter was 4.5 mm (n=42), followed by 3.5 mm (n=28). 7 implants were 4.0 mm in diameter and 1 implant 5 mm in diameter. As far as length is concerned, 50 implants were 15 mm long, 17 implants were 13 mm, 10 implants were 17 mm and 1 implant was 11 mm long.

Of the 78 implants placed, 56 were placed immediately after tooth extraction (II) and the other 22 implants were placed in healed sockets (DI).

Due to aesthetic reasons, in 3 implants connective tissue grafts were carried out at the time of their placement (Fig. 2) and in 5 other implants GBR was implemented because they either showed bone dehiscence that did not compromise their stability or survival, or the buccal bone plate was very thin.

Seven cases were excluded from the final analysis. One immediate implant placed in the upper premolar region had an infectious process five weeks after its installation and it was removed (survival rate 98.7%). After the implant site was healed another implant was placed using a delayed loading protocol. One implant was excluded because the prosthodontist decided to include it in a fixed partial restoration with adjacent teeth. Another 4 implants were excluded because the patients didn't attend the last follow-up visit. Likewise, another DI implant was excluded from the analysis due to a peri-

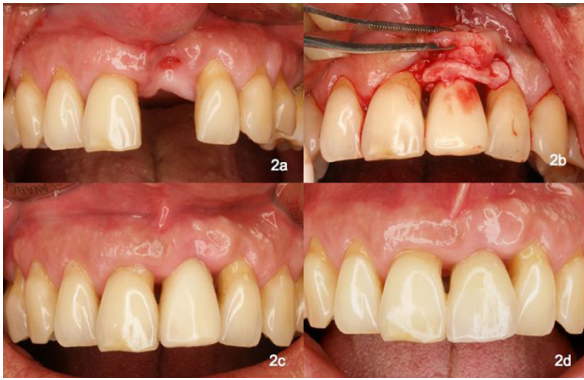

Fig. 2a. Absence of an upper central incisor in a patient with aggressive periodontitis, after full periodontal treatment.
2b. Connective tissue graft placed over the fixture and the provisional crown.
2c. Final healing before referring the patient to the prosthodontist. Note the shorter length of the provisional crown to avoid occlusal contacts.
2d. Final clinical picture. Note the health of the gingival tissues.

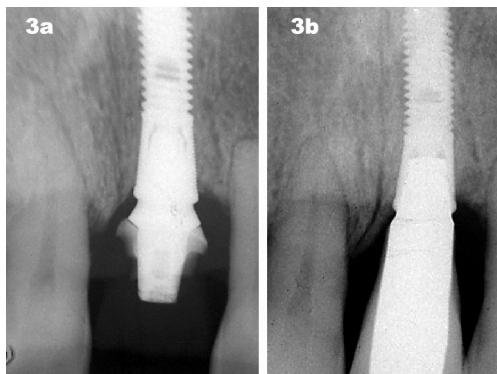


Fig. 3a. X-ray at the time of placing the fixture and the provisional crown.
3b. X-ray at the end of the study, 18 months later. Note the bone level stability.

implant abscess induced by the big quantity of remnant subgingival cement not removed by the prosthodontist when cementing the final crown. It caused an important bone loss (“outlier”) of 4.5 mm. In consequence, the final number of fixations where the bone changes were analysed, was 71 (n=71).

The mean duration of the implant follow-up was similar in both placement procedures: 93.3 weeks for those placed immediately after teeth extraction (II) and 91.4 weeks for those placed in healed sockets (DI). In 18 implants the follow-up was longer than 133 weeks.

Mesial bone loss was 0.19 ± 0.41 mm [0.17- -2.5] and distal 0.20 ± 0.42 mm [0.21- -2.5]. According to the Student’s T test, the differences found between immediate implants and delayed implants (mesial $p = 0.61$; distal $p = 0.32$) were not statistically significant. 67 implants showed a bone loss lower than 1 mm and 36 implants in this study did not show bone loss at all (Fig. 3). In some cases a small bone gain could even be seen.

The mean bone loss was 0.1 mm in delayed implants (DI) while in immediate implants (II) the mean bone loss was 0.4 mm. The difference found in mean bone loss was not statistically significant according to Student’s T test. In figure 4 a box diagram is shown with the distribution of mean bone loss according to the different kinds of placement (immediate or delayed) used for this study.

The bone loss median was 0.1 mm for both immediate and delayed implants. A slightly higher variability was found in mean bone loss for immediate implants, though the comparison between standard deviations was not statistically significant.

The most frequent complications were the crown decementation, involving 11 crowns in 10 patients and the

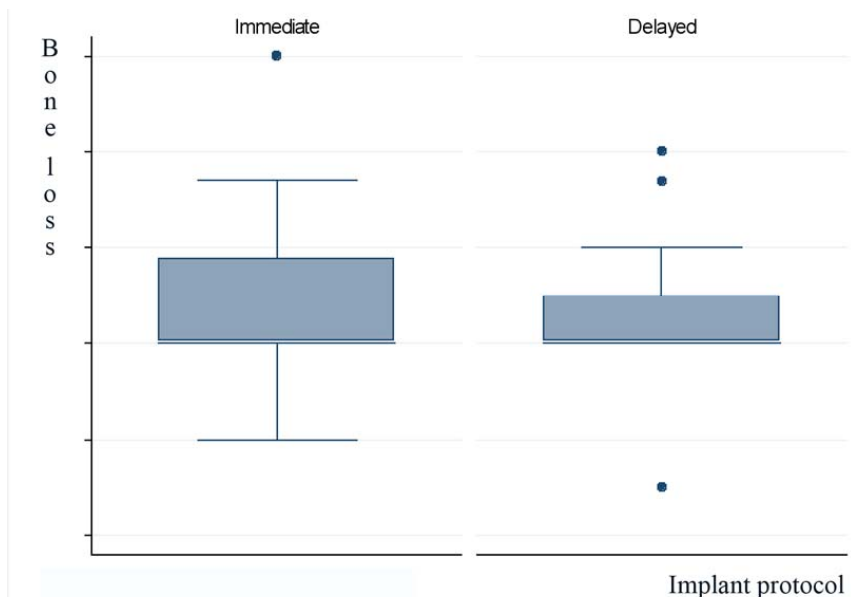


Fig. 4. Box diagram showing the distribution of bone loss according to the time of implant placement.

presence of small cement remnants in the peri-implant tissues around 10 crowns in 9 patients. The crowns were removed and the cement excess was eliminated as well, and no further complications arose.

In addition, periapical lesions were found around 6 implants in 3 patients that were solved with antibiotic (amoxicillin and metronidazole three times a day, for 7 days) and anti-inflammatory therapy (Ibuprofen 600 mg, three times a day, while the inflammation lasted), and a slight gingival margin recession that was corrected by changing the provisional crown contour.

No statistically significant differences were found in mean bone loss between those implants that showed some kind of complication and those that did not.

Discussion

From a clinical point of view, replacing an anterior tooth with an implant and a provisional crown provides clear benefits: the immediate solution of an aesthetic problem that some patients perceive as a tragedy. Nonetheless, performing this kind of procedure has been controversial in the literature.

Published reports on immediate restoration with single-tooth implants show survival rates ranging from 82.4 to 100% (4,13,14). Caution must be used when reading the results published by some of these authors because, in many reports, the number of studied cases is very low (13,14). Concerning the poor results in the Chaushu et al. report (4), the reason may lie in the kind of implants they used: these being impacted implants. Worth mentioning is the study by Norton (15) where, using the same implant system (Astra Tech®), they found a 96.4% survival rate for single-tooth implants after 2.5 years, and this result is not far from the 98.7% found in the present study.

This study has to do with immediate provisionalization and although most published reports are similar to the current study, there is no scientific evidence supporting the need to avoid such contacts from the beginning of loading. This is the case in reports such as Lindeboom's et al. (10), where they compared both situations and did not find any statistically significant differences in terms of implant stability, or the radiographic results of the evaluation at one year. The authors accounted for this fact on the basis of the potential tongue pressure and the perioral muscles on immediately provisionalized but not loaded implants. In any case, it seems prudent to control loading during the early stages of osseointegration since what patients actually want is to have their teeth as soon as possible in order to solve the aesthetic problem.

As to the bone loss found around immediately restored single-tooth implants, in general the values found by different authors range between 0.2 and 0.5 to 1 mm during the first year (10,13,14), so that bone loss is smaller than that considered normal in the early days

of implant dentistry (16). Comparing again the present study in terms of similarities to Norton's report (15), the bone loss in the current study was slightly lower, 0.2 mm versus the bone loss in his study of 0.4 mm, although the mean follow-up was longer in the first one. It is worth mentioning as well that bone loss, just like the survival rate, was similar to that reported for single-tooth implants using the same system and placed according to a conventional delayed protocol (17).

On the other hand, all the patients in the present study had previously periodontally-treated disease. Despite this fact and the implementation of an immediate provisionalization protocol, the bone loss found was lower than the one reported in the literature for this kind of patients in conventional protocols (18).

In addition, several authors state that some bone gain could be found in some of their implants. Such is the case of Kan et al. (13), where the range was between -1.4 and +0.5 mm. In this work, the range was between -2.5 and +0.2 mm and in three implants some bone gain was found by the end of the study.

In the present study two different situations occurred: implants placed immediately after extraction and implants placed in healed sockets. The results did not show any statistically significant differences concerning bone loss. Recently, Palatella et al. (19) studied this variable and did not find any statistically significant differences between both groups, neither in terms of bone loss nor in terms of the aesthetic parameters they studied. Conversely, Chaushu et al. (4) found an 82.4% survival rate in immediate implants versus 100% in implants placed in healed areas.

Concerning this point, it is worth mentioning that all those cases that showed periapical lesions around implants occurred in post-extraction implants (II). It has been suggested that the aetiology of such lesions is multi-factorial (20) and that the reason could be the existence of residual microorganisms in the socket or in the neighbouring teeth (20,21), bone over-heating generated during long implant placement (21,22), bone microfractures due to micro-movements (overloading) (21), as well as residual bone cavities left when placing implants shorter than the surgical site (23). Several treatments have been suggested for this type of lesions: antibiotic therapy (24), implant detoxification (24,25), performing implant apicoectomy (20), or removing the involved implant (26). In this study, all cases were solved with antibiotic therapy and anti-inflammatory agents and none of these implants were lost.

Another frequent complication in the present study was the presence of small cement remnants around implant-supported crowns, both the provisional and the final ones. Such remnants may have negative implications for the peri-implant tissue, causing swollen and unattractive gingival tissues (27) and in some cases implant loss (28).

It is worth remembering that, in tissues around implants, supracrestal connective fibres do not become attached to the implant and therefore would not provide the required protection when too much cement is left in the sulcus around the implant (29). As previously mentioned, in the current study, when the cement remnants were removed, all the cases evolved without major complications.

Note that such cement remnants were not diagnosed when the control x-rays were analyzed by the naked eye but rather when they were scanned and magnified in order to measure the potential bone loss. This seems to suggest the need to magnify the control x-rays for the cement-retained implant-supported restorations.

Within the limits of this study, it can be concluded by saying that replacing anterior teeth with Astra Tech® single-tooth implants, together with provisional crowns in non-occlusion, may be considered as a predictable technique. Also, no difference was found in this work in terms of bone loss between implants placed immediately after extraction and implants placed in healed areas. Only the periapical lesions showed differences with regard to the complications in the protocols of immediate or deferred placement.

Further studies with larger patient samples and longer follow-up periods should be conducted so that these results can be confirmed and it can be stated that such results may last for a long time.

References

References with links to Crossref- DOI

- Brunski JB, Moccia AF Jr, Pollack SR, Korostoff E, Trachtenberg DI. The influence of functional use of endosseous dental implants on the tissue-implant interface. I. Histological aspects. *J Dent Res*. 1979;58:1953-69.
- Brunski JB, Moccia AF Jr, Pollack SR, Korostoff E, Trachtenberg DI. The influence of functional use of endosseous dental implants on the tissue-implant interface. II. Clinical aspects. *J Dent Res*. 1979;58:1970-80.
- Brånemark PI, Hansson BO, Adell R, Breine U, Lindström J, Hallén O, et al. Osseointegrated implants in the treatment of the edentulous jaw. Experience from a 10-year period. *Scand J Plast Reconstr Surg Suppl*. 1977;16:1-132.
- Chausu G, Chausu S, Tzohar A, Dayan D. Immediate loading of single-tooth implants: immediate versus non-immediate implantation. A clinical report. *Int J Oral Maxillofac Implants*. 2001;16:267-72.
- Cornelini R, Cangini F, Covani U, Wilson TG Jr. Immediate restoration of implants placed into fresh extraction sockets for single-tooth replacement: a prospective clinical study. *Int J Periodontics Restorative Dent*. 2005;25:439-47.
- Testori T, Bianchi F, Del Fabbro M, Szmukler-Moncler S, Francetti L, Weinstein RL. Immediate non-occlusal loading vs. early loading in partially edentulous patients. *Pract Proceed Aesthet Dent*. 2003;15:787-94.
- Cochran DL, Morton D, Weber HP. Consensus statements and recommended clinical procedures regarding loading protocols for endosseous dental implants. *Int J Oral Maxillofac Implants*. 2004;19 Suppl:109-13.
- Nkenke E, Fenner M. Indications for immediate loading of implants and implant success. *Clin Oral Implants Res*. 2006;17 Suppl 2:19-34.
- Randow K, Ericsson I, Nilner K, Petersson A, Glantz PO. Immediate functional loading of Brånemark dental implants. An 18-month clinical follow-up study. *Clin Oral Implants Res*. 1999;10:8-15.
- Lindeboom JA, Frenken JW, Dubois L, Frank M, Abbink I, Kroon FH. Immediate loading versus immediate provisionalization of maxillary single-tooth replacements: a prospective randomized study with BioComp implants. *J Oral Maxillofac Surg*. 2006;64:936-42.
- Kan JY, Rungcharassaeng K. Immediate placement and provisionalization of maxillary anterior single implants: a surgical and prosthodontic rationale. *Pract Periodontics Aesthet Dent*. 2000;12:817-24.
- Hui E, Chow J, Li D, Liu J, Wat P, Law H. Immediate provisional for single-tooth implant replacement with Brånemark system: preliminary report. *Clin Implant Dent Relat Res*. 2001;3:79-86.
- Kan JY, Rungcharassaeng K, Lozada J. Immediate placement and provisionalization of maxillary anterior single implants: 1-year prospective study. *Int J Oral Maxillofac Implants*. 2003;18:31-9.
- Lorenzoni M, Pertl C, Zhang K, Wimmer G, Wegscheider WA. Immediate loading of single-tooth implants in the anterior maxilla. Preliminary results after one year. *Clin Oral Implants Res*. 2003;14:180-7.
- Norton MR. A short-term clinical evaluation of immediately restored maxillary TiOblast single-tooth implants. *Int J Oral Maxillofac Implants*. 2004;19:274-81.
- Jemt T, Pettersson P. A 3-year follow-up study on single implant treatment. *J Dent*. 1993;21:203-8.
- Wennström JL, Ekstubb A, Gröndahl K, Karlsson S, Lindhe J. Implant-supported single-tooth restorations: a 5-year prospective study. *J Clin Periodontol*. 2005;32:567-74.
- Mengel R, Flores-de-Jacoby L. Implants in patients treated for generalized aggressive and chronic periodontitis: a 3-year prospective longitudinal study. *J Periodontol*. 2005;76:534-43.
- Palattella P, Torsello F, Cordaro L. Two-year prospective clinical comparison of immediate replacement vs. immediate restoration of single tooth in the esthetic zone. *Clin Oral Implants Res*. 2008;19:1148-53.
- Balshi SF, Wolfinger GJ, Balshi TJ. A retrospective evaluation of a treatment protocol for dental implant periapical lesions: long-term results of 39 implant apicoectomies. *Int J Oral Maxillofac Implants*. 2007;22:267-72.
- Shaffer MD, Juruaz DA, Haggerty PC. The effect of periradicular endodontic pathosis on the apical region of adjacent implants. *Oral Surg Oral Med Oral Pathol Oral Radiol Endod*. 1998;86:578-81.
- Eriksson RA, Adell R. Temperatures during drilling for the placement of implants using the osseointegration technique. *J Oral Maxillofac Surg*. 1986;44:4-7.
- Reiser GM, Nevins M. The implant periapical lesion: etiology, prevention, and treatment. *Compend Contin Educ Dent*. 1995;16:768,770,772.
- Ayango L, Sheridan PJ. Development and treatment of retrograde peri-implantitis involving a site with a history of failed endodontic and apicoectomy procedures: a series of reports. *Int J Oral Maxillofac Implants*. 2001;16:412-7.
- Zablotsky MH, Diedrich DL, Meffert RM. Detoxification of endotoxin-contaminated titanium and hydroxyapatite-coated surfaces utilizing various chemotherapeutic and mechanical modalities. *Implant Dent*. 1992;1:154-8.
- Scarano A, Di Domizio P, Petrone G, Iezzi G, Piattelli A. Implant periapical lesion: a clinical and histologic case report. *J Oral Implantol*. 2000;26:109-13.
- Agar JR, Cameron SM, Hughbanks JC, Parker MH. Cement removal from restorations luted to titanium abutments with simulated subgingival margins. *J Prosthet Dent*. 1997;78:43-7.
- Gapski R, Neugeboren N, Pomeranz AZ, Reissner MW. Endosseous implant failure influenced by crown cementation: a clinical case report. *Int J Oral Maxillofac Implants*. 2008;23:943-6.
- Cochran DL, Hermann JS, Schenk RK, Higginbottom FL, Buser D. Biologic width around titanium implants. A histometric analysis of the implant-to-gingival junction around unloaded and loaded nonsubmerged implants in the canine mandible. *J Periodontol*. 1997;68:186-98.