

Caso Clínico // Case Report

REMOTE SPINAL EPIDURAL HEMATOMA AFTER SPINAL ANESTHESIA FOR CAESAREAN SECTION

MARIA JL VILAÇA¹, ANA FAÍSCO¹, EDUARDO BEIRÃO REIS¹, GIL ALEXANDRE¹, MARIA DO CARMO TEIXEIRA²

Palavras-chave:

- Anestesia Obstétrica;
- Cesariana;
- Hematoma Epidural Espinhal

Resumo

Nas últimas décadas tem havido uma generalização do uso do bloqueio do neuroeixo (BNE) em obstetrícia. As complicações associadas ao BNE oscilam entre o incomodativo e o extremamente grave e potencialmente letal. O Hematoma epidural espinhal (HES) é uma das complicações mais graves. Uma grávida de 29 anos de idade em termo de gestação, ASA II, foi proposta para cesariana após progressão inadequada do trabalho de parto. Foi realizado um bloqueio subaracnoideu e a cirurgia decorreu sem intercorrências. A parturiente recuperou do bloqueio motor e sensitivo mas, doze horas após o procedimento, começou a referir parestesia nos membros inferiores que progrediram para paraplegia posteriormente. A ressonância magnética realizada revelou um HES localizado a nível dorsal, de D7 a D9, localização remota do local de punção com agulha. A doente foi transferida para realização de laminectomia e evacuação do hematoma. Um ano após o evento permanecia com deficit neurológicos.

REMOTE SPINAL EPIDURAL HEMATOMA AFTER CESAREAN SECTION

MARIA JL VILAÇA¹, ANA FAÍSCO¹, EDUARDO BEIRÃO REIS¹, GIL ALEXANDRE¹, MARIA DO CARMO TEIXEIRA²

Keywords:

- Anesthesia, Obstetrical;
- Cesarean Section;
- Hematoma, Epidural, Spinal

Abstract

In the last few decades there has been a widespread of the use of central neuraxial blockages (CNB) in obstetric patients. The complications from the CNB range from the bothersome to the crippling and life-threatening. Spinal epidural hematoma (SEH) is one of such severe complications. A 29-year-old pregnant woman at term, ASA II, was proposed for a caesarean section after inadequate progression of labour. Spinal anesthesia was administered and surgery was uneventful. The patient recovered from the motor and sensitive blockage but, twelve hours after the procedure, she started complaining of paresthesia over the lower limbs that progressed to paraplegia. An urgent magnetic resonance revealed a dorsally located SEH extending from D7 to D9, remote from the site of needle puncture. The patient was transferred and an emergency laminectomy and evacuation of the hematoma was conducted. One year after the event she remained with neurological deficits.

Data de submissão - 3 de maio, 2016

Data de aceitação - 21 de julho, 2016

¹ Interno Formação específica Anestesiologia, Serviço de Anestesiologia, Reanimação e Terapêutica da Dor, Hospital Professor Doutor Fernando Fonseca, Amadora, Portugal

² Assistente Hospitalar Anestesiologia, Serviço de Anestesiologia, Reanimação e Terapêutica da Dor, Hospital Professor Doutor Fernando Fonseca, Amadora, Portugal

INTRODUCTION

In the last few decades there has been a widespread of the use of central neuraxial blockages (CNB) in obstetric patients. CNB provide excellent analgesia and, when needed, anesthesia during childbirth with a well-known safety. The complications from the CNB have a low incidence but can range from

the bothersome to the crippling and life threatening.¹

The occurrence of a spinal epidural hematoma (SEH) causing spinal cord compression is one of such severe complications and, although fortunately rare, is a potentially cause of long-term neurological disability. Spinal cord hematoma can result from several unusual disease processes,^{1,2} including vascular malformations of the spinal cord, clotting disorders, vasculitis, spinal cord tumors, abscess, syringomyelia, and unknown etiologies. Traumatic events to the spinal epidural arteriovenous plexus, such as spinal or epidural anesthesia, are also a possible cause of spinal cord hematoma. When SEH occurs in the setting of an epidural or spinal block, the hematoma usually develops at the level of puncture or as high as the catheter was inserted. Remote hematomas from the level of puncture/ catheter placement of a CNB have been previously described^{2,3} but, to our knowledge, only one case² had a similar presentation in an obstetric setting.

CASE REPORT

A 29-year-old pregnant woman at term, ASA II, was admitted to our hospital in labour (phase 1). She did not have any known disease, her vitals were normal, and her only medical history was a previous caesarean section under neuroaxial block and two previous miscarriages, without any anesthetic or surgical complications described. Due to inadequate progression of labour she was proposed for an urgent caesarean section. After confirmation of a recent platelet count, aPTT, PT and INR all in normal range, spinal anesthesia (SA) was performed in the seated position, L3-L4 interspace identified by anatomical references, with a 27 G spinal needle. The first puncture was bloody but after repositioning clear liquor was obtained and 8 mg of 0.5% heavy bupivacaine with 2.5 mcg of sufentanil (total volume 2.1 mL) was injected. Surgery was uneventful and there was only a slight hypotension period at the beginning of the surgery. The patient recovered from the motor block the next hours after surgery and was discharged to the nursery. Twelve hours after the procedure she started complaining of back pain, numbness and muscle weakness of lower limbs, referring a slight recover of the force and sensibility a few minutes after. Due to this, and suspecting of a CNB complication, an urgent lumbar MRI was request, covering the level of the puncture, which was considered normal. During the MRI the patient complained again of a worsening of the symptoms with hemiplegia and diminished sensibility of the lower limbs again with partial recovery. Over the next 4 h after the first MRI there was a progression of the symptoms to paraplegia, with loss of tactile, thermal sensation and preservation of vibratory sensation. A new MRI, now thoraco-lumbar, was done revealing a dorsally located SEH extending from D7 to D9 (Fig. 1).

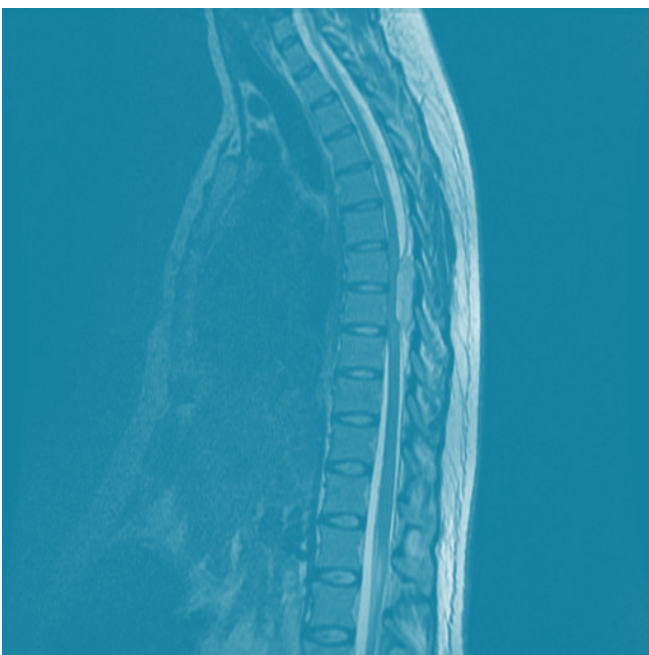


Figure 1 – Thoracolumbar MRI

Laboratory investigation showed a normal hemogram, with a normal platelet count, and an aPTT, PT and INR in a normal range. There was no history of antiplatelet or anticoagulant intake, neither the take of other drugs other than the normal pregnancy supplements (iron and folic acid). There was no history of bleeding manifestations.

The patient was transferred to a neurosurgical center and an emergency laminectomy was conducted under general anesthesia with identification of a vascular lesion possibly related to an arteriovenous malformation. The cloth was subjected to histopathological examination that reinforce the possibility of an arteriovenous malformation (AVM). Due to the emergency of the situation no angiography was done before the surgery, only after, and came back negative for AVM.

Although the lesion was decompressed in less than 12 h after the first neurological symptoms, the neurological recovery was not complete and one year after the event the patient remained with neurological deficits.

DISCUSSION

The exact incidence of SEH is difficult to estimate but studies suggest to be less than 1 in 150,000 epidurals and even rarer following spinal anesthesia (1 in 220,000) in patients with no added morbidity.^{1,2} In most cases SEH has an acute clinical onset, leading to immediate and severe neurological deficits, and only rarely has it a chronic, progressive clinical course, simulating a herniated disc or a spinal tumor.

Overall, hematomas related to neuraxial anesthesia seem to be less frequent in the obstetrical compared with the elderly surgical population. The few obstetric cases that have been reported are mainly associated with coagulopathy due to large obstetric hemorrhage, preeclampsia, or HELLP syndrome.

The presence of occult arteriovenous malformation is a rare cause of SEH. AVM in the spinal cord can exist without any symptoms or complications through the life of a person, so what may have put our patient at risk and created the conditions for the rupture?

Direct trauma do the AVM itself by regional anesthesia can lead to hemorrhage and hematoma formation. As an extensive AVM generates high flow rates and enlarges the epidural veins, disruption can result in a significant epidural hematoma.

Instead of direct trauma, loss of CSF from the dural sac can change spinal cord anatomy and place AVM under tension leading to its rupture. However, with a 27 gauge bevel needle, the leak of CSF would probably not be enough to create a significant tension on a spinal lesion causing it to rupture.

Because the epidural veins are valveless, increase in the intra-abdominal pressure, as occurs with labour, is theoretically transmitted to these venous plexus with stretching and tearing that can result in a spontaneous bleeding. The sudden decompression of the inferior vena cava after delivery of the fetus during the caesarean section could also contribute to a pressure alteration in the venous plexus, with a sudden decompression and subsequent rupture of the AVM.

There are reports of SEH in patients with normal coagulation profiles after SA with 27G needle. Generally the patients developed SEH adjacent to the level at which lumbar puncture was performed, but SEH occurring many levels above the lumbar puncture as in our case was previously described.^{2,3} Considering a relationship between the anesthesia and the development of the SEH our patient showed a very unusual phenomenon – a spinal lucid interval, as it was first described by Madhuguri et al² – in sense that she recovered from the motor block after the SA, and only hours after developed sensory symptoms and subsequently paraplegia when the epidural hematoma reached the critical size to cause spinal compression.

We also cannot exclude the possibility that a spontaneous rupture occurred without any relationship with the labour or the anesthetic technique. Although rare, spontaneous SEH were previously described during pregnancy and post-partum period in healthy women.⁴

Magnetic resonance imaging is currently considered the modality of choice for diagnosis of spinal epidural hematoma. Immediate surgical decompression by laminectomy is considered in cases with acute compromise of cord function but a conservative management is possible in certain patients with minimal neurological deficits and spontaneous resolution of the hematoma. The rapidity of surgical intervention, when needed, correlates with the neurological outcome. Studies have demonstrated recovery was significantly improved when a symptomatic hematoma is decompressed within 36 hours in patients with complete deficits, with some authors suggesting even faster intervention within 6 hours, and within 48 hours in patients with incomplete deficits. The neurological outcome after surgery is also significantly better in patients with preoperative incomplete neurological deficits than in patients with preoperative complete neurological deficits.⁵

A delay in our diagnosis occurred due to the fact that a lumbar hematoma was first considered at the level of the puncture. Should a full spinal scan done at the first investigation and maybe the deficits would have been more reversible.

CONCLUSION

Although a rare condition, a spinal epidural hematoma can occur in the absence of any known risk factors.

A high suspicion should be maintained and new neurological symptoms should be promptly investigated. A whole spine MRI may be preferred since the hematoma can develop far from the level where the CNB was conducted.

Conflicts of interest: The authors have no conflicts of interest to declare.

Financing Support: This work has not received any contribution, grant or scholarship.

Confidentiality of data: The authors declare that they have followed the protocols of their work center on the publi-

cation of data from patients.

Protection of human and animal subjects: The authors declare that the procedures followed were in accordance with the regulations of the relevant clinical research ethics committee and with those of the Code of Ethics of the World Medical Association (Declaration of Helsinki).

REFERENCES:

1. Moen V, Irestedt L. Neurological complications following central neuraxial blockades in obstetrics. *Curr Opin Anaesthesiol.* 2008; 21:275-80.
2. Madhugiri SV, Singh M, Sasidharan G, Kumar VR. Remote spinal epidural haematoma after spinal anaesthesia presenting with a 'spinal lucid interval'. *BMJ Case Reports.* 2012: bcr2012007258.
3. Makris A, Gkliatis M, Diakomi M, Karmanioliou I, Mela A. Delayed spinal epidural hematoma following spinal anesthesia, far from needle puncture site. *Spinal Cord.* 2014; 52: S14 – S6
4. Badar F, Kirmani S, Rashid M, Azfar SF, Yasmeen S, Ullah E. Spontaneous spinal epidural hematoma during pregnancy: a rare obstetric emergency. *Emerg Radiol.* 2011; 18: 443-36.
5. Giugno A, Basile L, Maugeri R, Iacopino DG. Emergency surgery in a patient with large spontaneous spinal epidural hematoma determining excellent neurological recovery: a review of the literature. *Spinal Cord.* 2014; 52: S22-S4