

Editorial

Macrocirculation versus microcirculation and digital ulcers in systemic sclerosis patients

Macro-microcirculation and scleroderma

In their research published in this issue, Lüders *et al.* aimed to compare, in SSc patients, the presence of hand-altered arteries with nailfold capillaroscopy (NC) and with clinical signs of digital ischaemia, that is, digital ulcers (DUs) or pitting scars (PSs).

The authors confirmed the already reported presence of structural changes in the arteries at the level of the wrists and hands, as detected by colour Doppler ultrasonography (CDUS) [1, 2]. These changes are highly frequent in SSc patients but absent in healthy subjects or patients with primary RP [3]. Furthermore, ulnar artery occlusions have already been identified as a risk factor for new DUs [2].

Lüders *et al.* [1] analysed 79 SSc patients and showed that almost 40% of all assessable arteries, almost 50% of all proper palmar digital arteries (PPDAs), but only 15% of proximal arteries showed narrowed or occluded lumens [1]. More specifically, fingerwise analyses presented significant coincidence of pathological CDUS findings and DUs/PSs (Fig. 1B). Interestingly, patients with a non-SSc-specific or early NC pattern tended to have a non-significant lower number of pathological arteries in CDUS than patients with active or late NC patterns.

However and unexpectedly, no significant difference was observed in the number of altered arteries (macrocirculation) in patients with the late NC pattern (microcirculation), compared with the other patterns (non-SSc, early and active patterns) put together. In addition and unexpectedly, there was no link between reduced capillary density (<7/mm at NC), present in 79% of assessable fingers, and the existence of pathological vessels in CDUS.

Therefore, the dissociation observed in the present study seems partially in contrast with a very recent multicentre study, which analysed 468 SSc patients, and defined the mean number of capillaries per millimetre, together with the number of DUs, as well as signs of severe digital ischaemia at baseline, as significant risk factors for the development of new DUs during a 6-month follow-up [4]. These results confirmed a previous study that offered a simple prognostic index for digital trophic lesions for daily use in SSc clinics, limited to the mean score of capillary loss [5].

At this point, one should expect that the microvascular counterpart, namely the presence of the late NC pattern indicating the most advanced nailfold capillary loss in SSc, should be coincident since almost 50% of all the PPDAs showed narrowed or occluded lumens, as a consequence of the advanced peripheral macrovessel intimal fibrosis [6].

However, assuming a link between macrovasculopathy and microvasculopathy in SSc, the problems arising from the controversies related to the morphological vascular aspects might be better clarified if integrated by functional analysis, through quantification of the blood flow changes in both peripheral arteries and capillaries.

Rosato *et al.* [7] analysed SSc patients and healthy matched controls, in order to assess both morphology and blood flow of PPDAs by CDUS, skin blood perfusion, digital artery pulsatility and the relationships with NC patterns. Interestingly, CDUS was found to be pathological in 69% of SSc patients and in none of the healthy controls. SSc patients with low microvascular damage (the early NC pattern) showed a normal morphology of PPDAs, but the blood flow was found to be reduced and vascular resistance was found to be increased.

At this stage, the mean perfusion evaluated by laser Doppler perfusion imaging and the digital artery pulsatility was found to be reduced. Finally, the US hand changes appeared associated with microvascular damage progression (active and late NC patterns), while, in contrast, the PPDA blood flow progressively decreased.

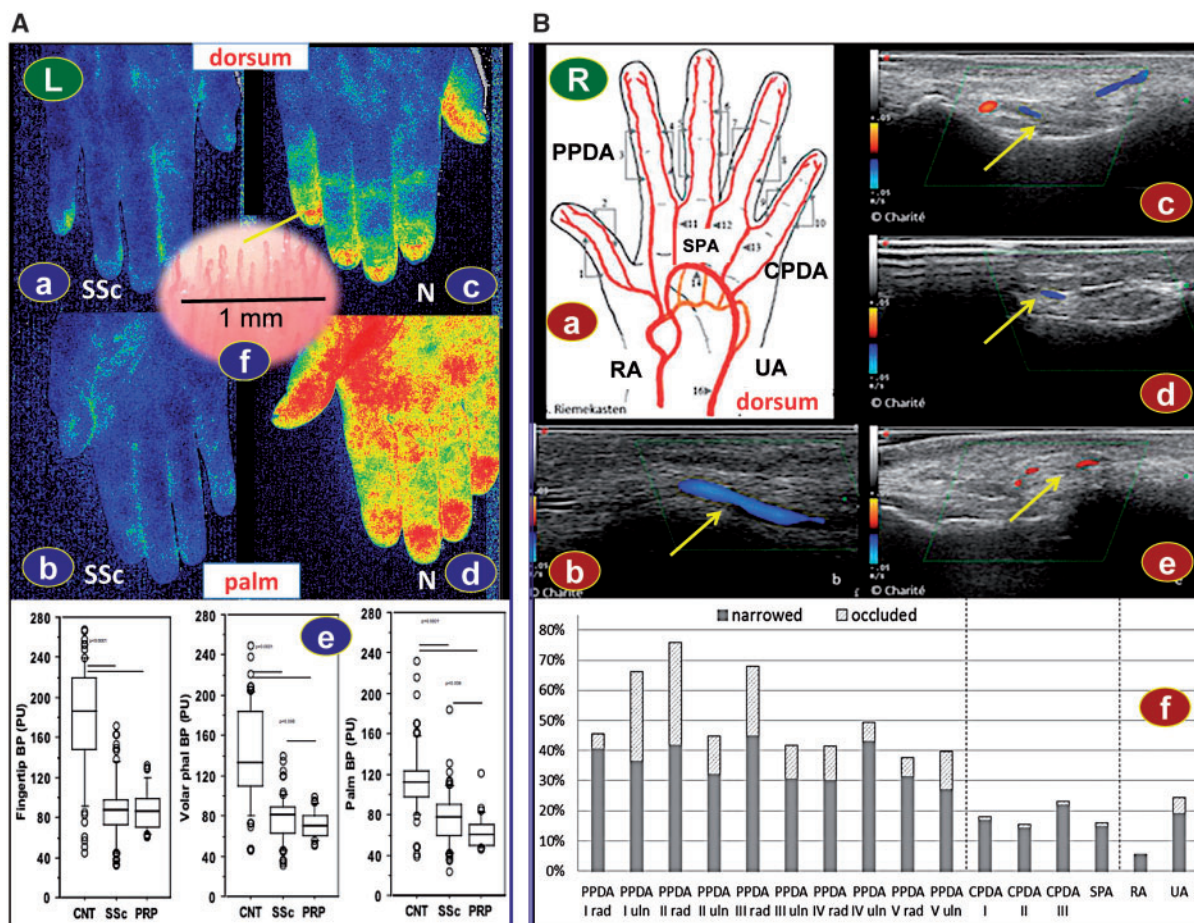
Interestingly, we described the simultaneous presence of macrovascular and microvascular impairment in patients with SSc, but by evaluating the endothelium-dependent flow-mediated dilation at the level of the brachial artery, and the impairment was already present in patients with early NC pattern vs controls [8].

Rosato *et al.* did not observe any association between DU history and US findings. On the contrary, in the study of Lüders *et al.* DUs/PSs were predominantly found in the same fingers that presented the highest percentages of pathological—and especially occluded—arteries. The findings are partially in contrast to the observations made by Rosato *et al.* since they are just as possible the result of a reduced comparability due to differences in arterial grading and the additional fingerwise evaluation made by Lüders *et al.*

Unfortunately, in the study of Lüders *et al.* no healthy controls were considered, and no quantitative analysis was added, but just a qualitative and semi-quantitative evaluation (percentage) of the hand macrovasculature alterations. In addition, in Rosato *et al.*'s study patients were untreated at the time of the examinations, whereas in Lüders *et al.*'s trial, all concomitant treatments were allowed.

As a matter of fact, Lüders *et al.* admitted as one of their study limitations to have included different therapies and

Fig. 1 Macro and micro blood flow analysis in the hands of SSc patients



(Aa–d) Laser speckle contrast analysis (LASCA) of an SSc patient at the level of dorsum (a) and palm (b) of the hand, same as in a healthy control (N) (c and d). (e) Quantification of the blood flow (BP) as obtained by the LASCA, and expressed in perfusion units (PU) at the level of fingertip, dorsum and palm of healthy controls (CNT), SSc and primary Raynaud’s patients (PRP). (f) Capillaroscopic picture showing the capillary density count (1 mm) at the level of the nailfold bed of a healthy CT (Source: Personal files). (B) Colour Doppler ultrasonography of the arteries of fingers, palms and wrists; modified from Lüders *et al.* [1], Detection of severe digital vasculopathy in SSc by colour Doppler sonography is associated with digital ulcers, with permission from Oxford University Press. (a) The arteries examined: PPDA, CPDA, SPAr, RA and UA. The probe was placed at every point marked by little black arrowhead. (b) Screenshot of a normal PPDA with a broad and homogeneous colour signal. (c–e) Yellow arrows show pathological vessels with narrowed arteries (c), occluded arteries (d) and collateral flow (e). (f) Graph showing percentage of pathological vessels (narrowed or occluded) per artery for the right hand of an SSc patient in the study of Lüders *et al.* CPDA: common palmar digital arteries; PPDA: proper palmar digital arteries; RA: radial artery; SPAr: superficial palmar arch; UA: ulnar artery.

their possible effect on vascular performance, although they tried to minimize the effects of vasoactive therapies by a warm water bath prior to CDUS. In our own experience, by analysing the microcirculation of SSc patients by laser speckle contrast analysis, which is a validated fast and safe method of detection (60 s), even quantifiable in perfusion units, we found significant correlations with the progressive microvascular damage, as assessed by the NC patterns and the microangiopathy evolution score) [9] (Fig. 1A).

Lüders *et al.* concluded that based on their recent experience, CDUS could complement vascular diagnostics in SSc, and even suggested a shorter examination

protocol (15 min), focusing just on the right hand’s digits II–V (PPDA) that revealed similar results to the more time consuming CDUS on full-fingers analysis (10 fingers, 45 min), including a very low positive predictive value, (AUC = 0.751; sensitivity: 93.0%; specificity: 43.5%).

In conclusion, Lüders *et al.* confirmed that CDUS offers a complementary tool to assess structural macrovasculopathy in SSc. However, the CDUS analysis at the level of the hands seems time consuming and does not offer a real quantitative evaluation of the blood flow, and a wide variability exists within patients. In addition, by considering the discussed biases, the value of the isolated hand

macrovascular CDUS analysis for prediction of the development of DUs in SSc seems preliminary and need further surveys (supplementary Table S1, available at *Rheumatology* Online). Therefore analysis of the microcirculation in SSc patients (both qualitative and quantitative) seems the most convenient and tested clinical approach for the prediction of DUs and for the selection/follow-up of therapeutic methods [10]. However, the merging of these safe diagnostic tools, testing both the macro- and micro-circulatory status, would contribute to an optimization of the analysis of the vascular conditions in SSc patients.

Acknowledgement

We thank Sara De Gregorio for helping in the preparation of the figure.

Funding: No specific funding was received from any bodies in the public, commercial or not-for-profit sectors to carry out the work described in this manuscript.

Disclosure statement: The authors have declared no conflicts of interest.

Maurizio Cutolo¹, Barbara Ruaro¹ and Vanessa Smith²

¹Research Laboratory and Academic Division of Clinical Rheumatology, Department of Internal Medicine, IRCCS San Martino, University of Genova, Italy and ²Department of Rheumatology, Ghent University Hospital, Ghent University, Ghent, Belgium

Revised version accepted 20 March 2017

Correspondence to: Maurizio Cutolo, Research Laboratory and Academic Division of Clinical Rheumatology, Department of Internal Medicine, IRCCS San Martino AOU, University of Genova, Viale Benedetto XV, no. 6 - 16132 Genova, Italy. E-mail: mcutolo@unige.it

Supplementary data

Supplementary data are available at *Rheumatology* Online.

References

- 1 Lüders S, Friedrich S, Ohrndorf S *et al.* Detection of severe digital vasculopathy in systemic sclerosis by colour Doppler sonography is associated with digital ulcers. *Rheumatology* 2017;56:1865–73.
- 2 Frerix M, Stegbauer J, Dragun D, Kreuter A, Weiner SM. Ulnar artery occlusion is predictive of digital ulcers in SSc: a duplex sonography study. *Rheumatology* 2012;51:735–42.
- 3 Schmidt WA, Krause A, Schicke B, Wernicke D. Color Doppler ultrasonography of hand and finger arteries to differentiate primary from secondary forms of Raynaud's phenomenon. *J Rheumatol* 2008;35:1591–8.
- 4 Cutolo M, Herrick AL, Distler O *et al.* Nailfold videocapillaroscopic and other clinical risk factors for digital ulcers in systemic sclerosis: a multicenter, prospective cohort study. *Arthritis Rheumatol* 2016;68:2527–39.
- 5 Smith V, De Keyser F, Pizzorni C *et al.* Nailfold capillaroscopy for day-to-day clinical use: construction of a simple scoring modality as a clinical prognostic index for digital trophic lesions. *Ann Rheum Dis* 2011;70:180–3.
- 6 Cutolo M, Pizzorni C, Secchi ME, Sulli A. Capillaroscopy. *Best Pract Res Clin Rheumatol* 2008;22:1093–108.
- 7 Rosato E, Gigante A, Barbano B *et al.* In systemic sclerosis macrovascular damage of hands digital arteries correlates with microvascular damage. *Microvasc Res* 2011;82:410–5.
- 8 Rollando D, Bezante GP, Sulli A *et al.* Brachial artery endothelial-dependent flow-mediated dilation identifies early-stage endothelial dysfunction in systemic sclerosis and correlates with nailfold microvascular impairment. *J Rheumatol* 2010;37:1168–73.
- 9 Ruaro B, Sulli A, Alessandri E *et al.* Laser speckle contrast analysis: a new method to evaluate peripheral blood perfusion in systemic sclerosis patients. *Ann Rheum Dis* 2014;73:1181–5.
- 10 Cutolo M, Sulli A. Therapy. Optimized treatment algorithms for digital vasculopathy in SSc. *Nat Rev Rheumatol* 2015;11:569–71.