



# Sonography of Scrotal Wall Lesions and Correlation With Other Modalities

Raffaella Conzi, MD, Maria Beatrice Damasio, MD, Michele Bertolotto, MD , Mustafa Secil, MD, Subramaniyan Ramanathan, MD, Laurence Rocher, MD, Faye Cuthbert, MD, Jonathan Richenberg, MD, Lorenzo E. Derchi, MD , on Behalf of the Scrotal Imaging Group of the European Society of Urogenital Radiology

The scrotal wall may be involved in a variety of pathologic processes. Such lesions may arise primarily from the layers of the scrotum or may be due to a process arising from scrotal content. Imaging is not needed in most cases, but it may be useful for making such differentiations and for evaluation of possible involvement of the testes and epididymides in cases of primary wall abnormalities. This pictorial essay will show the imaging findings observed in a variety of pathologic conditions affecting the scrotal wall, both common and unusual ones, with an emphasis on clinically relevant findings and features that lead to a specific diagnosis.

**Key Words**—genitourinary ultrasound; scrotal wall; diffuse thickening; scrotal wall; focal thickening; scrotal wall; sonographic anatomy

The scrotal wall may be involved in a large variety of pathologic processes, both primary and secondary, which may be difficult to differentiate on a physical examination alone. In fact, lesions arising primarily from the layers of the scrotum may mimic testicular or epididymal diseases clinically, whereas, vice-versa, scrotal wall involvement may be the result of a process arising from the scrotal content.

Imaging is not needed in most patients with a lesion of the scrotal wall, and when requested, it usually aims at evaluation of possible underlying involvement of testes and epididymides. However, scrotal wall lesions may be severe in some cases, and accurate identification of their nature and extent is necessary for proper management.<sup>1-3</sup>

Color Doppler sonography is usually the imaging modality of choice in patients with scrotal conditions and is frequently able to establish a firm diagnosis. Computed tomography (CT) or magnetic resonance imaging (MRI) may be indicated in complex cases and may be specifically needed in some of them.

This presentation will discuss the imaging findings observed in a variety of pathologic conditions affecting the scrotal wall, both common and unusual ones, with emphasis to clinically relevant findings and features that lead to a specific diagnosis.

## Normal Anatomy of the Scrotal Wall

The scrotum is a musculocutaneous pouch that contains the testes, the epididymides, and part of the spermatic cord. It is divided into 2 cavities by the median raphe, which is visible on the skin surface as a

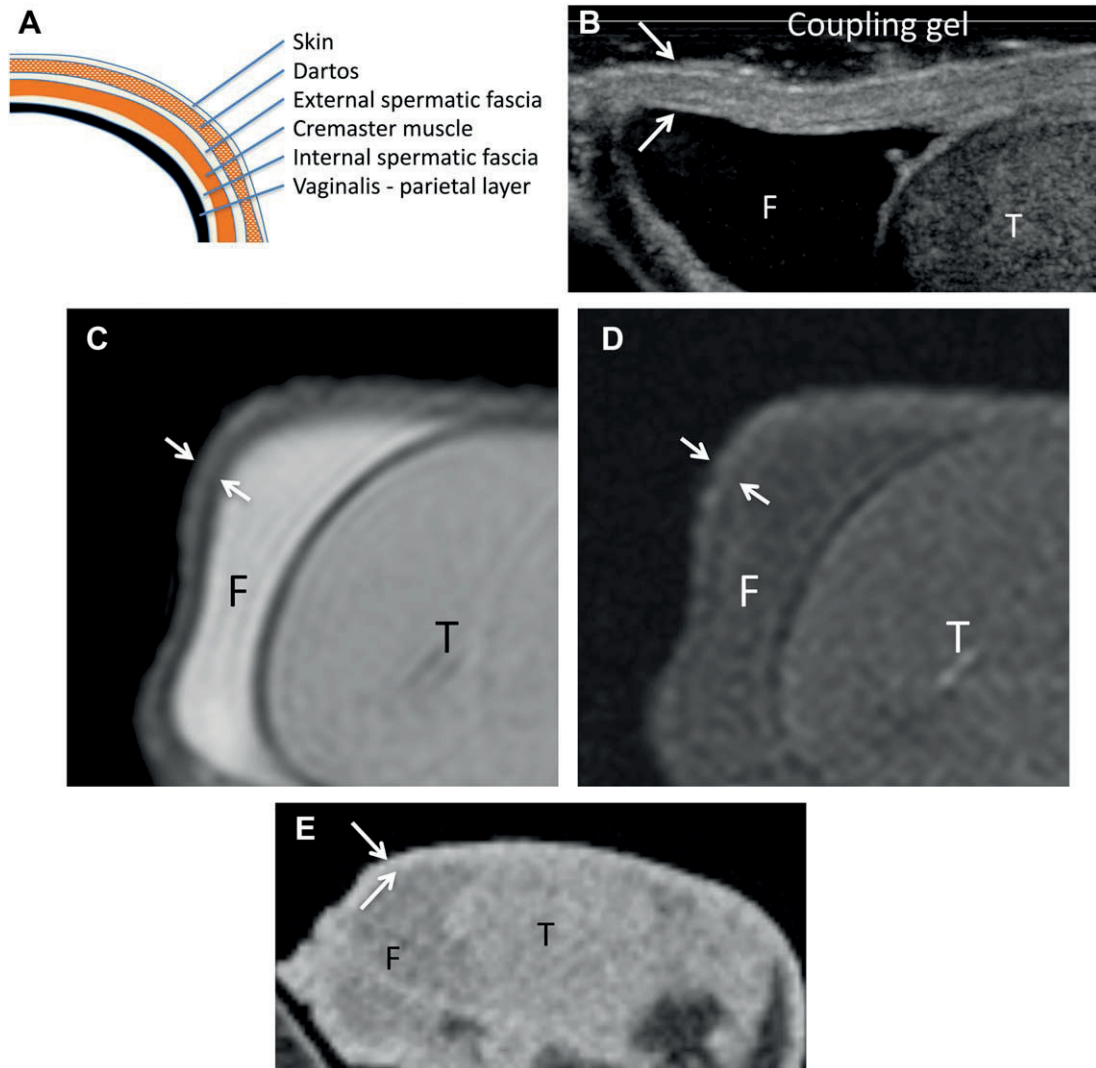
line extending from the anus along the perineum to the ventral surface of the penis.

The wall of the scrotum is composed (from superficial to deep) of skin, the superficial fascia, the dartos muscle, the external spermatic fascia, the cremasteric fascia, and the internal spermatic fascia. The internal surface of the cavities is outlined by the tunica vaginalis, a mesothelial layer originating from an outpouching of the peritoneum at about 8 weeks' gestation. During this evagination process, each of the superficial layers covering the processus vaginalis originates from fascial

extensions of the abdominal wall. The fascia transversalis becomes the internal spermatic fascia, the internal oblique muscle forms the cremasteric muscle; and the external oblique muscle gives rise to the external spermatic fascia. The dartos muscle and the scrotal skin are the most external coverings (Figure 1A).<sup>1,3,4</sup>

A poorly defined multilayered appearance can be seen when examining the scrotal wall with sonography (using high-frequency/high-resolution probes; Figure 1B), as well as on MRI examinations (Figure 1, C and

**Figure 1.** Normal anatomy of the scrotal wall (arrows). **A**, Diagram showing the anatomic stratification of the scrotal wall. **B**, Axial sonogram obtained with a high-frequency transducer (L17-5; Philips Healthcare, Eindhoven, the Netherlands) showing the multilayered appearance of the scrotal wall. Five layers of slightly different echogenicity are barely recognized, with the second and fourth (from inner to outer) relatively hypoechogenic. **C**, Axial T2-weighted image showing 2 apparent layers of the scrotal wall. **D**, Corresponding axial T1-weighted image showing no wall stratification. **E**, Computed tomogram showing no apparent layers. F indicates hydrocele; and T, testis.



D); on the contrary, the wall has a homogeneous appearance on CT (Figure 1E). A direct correlation with the anatomic layers of the wall, however, cannot be easily obtained. Small vessels can be sometimes recognized on MRI within the scrotal wall; they are usually not visible on sonography because of pressure on the surface from the ultrasound transducer.

It must be remembered that the lymphatic drainage routes of the scrotal wall go to the lymph nodes of the inguinal region. Then, nodal enlargement from scrotal

wall diseases occurs at this level and not at retroperitoneal nodes.

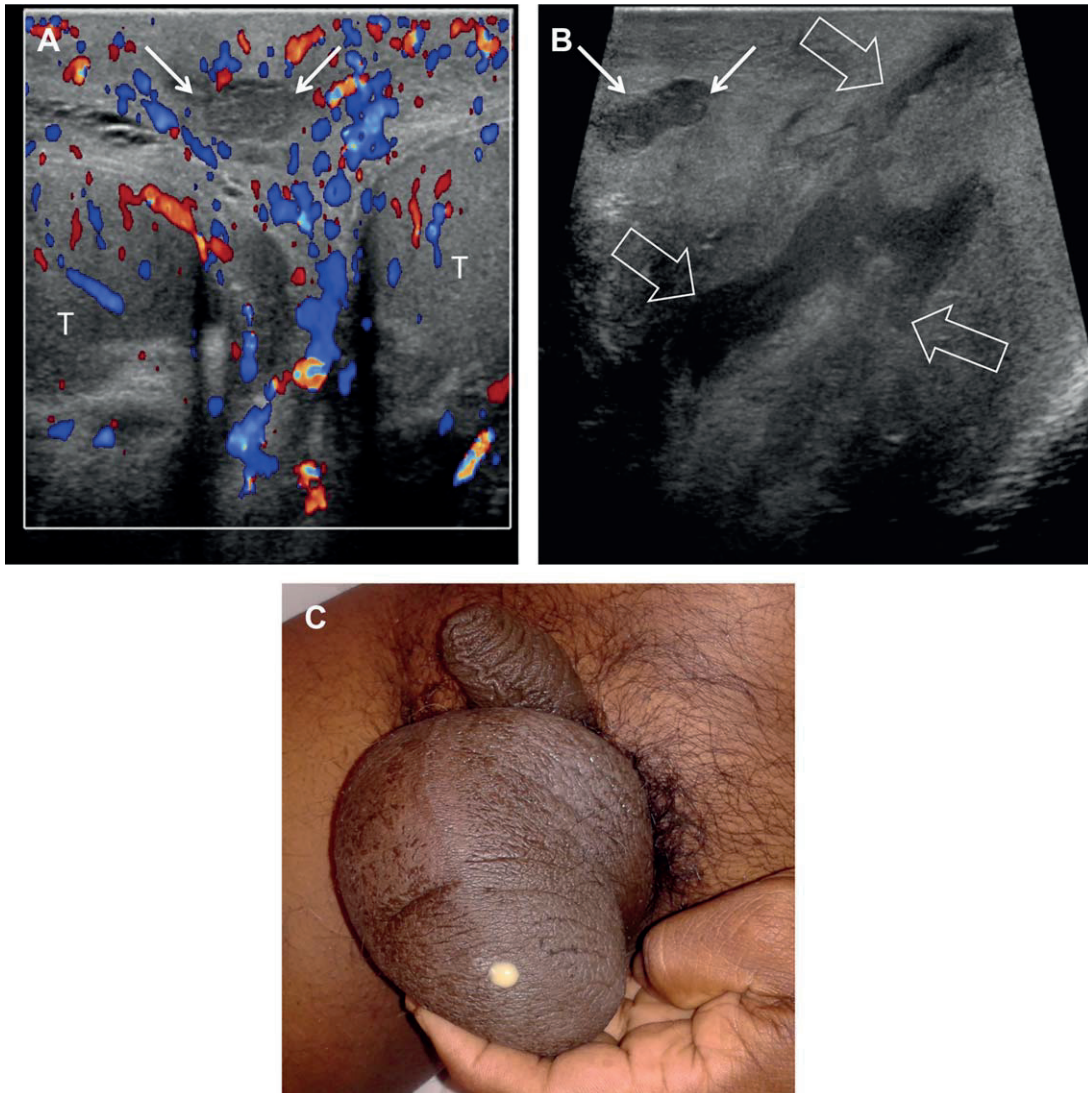
## Diffuse Thickening

### *Inflammation*

#### *Cellulitis*

Clinical diagnosis of cellulitis of the scrotal wall is usually straightforward, and imaging is rarely indicated. In severe

**Figure 2.** Scrotal wall cellulitis with abscess. **A**, Axial image showing diffuse thickening of the scrotal wall, which is hypervascularized on color Doppler imaging. A small rounded abscess (arrows) is seen, with low-level internal echoes. Both testes are normal. **B**, On a sagittal scan plane along the midline, a larger abscess is seen inferiorly to the small one (open arrows); it has irregular margins and a fistula draining to the skin surface. **C**, Pus exits through the fistula to the skin. T indicates testis.

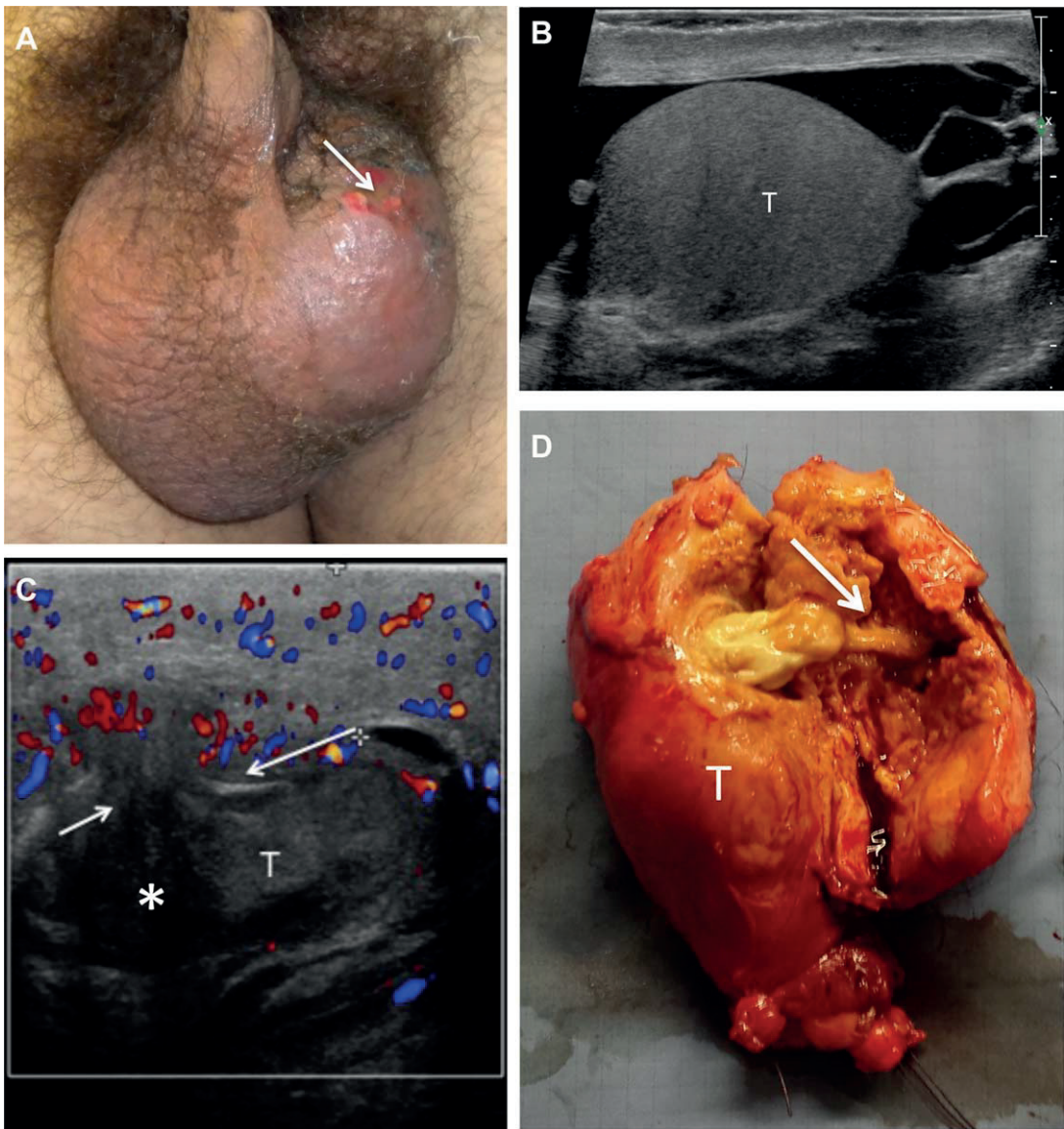


cases, however, patients may be referred for imaging investigations, in most cases with sonography, to exclude abscess formation and involvement of the scrotal content.

Patients with severe cellulitis present with pain, tenderness, thickening of the scrotal wall, and reddening of the skin surface; most commonly, they are obese,

diabetic, or immunocompromised.<sup>1</sup> On sonography, there is increased scrotal wall thickness, with markedly increased blood flow visible on color Doppler imaging. If an abscess develops, it is seen as an irregularly shaped area with low-level internal echoes surrounded by increased blood flow. The presence of a cutaneous drainage fistula can be recognized as an extension of the fluid

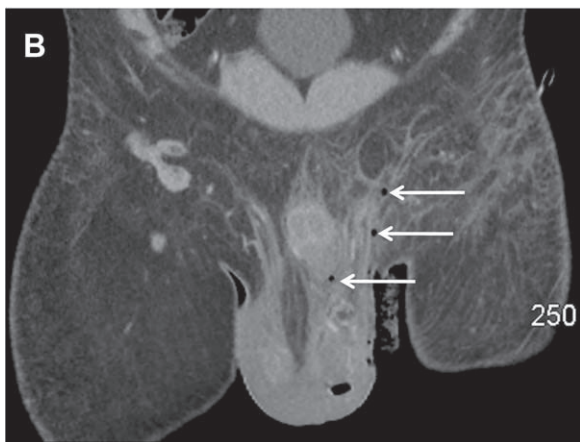
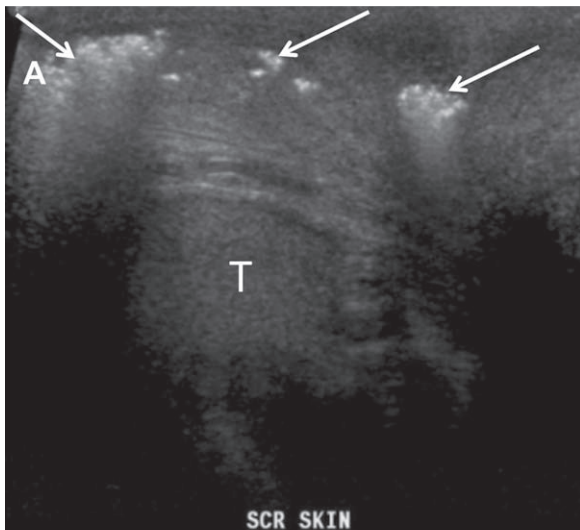
**Figure 3.** **A**, Scrotal wall abscess with cutaneous fistula (arrow). **B**, On the right side, there is septated hydrocele; the testis and scrotal wall are normal. **C**, The left testis is small and heterogeneous, with a hypoechoic abscess (asterisk) that extends anteriorly (arrows) into the scrotal wall. Diffuse thickening and hyperemia are associated. **D**, Surgical specimen showing the testis and adjacent wall layers. The arrow points to the fistula between the abscess cavity and the scrotal wall. T indicates testis.



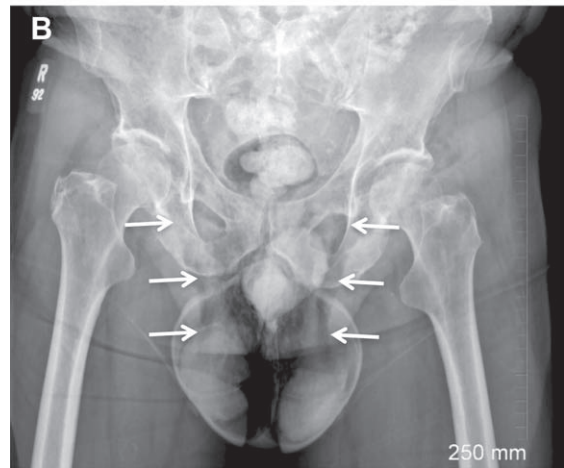

collection toward the skin (Figure 2). In equivocal cases, abscess formation and fistulas are best identified on contrast-enhanced sonography. Magnetic resonance imaging may be indicated in complex cases with widely spread inflammation. Also, a complicated furuncle of the scrotal skin can be the cause of cellulitis within the underlying and adjacent subcutaneous tissues.

Inflammation of the scrotal wall can also be caused by extension of an intrascrotal process. Mild inflammatory signs are commonly seen in patients with acute epididymitis as a slight thickening of the scrotal wall, with hyperemia on color Doppler imaging, adjacent to

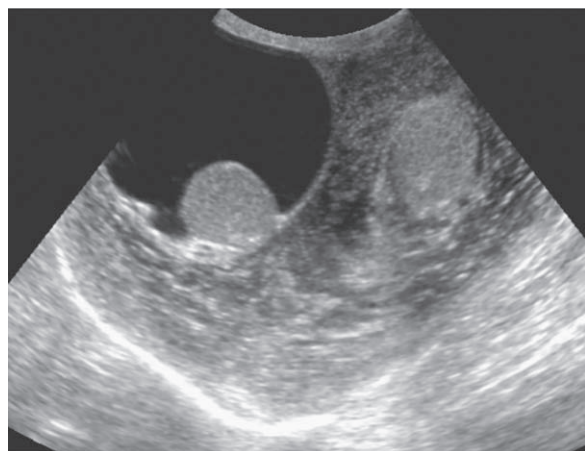
**Figure 4.** Fournier gangrene in 56-year-old diabetic patient with fever, scrotal erythema, tenderness, and crepitus on palpation. **A**, Longitudinal sonogram showing scrotal wall thickening and air bubbles (arrows) with reverberation artifacts. **B**, Computed tomogram confirming scrotal wall thickening, with gas in it, and showing additional air foci (arrows) in the left inguinal region. T indicates testis.



**Figure 5.** Air in the scrotal wall extending from subcutaneous emphysema of the abdominal wall after thoracic trauma. **A**, Sonogram showing multiple air foci (arrows) with dirty shadowing in the scrotal wall. **B**, Radiograph of the pelvis showing air tracking along the inguinal canal (arrows) into the scrotal wall.



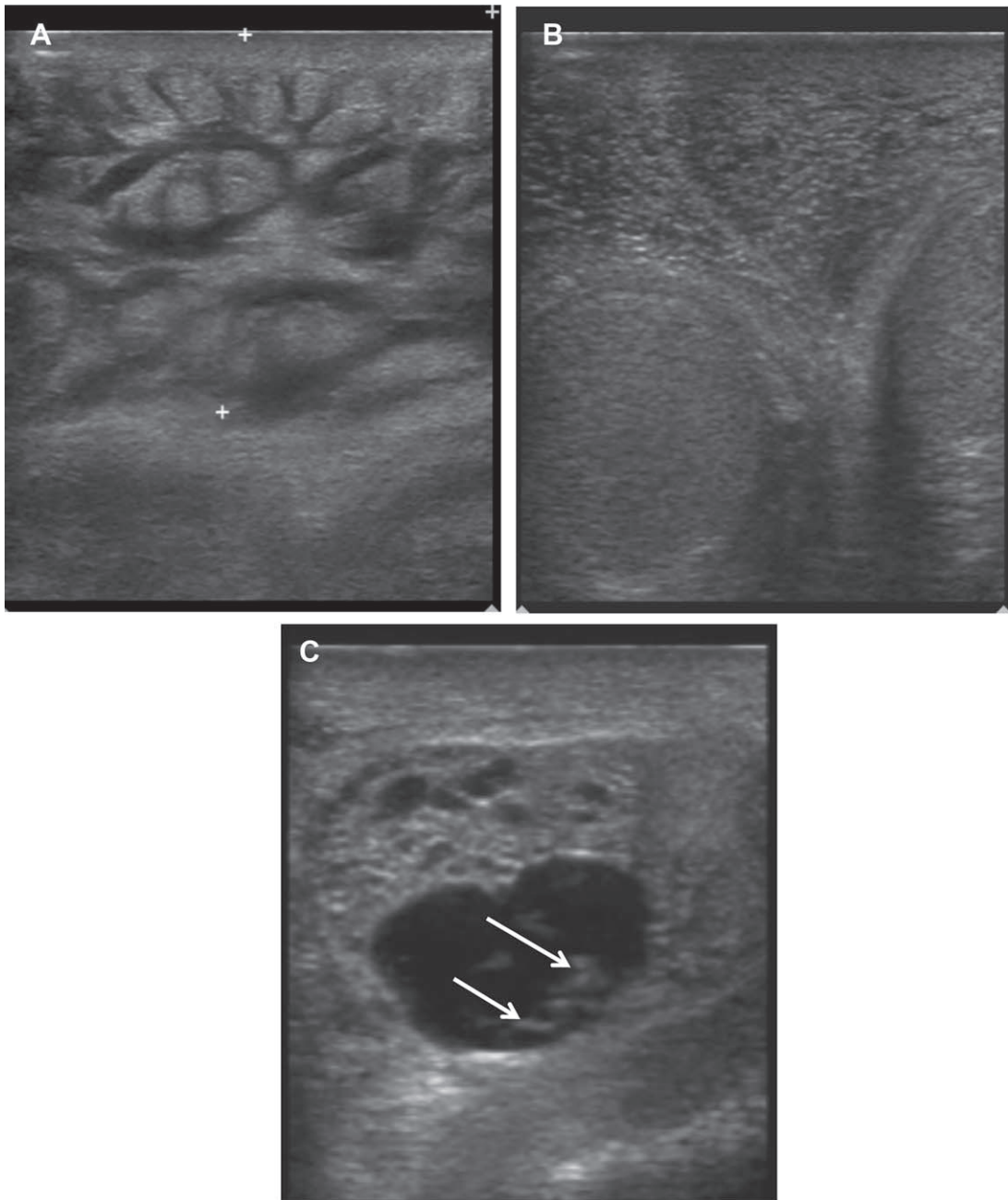
**Figure 6.** Chronic scrotal wall edema in a patient with congestive heart failure. The study was obtained with a 3.5-MHz transducer for a complete view of the whole scrotum. There was severe diffuse wall thickening (except at the anterior portion of the right hemiscrotum). Both testes were normal; right hydrocele was associated.



the inflamed portion of the epididymis. Less frequently, a severe intratesticular or epididymal inflammatory condition may directly extend into the scrotal wall (Figure

3). Such a condition is usually an ominous finding, and surgery, often with orchidectomy, is needed to treat the patient.<sup>5</sup>

**Figure 7.** Filariasis in a 2-year-old boy with left lower limb and scrotal edema. **A.** Axial image of the left thigh showing diffuse lymphedema of subcutaneous tissues. **B.** Axial image of the scrotum, along the midline, showing diffuse scrotal wall edema; both testes were normal. **C.** Sonogram of the left hemiscrotum showing cystic areas suggestive of dilated lymphatic channels, with multiple curvilinear structures (arrows), which, on real-time observation, had persistent twirling motion.



### *Fournier Gangrene*

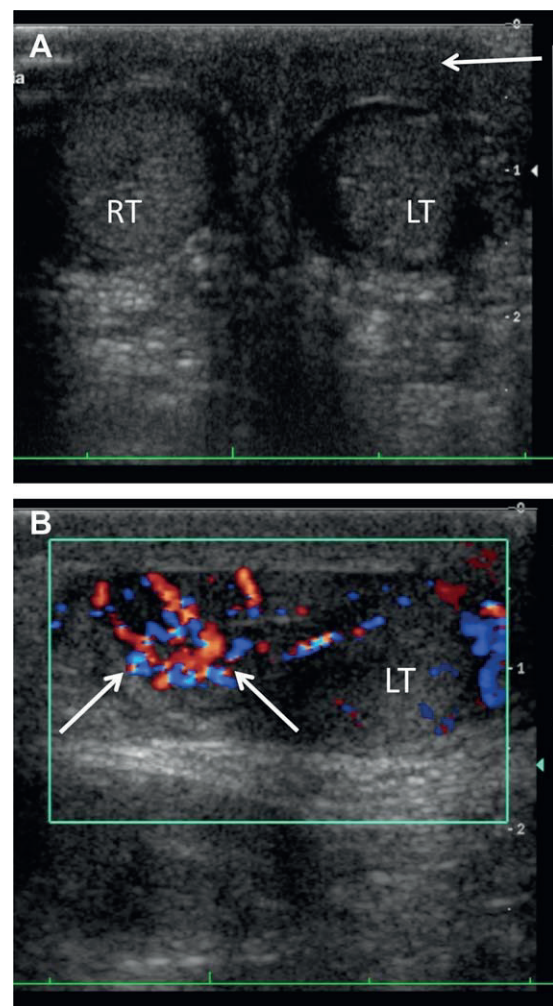
This condition is a polymicrobial necrotizing fasciitis of the perineum, the perianal region, and the scrotal wall that can be very aggressive and is potentially fatal. The most common sites of origin of the infection are anal fistulas and fissurations, and diabetes mellitus, alcohol abuse, and immunodeficiencies are well-known predisposing factors. The disease induces obliterative endarteritis, with subsequent cutaneous and subcutaneous vascular necrosis that spreads quite rapidly. The diagnosis of Fournier gangrene is commonly made on clinical grounds, based on scrotal swelling, pain, hyperemia, pruritus, fever, and crepitus on palpation. Then, imaging is rarely needed to confirm the diagnosis but may be necessary for this purpose in clinically ambiguous or questionable cases only. On sonography, the scrotal and perineal walls are thickened and may contain abscess cavities. The distinctive feature of Fournier gangrene, however, is the presence of gas within soft tissues; it appears as hyperechoic foci that cast a posterior “dirty” shadow due to reverberation artifacts (Figure 4).<sup>6</sup> It must be remembered, however, that although detectable in most patients with Fournier gangrene, gas in soft tissues is not always present. These rare cases may be quite difficult to diagnose with imaging. The testes and epididymides have a normal appearance and normal vascularization on color Doppler imaging, since the blood supply to the scrotal wall is different from that to the testis. Although sonography is able to indicate Fournier gangrene by showing the presence of gas within the soft tissues, CT is the imaging procedure of choice in these patients. It is needed to evaluate the full extent of the disease process, since it has the capability to accurately assess the presence of gas at any anatomic sites, to show the presence of fluid collections and abscesses, and to show spreading of the disease process out of the perineal region, thus guiding surgical debridement of infected tissues.<sup>7</sup> Rarely, however, gas within the scrotum may not be due to Fournier gangrene but to extension of post-traumatic subcutaneous emphysema of the abdominal wall to the scrotum along the inguinal canal. The clinical history and a lack of inflammatory signs at clinical examinations and laboratory tests may help in the differential diagnosis (Figure 5).

### *Scrotal Wall Edema*

Chronic scrotal wall edema, be it of venous or lymphatic origin, can be due to a large variety of causes. Among

them, cardiac failure, a fluid imbalance, and retroperitoneal lesions are the most common causes of venous edema. The etiology of lymphatic edema varies widely according to the geographic area. In regions where filariasis is endemic, it is the most common cause; in other areas, neoplastic infiltration of inguinal lymph nodes with impaired lymphatic drainage is the most frequent reason. Imaging shows diffuse thickening of the wall, usually with a laminated pattern (Figure 6). Increased flow is not visible on color Doppler imaging or after contrast agent administration. The appearance of the

**Figure 8.** Acute pain and swelling of the left hemiscrotum were noted in an 8-year-old boy with Schönlein-Henoch purpura. **A** and **B**, Sonograms showing increased thickness of the wall, mainly at the left hemiscrotum (arrow in **A**), and enlargement and hyperemia of the epididymis (arrows in **B**). The left testis was normal. LT indicates left testis; and RT, right testis.



epididymides and testes is normal in these patients, since their venous and lymphatic drainage routes are different from those of the scrotal wall.<sup>8</sup>

### *Scrotal Wall Filariasis*

In filariasis, the adult worms live within the lymphatic system of the infected patient. The lymphatic vessels dilate, and lymphedema of the limbs develops. Diffuse thickening of the scrotum from lymphedema is quite commonly associated in male patients, and sonography has the capability to show dilated lymphatic vessels within which the worms can be identified. Within the anechoic lymphatic channels, small linear echogenic structures with a persistent twirling motion, the “filarial dance” sign, are frequently observed on high-resolution sonography.<sup>9</sup> It is not clear whether these structures represent adult worms with active movements or microfilariae that move as a result of a streaming effect induced by the ultrasonic beam (Figure 7).<sup>10</sup> However, these findings, when observed in a proper clinical setting, are considered characteristic of filarial infection and also have been used to monitor patients receiving antiparasitic therapy. Absence of movements on follow-up examinations is taken as a positive response to therapy.<sup>9</sup>

### *Schönlein-Henoch Purpura*

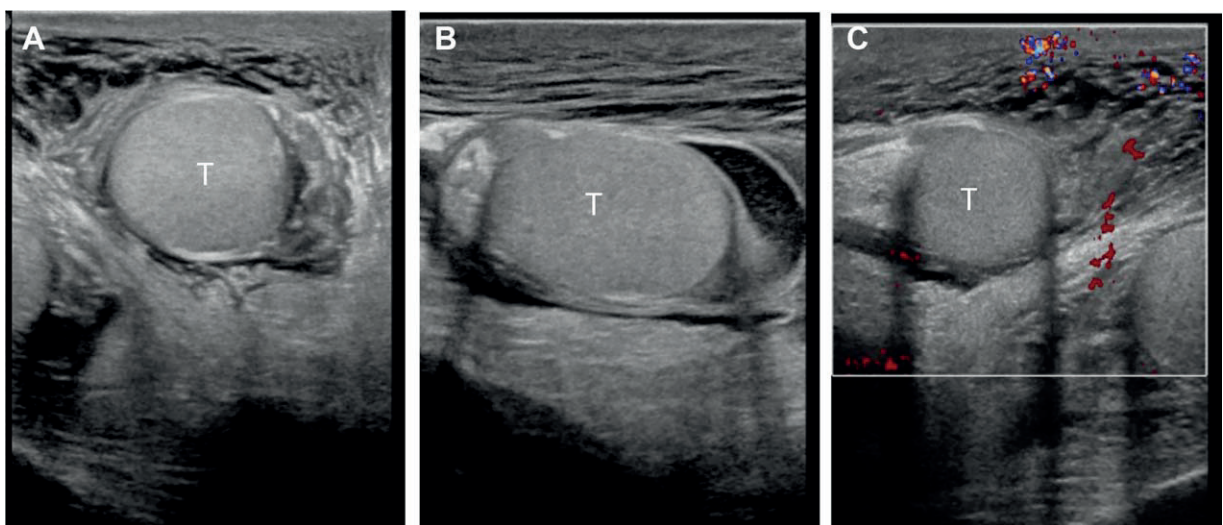
Schönlein-Henoch purpura is a systemic vasculitis that usually affects the skin, kidneys, gastrointestinal tract,

and joints. It is more commonly encountered in the pediatric age group, and episodes of acute scrotal symptoms with pain and enlargement can be encountered in up to 15% of boys with this condition. The sonographic findings include thickening of the scrotal skin, enlargement of the epididymis, often with hypervascularity, and the presence of hydrocele.<sup>11</sup> Unilateral involvement may be observed. The testes are not affected and have a normal volume, shape, and vasculature. A differential diagnosis from an episode of torsion is usually straightforward on the basis of these latter findings (Figure 8).

### *Acute Idiopathic Scrotal Edema*

Acute idiopathic scrotal edema is a relatively frequent condition in boys; it is the fourth most common cause of acute scrotum, following testicular torsion, torsion of testicular appendages, and infections. Rarely, it can be also encountered in the adult population. It is a benign, self-limiting condition that usually resolves without sequelae in a few days. Clinically, it presents with scrotal enlargement, erythema, and, in most cases, acute pain. On sonography, there is diffuse thickening and hypervascularity of the scrotal wall.<sup>12</sup> No space-occupying lesions develop within the scrotal wall in these cases, and vessels have a normal, nondistorted course; this latter finding has been recently described as “the fountain sign.”<sup>13</sup> The wall is easily compressible by the transducer, and involvement is usually bilateral. Both epididymides and

**Figure 9.** Idiopathic scrotal edema in a 10-year-old child admitted for scrotal enlargement and acute pain. **A** and **B**, Axial (**A**) and sagittal (**B**) images of the scrotum showing diffuse thickening of the scrotal wall; the epididymides and both testes were normal. **C**, Slight hypervascularity of the thickened wall is seen on color Doppler imaging. T indicates testis.



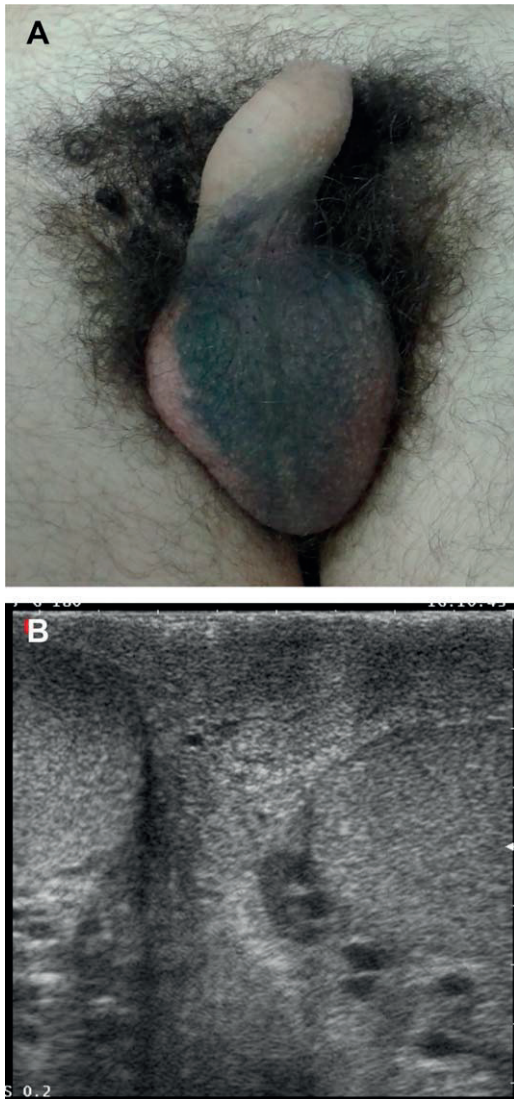


testes have a normal shape, structure, and vascularization (Figure 9). Thickening of the subcutaneous fat in the inguinal and perineal regions can be associated, and inguinal lymph nodes can be enlarged, with an oval shape and increased blood flow at their hilum.

**Trauma and Iatrogenic Lesions**

The role of imaging in patients with blunt scrotal trauma is to rule out possible testicular lesions. However,

**Figure 10.** Scrotal trauma in a 24-year-old amateur soccer player. **A,** Ecchymosis of the scrotal wall along the midline and the left hemiscrotum. **B,** Sonogram showing wall thickening on the left side and at the midline. Both testes were normal. Left varicocele was associated.



thickening of the scrotal wall is usually associated in these cases, and it may be the only finding in some of them (Figure 10). Furthermore, hemorrhagic infiltration within the scrotal wall can be observed in some cases after surgery at the inguinal region, be it for hernia repair, after an inguinal approach for testicular or spermatic cord lesions, or after interventional maneuvers at this level. When requested, imaging is usually aimed at ruling out lesions of the scrotal content.

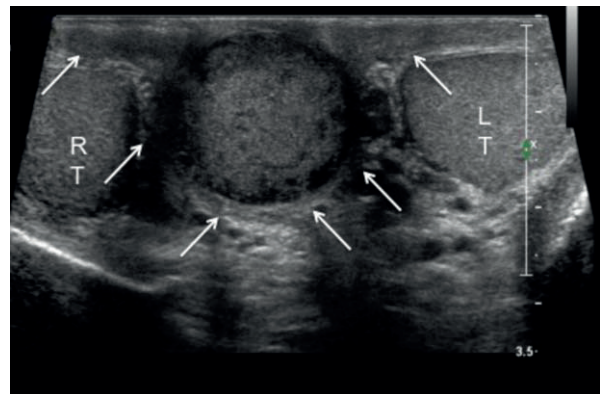
**Focal Thickening**

A variety of space-occupying lesions can be observed within the scrotal wall.

**Epidermal Inclusion Cysts**

Such lesions are common, slow-growing dermal or subcutaneous epithelial cysts containing keratin and lined by a true epidermis. They usually occur in hair-bearing areas of the body, such as the scalp, face, neck, trunk, and back, and are thought to result from occlusion of a pilosebaceous unit or implantation of viable epidermal cells in the dermis or subcutis. They are usually asymptomatic but can undergo infection or rupture. Development of a malignant tumor from an epidermal inclusion cyst has been rarely described. At the scrotal level, such lesions seem more frequent at the midline, along the median raphe, and may clinically resemble polyorchidism. Various sonographic patterns have been described:

**Figure 11.** Axial sonogram from a 52-year-old patient with an epidermal cyst of the scrotal wall showing a pseudotesticular pattern. Both testes were normal. Between them, along the midline, there is a rounded solid mass, which can be recognized as contained within the scrotal wall (arrows point to deep wall layers). LT indicates left testis; and RT, right testis.



AQ6

homogeneous, heterogeneous, hyperechoic, and hypoechoic, depending on the lesion content.<sup>14</sup> A sonographically homogeneously echogenic pattern, called “pseudotesticular,” has been specifically described; when encountered in a cyst arising in the scrotum, it can make the differential diagnosis difficult. However, it is usually possible to identify the location of the cyst within the wall layers, thus allowing proper recognition (Figure 11).<sup>15</sup> Inclusion cysts that undergo complications, such as rupture and inflammation, may have a heterogeneous structure and irregular outer margins, may be surrounded by inflammatory changes, and may be more difficult to recognize. Even if inflamed, however, they lack internal vascularization on color Doppler imaging as well as after contrast agent administration on contrast-enhanced sonography.

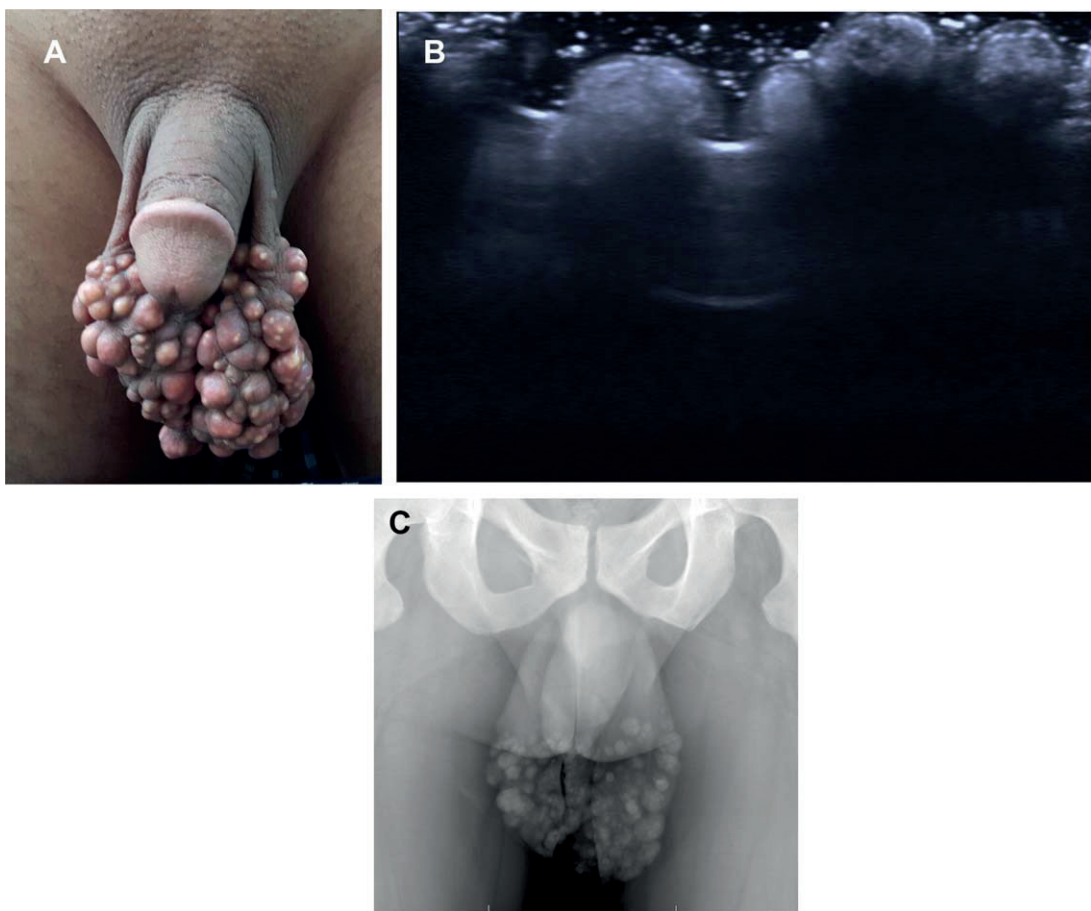
#### ***Idiopathic Scrotal Calcinosis***

This rare condition is characterized by the presence of multiple brown nodules in the scrotal wall. These lesions are located within the dermis, tend to grow slowly in number and size, and contain chalky material corresponding to calcium deposits. The diagnosis can be easily confirmed by depiction of the calcific content of the nodules on radiography (Figure 12). Although this condition is commonly asymptomatic, surgery is indicated for cosmetic reasons.<sup>16</sup>

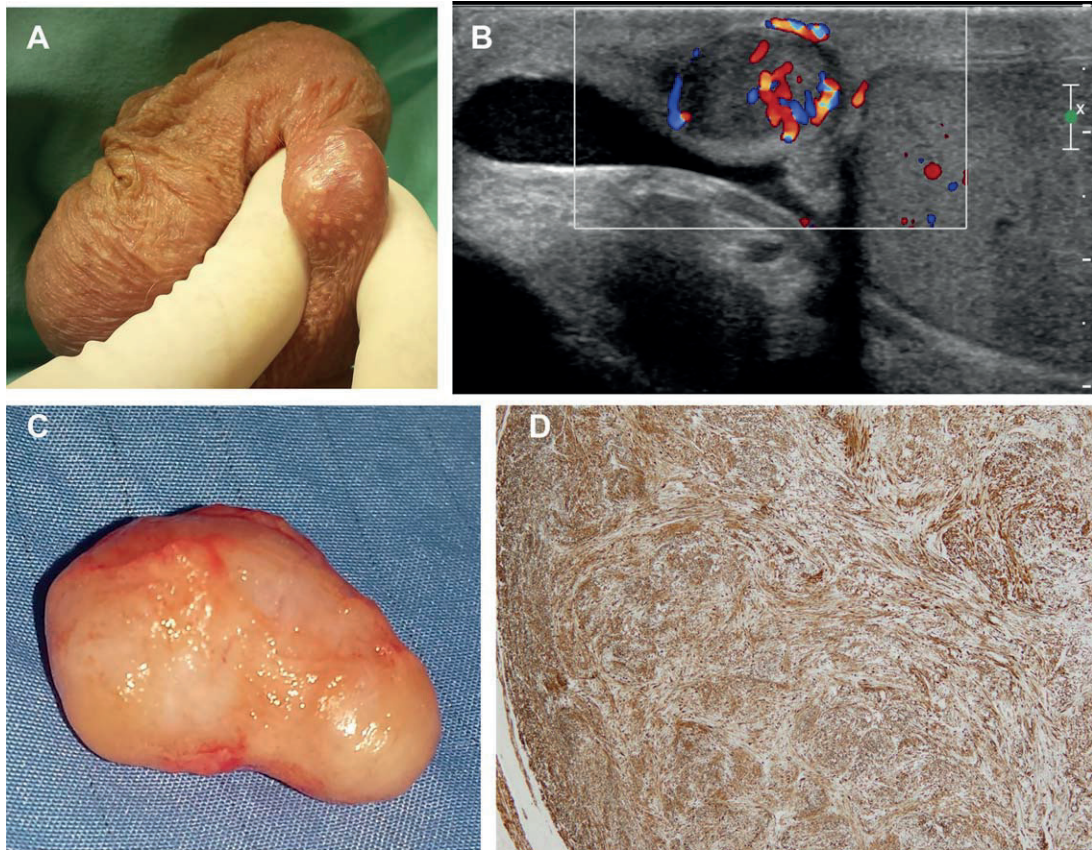
#### ***Skin Tumors***

Primary skin tumors also can be encountered in the scrotal wall. However, they are not usually sent for imaging; only advanced cases may undergo evaluations to check for involvement of deep structures.

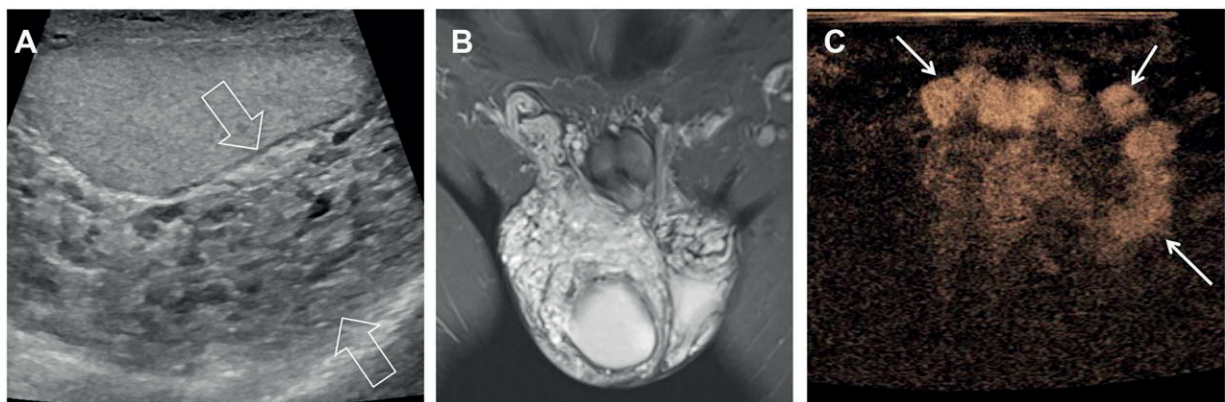
**Figure 12.** Idiopathic scrotal wall calcinosis. **A.** Multiple diffuse nodules are seen on the scrotal wall. **B.** Sonogram showing multiple hyperechoic cutaneous nodules with posterior acoustic shadows. **C.** Plain radiograph showing that the nodules have internal calcifications.



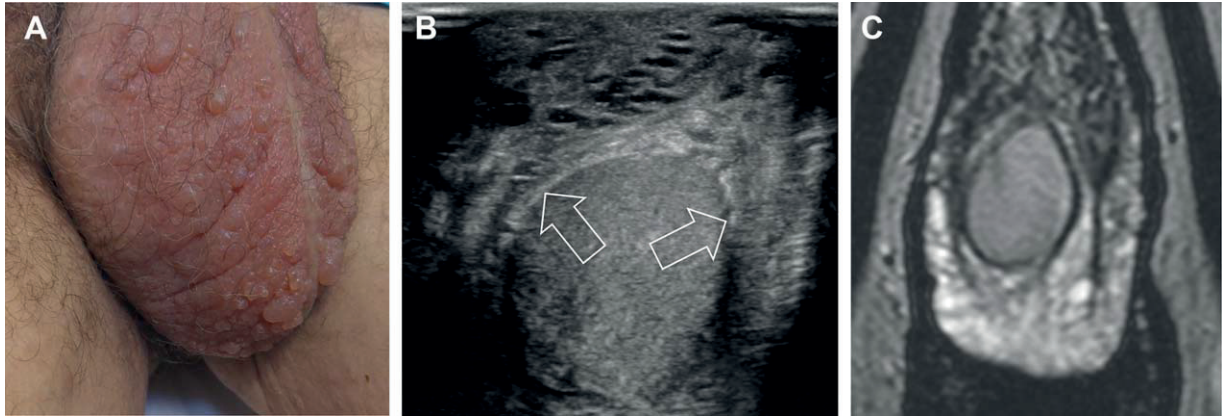
**Figure 13.** **A**, A 74-year-old man underwent scrotal sonography for a palpable nontender nodule. **B**, The lesion was solid, well vascularized, and separate from the testis and epididymis, located within the layers of the scrotal wall. **C** and **D**, A leiomyoma arising from the dartos muscle was found at surgery.



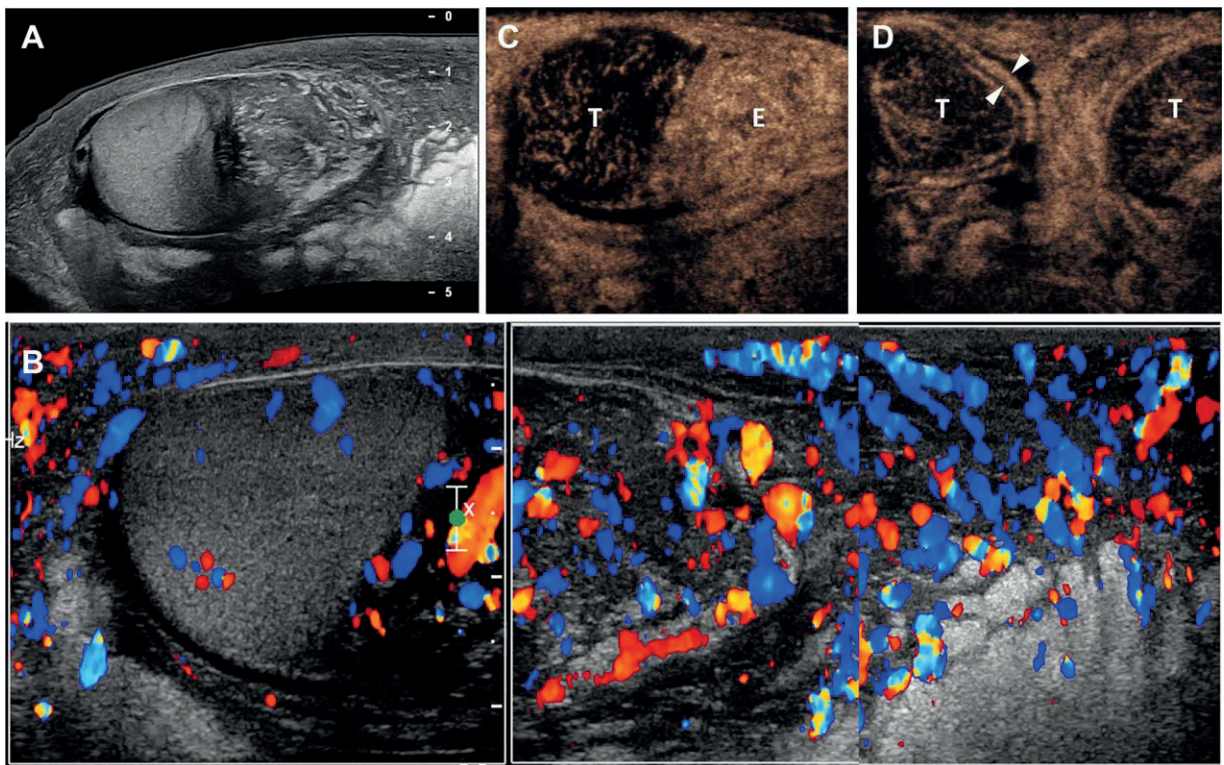
**Figure 14.** Scrotal wall cavernous hemangioma. **A**, Sagittal sonogram showing diffuse inhomogeneous thickening of the scrotal wall (arrows) by the presence of anechoic round and elongated spaces. The lesion did not show vascularization on color Doppler interrogation (not shown). **B**, T2-weighted coronal MRI showing a high-signal intensity mass involving the scrotal wall bilaterally. **C**, Contrast-enhanced sonogram showing filling of large venous spaces (arrows) within the lesion.



**Figure 15.** Lymphangioma of the scrotal wall. **A**, A 55-year-old man presented with multiple clusters of tiny translucent vesicles containing clear fluid for 10 years. A diagnosis of lymphangioma circumscriptum, a form of cutaneous lymphangioma, was made. **B**, Axial sonogram showing deep involvement of the scrotal wall, with diffuse inhomogeneous thickening (arrows) and anechoic round and elongated spaces. **C**, T2-weighted coronal MRI confirming deep involvement of the scrotal wall, with diffuse thickening and internal fluid-filled high-signal intensity areas.



**Figure 16.** Large cell plasmablastic lymphoma involving the epididymis, the tunica vaginalis, and the scrotal wall of a 61-year-old human immunodeficiency virus–positive patient. The patient presented with a rapidly enlarging painless induration of the left hemiscrotum. **A** and **B**, On sonography, the left testis was normal; there was marked enlargement of the left epididymis and marked thickening of the wall of the left hemiscrotum, which were highly vascularized on color Doppler interrogation (**B**). The patient was also examined with contrast-enhanced sonography. **C**, On a sagittal view of the left hemiscrotum, the testis (T) was normal while the epididymis and adjacent scrotal wall were markedly enlarged, showing avid homogeneous contrast enhancement. **D**, Transverse “spectacle” view of the scrotum showing a normal testes, a thickened and hyperenhancing tunica vaginalis (arrowheads) of the right testis, as well as a thickened and hyperenhancing scrotal wall and septum, more evident on the left side. E indicates epididymis; and T, testis.



### *Mesenchymal Tumors*

Although extremely rare, primary tumors may arise from any of the mesenchymal structures within the scrotal wall. Both benign and malignant lesions have been described in the literature, usually as case reports.<sup>17,18</sup> They present as palpable nontender nodules, which appear on sonography as solid vascularized lesions located within the layers of the wall. Unless they have invasive features, they are separated from intrascrotal structures (Figure 13).

### *Hemangiomas, Lymphangiomas, and Arteriovenous Malformations*

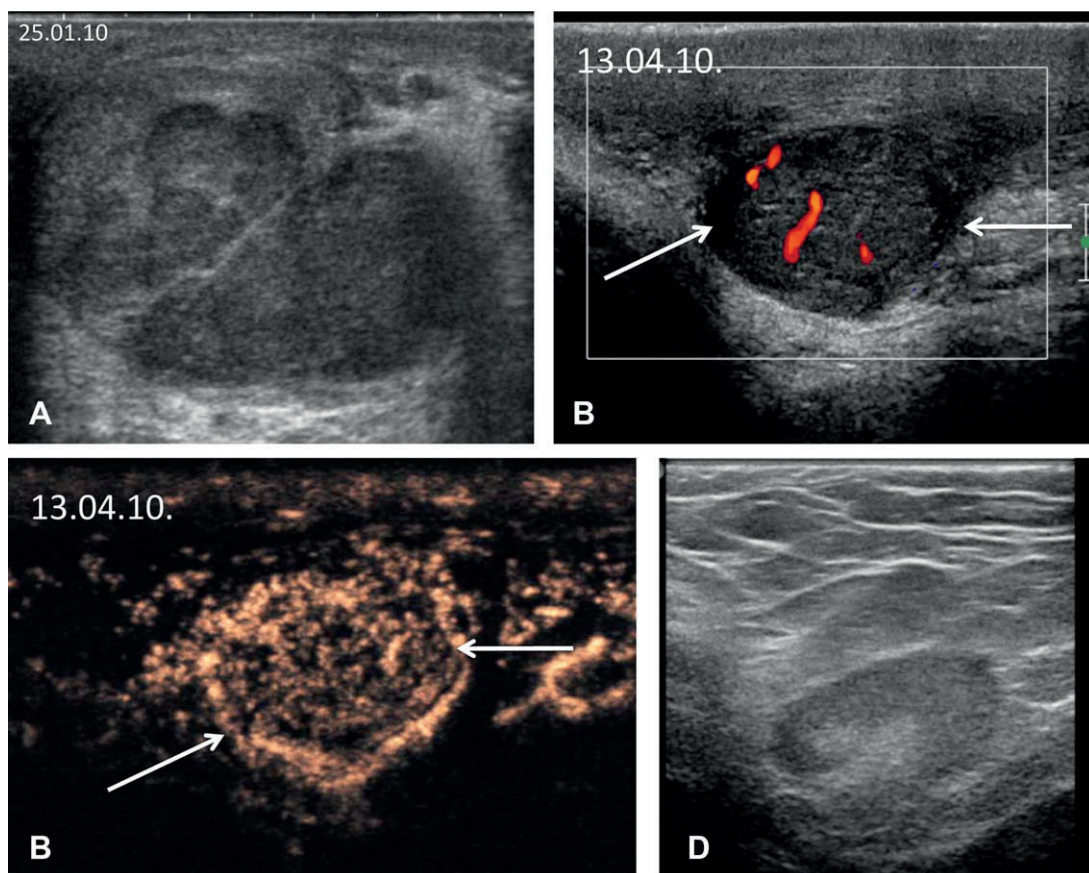
Hemangiomas of the scrotal wall are rare vascular malformations, which often show extension to the penis and

into the perineum.<sup>19</sup> Involvement of the thigh, anterior abdominal wall, and, occasionally, deep organs such as the rectum and sigmoid colon have been described. Lymphangiomas<sup>20</sup> and vascular malformations of the scrotal wall may have a similar appearance.

Hemangiomas are composed of large dilated blood-filled vessels lined by a flattened endothelium; lymphangiomas are composed of dilated lymphatic channels<sup>19-21</sup>; and arteriovenous malformations are abnormal connections between arteries and veins.

Both hemangiomas and lymphangiomas may be superficial (cutaneous) or deep (subcutaneous) or may have both superficial and deep involvement. In lesions with deep components, imaging is indicated to determine the extent of the lesion, to detect any

**Figure 17.** **A**, Sonogram from a 36-year-old patient who underwent left orchidectomy for a 4-cm seminoma through an inguinal approach. During surgery, extraction of the testis proved difficult because of intrascrotal adhesions but was at last successful. **B** and **C**, About 3 months later the patient returned with a palpable mass involving the left scrotal wall (arrows in **B**); it had a few internal vessels on color Doppler imaging and was highly vascularized on contrast-enhanced sonography (**C**). **D**, Enlarged lymph nodes were seen at the inguinal level. Left hemiscrotectomy was performed, and the pathologic examination showed a metastatic nodule involving the scrotal wall.



associated abnormalities, and to help plan therapy and follow-up.

On sonography, scrotal wall hemangiomas present with a heterogeneous echo texture and increased through-transmission, showing septa and enlarged vascular spaces (Figure 14). Phleboliths may be seen as foci with distal acoustic shadowing. Lymphangiomas may present as lobulated cystic masses or with findings similar to those of hemangiomas (Figure 15). Vascular signals within hemangiomas may be difficult to detect on color Doppler imaging because of their characteristic slow flow. Arteriovenous malformations, on the contrary, show prominent vessels that have both venous and arterial components, with high-velocity flow. Persistent filling of large venous spaces fed by multiple small afferent vessels can be identified in hemangiomas on contrast-enhanced sonography, whereas the dilated lymphatic channels of lymphangiomas do not enhance. Also, identification of phleboliths is highly suggestive of scrotal wall hemangiomas on sonography, plain radiography, and CT.<sup>22</sup>

Due to its higher panoramic capability and excellent contrast resolution, MRI is the modality of choice for delineating the extent of these lesions before performing surgical procedures. Hemangiomas and lymphangiomas present on MRI as lobulated scrotal masses with intermediate-to-low signal intensity on T1-weighted images and high signal intensity on T2-weighted images. Arteriovenous malformations appear as a tangle of abnormal vessels, frequently with internal flow voids on both T1- and T2-weighted images, which are produced by high-velocity flow. Focal areas of signal voids also can be seen in hemangiomas, consistent with thrombi. Hemangiomas show enhancement of the dilated vascular channels, whereas lymphangiomas are poorly vascularized.<sup>23</sup>

### **Lymphomas**

Lymphomas of the soft tissues are relatively rare; they also have been described at the level of the scrotal wall as cutaneous nodules with a nonspecific appearance; and their imaging findings have not been reported. Lymphomas, however, have to be considered in patients older than 60 years and in human immunodeficiency virus–positive patients. Lymphomas of the scrotal wall may be due to secondary involvement in patients with systemic disease, may be the first location of the disease process, and may arise in the testis or at the epididymal

level, with invasion of the adjacent scrotal wall (Figure 16). Such lesions appear as hypoechoic hypervascular thickening on color Doppler interrogation and contrast-enhanced sonography; MRI shows scrotal wall thickening, either diffuse or focal, with intermediate signal intensity on both T1- and T2-weighted images and with marked contrast enhancement after contrast agent injection. Although these imaging findings can be difficult to differentiate from those of inflammatory conditions, their clinical presentation, which is usually characterized by rapid enlargement of the affected area that is not associated with pain, has to suggest lymphoma in the differential diagnosis.<sup>24,25</sup>

### **Metastases**

Metastatic lesions affecting the scrotal wall are rare, with only a few case reports in the literature. Metastatic melanoma and secondary deposits from penile, anal, and lung carcinomas have been described. Various findings have been reported, with the lesions presenting either as solid nodules or as diffuse hypervascular thickening of the scrotal wall.<sup>26,27</sup> Local recurrence may even be found after inguinal orchidectomy in patients with testicular tumors at the T2 stage, which had already involved the parietal layer of the tunica vaginalis. If this condition is not preoperatively identified, extraction of the diseased testis through the inguinal approach may leave neoplastic residuals, which can cause scrotal wall recurrence (Figure 17).

## **References**

1. Dogra V, Gottlieb RH, Oka M, Rubens DJ. Sonography of the scrotum. *Radiology* 2003; 227:18–36.
2. Akbar SA, Sayyed TA, Jafri SZ, Hasteh F, Neill JS. Multimodality imaging of paratesticular neoplasms and their rare mimics. *Radiographics* 2003; 23:1461–1476.
3. Woodward PJ, Schwab CM, Sesterhenn IA. Extratesticular scrotal masses: radiologic-pathologic correlation. *Radiographics* 2003; 23: 215–240.
4. Garriga V, Serrano A, Marin A, Medrano S, Roson N, Pruna X. US of the tunica vaginalis testis: anatomic relationships and pathologic conditions. *Radiographics* 2009; 29:2017–2032.
5. Derchi LE, Bertolotto M, Valentino M, Simonato A. The acute scrotum. *Ultrasound Clin* 2013; 8:531–544.
6. Oktar SO, Yucel C, Ercan NT, Capkan D, Ozdemir H. Fournier's gangrene: US and MR imaging findings. *Eur J Radiol Extra* 2004; 50: 81–87.

7. Levenson RB, Singh AK, Novelline RA. Fournier gangrene: role of imaging. *Radiographics* 2008; 28:519–528.
8. Grainger AJ, Hide IG, Elliott ST. The ultrasound appearance of scrotal oedema. *Eur J Ultrasound* 1998; 12:19–34.
9. Chaubal N, Pradhan GM, Chaubal JN, Ramani SK. Dance of adult filarial worms is a reliable sign of scrotal filarial infection. *J Ultrasound Med* 2003; 22:765–769.
10. Adejolu M, Sidhu PS. The “filaria dance” is not characteristic of filariasis: observation of “dancing megasperm” on high-resolution sonography in patients from nonendemic areas mimicking the filarial dance and a proposed mechanism for this phenomenon. *J Ultrasound Med* 2011; 30:1145–1150.
11. Ben-Sira L, Laor T. Severe scrotal pain in boys with Henoch-Schönlein purpura: incidence and sonography. *Pediatr Radiol* 2000; 30:125–128.
12. Lee A, Park SJ, Lee HK, Hong HS, Lee BH, Kim DH. Acute idiopathic scrotal edema: ultrasonographic findings at an emergency unit. *Eur Radiol* 2009; 19:2075–2080.
13. Geiger J, Epelman M, Darge K. The fountain sign: a novel sonographic sign for the diagnosis of acute idiopathic scrotal edema. *J Ultrasound Med* 2010; 29:1233–1237.
14. Worstman X. Common applications of dermatologic sonography. *J Ultrasound Med* 2012; 31:97–111.
15. Huang CC, Ko SF, Huang HY, et al. Epidermal cysts in the superficial soft tissues: sonographic features with an emphasis on the pseudotestis pattern. *J Ultrasound Med* 2011; 30:11–17.
16. Pompeo A, Molina WR, Pohlman GD, Sehr D, Kim FJ. Idiopathic scrotal calcinosis: a rare entity and a review of the literature. *Can Urol Assoc J* 2013; 7:e439–e441.
17. Li D, Li Y, Wang K, et al. Embryonal rhabdomyosarcoma of the tunica dartos in the scrotum. *J Ultrasound Med* 2011; 30:105–109.
18. Siegal GP, Gaffey TA. Solitary leiomyomas arising from the tunica dartos scroti. *J Urol* 1976; 116:69–71.
19. Ergün O, Ceylan BG, Armagan A, Kapucuoglu N, Ceyhan AM, Perk H. A giant scrotal cavernous hemangioma extending to the penis and perineum: a case report. *Kaohsiung J Med Sci* 2009; 25:559–561.
20. Weidman ER, Cendron M, Schned AR, Harris RD. Scrotal lymphangioma: an uncommon cause for a scrotal mass. *J Ultrasound Med* 2002; 21:669–672.
21. Zacharia JR, Gupta AK, Lamba S. Arteriovenous malformation of the scrotum: is preoperative angioembolization a necessity? *Indian J Urol* 2012; 28:329–334.
22. Rastogi R. Cavernous hemangioma of the penis, scrotum, perineum and rectum: a rare tumor. *Saudi J Kidney Dis Transplant* 2008; 19: 614–618.
23. Parker RA III, Menias CO, Quazi R, et al. MR imaging of the penis and scrotum. *Radiographics* 2015; 35:1033–1050.
24. Modi S, Yang DJ, Sule N, Rosen T. Primary cutaneous CD30<sup>+</sup> large-cell lymphoma presenting as a scrotal plaque. *Dermatol Online J* 2009; 15:9.
25. Draghi F, Bonardi M, Dellabianca C, Tarantino CC, Alessi S. Lymphoma of the scrotum in patients with Down’s syndrome: US appearance. Mini-pictorial essay. *J Ultrasound* 2011; 14:216–219.
26. Dogra V, Saad W, Rubens DJ. Sonographic appearance of scrotal wall metastases from lung adenocarcinoma. *AJR Am J Roentgenol* 2002; 179:1647–1648.
27. Draghi F, Schiavina G, Ferrozzi G, Bandini V, Consonni M. Color Doppler findings of secondary carcinoma of the tunica vaginalis testis. *J Clin Ultrasound* 1996; 24:141–144.