

Diagnosis and ultrasound-guided retrieval of a vaginal foreign body in a dog and a cat

Diagnose en echogeïde verwijdering van een vaginaal vreemd voorwerp bij een hond en een kat

¹L. Gatel, ²G. Gory, ³B. De Pauw, ²D.N. Rault

¹Department of Veterinary Medical Imaging and Small Animal Orthopedics, Faculty of Veterinary Medicine, Ghent University, Salisburylaan 133, B-9820 Merelbeke, Belgium

²Azurvet, Referral Center in Veterinary Diagnostic Imaging and Neurology. Hippodrome – 2 Boulevard Kennedy 06800 Cagnes-sur-Mer, France

³Veterinary University Hospital Center, Small Animal Department, Faculty of Veterinary Medicine, Montreal University, Saint Hyacinthe, Canada

laure.gatel@gmail.com

A BSTRACT

In this case report, the diagnosis and ultrasound-guided retrieval of an intravaginal grass awn in a dog and a cat are described. The dog was presented with chronic vaginal discharge for over two years. The cat was presented for acute lethargy and bloody vaginal discharge and a two-week history of a perivulvar leakage. Ultrasonographic diagnosis included the visualization of a linear, hyperechoic and spindle-shaped structure and mild thickness of the vagina. The grass awns were successfully retrieved non-invasively, under general anesthesia using ultrasound-guided Hartmann forceps inserted into the vagina. Ultrasound-guided grass awn retrieval from the vagina appears to be a safe and inexpensive procedure.

SAMENVATTING

In deze casuïstiek worden de identificatie en verwijdering beschreven van een intravaginaal grasaar met behulp van echografie bij een hond en een kat. De hond werd aangeboden voor chronische vaginale uitvloeï gedurende reeds meer dan twee jaar. De kat werd aangeboden voor acute lethargie, bloederige vaginale uitvloeï en een voorgeschiedenis van perivulvaire uitvloeï gedurende twee weken. Met behulp van echografie werden er een lineaire, hyperechogene, spoelvormige structuur en een milde verdikking van de vaginawand in beeld gebracht. Het grasaar werd in beide gevallen succesvol onder algemene anesthesie niet-invasief verwijderd, onder echobegeleiding en met behulp van een hartmanntang. Echogeïde verwijdering van een grasaar uit de vagina is een veilige en goedkope techniek.

INTRODUCTION

To the authors' knowledge, only few cases of vaginal foreign body in dogs and cats have been reported in the literature, and although grass awn migration is common in some parts of the world, it has not been reported in the vagina. Vaginal foreign bodies which have already been encountered in dogs, include a piece of lollipop stick, a disposable cigarette lighter, half a ballpoint pen and a fragment of fetal calvarium (Ratcliffe, 1971; Dietrich, 1979; McCabe and Steffey, 2004; Snead et al., 2010). Vaginal foreign bodies are considered as differential diagnosis for recurrent mucopurulent or hemorrhagic chronic vaginal discharge.

Migrating grass awns have been more frequently described in dogs than in cats. The three main locations described for grass awns in dogs are the external ear canal (54%), the interdigital space (23 %) and the eye and orbit (15 %). No description of grass awn migration in the uterus or vagina have been reported in these species, even though grass awns have been found in the urinary bladder and in the urethra (Brennan and Ihrke, 1983; Morshead, 1983; Cherbinski et al., 2010).

Ultrasound-guided grass awn retrieval is minimally invasive and hence, appears to be a safe, effective method for retrieving superficially located plant awns in the dog (Della Santa et al., 2008). It was successfully used for the retrieval of vaginal grass awn foreign bodies in the two cases reported here.

CASE REPORT

Case 1

A three-year-old, female, spayed Dachshund weighing 9 kg was presented to Azurvet Center (France) for vaginal discharge that initiated six months after sterilisation. The dog had regular access to the outdoor countryside. It was spayed by ovariohysterectomy 33 months prior to referral. The discharge was initially intermittent and was characterized by a small amount of brown fluid without perivulvar dermatitis. The dog was presented to a first veterinarian five months after the onset of vaginal discharge because of constant vulvar licking, and was treated with oral antibiotics (molecule and dose unknown) for 15 days. Despite clinical improvement of short duration, the vaginal discharge recurred after the end of treatment. One year later, the dog was still licking its vulva and was presented to a second veterinarian, who performed a vaginal exploration with a speculum. A moderate amount of purulent fluid was observed, no foreign body was visualized, and cystitis was suspected. An oral course of amoxicilline and clavulanic acid (12.5 mg/kg, q12h) for 20 days was prescribed. Although a decrease of the vaginal discharge was noted at the first follow-up examination, it relapsed again 15 days prior to the referral to Azurvet Center (France), at which stage, it was significantly more pronounced. The patient was referred for chronic, mucopurulent vaginal discharge of a 27-month duration.

Upon admission, the dog was in good body condition. The main differential diagnosis included chronic vaginitis secondary to urinary tract infection, ovarian remnant syndrome, and exogenous hyperestrogenism. The other possibilities were genital tract congenital malformation, uterine stump infection, urogenital tumor and an intravaginal foreign body. The dog did not have access to oestrogen-containing products, and the discharge was not cyclic. A transabdominal cystocentesis revealed yellow-colored and slightly cloudy urine with a normal urinalysis (specific gravity 1.038, pH=6, absence of protein, glucose, white or red blood cells).

Case 2

A six-year-old, female, spayed domestic shorthair cat was referred to Azurvet Center (France) for perivulvar hair loss, which had been noticed two weeks previously (during summer time). Vaginitis and/or cystitis were/was suspected by the first-line veterinarian, who prescribed phloroglucinol (6mg q24h) and meloxicam (0,1mg/kg q24h) per os. Five days after the onset of treatment, no improvement was noticed. The cat was presented with vaginal, seropurulent discharge, lethargy, dehydration and vomiting. A serum biochemical analysis did not reveal any significant abnormalities, except for dehydration (BUN: 2.2g/l

(reference interval: 0.2 – 0.6 g/l), creatinine = 112 µmol/l (reference interval: 70.7-159 µmol/l), TP = 95g/l (reference interval: 54 – 78 g/l). The cat was admitted to the clinic, received adapted fluid therapy and intramuscular marbofloxacin (3mg/kg q24h). An improvement was noticed within 48 hours with normalization of serum BUN and creatinine concentrations.

The main differential diagnosis included urinary tract infection and uterine stump pyometra. The other possibilities were a urogenital foreign body, urogenital congenital malformation and urogenital neoplasia.

Diagnostic Imaging

Perineal and abdominal ultrasonographic examinations were performed in both cases using a microconvex transducer (11-8 MHz) and a linear transducer (14-8 MHz) (Aplio400, Toshiba, Tochigi, Japan). In the first case, perineal examination of the caudal portion of the genital tract revealed no obvious abnormalities. Standard abdominal examination showed that the kidneys and urinary bladder had a normal appearance. The adrenal glands were normal in size and appearance, and had a normal shape. The uterine stump was homogeneous. A subjectively mild enlargement of the cranial vagina was noticed (4 mm) (Figure 1). After careful examination of the cranial portion of the vagina, a linear, spindle-shaped and moderately hyperechoic structure without distal acoustic shadowing was visualized within the lumen, when the transducer was perpendicular to the vagina. It measured 17.9 mm in length. Neither inflammation of the surrounding fat nor intraluminal fluid accumulation was observed.

In case 2, perineal ultrasonographic examination yielded unusually distended anal glands without evidence of a fistula or perianal cellulitis. Abdominal ultrasonographic examination showed mild thickening of the abdominal vagina, with a prominent vaginal wall, a small amount of intraluminal fluid and the presence of a linear, spindle-shaped and hyperechoic structure within the vaginal lumen (Figure 2). It created a mild distal acoustic shadowing. No inflammation of the surrounding fat was detected. The urinary bladder had a normal appearance. Mild, bilateral renal pelvic dilation was noticed, most likely secondary to fluid therapy.

In both cases, the diagnosis of an intravaginal grass awn was performed and ultrasound-guided retrieval was planned. The animals were anesthetized with diazepam (6 mg/kg) and propofol (4 mg/kg). Subsequently, an endotracheal tube was placed and isoflurane was administered. The animals were placed in dorsal recumbency. In both cases, the perianal region was shaved and aseptically prepared. The Hartmann forceps was introduced in the vagina similarly as a vaginal swab. The extremity of the forceps was visualized with the ultrasound transducer through an

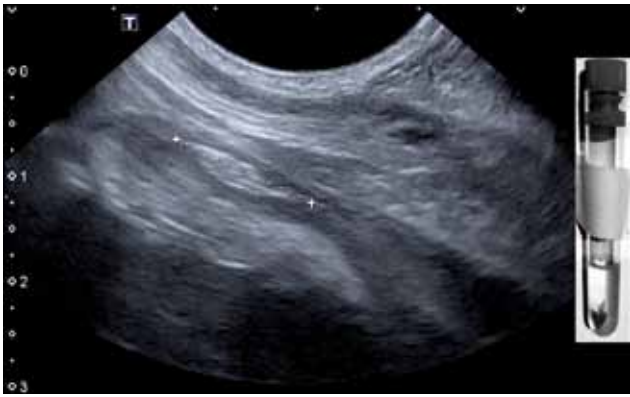

Figure 1. Grass awn in the vagina of a dog. A hyper-echoic, spindle-shaped structure (between cursors) with multiple parallel bright interfaces is observed in longitudinal plane in the vagina. Its length is approximately 15 mm. Distal acoustic shadowing is absent.

abdominal window. The extremity of the forceps was moved as close as possible to the caudal extremity of the grass awn. Then, the forceps was opened, shortly moved cranially, slightly rotated along its long axis to ensure to be on either side of the foreign body, and was then closed and removed. After the procedure, in both cases, some gas bubbles were visualized in the lumen of the vagina due to the entrance of the forceps. The grass awns and the vagina were carefully inspected to confirm that the foreign body had been entirely removed. In both cases, the grass awns were adherent to the vaginal wall. This mural adhesion influenced the traction strength necessary to carry on the forceps to retrieve the foreign body. In case 2, a piece of vaginal mucosa was removed with the grass awn without consequence for the cat.

Antibiotics were continued for a further 15 days in the case of the dog and one month in the case of the cat. Phone-based follow-up one month and six months later confirmed the dog and the cat to be in good health with no recurrence of the vulvar discharge or licking.

DISCUSSION

Grass awns are adapted to a strict anterograde migration because of their anterior, barbed florets (Brennan and Ihrke, 1983; Schultz and Zwingenberger, 2008; Del Angel-Caraza et al., 2011). How the awns entered the vagina in the two present cases is unclear, although an ascending migration through the vulva may be suspected. The normal micturition position of a female dog or cat (i.e. the vulva close to the ground) or rubbing the perineum on the ground because of anal sac impaction may predispose to awns being brought close to the vulva. In addition, ascending and descending contractions of the vagina and uterus are common (during oestrus but also anoestrus), and may facilitate progression of the foreign body in these tubular organs (Brennan and Ihrke, 1983; Chatdarong et al., 2006; Snead et al., 2010).

In dogs and cats, ultrasonography, computed

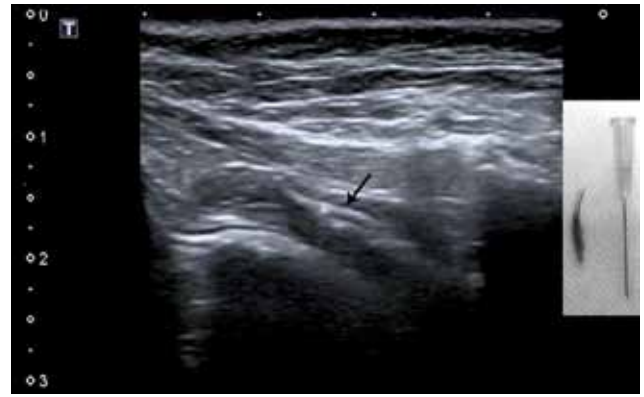


Figure 2. Grass awn in the vagina of a cat. A hyperechoic, spindle-shaped structure (arrow) of approximately 17 mm in length is observed in the vagina of a cat. Slight distal acoustic shadowing is present.

tomography, magnetic resonance imaging, otoscopy and vaginoscopy have been used for the diagnosis of grass awn migration (Schultz and Zwingenberger, 2008; Whitty et al., 2013). Ultrasound examination is a non-invasive technique that can be used to confirm the presence and to precisely identify the location and size of radiolucent foreign bodies (Staudte et al., 2004). The typical ultrasonographic appearance of a foreign body is a bright, hyperechoic interface, with focal distal acoustic shadowing, and associated with an anechoic halo representing fluid (Staudte et al., 2004; Gnudi et al., 2005). In most cases, grass awns can be visualized ultrasonographically (Gnudi et al., 2005). Grass awn foreign bodies have been described as linear, spindle-shaped and hyperechoic images of variable length (4 to 15 mm), with two or three parallel reflecting interfaces corresponding to the seed and its envelopes. According to a previous report, there is acoustic shadowing distal to grass awns on sagittal plane in only 28% of the cases. The acoustic shadowing artefact is even less visible on transverse images (Staudte et al., 2004). In some acute cases, acoustic shadowing is not visible at all (Staudte et al., 2004). When the foreign body is not easily visible, peripheral steatitis (hyperechoic appearance of the surrounding fat) and the presence of free fluid (anechoic content in the lumen) could help to find it. However, in the two cases described here, neither surrounding steatitis nor a significant amount of vaginal fluid were noticed.

Furthermore, the retrieved grass awns were intact without sign of inflammatory damage. No significant vaginal wall remodelling or thickening was observed, even after a suspected presence of the foreign body for already two years in case 1. Only a mild increase of the vaginal diameter and focal echogenic content drew the observer's attention. These observations and the small number of reports describing vaginal foreign bodies allow the authors to assume that they may be well-tolerated in small animals and in humans (Smith et al., 2002; Sugar and Graham, 2006; Ahmidat and Taylor, 2010). The specific vasculature and innerva-

tion of the vagina may explain this tolerance, as the vessels and nerves are localized in the serosa and not in the endometrium (Schatten and Constantinescu, 2007).

In cases of chronic vaginal discharge in spayed, female patients, other potential causes should be excluded before looking for a vaginal foreign body. The first differential to be ruled out is hormonal impregnation of the urogenital tract (Snead et al., 2010, De Loor and Van Soom, 2012). In case 1, the owner was asked if she used exogenous oestrogenic ointments; during ultrasonographic examination, careful examination of the adrenal glands was performed. No ovarian remnant tissue was found. However, ultrasonography is not the easiest method to diagnose it; vaginal cytology and hormonal dosage are preferred (Demirel and Acar, 2012, Fleischer et al., 1998, Ball et al., 2010). Additionally, urinary infection, congenital abnormalities and the presence of a urogenital mass (malformation, tumor, cyst, abscess, granuloma) should be ruled out (Snead et al., 2010, Wang et al., 2006).

Vaginoscopic examination is the most common procedure used to diagnose and treat vaginal foreign bodies (Snead et al., 2010). In the two present cases, ultrasound-guided retrieval was performed. This method appears to be safe, fast and inexpensive. Limitations depend on the ultrasound device, the operator's experience, the location of the foreign body and the risk of incomplete retrieval (Armbrust et al., 2012). The presence of gas bubbles after the introduction of the forceps may interfere with a second intervention in case of an incomplete removal, and may limit the final success of the procedure (Della Santa et al., 2008). Pelvic location of a vaginal foreign body renders ultrasound guidance useless since the awn cannot be visualized. If a suspected foreign body cannot be identified at the initial ultrasonographic examination, it may be important to follow up the case, repeat the ultrasonographic examination after antibacterial treatment withdrawal or to perform vaginoscopy.

Compared to what has been reported for the treatment of other vaginal foreign bodies (Johnson, 1991, Okkens et al., 1992), no vaginal flush was performed after retrieval in the present cases due to the ultrasonographic appearance of the uterus. Only systemic antibiotic therapy was continued in these animals. None of the two owners noticed any recurrence of the vaginal discharge after the intervention.

CONCLUSION

These two cases are original and are the first description of chronic grass awn migration in the vaginal lumen in a dog and a cat. The presence of these foreign bodies was associated with slight, intermittent vaginal discharge. To find the vaginal grass awn by ultrasonography may be difficult because of the absence of obvious vaginal reaction (surrounding steatitis and fluid accumulation in the

lumen), an unusual location, and depends on the operator's experience. However, ultrasound-guided retrieval of vaginal grass awns appears to be a safe, fast and inexpensive procedure.

ACKNOWLEDGEMENTS

The authors would like to thank Anaïs Combes and Eddy Cauvin for their help in the preparation of the manuscript.

REFERENCES

- Ahmidat A., Tailor A. (2010). Unusual presentation of vaginal foreign body. *Journal of Obstetrics and Gynecology* 30, 873-875.
- Armbrust L.J., Biller D.S., Bamford A., Chun R., Garrett L.D., Sanderson M.W. (2012). Comparison of three-view thoracic radiography and computed tomography for detection of pulmonary nodules in dogs with neoplasia. *Journal of the American Veterinary Medical Association* 240, 1088-1094.
- Ball R.L., Birchard S.J., May L.R., Threlfall W.R., Young G.S. (2010). Ovarian remnant syndrome in dogs and cats: 21 cases (2000-2007). *Journal of the American Veterinary Medical Association* 236, 548-553.
- Brennan K.E., Ihrke P.J. (1983). Grass awn migration in dogs and cats: a retrospective study of 182 cases. *Journal of the American Veterinary Medical Association* 182, 1201-1204.
- Chatdarong K., Lohachit C., Kiartmanakul S., Axner E., Forsberg C.L. (2006). Cervical patency during non-ovulatory and ovulatory estrus cycles in domestic cats. *Theriogenology* 66, 804-810.
- Cherbinsky O., Westropp J., Tinga S., Jones B., Pollard R. (2010). Ultrasonographic features of grass awns in the urinary bladder. *Veterinary Radiology & Ultrasound* 51, 462-465.
- De Loor J., Van Soom A. (2012). Hyperestrogenism in a female Chihuahua puppy. *Vlaams Diergeneeskundig Tijdschrift* 81, 32-37.
- Del Angel-Caraza J., Pérez-García C.C., Bende B., Diez-Prieto I., García-Rodríguez B. (2011). Mouse barley awn (*Hordeum murinum*) migration induced cystolithiasis in 2 male dogs. *Canadian Veterinary Journal* 52, 67-69.
- Della Santa D., Rossi F., Carlucci F., Vignoli M., Kircher P. (2008). Ultrasound-guided retrieval of plant awns. *Veterinary Radiology & Ultrasound* 49, 484-486.
- Demirel M.A., Acar D.B. (2012). Ovarian remnant syndrome and uterine stump pyometra in three queens. *Journal of Feline Medicine & Surgery* 14, 913-918.
- Dietch B.E. (1979). Persistent vaginal discharge in a spayed dog. *Veterinary Medicine, Small Animal Clinician* 74, 1748-1749.
- Fleischer A.C., Tait D., Mayo J., Burnett L., Simpson J. (1998). Sonographic features of ovarian remnants. *Journal of Ultrasound Medicine* 17, 551-555.
- Gnudi G., Volta A., Bonazzi M., Gazzola M., Bertoni G. (2005). Ultrasonographic features of grass awn migration in the dog. *Veterinary Radiology & Ultrasound* 46, 423-426.
- Johnson CA. (1991). Diagnosis and treatment of chronic vaginitis in the bitch. *Veterinary Clinics of North America: Small Animal Practice* 21, 523-531.

- McCabe J.R., Steffey M.A. (2004). What is your diagnosis? Dystocia during a previous parturition. *Journal of the American Veterinary Medical Association* 224, 1255-1256.
- Morshead D. (1983). Submucosal urethral calculus secondary to foxtail awn migration in a dog. *Journal of the American Veterinary Medical Association* 182, 1247-1248.
- Okkens A.C., van Haften B., Nickel R. (1992). Fertility problems in the bitch. *Vlaams Diergeneeskundig Tijdschrift* 117, 229-234.
- Ratcliffe J. (1971). Vaginal bleeding in a spayed bitch: a case report. *Journal of Small Animal Practice* 12, 169.
- Schatten H., Constantinescu G.M. (2007). *Comparative Reproductive Biology*. First edition, Iowa State University Press.
- Schultz R.M., Zwingenberger A. (2008). Radiographic, computed tomographic, and ultrasonographic findings with migrating intrathoracic grass awns in dogs and cats. *Veterinary Radiology & Ultrasound* 49, 249-255.
- Smith Y.R., Berman D.R., Quint E.H. (2002). Premenarchal vaginal discharge: findings of procedures to rule out foreign bodies. *Journal of Pediatric and Adolescent Gynecology* 15, 227-230.
- Snead E.C., Pharr J.W., Ringwood B.P., Beckwith J. (2010). Long-retained vaginal foreign body causing chronic vaginitis in a bulldog. *Journal of the American Animal Hospital Association* 46, 56-60.
- Staudte K.L., Hopper B.J., Gibson N.R., Read R.A. (2004). Use of ultrasonography to facilitate surgical removal of non-enteric foreign bodies in 17 dogs. *Journal of Small Animal Practice* 45, 395-400.
- Sugar N.F., Graham E.A. (2006). Common gynecologic problems in prepubertal girls. *Pediatrics in Review* 27, 213-223.
- Wang K.Y., Samii V.F., Chew D.J., McLoughlin M.A., DiBartola S.P., Masty J. and Lehman A.M. (2006). Vestibular, vaginal, and urethral relations in spayed dogs with and without lower urinary tract signs. *Journal of Veterinarian Internal Medicine* 20, 1065-1073.
- Whitty C., Milner H., Oram B. (2013). Use of Magnetic Resonance Imaging in the diagnosis of spinal empyema caused by a migrating grass awn in a dog. *New Zealand Veterinary Journal* 61, 115-118.

Uit het verleden

KAT GENAAID

Bij het beproeven van een gewaagde stelling
 uit de evenwichtsleer
 werd ons poesje het slachtoffer
 van te slap gespannen prikkeldraad.
 Mijn vader, gehaaid kleermaker,
 naaide zonder veel omhaal
 de als darmen klagende kat weer vast.
 Daarbij doorpriemde de stopnaald
 het melkwegstelsel van een zenuwcel.
 Als een raket schoot het krijsende dier
 vanonder zijn helende vingers,
 knalde tegen het plafond,
 schoot tegen de brandende kachel aan.
 Met één zwaai van de wereldatlas
 kon ik het beestje uit zijn lijden verlossen.

Koenraad De Waele. Fragment uit 'De droom van het nieuwe geloof' verschenen in de bundel *Plankgas*, Poëziecentrum, Gent, 1988.

Luc Devriese