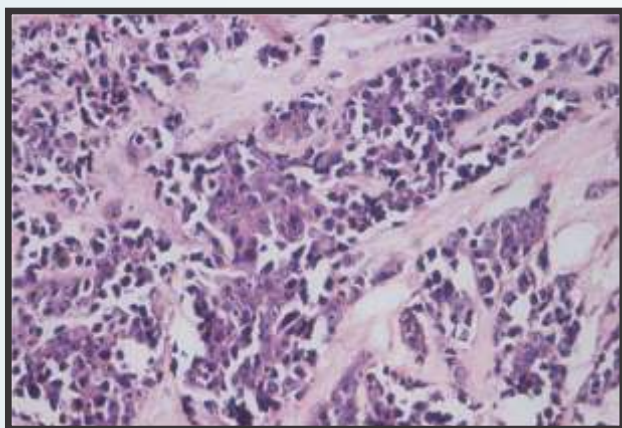


ISSN 0973-029X

JOURNAL OF ORAL AND MAXILLOFACIAL PATHOLOGY

Volume XX Issue 1 Jan - Apr 2016



JOMFP
www.jomfp.in

The Official Publication of Indian Association of Oral and Maxillofacial Pathologists

Medknow

Pub Med

 Wolters Kluwer

CASE REPORT

Epithelioid hemangioendothelioma of the mandibular gingiva: A rare case of metastasis 4 years after radical excision and literature review

Attilio Carlo Salgarelli, Pierantonio Bellini, Livia Maccio¹, Giacomo Setti

Department of Head and Neck, Unit of Oral-Maxillofacial Surgery, Modena and Reggio Emilia University, ¹Department of Diagnostic Medicine, Clinical and Health Public, Modena and Reggio Emilia University, Via del Pozzo 71, 41100 Modena, Italy

Address for correspondence:

Prof. Attilio Carlo Salgarelli,
Department of Head and Neck, Unit of
Oral-Maxillofacial Surgery, Modena and Reggio
Emilia University, Via del Pozzo 71,
41100 Modena, Italy.
E-mail: attiliocarlosalgarelli@unimore.it

Received: 18-11-2014

Accepted: 16-02-2016

ABSTRACT

Malignant epithelioid hemangioendothelioma (MEH), or high-risk epithelioid hemangioendothelioma, is a low- to intermediate-grade vascular malignancy. A few cases of MEH have been documented in the head and neck region, including the neck, thyroid gland, larynx and scalp. MEHs are extremely rare in the oral cavity. Only 31 cases of MEH in the oral cavity were described in English literature between 1975 and 2014. Further, only eleven cases were referred to MEH of the maxillary or mandibular gingiva. No gingival MEH metastases have been described in literature. We report a literature review and a case of MEH with a metastatic occurrence 4 years after surgical excision.

Key words: Malignant hemangioendothelioma, mandibular gingiva, vascular tumor

INTRODUCTION

Malignant epithelioid hemangioendothelioma (MEH), or high-risk epithelioid hemangioendothelioma,^[1] is a low-to intermediate-grade vascular malignancy originally described by Weiss and Enzinger in 1982 as a vascular neoplasm of endothelial origin.^[2] Since this original description, epithelioid hemangioendotheliomas have been reported in numerous locations, particularly the lungs, liver, soft tissues, viscera, skin and bone. The World Health Organization describes MEH as an intermediate malignant neoplasm.^[3-5]

A few cases of MEH have been documented in the head and neck region, including the neck, thyroid gland, larynx and scalp.^[1,5,6] MEHs are extremely rare in the oral cavity. Only 31 cases of MEH in the oral cavity were described in the English literature between 1975 and 2013. Further, only 11 cases were referred to MEH of the maxillary or mandibular gingiva [Table 1].

CASE REPORT

A 33-year-old male was referred to our oral and maxillofacial service in 2009 for the evaluation of a lesion on the anterior alveolar mucosa. The lesion extended from right central incisor to first left premolar. The growth site was associated with gingival recession (Miller's Class III) [Figure 1].

A panoramic radiographic review showed radiolucency between lateral incisor and second premolar roots. However, positive results were obtained by cold testing for tooth vitality. Computed tomography scans showed a diffuse cortical bone loss. No signs of radiographic root resorption were detected [Figures 2 and 3]. The patient denied any history of pain or swelling. A tissue punch biopsy was performed by removing two punches of tissue (0.7 cm × 0.5 cm each).

This is an open access article distributed under the terms of the Creative Commons Attribution-NonCommercial-ShareAlike 3.0 License, which allows others to remix, tweak, and build upon the work non-commercially, as long as the author is credited and the new creations are licensed under the identical terms.

For reprints contact: reprints@medknow.com

How to cite this article: Salgarelli AC, Bellini P, Maccio L, Setti G. Epithelioid hemangioendothelioma of the mandibular gingiva: A rare case of metastasis 4 years after radical excision and literature review. J Oral Maxillofac Pathol 2016;20:137-41.

Access this article online

Quick Response Code:



Website:
www.jomfp.in

DOI:
10.4103/0973-029X.180975

Table 1: literature review of malignant epithelioid hemangioendothelioma cases

Author (year) (reference number)	Age	Sex	Location	History and examination	Follow-up
Wesley <i>et al.</i> (1975) ^[1]	18	Female	Mandibular gingiva	Bone resorption	Alive, no disease after 2 years
Ellis and Kratochvil (1986) ^[15]	4	Female	Mandibular gingiva	Tooth mobility, bone resorption	Not available
De Araujo <i>et al.</i> (1987) ^[17]	4	Male	Mandibular gingiva	Ulcerated mass, tooth mobility	Not available
Marrogi <i>et al.</i> (1991) ^[12]	45	Male	Maxillary gingiva	Erythematous lesion (1.5 cm)	Recurrence, 3.6 months
Flaitz <i>et al.</i> (1995) ^[18]	7	Female	Mandibular gingiva	Reddish nontender mass (1.5 cm), tooth mobility, bone destruction	Alive, no disease after 52 months
Chi <i>et al.</i> (2005) ^[8]	28	Female	Maxillary gingiva	Purple mass (0.6 cm)	Alive, no disease after 8 months
Sun <i>et al.</i> (2007) ^[11]	12	Male	Maxillary gingiva	Ulcerated mass (3.0 cm), bony destruction, tooth mobility	Alive, no disease after 6 months
Sun <i>et al.</i> (2007) ^[11]	11	Male	Mandibular gingiva	Painful mass (2.0 cm), bony destruction, tooth mobility	Alive, no disease after 8 years
Mohtasham <i>et al.</i> (2008) ^[20]	9	Male	Maxillary gingiva	Ulcerated reddish swelling (1.0 cm), asymptomatic	Recurrence, 1-year
Gordón-Núñez <i>et al.</i> (2010) ^[21]	17	Female	Mandibular gingiva	Swelling (2.0 cm), pink, exophytic, firm, painless, rapid growth, pediculated, without radiographic appearance, clinical diagnosis of pyogenic granuloma	Alive, no disease at 21 months
Present article (2014)	32	Male	Mandibular gingiva	Mandibular translucency (1.5 cm), cortical bone destruction, soft mucosal formation, gingival recession (Miller's class III), no pain, no swelling	Alive, node metastases after 4 years

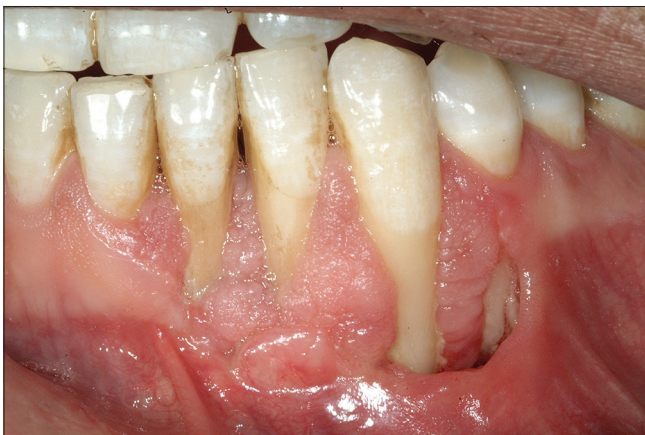

Figure 1: Gingival lesion at first evaluation. Note, the mandibular gingival recession bounded between right central incisor and first left premolar

A microscopic evaluation revealed fragments composed of a proliferation of spindled, ovoid and epithelioid cells arranged in nests, cords and short strands. The neoplastic cells were large and polygonal with abundant granular cytoplasm, nuclear pleomorphism and nuclear hyperchromatism. The lesion exhibited small vascular channels with a moderate cellular inflammatory infiltrate, composed mainly of lymphocytes, plasma cells and eosinophils surrounding the vessels [Figure 4]. Focal mitotic activity (≤ 3 mitotic figures per ten high-power fields) was identified and the Ki-67 score was 20%.

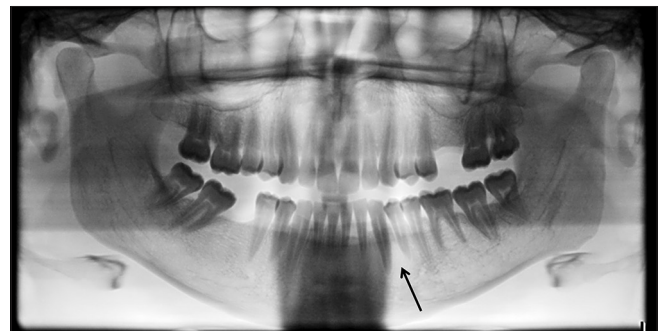


Figure 2: Radiographic findings. Optical projection tomography: Radiolucency was appreciable between the left mandibular canine and first premolar teeth (arrow)

Immunohistochemistry revealed positivity for CD31 and CD34 and negativity for S100, smooth muscle actin, HMB45, CK7, CK20, p63, CD20, CD3 and CD68. Thus, a diagnosis of MEH was made [Figure 4].

Interestingly, no signs of metastasis were detected (cN0) by an investigation of the patient's neck nodes, computed tomography and ultrasonography.

Therefore, anterior mandibular bone excision, including eight teeth and all related soft tissues, was performed under general anesthesia. Below the keratinized mucosa, a deep blue area was markedly visible. A histologic examination

of the lesion confirmed the diagnosis of MEH. Considering the aggressiveness of the disease, wide local excision was performed, with a 10-mm minimum margin of normal tissue. The limits of resection were investigated to ensure clean and safe excision margins. No neck dissection was performed at this time.

Mandibular reconstruction and stabilization were obtained by an iliac bone crest graft fixed with titanium reconstruction plates and screws [Figure 5]. Soft tissue regeneration was guided using proximal flaps. The patient was followed up at 15 days, 1 month, 3 months, 6 months and then every 6 months for 4 years with a clinical investigation of soft tissues, clinical and ultrasonographic evaluations of lymph nodes and radiographic assessment of bone healing. The entire follow-up period was 46 months [Figure 6].

At 4 years after tumor excision, the patient showed lymphatic involvement in the left jugular-digastric and submandibular regions. No fine needle aspiration biopsy was performed because of the certainty of the suspected diagnosis; instead,

surgical excision was performed under general anesthesia. After ultrasonography and computed tomography, a bilateral selective neck dissection was performed and those nodes at levels 1–3 were excised; in addition, the submandibular glands were removed bilaterally with all associated nodes [Figure 7]. Of 86 nodes investigated, three (homolateral IIa neck level) were positive for MEH metastasis.

DISCUSSION

No consistent clinical or histologic criteria for predicting the biologic behavior of MEHs (including increased numbers of mitotic figures or necrosis) have been identified. The lesions exhibit the following histopathologic features: the proliferation of rounded, eosinophilic endothelial cells with frequent cytoplasmic vacuolization, a distinctive epithelioid appearance and growth pattern potentially leading to a mistaken diagnosis of carcinoma, frequent angiocentricity and myxohyaline stroma.^[6-8] However, certain features are believed to be associated with a more aggressive clinical outcome, including significant cellular atypia, mitotic

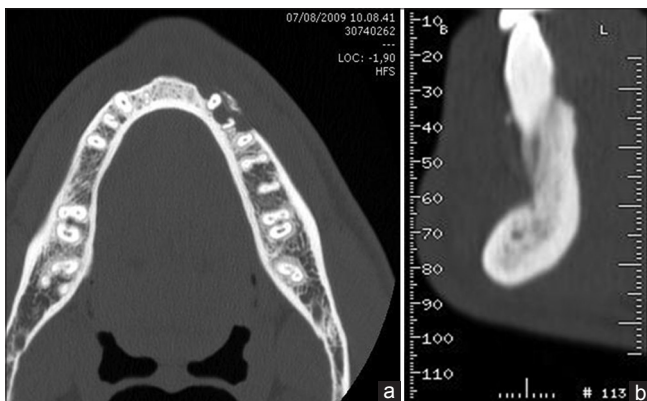


Figure 3: (a) Computed tomography scan (occlusal view) showing buccal cortical bone loss. (b) Computed tomography showing buccal cortical bone loss

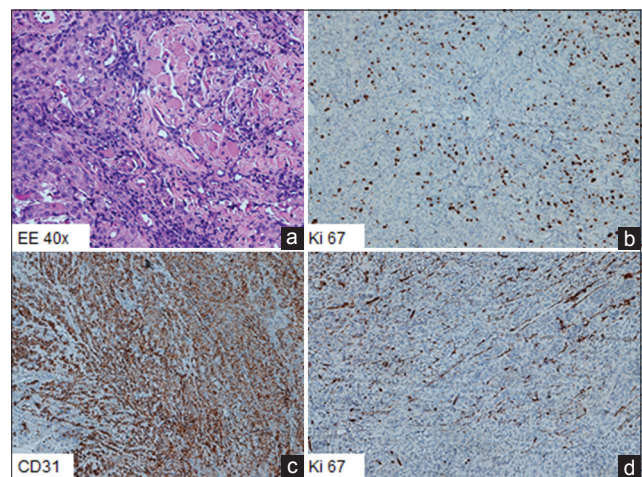


Figure 4: (a) Proliferation of ovoid and fusiform epithelioid cells with nuclear and cellular pleomorphism arranged in nests and cords forming small vascular channels (H&E stain, x100). (b) The Ki-67 index was 20% (IHC stain, x100). The neoplastic cells were positive for (c): CD31 in both stromal and endothelial cells (IHC stain, x100) and (d): CD34 (IHC stain, x100)

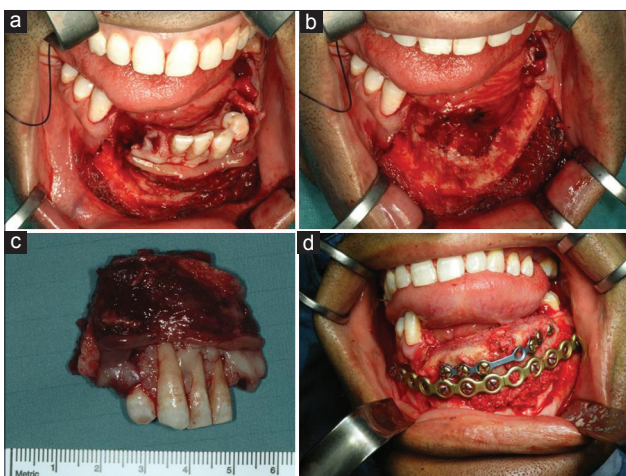


Figure 5: (a-d) Surgical excision and reconstruction of the mandible with an iliac crest bone graft

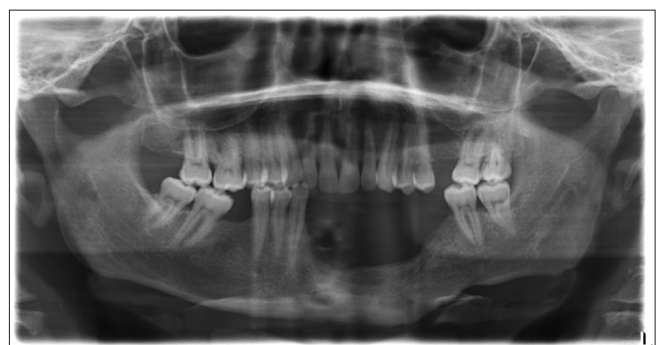

Figure 6: Radiographic findings 4 years after bone reconstruction

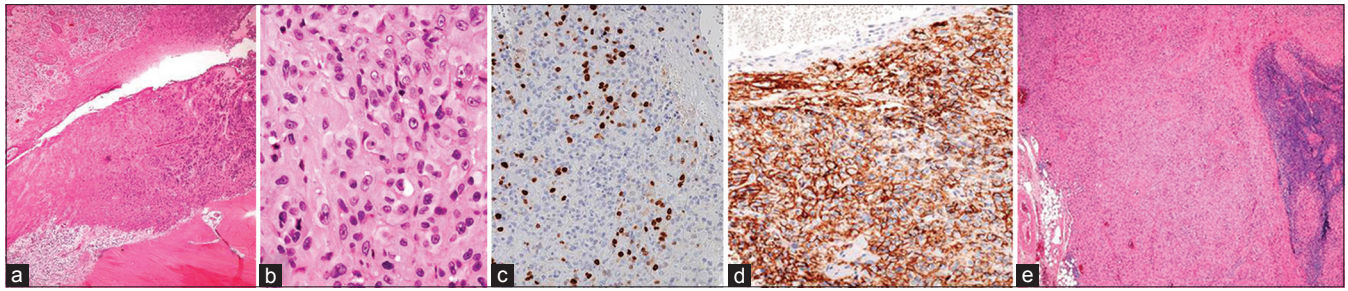


Figure 7: Involvement of bone and mucosa by the malignant cells (a) H&E stain, x40, (b) H&E stain, x400. Cells positive for (c) Ki-67 (IHC stain, x200) and (d) CD 31 (IHC stain, x100). (e) lymph node metastases (H&E stain, x40)

activity $>1/10$ high-power fields, an increased proportion of spindle tumor cells, focal necrosis and metaplastic bone formation.

A higher mortality rate is observed when epithelioid hemangioendotheliomas occur in bone, liver or the lungs.^[9] Because of their predominant morphological characteristics, MEHs can be confused with other lesions, including hemangiomas or squamous cell carcinomas; therefore, the importance of immunohistochemical analyses to establish a definitive diagnosis should be emphasized. In this context, a review of published cases verified that the majority of intraoral epithelioid hemangioendothelioma lesions were immunoreactive for CD34, CD31, factor VIII-Rag and vimentin, which characterize the epithelioid endothelial origin of this entity.^[9] As in the literature review, our immunohistochemical findings indicated that the neoplastic cells were CD34⁺ and CD31⁺.

It was not possible to identify common risk factors for MEH. The literature review indicated a mean age at diagnosis for MEH of 17 ± 13.01 years, suggesting a predisposition to disease in young people. Genetic and molecular investigations to identify genes involved in malignant transformation and metastatic events should be performed in future.^[10-12]

Systemic metastases have been described in the literature at a rate of 21%, and a mortality rate of 17% has been described for cutaneous MEH, in accordance with the histological aspects of the malignancy.^[13,14] In gingival MEH, no metastases have been described in literature before our case report.

Because of the potential malignancy of epithelioid hemangioendotheliomas, wide local excision is the treatment of choice for oral cavity cases according to the literature. Surgeons must look for safe and clean margins; conservative treatment is avoided due to the high rate of recurrence of the disease. Nonetheless, different types of treatment, including chemotherapy and radiotherapy, were proposed without evidence of efficacy.^[7-9,13-21]

According to our review, the mean follow-up period was 30.11 ± 30.29 months (except for two papers in which the follow-up period was not reported/available). The mean

recurrence time was 21.33 ± 23.44 months. Given the possibility of recurrence and metastasis several years after clean and safe excision, clinicians should apply an adequate follow-up period for this malignancy (at least 5 years).

CONCLUSION

Epithelioid hemangioendotheliomas have unpredictable behavior and accordingly with literature, when histology clearly address to a malignant type, clean and safe excision and investigation for metastases are mandatory.

To improve diagnosis, execution of sentinel node biopsy through lymphoscintigraphy in MEH cN0 cases could be performed; specimen sub-serialiation and monoclonal antibody marking would help in micrometastases recognition.

Financial support and sponsorship

Nil.

Conflicts of interest

There are no conflicts of interest.

REFERENCES

1. Wesley RK, Mintz SM, Wertheimer FW. Primary malignant hemangioendothelioma of the gingiva. *Oral Surg Oral Med Oral Pathol* 1975;39: 103–112.
2. Weiss SW, Enzinger FM. Epithelioid hemangioendothelioma: A vascular tumor often mistaken for a carcinoma. *Cancer* 1982;50:970-81.
3. Fletcher CD, Bridge JA, Hogendoorn P, Mertens F. WHO Classification of Tumours of Soft Tissue and Bone. World Health Organization; 4 edition, vol 5. Lyon, IARC; 2013.
4. Makhlof HR, Ishak KG, Goodman ZD. Epithelioid hemangioendothelioma of the liver: A clinicopathologic study of 137 cases. *Cancer* 1999;85:562-82.
5. Mentzel T, Beham A, Calonje E, Katenkamp D, Fletcher CD. Epithelioid hemangioendothelioma of skin and soft tissues: Clinicopathologic and immunohistochemical study of 30 cases. *Am J Surg Pathol* 1997;21:363-74.
6. Pigadas N, Mohamid W, McDermott P. Epithelioid hemangioendothelioma of the parotid salivary gland. *Oral Surg Oral Med Oral Pathol Oral Radiol Endod* 2000;89:730-8.

7. Amin KS, McGuff HS, Cashman SW, Otto RA. Epithelioid hemangioendothelioma of the parotid gland with atypical features. *Otolaryngol Head Neck Surg* 2003;129:596-8.
8. Chi AC, Weathers DR, Folpe AL, Dunlap DT, Rasenberger K, Neville BW. Epithelioid hemangioendothelioma of the oral cavity: Report of two cases and review of the literature. *Oral Surg Oral Med Oral Pathol Oral Radiol Endod* 2005;100:717-24.
9. Goldblum JR, Weiss SW, Folpe AL. *Enzinger and Weiss's Soft Tissue Tumors*. 6th ed. Elsevier Saunders, Philadelphia; 2014.
10. Orsini G, Fioroni M, Rubini C, Piattelli A. Epithelioid hemangioendothelioma of the oral cavity: Report of case. *J Oral Maxillofac Surg* 2001;59:334-7.
11. Sun ZJ, Zhang L, Zhang WF, Chen XM, Lai FM, Zhao YF. Epithelioid hemangioendothelioma of the oral cavity. *Oral Dis* 2007;13:244-50.
12. Marrogi AJ, Boyd D, el-Mofty S, Waldron C. Epithelioid hemangioendothelioma of the oral cavity: Report of two cases and review of literature. *J Oral Maxillofac Surg* 1991;49:633-638.
13. Requena L, Kutzner H. Hemangioendothelioma. *Semin Diagn Pathol* 2013;30:29-44.
14. Requena L, Luis Díaz J, Manzarbeitia F, Carrillo R, Fernández-Herrera J, Kutzner H. Cutaneous composite hemangioendothelioma with satellitosis and lymph node metastases. *J Cutan Pathol* 2008;35:225-30.
15. Ellis GL, Kratochvil FJ 3rd. Epithelioid hemangioendothelioma of the head and neck: A clinicopathologic report of twelve cases. *Oral Surg Oral Med Oral Pathol* 1986;61:61-8.
16. Ramer MA, Lumerman H, Kopp W, Fisher KS, Cohen SA. Epithelioid hemangioendothelioma of the maxilla: Case report and review of literature. *Periodontal Clin Investig* 2001;23:31-5.
17. de Araújo VC, Marcucci G, Sesso A, de Araújo NS. Epithelioid hemangioendothelioma of the gingiva: Case report and ultrastructural study. *Oral Surg Oral Med Oral Pathol* 1987;63:472-7.
18. Flaitz CM, McDaniel RK, Mackay B, Kennady MC, Luna MA, Hicks MJ. Primary intraoral epithelioid hemangioendothelioma presenting in childhood: Review of the literature and case report. *Ultrastruct Pathol* 1995;19:275-9.
19. Ebo CM, de Boever JA, Adriaens PA, Roels H. Hemangioendothelioma of the gingiva. Histopathologic and therapeutic considerations. *J Clin Periodontol* 1986;13:11-8.
20. Mohtasham N, Kharrazi AA, Jamshidi S, Jafarzadeh H. Epithelioid hemangioendothelioma of the oral cavity: A case report. *J Oral Sci* 2008;50:219-
21. Gordón-Núñez MA, Silva EM, Lopes MF, de Oliveira-Neto SF, Maia AP, Galvão HC. Intraoral epithelioid hemangioendothelioma: A case report and review of the literature. *Med Oral Patol Oral Cir Bucal* 2010;15:e340-6.