

# Treatment of Ewing Sarcoma, Paediatric Bone Sarcomas and Severe Paediatric Spinal Deformities in Finland

Joni Serlo

ACADEMIC DISSERTATION

To be presented, with the permission of the Faculty of Medicine of the University of Helsinki, for public examination in the main lecture hall of the Comprehensive Cancer Center, Helsinki, on 26<sup>th</sup> May 2017, at 12 noon.

Comprehensive Cancer Center, Helsinki University Hospital and University of Helsinki, Finland

Department of Paediatric Orthopaedic Surgery, Turku University Hospital and University of Turku, Finland

Supervisors	Professor Ilkka Helenius Department of Paediatric Orthopaedic Surgery, University of Turku and Turku University Hospital, Turku, Finland
	Docent Maija Tarkkanen Comprehensive Cancer Center Helsinki University Hospital, and University of Helsinki, Finland
Reviewers	Docent Minna Laitinen Department of Orthopaedic Surgery, Tampere University Hospital, Tampere, Finland
	Docent Olli Lohi Department of Paediatric Haematology and Oncology Tampere University Hospital, Tampere, Finland
Opponent	Professor Hannu Aro Department of Orthopaedic Surgery, Turku University Hospital, Turku, Finland

Language edited by Carol Ann Pelli, University of Helsinki Language Services

Anatomical drawings by Helena Schmidt

Unigrafia, yliopistopaino Helsinki 2017

ISBN 978-951-51-2900-0 (paperback)

ISBN 978-951-51-2901-7 (PDF)

<http://ethesis.helsinki.fi>

## LIST OF ORIGINAL PUBLICATIONS

This thesis is based on the following publications:

- I Serlo J, Helenius I, Sampo M, Vettenranta K, Saarinen-Pihkala U M, Kivivuori S-M, Riikonen P, Kivioja A, Böhling T, Kallajoki M, Ristimäki A, Vasama K, Tarkkanen M. Ewing's sarcoma family of tumors in Finland during 1990-2009: a population-based study. *Acta Oncol.* 2013 May;52(4):767-75
- II Serlo J, Helenius I, Vettenranta K, Perkkiö M, Riikonen P, Sampo M, Tarkkanen M. Surgically treated patients with axial and peripheral Ewing's sarcoma family of tumours: A population based study in Finland during 1990-2009. *Eur J Surg Oncol.* 2015 Jul;41(7):893-8
- III Serlo J, Tarkkanen M, Sampo M, Vettenranta K, Riikonen P, Helenius I. Incidence, treatment and survival of paediatric patients with bone sarcomas in Finland from 1991 to 2005. *Acta Paediatr.* 2015 Jul;104(7):738-45
- IV Helenius I, Serlo J, Pajulo O. The incidence and outcomes of vertebral column resection in paediatric patients: a population-based, multicentre, follow-up study. *J Bone Joint Surg Br.* 2012 Jul;94(7):950-5

## ABSTRACT

**Background** Ewing sarcomas are rare highly malignant tumours, mainly affecting the paediatric and adolescent population. The prognosis is dismal without therapy, but with modern chemotherapy and local treatment of the primary tumour, most patients are alive at five-year follow-up. There are not many population-based studies including both bone and soft tissue tumours, even though they are basically the same disease. The prognosis is still poor in axial and metastatic disease.

Previous reports have suggested that the incidence of Ewing sarcoma in the paediatric population may be lower in Northern Europe compared to other parts of Europe and the United States. The prognosis of paediatric patients with bone sarcoma are nowadays generally good, but particularly in osteosarcoma, the prognostic effect of age is somewhat unclear.

The surgical techniques of vertebral column resections, including those used for resection of malignant spinal tumours have evolved, with the invention of techniques using only a posterior approach. There are still not many reports that compare the anteroposterior approach to posterior-only approach.

**Aims** Our aim in this study was to find out how the treatment of Ewing sarcoma is carried out in Finland and to find out what are the five-year overall- and event-free survival rates and to find possible prognostic factors. Another aim of the study was to reveal the surgical treatment and its complications, particularly of axial tumours. We also aimed at establishing the incidence rates of Ewing sarcoma and other bone sarcomas in the paediatric and adolescent population in Finland and to establish the ten-year survival rates. Additionally, we aimed to report the results of a population-based material on paediatric vertebral column resection including patients operated via anteroposterior and posterior-only approach.

**Material and methods** We identified all Finnish patients with Ewing sarcoma diagnosed during 1990-2009, all paediatric bone sarcoma patients diagnosed during 1991-2005 and all paediatric patients who underwent vertebral column resection during 2005-2009. The medical records were reviewed for detailed information on the disease, treatments, treatment complications and outcome and these data were analysed. The study is retrospective, nationwide and population-based.

**Results** Seventy-six Ewing sarcoma patients with a median age of 17.8 years and a 2:1 male to female ratio were included in the final analyses of study I. Nineteen had a metastatic disease. The five-year sarcoma-specific survival rates were 70% for those with localized and 33% for those with metastatic disease ( $p=0.001$ ). Older age ( $p=0.031$ ), axial site of the primary tumour ( $p=0.016$ ) and not receiving surgery with adequate margins for the primary tumour ( $p=0.033$ ) were associated with impaired five-year sarcoma specific survival in univariate analyses.

Fifty-seven patients underwent surgical treatment of the primary tumour. Eleven patients had early and 14 had late surgical complications, most of the late complications involving reconstructions of bone deficiencies. Five-year local-relapse free survival was significantly better with surgical resection margins free of tumour cells (84% vs. 33% with contaminated margins,  $p=0.003$ ).

The annual incidence rates of osteosarcoma, Ewing sarcoma and chondrosarcoma per million 0-18-year-old people in Finland during 1991-2005 were 3.6, 1.2 and 0.3, respectively. The patients with Ewing sarcoma were younger than those with osteosarcoma (median age in years 12.0 vs. 14.2,  $p=0.012$ ) and more often had axial tumours (57% vs. 11%,  $p<0.001$ ). The ten-year overall survival was 74% for osteosarcoma, 76% for Ewing sarcoma and 80% for chondrosarcoma.

Between seven patients with paediatric spinal deformity that underwent vertebral column via anteroposterior approach and seven operated via posterolateral approach, there were no differences in

the mean final radiological corrections (54% vs. 60%, respectively,  $p=0.53$ ), estimated blood loss (3082ml vs. 2329ml,  $p=0.59$ ) or the mean quality-of-life results (SRS-24 scores 100 vs 102,  $p=0.72$ ). The mean operative time was shorter with posterolateral approach than with anteroposterior approach (5h30min vs. 7h54min, respectively,  $p=0.002$ ).

**Conclusions** Our study was the first report of population-based outcomes of Ewing sarcoma treatment in Finland and the first to report quality-of-life results of vertebral column resections in paediatric patients. We found that the outcomes in the treatment of Ewing sarcoma in Finland are comparable to previously reported European and American outcomes. High-dose chemotherapy may be beneficial in metastatic and high-risk Ewing sarcoma but randomised controlled studies are needed. We conclude that the incidence of osteosarcoma and chondrosarcoma in paediatric population in Finland is essentially the same as in other parts of Europe and the United states, but the incidence of Ewing sarcoma seems a bit lower. The outcomes of treatment of paediatric bone sarcoma patients in Finland are good. We also found that posterior-only approach in paediatric vertebral column resections in Finland carry comparable results to anteroposterior approach but the operation time is reduced and that estimated blood loss may also be reduced but larger studies are needed to confirm this.

## TABLE OF CONTENTS

LIST OF ORIGINAL PUBLICATIONS.....	iii
ABSTRACT.....	iv
ABBREVIATIONS.....	7
1. INTRODUCTION.....	8
2. REVIEW OF THE LITERATURE.....	9
2.1 Ewing sarcoma.....	9
2.1.1 Nomenclature and source materials.....	9
2.1.2 History.....	9
2.1.3 Genetic alterations in Ewing sarcoma.....	10
2.1.4 Epidemiology.....	10
2.1.5 Clinical presentation.....	11
2.1.6 Diagnosis.....	12
2.1.7 Prognosis and prognostic factors.....	13
2.1.8 Systemic treatment and treatment-related complications.....	15
2.1.9 Local treatment of primary tumour and treatment-related complications.....	17
2.2 Other bone sarcomas in children.....	20
2.2.1 Epidemiology.....	20
2.2.2 Treatment of bone sarcomas other than Ewing sarcoma in children.....	21
2.2.3 Prognosis and prognostic factors.....	22
2.3 Vertebral column resection and surgical treatment of spinal tumours.....	23
2.3.1 Spinal tumours.....	23
2.3.2 History of vertebral resections and results in correcting deformities.....	23
2.3.4 Role of surgery in treatment of malignant tumours of the spine.....	25
3. AIMS OF THE STUDY.....	28
4. MATERIALS AND METHODS.....	29
5. RESULTS.....	30
5.1 Treatment, survival and prognostic factors in bone and soft tissue Ewing sarcoma in Finland during 1990-2009 (Study I).....	30
5.2 Surgical treatment, its complications and survival of patients with axial and peripheral bone and soft tissue Ewing sarcoma in Finland during 2000-2009 (Study II).....	32
5.3 Incidence, treatment, survival and prognostic factors in paediatric and adolescent patients with bone sarcoma in Finland during 1991-2005 (Study III).....	32
5.4 Incidence, radiological and clinical outcomes of vertebral column resection for paediatric spinal deformity (study IV).....	35
6. DISCUSSION.....	37
6.1 Treatment and outcome of patients with bone and soft tissue ES in Finland during 1990-2009. Surgical treatment of patients with axial and peripheral ES (Studies I and II).....	37
6.2 Incidence of paediatric bone sarcoma in Finland during 1991-2005. Ten-year survival rates and prognostic factors (Study III).....	39
6.3 Clinical, radiological and quality of life results of vertebral column resection for paediatric spinal deformity (Study IV).....	40
7. CONCLUSIONS.....	42
ACKNOWLEDGEMENTS.....	43
REFERENCES.....	45
ORIGINAL PUBLICATIONS.....	62

## ABBREVIATIONS

ACCIS	Automated Childhood Cancer Information System
AJCC	the American Joint Committee on Cancer
AP	Anteroposterior
CI	Confidence interval
CS	Chondrosarcoma
CT	Computed tomography
CTC	Common toxicity criteria
ES	Ewing sarcoma
ESB	Ewing sarcoma of bone
EFS	Event-free survival
ESFT	Ewing sarcoma family of tumours
ESMO	The European Society of Medical Oncology
FDG	Fluorodeoxyglucose ( <sup>18</sup> F)
FISH	Fluorescence in situ hybridisation
HDCT	High-dose chemotherapy
HR	Hazard ratio
LSS	Limb-sparing surgery
MRI	Magnetic resonance imaging
OAS	Overall survival
OR	Odds ratio
OS	Osteosarcoma
PCR	Polymerase chain reaction
PET	Positron emission tomography
PL	Posterolateral
pPNET	Peripheral primitive neuroectodermal tumour
RCT	Randomized controlled trial
RFS	Relapse-free survival
RT	Radiation therapy
RT PCR	Reverse transcription polymerase chain reaction
SEER	Surveillance, Epidemiology, and End Results database
TES	Total en bloc spondylectomy
TLI	Total lung irradiation
TNM	A cancer staging notation system based on the extent of the tumor (T), the extent of spread to the lymph nodes (N), and the presence of metastasis (M).
VCR	Vertebral column resection
WHO	World Health Organization

## 1. INTRODUCTION

Ewing sarcomas (ESs), also called Ewing sarcoma family of tumours (ESFT), are highly malignant, rare tumours of the bone and soft tissue. The group includes the formerly distinct tumours of classical Ewing sarcoma of bone (ESB), extraskeletal Ewing sarcoma, peripheral primitive neuroectodermal tumour (pPNET), Askin tumour (Ewing sarcoma of the thoracic wall), and atypical Ewing sarcomas. Tumours of the group were long considered to be different tumours based on their anatomical and histological appearance. After the recognition of their common genetic basis, it has become evident that these tumours form a uniform entity.

Population-based data on ES, particularly other than classical ESB, are scarce. The reports are still most commonly limited either to bone or soft tissue tumours or to their anatomical location. This may be reasonable from a clinical point of view since tumour location is a key factor influencing the choice of optimal local therapy. The systemic treatment, however, does not differ with bone and soft tissue ES. As reports on possible differences in outcome of bone and soft tissue ES are controversial (Applebaum et al. 2011, Pradhan et al. 2011), new population-based reports including all ESs, whether arising in bone or soft tissue, are valuable. One of the topics of interest in clinical ES research is local treatment of the primary tumour, particularly in axially locating tumours.

Some bone sarcomas are more common in old age, but those arising in the young have the most significant effect on life expectancy and quality of life of long-term survivors. Bone sarcomas have a bimodal age distribution (Hung et al. 2014, Whelan et al. 2012a), with the first incidence peak in the age group 15-19 years, with approximately 5 new tumours per million inhabitants in Europe (Stiller et al. 2006a, Whelan et al. 2012a). The incidence increases also in older age groups, largely due to a gradual increase in the incidence of chondrosarcoma (Whelan et al. 2012a). Incidence reports are register-based and some uncertainty in the accuracy of the diagnoses reported to the registers is to be expected. Earlier, surgery was the sole treatment and the children and adolescents with bone sarcoma had long-term survival rates of 10-20% (Boyer et al. 1967, Dahlin et al. 1961, Marcove et al. 1970). The five-year survival of patients has improved dramatically with the development of effective multidisciplinary treatment including chemotherapy. Stiller et al. (2006a) reported an improvement in the five-year survival from 37% to 63% for paediatric and adolescent patients diagnosed in Europe in the time periods 1978-1982 and 1993-1997, respectively. After the beginning of the 1990s there has been little or no progress in the five-year survival rates (Gatta et al. 2014, Stiller 2006a, Trama et al. 2016, Whelan 2012a).

A total en bloc spondylectomy (TES) is practically the only possibility to achieve adequate surgical margins in malignant bone tumours involving the mobile spine. The techniques for vertebral column resection (VCR), including TES, have developed in the last decades. With the new techniques taken into clinical practice worldwide, the results should be carefully analysed and reported. The VCR operation carries a risk for severe complications, including total spinal cord injury, and critical retrospective analyses are of the utmost importance.

We started this study to gather nationwide, population based data on Finnish patients with bone or soft tissue ES. There are no previous reports on survival of Finnish ES patients or their treatment regimes. We also wanted to investigate the role of surgery in the treatment of axial ES. Further, we aimed at establishing accurate incidence rates for bone sarcoma in Finnish paediatric and adolescent populations and at identifying their 10-year survival rates. Finally, we report the results of a nationwide data of paediatric patients undergoing VCR with half of the patients operated on using a posterior-only approach, representing a development in surgical technique.



## 2. REVIEW OF THE LITERATURE

### 2.1 Ewing sarcoma

#### 2.1.1 Nomenclature and source materials

Significant variation exists in the nomenclature of ES in the literature. Sometimes the term “Ewing sarcoma” is meant to include all ESs and sometimes only bone tumours. “Extraskeletal ES” is sometimes used as a synonym for soft tissue ES, but sometimes it does not include pPNET or Askin tumour. The term “Ewing sarcoma family tumours” has been used to cover all types of ES. “Ewing family tumours” and “Ewing tumours” are also used for this purpose. The World Health Organisation (WHO) supports the term “Ewing sarcoma” for the whole group in its newest classification of bone and soft tissue tumours (Fletcher et al. 2013).

Because of the rarity of ES, large, population-based data are needed for research. Probably the largest source database for population based cancer reports is the US Surveillance, Epidemiology, and End-point Register (SEER) with an estimated coverage of 30% of the US population (Mukherjee et al. 2013). The vast SEER-based data do not cover all ESs. Part of the studies exclude patients based on their age (Applebaum et al. 2011, Esiashvili et al. 2008, Worch et al. 2010) and some do not include all soft tissue or even all bone ESs (Jawad et al. 2009, Lee et al. 2010). The same is true for many of the large studies from Europe and Asia (Cotterill et al. 2000, Gatta et al. 2014, Obata et al. 2007, Stiller et al. 2006a, Trama et al. 2016). Comparison of the reports is also hindered by the different types of survival rates reported. Some studies only report overall or disease-specific survival (Esiashvili et al. 2008, Lee et al. 2010, Stiller et al. 2006a), while others report only relapse-free survival (Cotterill et al. 2000).

#### 2.1.2 History

Peripheral PNET, originally described by Arthur Stout (1918) as a small round cell tumour of the ulnar nerve, and Ewing sarcoma, originally described as diffuse endothelioma of bone by James Ewing (1921), were long considered different entities belonging to the group of so-called small round cell tumours. Similar tumours were found in extraskeletal locations (Angervall & Enzinger 1975) and in the chest wall (Askin et al. 1979). Differential diagnosis between small round cell tumours was challenging as microscopy was the main diagnostic tool. Differing clinical appearance and certain immunohistochemical characteristics, such as positivity for CD99, grouped these tumours together and apart from other small round cell tumours. The distinction between different soft tissue ES, mainly extraskeletal and pPNET, was based on the level of neural differentiation. The development of molecular genetics and the recognition of the specific chromosomal translocation in ES (Turc-Carel et al. 1984 and 1988) lead to the acknowledgement of ES, including also pPNET, as a distinct group of tumours (deLattre et al. 1994).

Until the late 1960s the state-of-art treatment of ES in the extremities was amputation. Before the era of systemic chemotherapy for ES Boyer et al. (1967) stated that since ESB could not be cured by radical surgery and radiation therapy (RT) resulted in comparable local control, surgery should not be used. This resulted in a paradigm shift towards RT, but survival continued to be poor and optimal local therapy has undergone much debate since Boyer’s report. The first retrospective reports of a possible beneficial effect of surgery (Pritchard et al. 1975) were arguable at best, but questioned the diminished role of surgery. Extraskeletal tumours were still commonly operated (Angervall & Enzinger 1975). The real progress in the treatment of ES started when Hustu et al. (1972) reported extraordinary survival of 12 patients treated with RT combined with systemic therapy of vincristine and cyclophosphamide. Chemotherapy has since been the key to curative treatment and the prognosis has improved along with the onset of new chemotherapy regimens validated in prospective clinical trials.

### 2.1.3 Genetic alterations in Ewing sarcoma

Ewing sarcomas are genetically characterized by specific translocations that involve the *EWSR1* gene, encoding the protein EWS, in chromosome band 22q12 fusing with one of the genes in the ETS family. The most common of these is *FLI1* in chromosome band 11q24, found in about 85% of the tumours (Turc-Carel et al. 1988). The next ETS genes reported in ES were *ERG* (Sorensen et al. 1994) and *ETV1* (Jeon et al. 1995). There are other, less frequent ETS genes associated with ES and in rare occasions the fusion includes FUS instead of EWS (Lawlor & Sorensen 2015, Shing et al. 2003). FUS, like EWS, is a member of the FET family of RNA-binding proteins, aberrations of which are also seen in other types of cancer (Kovar 2011). Despite the relatively few different somatic mutations encountered in ES, there is significant epigenetic inter- and intratumour heterogeneity that may correlate with the clinicopathological heterogeneity in ES (Sheffield et al. 2017).

The ETS family genes normally act as transcription regulators (Sharrocks 2001). The t(11;22)(q24q12) fusion gene codes a fusion EWS-FLI1 protein that functions as an active transcription activator (Baillly et al. 1994). The DNA binding and transcription regulation of the fusion proteins seem to depend on GGAA microsatellites (Monument et al. 2012). As the other target genes of the ETS family act as transcription factors much like FLI1, all of the fusion proteins probably have a similar, critical role in tumorigenesis (deAlava & Gerald 2000). EWS-ETS proteins also modulate gene and protein expression through non-transcriptional mechanisms, e.g. by epigenetic deregulation, disrupting RNA splicing and abnormal expression and regulation of microRNA (Lawlor & Sorensen 2015).

Additional frequent chromosomal abnormalities in ES include gains of chromosomes 8, 12 and 1q (Armengol et al. 1997, Lawlor & Sorensen 2015). Other genetic alterations sometimes seen include those in the genes of the p53 and retinoblastoma (RB) tumour suppressor pathways (Randall et al. 2010). Alterations of *p53* are found in approximately 10% of all ESs and homozygous deletions in *p16/p14ARF* in slightly less than 20% (Huang et al. 2005). The same gene encodes for both p16 and p14ARF, the latter resulting from alternative splicing (ARF for alternative reading frame) (Quelle et al. 1995). While p16 affects the RB pathway, p14ARF acts mainly through the p53 pathway.

### 2.1.4 Epidemiology

Ewing sarcoma is most commonly a tumour of bone and the incidence of ES of bone (ESB) in Europe has been reported to peak in the age group 15-19 years, at approximately 5 per million annually (Stiller et al. 2006a, Whelan et al. 2012a). The reported annual incidence in the US for patients aged 0- 19 years old is about 3 per million, including ES of bone and soft tissue (Esiashvili et al. 2008). Only 6% of the 906 patients were aged 0-4 years. Based on these data ES can be thought of as tumours of youth. Nevertheless, according to a population-based study including both bone and soft tissue tumours and patients of all ages a substantial proportion of ESs arise in the adult population (Lee et al. 2010). In a single-centre report by Pradhan et al. (2011), the age of patients ranged between 1 and 71 years. Extraskelatal sites seem to become more frequent with older age at diagnosis (Applebaum et al. 2011, Pradhan et al. 2011). Males have a 1.5-fold risk compared with females (Lee et al. 2010, Whelan et al. 2012a). There is no evident difference in childhood, but the incidence peak of ESB among males at 15 years of age is much higher than in females (Stiller et al. 2006a) and the difference remains throughout adulthood (Lee et al. 2010, Whelan et al. 2012a). Based on incidence curves and some case-control studies (Cotterill et al. 2004) ES of bone seemst to be associated with bone growth. The earlier incidence peak in females is probably related to the earlier onset of the pubertal growth spurt and the higher peak in males to the greater magnitude of growth.

Ewing sarcomas are extremely rare in East Asia and Africa (Stiller 2007). This cannot be explained entirely by factors other than race. The rarity among the black population has been confirmed in a SEER report (Jawad et al. 2009), where the incidence was shown to be nine times higher in Caucasians than in African Americans. Israeli Jews seem to have a strikingly high incidence in the adolescent population. Their annual incidence of ESB was 17.0 and 6.3 per million males and females aged 15-19 years, respectively, while

Israeli non-Jews of the same age had an incidence of 3.4-3.5 per million (Stiller 2007). There is also evidence of differences in the incidence in other white populations; an ACCIS-based report stated ESB incidence to be lower in Northern European countries than in other parts of Europe (Stiller et al. 2006a). In addition to differences in incidence, there seem to be racial differences in clinicopathological characteristics. For example, extraskeletal sites are clearly more common in black and somewhat more frequent in Asian and Hispanic populations than in white non-Hispanics (Worch et al. 2010).

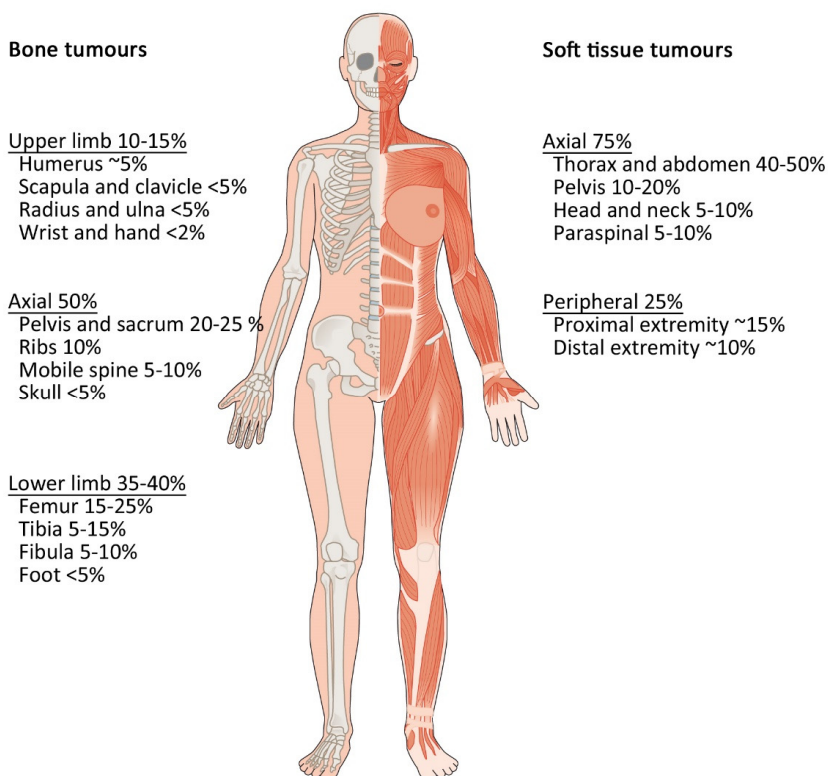
Winn et al.(1992) were the first to describe the association between umbilical and inguinal hernias and ES of bone. Their results also hinted that parental farming and smoking might be related to an increased risk. Some later reports show no association between parental smoking and bone sarcoma (Schuz et al. 1999). The correlations to hernias and parental farming, however, have been supported by more recent reports and meta-analyses (Valery et al. 2005a, Valery et al. 2005b). The authors also suggest parental farming as a common aetiological factor for both hernias and ES. The causality of these findings is unclear (Eyre et al. 2009a). Other factors linked to ESB include paternal occupation in social sciences and maternal occupation as teachers (Hum et al. 1998) and low birth weight (Hartley et al. 1988), but the evidence is too weak to draw any conclusions (Burningham et al. 2012). Contrary to what the association with race and hernia risk would suggest, no genetic predisposition to ES has been found (Randall et al. 2010). Because of the rarity of ES, establishing firm correlations and causality to these and other potential factors is challenging.

### 2.1.5 Clinical presentation

As ES can arise in practically any anatomical location, the symptoms and clinical presentations have vast variation. The most common symptoms are pain and a palpable mass (Brasme 2014, Widhe & Widhe 2000). Widhe and Widhe (2000) report other common findings at the first medical visit to include restricted joint movement and fever, both encountered in approximately 30% of patients with ESB. The most alarming and often present symptoms in tumours situated in the spine or paraspinal region are neurological (Boriani et al. 2011, Harimaya et al. 2003). Forty percent of patients with tumours of the pelvis or lower limbs limp (Widhe & Widhe 2000). Only 19% of patients in the material of Widhe and Widhe were suspected to suffer from a bone tumour based on their first medical visit, most of which were to a general practitioner, and the mean total diagnostic delay from onset of symptoms to diagnostic biopsy was 34 weeks (range 3-150 weeks). Diagnostic delay has been reported to vary from a median of 10 weeks to 5.7 months (Brasme 2014, Goyal et al. 2004, Pollock et al. 1991, Widhe et al. 2007). The diagnostic delay does not seem to affect survival (Brasme 2014, Goyal et al. 2004).

Thirty-one percent of patients with ES had extraskeletal tumours in a population-based study by Applebaum et al. (2011). Soft tissue tumours were more common in patients aged under 5 years or over 35 years. Pradhan et al. (2011) reported extraskeletal sites to be more common in older patients. Axial locations are much more common in soft tissue ES than in ESB (**Figure 1**) (Applebaum et al. 2011, Cash et al. 2016, El Weshi et al. 2010). Tumours are more often seen in lower than upper limbs with the femur being the most frequent bone involved (Cotterill et al. 2000). When located in a long bone such as the femur, tibia or humerus, approximately 90% of tumours arise in the meta-diaphyseal or diaphyseal region (Reinus & Gilula 1984).

About 25%-35% of the tumours have metastasised at presentation (Esiashvili et al. 2008, Lee et al. 2010, Pradhan et al. 2011). The metastases are situated in the lungs in one-third, in bone or bone marrow in another third and in both these combined in 20% of patients (Paulussen et al. 1998). The disease is thought to be systemic even if no clinical metastases are detected. More than 30% of patients with a primarily non-metastatic disease may have tumour cells in circulating blood or bone marrow detectable with RT-PCR (Peter et al. 1995).



**Figure 1** Anatomical distribution of bone and soft tissue Ewing sarcomas (Applebaum et al. 2011, Cash et al. 2016, Cotterill et al. 2000, El-Weshi et al. 2010, Pradhan et al. 2011, Whelan et al. 2012a).

### 2.1.6 Diagnosis

The most common first imaging study is a native radiograph in ESB. The radiographs usually show a tumour with poor margins, bone destruction with a 'moth-eaten', permeative pattern in approximately 80% and a soft tissue component in 56-80% (Murphey et al. 2013). Other common findings include laminated (onion skin) periosteal reaction, lytic and/or sclerotic component, spiculated periosteal reaction and Codman triangle; pathologic fracture is uncommon (Peersman et al. 2007, Reinus & Gilula 1984). The gold standard in the imaging of bone and soft tissue tumours is magnetic resonance imaging (MRI) and practically all patients with suspected ES undergo MRI. Typical MRI findings in ESB include bone marrow replacement, cortical destruction and an adjacent soft tissue mass (Murphey et al. 2013). MRI is superior to computed tomography (CT) in the assessment of the soft tissue component, intramedullary extension and possible skip metastases (Aisen et al. 1986, Bloem et al. 1988, Frouge et al. 1988). It is the only study to reliably determine the borders of soft tissue tumours (Murphey et al. 2013, Perouli et al. 2006).

The diagnosis is confirmed with a biopsy, which should be taken in the facility responsible for the definitive local therapy. The biopsy can be obtained by fine-needle aspiration, core needle biopsy or open incisional biopsy. Open biopsy, resulting in an ample tissue sample received in straight visualisation of the tumour, is the gold standard in bone and soft tissue tumour diagnostics, although it is more invasive and costly than percutaneous biopsies (Skrzynski et al. 1996). Core needle biopsy is less invasive, but needs radiological guidance, usually by CT. Some authors consider ultra-sound-guided fine-needle aspiration combined with appropriate molecular genetic and/or immunohistochemical studies to be sufficiently sensitive and specific (Brosjö & Bauer 2004, Fröstad et al. 2002, Klijanienko et al. 2012). A recent review by Traina et al. (2015)

reported no statistical differences in the diagnostic value of open biopsy relative to core needle biopsies or fine-needle aspirates. The European Society of Medical Oncology (ESMO) guidelines state that core needle biopsy is often an appropriate alternative for open biopsy but do not suggest fine-needle aspirates (ESMO 2014). If alarming symptoms or a false preoperative diagnosis lead to surgery without correct diagnosis the diagnosis is made from the surgical specimen.

Ewing sarcomas have characteristic histological and immunohistochemical appearance and pathognomonic molecular genetic findings. The common histological findings include small round blue cells with scarce cytoplasm and large nuclei (Klein 2010). Some tumours contain rosette-like structures and necrosis is common. Based on microscopy alone, differential diagnosis from other small round cell tumours e.g. lymphoma and neuroblastoma metastasis is challenging. Immunohistochemistry is a useful tool in differential diagnostics (D’Cruze et al. 2013). Ewing sarcoma shows positivity to CD99 almost uniformly (Klijanienko et al. 2012, Shibuya et al. 2014), making it the most specific marker for ES. It is especially helpful in differentiating neuroblastoma metastasis from ES (Klein 2010). Other small round cell tumours, however, are sometimes CD99-positive, and other, complementary markers have been suggested (D’Cruze et al. 2013, Shibuya et al. 2014). Still, differential diagnostics with mesenchymal chondrosarcoma, round cell variants of rhabdomyosarcoma and small cell osteosarcoma may be challenging by histology and immunohistochemistry alone (Klein 2010). Therefore, molecular genetic techniques have become the key tools in ES diagnostics. The most common techniques include fluorescence in situ hybridization (FISH) and reverse transcriptase PCR (RT-PCR) (Dagher et al. 2001, Ozaki 2015, Slater & Shipley 2007).

The most frequent staging systems for ES include the TNM -classification by the American Joint Committee on Cancer (AJCC, Edge et al. 2009) and the Enneking/Musculoskeletal Tumor Society (MSTS) staging system (Enneking 1980). The staging examinations usually include  $^{99m}\text{Tc}$  bone scan for detection of bone metastases and chest CT for detection of pulmonary metastases (Bielack & Carrle 2008). Fluorodeoxyglucose ( $^{18}\text{F}$ ) positron emission tomography combined with CT (FDG-PET-CT) is superior to bone scan in detection of bone and pulmonary metastases (Treglia et al. 2012, Völker et al. 2007). FDG-PET-CT has been reported to be less sensitive in detecting metastases in the skull (Newman et al. 2013).

Controversy exists concerning the need for bone marrow samples in staging. Some authors advocate that bone marrow samples be taken routinely to detect possible micrometastases (Bielack & Carrle 2008). Some centres do not take bone marrow aspirations, arguing that the result should not influence the treatment (Ludwig 2008). It also seems that imaging studies are at least as sensitive as bone marrow samples in detecting bone marrow metastases, suggesting that bone marrow aspiration as a routine examination is not necessary (Kopp et al. 2015, Newman et al. 2013). On the other hand, patients with clinically localized disease but RT PCR -detectable micrometastases at diagnosis have been reported to have a poor prognosis comparable to that of a clinically metastatic disease (Schleiermacher et al. 2003). The ESMO guidelines suggest bone marrow samples may be studied (ESMO 2014)

### **2.1.7 Prognosis and prognostic factors**

The five-year survival rates with surgery or radiotherapy alone were little more than 10% (Boyer 1967). With modern multimodal chemotherapy, the 5-year survival rates of ES in the latest population-based reports lie between 60% and 70% (Esiashvili et al. 2008, Lee et al. 2010, Stiller et al. 2006a). Many studies have reported similar prognoses for bone and soft tissue ESs (Lee et al. 2010, El Weshi et al. 2010, Pradhan et al. 2011), but a large study from SEER data (Applebaum et al. 2011) suggests otherwise, indicating that patients with soft tissue tumours have a better long-term prognosis. There also seems to be no difference in survival between histological subtypes of pPNET or ESB in bone tumours (Cotterill et al. 2000). The most important negative prognostic factor is metastatic disease at diagnosis (Cotterill et al. 2000, Lee et al. 2010, Pradhan et al. 2011). The site and number of metastases appear critical. Patients with only lung metastases have a better prognosis than those with bone or combined metastases, with five-year OAS rates of 20-30% and 10%-20%, respectively (Cotterill et al. 2000, Pradhan et al. 2011). All large and/or population-based studies have also shown younger patients to fare better (Bacci et al. 2006c, Cotterill et al. 2000, Ferrari et

al. 2011, Grier et al. 2003, Lee et al. 2010, Pradhan et al. 2011, Trama et al. 2016). This may be partly explained by comorbidities, worse access to care, longer delay in presentation, less aggressive treatment etc. among older patients, but age also appears to be an independent prognostic factor (Lee et al. 2010).

The site of the primary tumour is a strong and independent prognostic factor (Cotterill et al. 2000). The five-year OAS of patients with axial tumours is 40%-50%, whereas it is 60%-70% for those with peripheral tumours (Esiashvili et al. 2008, Grier et al. 2003, Pradhan et al. 2011). Paediatric patients with localized pelvic ES have been reported to have a five-year OAS between 40% and 50% (Laitinen et al. 2016). The five-year OAS in ES of the spine, including patients with a metastatic disease, has been reported to be 41% (Mukherjee et al. 2011) and that of paraspinal soft tissue ES may be even worse (Hariamya et al. 2003). A recent report from the Scandinavian Sarcoma Group, however, showed no difference in survival of those with non-metastatic axial or peripheral ES of bone (Zaikova et al. 2015). Large size of the primary tumour has also been associated with poor prognosis, with diameter of 8 cm or volume between 100 ml and 150 ml as a cut-off point (Bacci et al. 2006c, Cotterill et al. 2000, Grier et al. 2003, Lee et al. 2010).

The prognostic effect of tumour response to chemotherapy, according to either the system by Huvos (Huvos 1991) or that by Picci (Picci et al. 1993), is one of the most important prognostic factors (Albergo 2016, Bacci et al. 2002, Bacci et al. 2006c, Elomaa et al. 2000, Oberlin et al. 2001, Picci et al. 1997, Wunder et al. 1998). Poor response has been suggested also to be an even more important negative prognostic factor for local relapse than positive surgical margin (Lin 2007). Thus, modern chemotherapy protocols include intensified treatment arms for those who have poor response to neoadjuvant therapy (Gaspar 2015). Decrease of tumour volume after neoadjuvant therapy correlates to the grade of necrosis induced (Abudu et al. 1999). In those undergoing surgery, the size of the primary tumour may not be as influential as the response to chemotherapy (Oberlin et al. 2001). Elevated levels of serum lactate dehydrogenase have also been related to metastatic disease and poor prognosis in non-metastatic disease (Bacci et al. 1999, Bacci et al. 2006c).

Jawad et al. (2009) reported no difference in survival with respect to ethnic background for ES of bone or soft tissue. Wurch et al. (2010), however, using largely the same data reported significant differences in five-year OAS of blacks (41%) compared with white non-Hispanic patients (52%). The major differences in the study populations included the exclusion of patients aged  $\geq 40$  years and a wider histological scale in the study of Wurch et al., the latter resulting in a larger proportion of patients with soft tissue tumours. In another SEER-based study, Lee et al. (2010) were able to associate Hispanic race with poor prognosis, but also with inferior socio-economic status. The authors claim both as independent negative prognostic factors based on their multivariate analysis. How much of the poor survival in Hispanic patients was explained by possible inferior socioeconomic status is unclear, as their Ewing-specific survival did not differ from that of the other races in multivariate analysis.

The ETS –target of the genetic rearrangement does not seem to impact survival (LeDeley et al. 2010). The presence of additional genetic alterations has also been suggested to have an effect. The results of Huang et al. (2005) showed a strong negative prognostic effect of the presence of p53 mutations. A meta-analysis reported p16 alterations to be an independent risk factor for poor two-year survival, but the only other factor included in the analysis was the presence of metastases (Honoki et al. 2007). It is, however, intriguing to speculate the existence of fundamental, individual genetic differences in aggressiveness among ES. In the future, it may be possible to conduct an individual risk analysis for each patient based on the clinical and genetic profile.

Prognosis after recurrent ES is poor with five-year OAS varying between 10% and 25% (Barker et al. 2005, Ferrari et al. 2015, Rodriguez-Galindo et al. 2002, Stahl et al. 2011). The post-relapse prognosis is better in younger patients (Ferrari et al. 2015), those with strictly local relapses (Rodriguez-Galindo et al. 2002, Stahl et al. 2011), those with late-onset relapses (Bacci et al. 2006b, Barker et al. 2005, Ferrari et al. 2015, Rodriguez-Galindo et al. 2002, Stahl et al. 2011), those with good response to chemotherapy (Bacci et al.

2006b, Barker et al 2005) and those who achieve a second complete remission (Bacci et al. 2006b, Ferrari et al. 2015). Also, the given chemotherapy after relapse seems to affect survival (Rodriguez-Galindo et al. 2002) and HDCT may be beneficial (Barker et al. 2005).

### **2.1.8 Systemic treatment and treatment-related complications**

The modern treatment of ES includes chemotherapy which is administered in a neoadjuvant and adjuvant fashion (Balamuth & Worner 2010, Gaspar et al. 2015, Ludwig 2008, Potratz et al. 2012). The current chemotherapy regimens are the result of collaborative national or international studies (**Table 1**) and combine vincristine (V), doxorubicin (D), cyclophosphamide (C) and/or ifosphamide (I) and etoposide (E) and/or dactinomycin (A) (Bacci et al. 2002, Ferrari et al. 2011, Granowetter et al. 2009, Grier et al. 2003, Kolb et al. 2004, Ladenstein et al. 2010, Le Deley et al. 2014, Luksch et al. 2012, Paulussen et al. 2001a, Paulussen et al. 2008). The current standard therapy is slightly different in North America than in Europe (Gaspar et al. 2015). While VDC + IE according to the INT-0154 protocol (Granowetter et al. 2009) is considered standard therapy in North America, many European centres use VIDE induction chemotherapy according to the Euro-EWING 99 protocol (Juergens et al. 2006). The on-going Euro Ewing 2012 study compares these regimens (Euro Ewing 2012). New agents in large phase III trials in North America and Europe include topotecan and zoledronic acid (Gaspar et al. 2015). Despite the advancements in understanding the molecular and pathognomonic foundation of ES and attempts to develop novel therapeutic strategies targeted at the EWS-ETS fusion, there has yet been no clinically relevant success (Pishas & Lessnick 2016).

While the agents used in standard risk disease have largely remained the same, much of the ongoing and future research is designed to find more effective treatments for high-risk patients and those with metastatic disease. The role of high-dose chemotherapy (HDCT) and autologous stem cell rescue has been debated. There are several reports of improved survival in recurrent, progressing or primary metastatic disease relative to historical data (Burdach et al. 1993, Jahnukainen et al. 2015, Ladenstein et al. 1995, McTiernan et al. 2006). A study comparing HDCT with conventional therapy in recurring ES showed a significantly better five-year OAS in patients who received HDCT than in those who did not (40-42% vs. 10%), but there were substantially more high-risk patients in the conventional therapy group (Rasper et al. 2014). Luksch et al. (2012) reported a five-year OAS of 65% for patients with solitary pulmonary, pleural or bone metastasis receiving HDCT. High-dose chemotherapy has also been described to be beneficial in non-metastatic, poor response disease (Ferrari et al. 2011, Gaspar et al. 2012). Nevertheless, no randomized studies favouring HDCT have been published and reports of HDCT not improving survival also exist (Meyers et al. 2001).

HDCT also carries significant risks for severe toxic complications, so the role of HDCT and indications are still under investigation. The R2-part of the Euro-EWING 99 study randomized patients with large tumours ( $\geq 200$ ml), poor response to primary chemotherapy or pulmonary metastases to receive consolidation therapy either with conventional chemotherapy and total lung irradiation (TLI) if pulmonary metastatic or with HDCT (Juergens et al. 2006). The results have not yet been published. EWING 2008 is an on-going trial randomizing patients of three risk groups to altogether eight treatment arms, three of which include HDCT.

The treatment of primary metastatic disease usually includes standard conventional induction chemotherapy, local therapy of the primary tumour and consolidation therapy with either HDCT or treatment according to a clinical trial (Ladenstein et al. 2010, Luksch et al. 2012, Ewing 2008). Pulmonary metastases can sometimes be treated with surgery (Letourneau et al. 2011) or TLI (Owens et al. 2013). Standard local treatment of the primary tumour is considered advisable in metastatic ES since it has been associated with improved survival (Haeusler et al. 2010); however, a selection bias is possible. The treatment of recurrent disease is versatile with no defined standard treatment (Gaspar et al. 2015). The combinations of topotecan plus cyclophosphamide, temozolomide plus irinotecan and gemcitabine plus docetaxel are under investigation for recurrent disease (Owens et al. 2013, Gaspar et al. 2015).

Table 1 Prospective clinical studies on Ewing sarcoma chemotherapy regimens

Study/protocol (reference)	Years	No. pts	Tumours	Inclusion criteria	Grouping		5-year EFS	P	Comment/conclusion
					Description	n			
<b>SSG IX</b> (Elomaa et al. 2000)	1990-1999	88	B + ST	All ESFTs	Non-metastatic	73	58% <sup>b</sup>		
					Metastatic	15			
<b>CESS 86</b> (Paulussen et al. 2001)	1986-1991	301	B	Non-metastatic	SR	52	49% <sup>c</sup>	0.587	SR: Tumour <100ml and peripheral, others HR. Eight unallocated to SR or HR. 39 received other therapy
	1988-1991	141	B	Non-metastatic	HR	241	53% <sup>c</sup>		Response to chemotherapy is a significant prognostic factor
<b>ROI REN-3</b> (Bacci et al. 2002)	1991-1997	157	B	Age <50, non-metastatic			71%		Addition of IE beneficial
<b>INT-0091</b> (Grier et al. 2003)	1988-1992	530	B	Age ≤30	Non-metastatic	398	54%	0.005	Patients randomized to receive VDCA or VDCA + IE.
					Metastatic	120	22%	0.81	Addition of IE beneficial in non-metastatic disease
	1991-2001	68	B + ST	Tumour ≥100ml (before 1995)	Non-metastatic	44	82% <sup>d</sup>	n/a	Nine patients (eight with metastatic disease) received HDCT
<b>ECESS 92</b> (Paulussen et al. 2008)	n/a	647	B	Age <35, non-metastatic disease (first 6months)	SR	155	67%	0.72	Randomisation in selected risk groups, SR = Tumour <100ml and non-metastatic, HR = all others
	1995-1998	478	B + ST	Age <30, non-metastatic	HR	492	52%	0.12	
<b>INT-0154</b> (Granowetter et al. 2009)	1995-1998	478	B + ST	Age <30, non-metastatic	Standard	231	72.1%	n/a <sup>e</sup>	No benefit from C and E dose intensification
	1999-2005	281	B + ST	Age <50, metastatic <sup>f</sup>	Intensified	247	70.1%		3-year EFS for all patients 27% vs. 57% for those 24 who received HDCT after complete response
<b>Euro-EWING95-R3</b> (Ladenstein et al. 2010)	1999-2006	300	B + ST	Age <40, non-metastatic	GR	146	75%	n/a <sup>e</sup>	HDCT beneficial for PR, 5-year EFS for 22 PR patients receiving conventional therapy (no HDCT) was 33%
	1999-2006	281	B + ST	Age <50, metastatic <sup>f</sup>	PR	148	72%		SR: GR or tumour <100ml if unresected, IR: intermediate response or >100ml unresected tumour, HR: PR histologically or radiologically if unresected. CD or IE based on evaluation after 3x CD
<b>ISG/SSG III</b> (Ferrari et al. 2011)	1993-1999	214	B	Non-metastatic	SR	116	70%		
	1993-1999	214	B	Non-metastatic	IR	46	54%	n/a <sup>e</sup>	
<b>EW93</b> (Gaspar et al. 2012)	1993-1999	214	B	Non-metastatic	HR	48	48%		
<b>ISG/SSG IV</b> (Lulsch et al. 2012)	1999-2008	102	B + ST	Age <40, metastatic			54%		5-year EFS for all study patients was 43%
	2000-2010	856	B + ST	Age <50, non-metastatic, GR/tumour <200ml			78.2% <sup>g</sup>		Severe hematologic toxicity more common but tubular function impairment reduced in VAC arm
<b>Euro-EWING95-R1</b> (Le Deley et al. 2014)	2000-2010	856	B + ST	Age <50, non-metastatic, GR/tumour <200ml			75.4% <sup>g</sup>	n/a <sup>e</sup>	

A = dactinomycin, B = bone, C = cyclophosphamide, D = doxorubicin, EFS = event-free survival, GR = good response to chemotherapy, HDCT = high dose chemotherapy with autologous stem cell rescue, HR = high risk, I = iphosphamide, IR = intermediate risk, LM = lung metastases, OAS = overall survival, PR = poor response to chemotherapy, ROI = Rizzoli orthopaedic institute, SR = standard risk, ST = soft tissue, n/a = data not available

<sup>a</sup>if differs from group n, <sup>b</sup>metastasis-free survival, <sup>c</sup>10-year EFS, <sup>d</sup>4-year survival rates, <sup>e</sup>95% CI = no statistical significance, <sup>f</sup>excluded if only pulmonary metastases, <sup>g</sup>3-year survival rates



Immediate, early and late complications of chemotherapy are all common and possibly severe, even fatal. During almost 5000 courses given to 851 patients, five deaths related to VIDE occurred, three of them due to sepsis and two for unknown reason (Juergens et al. 2006). Most gastrointestinal, skin, renal, cardiac and neurological adverse reactions were grade 1-2 (mild or moderate). The most common grade 4 adverse effect, occurring in 86% of courses, was granulocytopenia but only 16% of the infections (occurring in 57% of all courses) were grade 3 (severe but not immediately life-threatening) or grade 4 (immediately life-threatening). Grade 4 renal, cardiac, neurological or liver-associated reactions occurred in less than 2% of all courses. All patients receiving HDCT experience a grade 4 neutropenia, almost all have infections of grade 3 or 4, and other grade 3-4 adverse effects are common too (Ferrari et al. 2011, McTiernan et al. 2006).

There are several health issues among the long-term survivors (Fidler et al. 2015). A case-control study of late effects of therapy in ES survivors using siblings as controls showed survivors to have impaired employment, marital status, fertility, functional status and many treatment-related health difficulties (Novakovic et al. 1997). Curiously, however, the self-rated health status did not differ among survivors and controls in this study. In a more recent study by Ginsberg et al. (2010) including 568 long-term survivors, there were significantly more chronic health problems among survivors, including severe cardiac, pulmonary and neurologic conditions. They reported a cumulative 46% incidence of a severe, life-threatening, disabling or fatal chronic condition at 25 years after diagnosis (Ginsberg et al. 2010).

Another major concern in treating young cancer patients is the risk for second malignancy (Bacci et al. 2005). Fidler et al. (2015) reported the risk of second malignancy in British bone sarcoma five-year survivors to be 4.4 times higher than expected. Second primary neoplasms caused 35% and 13% of the excess deaths of OS and ES survivors, respectively. The survivors also reported poor general health perception relative to UK norms. Youn et al. (2014) reported mortality of adolescent and young adult survivors of bone and soft tissue sarcoma to causes other than the original diagnosis to be 1.8 times higher than expected. Mortalities due to second malignancy or noncancerous reasons were 2.1 times and 1.7 times higher than expected, respectively. Non-cancerous mortality was most commonly induced by cardiovascular diseases.

The most important second malignancies include radiation-induced secondary sarcoma and acute leukaemia related to alkylating agents. Paulussen et al. (2001b) reported only six patients with second malignancies in 690 ES patients, none of which were sarcomas. Bacci et al. (2005), on the other hand, reported 14 second malignancies in 597 patients, including eight radiation-induced osteosarcomas and three acute leukaemias. The incidence rates of second myelodysplastic syndrome/acute myeloid leukaemia in both previously mentioned studies were lower than the 11 of 578 patients included in the INT-0091 - study reported by Bhatia et al. (2007). In the report of long-term childhood ES survivors by Ginsberg et al. (2010), 34 of 403 patients developed second malignancies other than non-melanoma of skin. Their material comprised only two acute myeloid leukaemias, with breast cancer being the most frequent second malignancy (n=11) followed by osteosarcoma (n=8).

### **2.1.9 Local treatment of primary tumour and treatment-related complications**

The choice of local treatment is between surgery and RT, or a combination of the two. Wilkins et al. (1986) reported superior results in surgically treated patients and results from Sailer et al. (1988) supported this. Surgery has been shown to be a superior local treatment compared with RT in terms of local control of ES in more recent studies, and nowadays surgery is carried out whenever adequate margins are feasible (Bacci et al. 2006a, DuBois et al. 2015, Schuck et al. 2003). If the preoperative situation does not allow adequate surgical margins without comprising crucial anatomic structures, no surgery should be performed, since definitive RT yields comparable results (La et al. 2006, Schuck et al. 2003). No prospective, randomized controlled trials on surgery vs. RT have been undertaken.

All surgery with curative intent aims to remove the tumour with adequate margins. Adequate margins, however, are debatable. Most frequently the margins in Ewing sarcoma surgery are considered adequate

when resection is wide or radical according to a classification by Enneking et al. (1980). It is notable, that while radical margins may require an amputation, not all amputations are radical (**Table 2**). Bacci et al. (2006a) showed that both event- and local relapse-free survival rates depend on adequate surgical margins. Classification was made by collaboration of the surgeon and the pathologist and careful gross and microscopic examination, and the margin was graded wide if the tumour was resected with a cuff of healthy tissue of at least 1 cm. There are reports suggesting that marginal resections carry equal prognosis (Qureshi et al. 2013) and others even describing no effect of positive surgical margins (Lin et al. 2007). Intralesional resections and microscopically positive surgical margins are to be avoided (ESMO 2014).

**Table 2** Classification of tumour resection margins, according to surgical procedures and their result. Modified from the table presented by Enneking et al. (1980) in *Clinical Orthopaedics and Related Research*.

Plane of dissection	Local resection	Amputation	Result
Debulking/curettage	Debulking/curettage	Debulking amputation	Leaves macroscopic disease
En bloc, through reactive zone	Marginal resection	Marginal amputation	May leave satellite or skip lesions
Intracompartmental en bloc, outside of reactive zone	Wide local resection	Wide amputation	May leave skip lesions
En bloc entire compartment	Radical local resection	Radical disarticulation	No residual

As approximately half of all ESs arise in axial locations, and the effect of the size and site of the tumour can confound the significance of surgery, deciding on the optimal local treatment is problematic. Bacci et al. (2006a) found no benefit from surgery in patients with axial tumours, but Mukherjee et al. (2013) reported a SEER-based data showing that even spinal tumours are nowadays more commonly operated and that surgery is associated with improved survival. Total en bloc spondylectomy (TES) is the recommended local control when technically possible (Sewell et al. 2015). Also patients with pelvic tumours have been reported to fare better if they had undergone surgical treatment (Raciborska et al. 2014), although there are also reports of very poor survival after internal hemipelvectomy (Farfalli et al. 2015). It is possible that part of the improved survival is explained by a selection bias, i.e. those with smaller tumours and good responders are more likely to undergo surgery.

Most of the operations on pelvic or extremity ES are limb-sparing surgeries (LSS), using bone and soft tissue reconstructive techniques as needed. LSS can lead to a good functional outcome and even to athletic activity (Hobusch et al. 2015). Patients undergoing LSS have been associated with improved survival relative to amputation (Schrager et al. 2011). It is uncertain whether this is explained by other treatment or tumour-related factors. The choice between LSS and amputation is always dependant on many tumour and patient-related factors and has to be made individually (Hosalkar & Dormans 2004, Weisstein et al. 2005). Most importantly, adequate margins must not be compromised to perform LSS and the remaining function after LSS must be assumed to exceed the functional outcome of an amputation and a personal prosthesis. Amputation is a valid option in peripheral tumours if adequate margins are not attainable by LSS.

Post-operative RT is indicated for inadequate surgical margins, since the outcome after combination treatment may be comparable to a resection with adequate margins (DuBois et al. 2015, Foulon et al. 2016, Schuck et al. 2003). Post-operative RT may also be beneficial when tumour response to induction chemotherapy is poor (Schuck et al. 2003). RT may also be administered preoperatively to enable LSS, and

the results may be comparable to surgery alone or surgery combined to post-operative RT (Schuck et al. 2003). A major problem related to preoperative RT is the induced unreliability of grading chemotherapy response (Gaspar et al. 2015), which in turn may make the choice for optimal consolidation therapy more difficult.

LSS in pelvic or extremity bone sarcoma is usually performed by reconstructing the resected bone with a metal endoprosthesis, allograft bone, vascularized autograft bone (usually a vascularized fibular graft), devitalized autograft bone or any combination of these (Aponte-Tinao et al. 2012, Ogura et al. 2015, Rabitsch et al. 2013, Tsagkosis et al. 2015). A study comparing vascularized with non-vascularized fibular graft found no difference in achieving primary union, but a higher complication rate in the group with vascularized grafts (Schuh et al. 2014). One of the novel reconstruction methods reported to carry good results is extracorporeal irradiation and reimplantation of the resected bone (Krieg et al. 2009); the autograft acquired in this manner may be particularly useful in pelvic ES. Bone reconstruction is not always needed since some bones, e.g. the fibula and the clavicle, are expendable. Even in pelvic tumours bone reconstruction may sometimes be left undone with acceptable results (Hillman et al. 2003). The most frequent bone reconstruction, especially in adult patients and with tumours close to a joint, is a metal endoprosthesis, nowadays frequently with a modular tumour megaendoprosthesis (Tsagkosis et al. 2015). The 10-year endoprosthesis survival is usually between 50% and 85% and the 15-year survival approximately 50% (Bernthal et al. 2010, Ham et al. 1998, Jeys et al. 2008, Tsagkosis et al. 2015), although poorer results have also been reported (Grimer et al. 2016). Upper limb endoprostheses seem to have a lower need of revision in 10 years than pelvic or lower limb prostheses (Jeys et al. 2008, Grimer et al. 2016).

The need to compensate for future growth is a special issue in LSS of young people (Lewis 2005). The problem is especially relevant in very young children and when the resection includes one or more physes in the lower limb. The results of LSS in children are acceptable, even if complications and reoperations are common (Futani et al. 2006). Expected limb length discrepancy must be addressed if it is suspected to exceed 2 cm since greater discrepancy may result in clinically relevant problems (Knutson 2005). There are several options, including growing endoprostheses, rotationplasty, distraction osteogenesis, contralateral epiphyseodesis and epiphyseal preservation with bone auto- and allograft reconstruction (Lewis 2005). Growing endoprostheses are an option when the resection includes the joint surface (Dotan et al. 2010, Eckardt et al. 2000, Nystrom & Morcuende 2010), but complications and need for revision are frequent (Eckardt et al. 2000, Cipriano et al. 2015). Rotationplasty basically converts an above-knee-amputation to a below-knee-amputation, offering good functional outcome but a bizarre appearance and is seldom the first option; it can be considered instead of amputation in very young patients not suitable for growing endoprostheses (Lewis 2005). Biological implants are often used in intercalary reconstructions after diaphyseal resections. Auto- and allograft bone and both combined have been used with good results: five-year graft survivals for intercalary allografts can be as good as 85% (Aponte-Tinao et al. 2012) and for intercalary combination grafts even more than 90% (Rabitsch et al. 2013). The choice for optimal reconstruction method must be made individually.

The range of surgical complications varies according to the site of the primary tumour and the type of the possible reconstruction of bone or soft tissue and is also related to many patient and treatment factors such as age, comorbidities and possible preceding operations or RT. Early or late surgical complications are reported in approximately 30%-50% of patients with pelvic tumours treated with LSS (Farfalli et al. 2015, Hillman et al. 2003, Raciborska et al. 2014,). Infections are quite common regardless of the operation area or reconstruction method (Farfalli et al. 2015, Hillman et al. 2003, Jeys et al. 2008). Deep infection of a metal endoprosthesis, occurring in about 10% of endoprosthesis reconstructions for bone tumours (Racano et al. 2013), is a devastating complication, usually leading to multiple reoperations, even amputation (Jeys et al. 2005). Mechanical issues and infection are the most important reasons for revision surgery in all bone reconstruction methods, when local tumour recurrence is excluded. The nature of the mechanical failures differs between reconstructions; metal endoprostheses are susceptible to aseptic loosening, wear, dislocation and implant breakage, while biological implants fail due to non-union and fractures (Aponte-

Tinao et al. 2012, Bus et al. 2014, Futani et al. 2006, Muscolo et al. 2008, Sainsbury et al. 2014, Tsagkozis et al. 2015).

It is unclear whether surgical metastasectomies are beneficial or not and how to identify those who might benefit. Metastasectomy may improve survival in ES patients with pulmonary metastases (Letorneau et al. 2011), and those with solitary pulmonary metastases seem most likely to benefit from surgical metastasectomy (Kim et al. 2011). The impairment in pulmonary function due to metastasectomy is usually mild (Denbo et al. 2014). Treasure et al. (2012), however, could not find evidence of either improved survival or a palliative effect of pulmonary metastasectomies in their systematic review. The authors pointed out that while there are several reports of improved survival in those who underwent metastasectomies, the results might simply be caused by a selection bias. This is the most important methodological problem in any study of surgery in ES to date. The possible bias cannot be managed without RCTs which, due to the vast variety of these rare tumours and the patient populations, are very difficult to perform.

## 2.2 Other bone sarcomas in children

### 2.2.1 Epidemiology

The most common bone sarcoma in childhood and adolescence is osteosarcoma. OS comprised 52% of all malignant primary bone tumours in a European population based material with an incidence of 2.8 per million in the age group 0-14 years and 10.8 in the age group 15-19 years (Stiller et al. 2006a). The second most common is ES (34%), followed by chondrosarcoma (CS, 6%) and other specified (4%) and unspecified (4%) tumours (Stiller et al. 2006a). There is some geological variation in the proportions mainly because of differences of ES incidence in different races and areas (Stiller 2007). There are several histological subtypes of OS, the most common of which is the osteoblastic conventional osteosarcoma (**Table 3**). Unlike ES, OS may present as a low-grade tumour with a very good prognosis (Berner 2015c).

Certain risk factors of OS have been identified. Some of them, such as Paget's disease, do not affect the paediatric population. Post-radiation osteosarcomas are also rare in young people, but as more and more long-term survivors who have received RT are alive, they are sometimes encountered (Schwartz et al. 2014). Osteosarcoma, particularly in the femur, has been associated with tall stature at diagnosis (Cotterill et al. 2004, Mirabello et al. 2011). The incidence peak at adolescence also indicates a relation to rapid growth. Increased birth weight also seems to increase risk for OS (Chen et al. 2015, Mirabello et al. 2011). Unlike in ES there are no reports of a statistically significant relationship between OS and parental occupation (Hum et al. 1998).

Li-Fraumeni syndrome, caused by germline alterations in the *p53* tumour suppressor gene (Malkin et al. 1990) is associated with an increased risk for many type of cancer, one of the most common of which is OS (Bougeard et al. 2008). There are also various other genetic alterations affecting *p53* regulators and effectors linked to OS (Kansara & Thomas 2007). Another important tumour suppressor gene behind OS is *RB1*, germline inactivating mutations of which were first linked to hereditary retinoblastoma but soon also to OS (Friend et al. 1986). Hereditary retinoblastoma is an independent predisposing factor for many secondary sarcomas, including OS (Wong et al. 1997). This has been associated with RT of retinoblastoma, but this is not the main reason behind the secondary OS (Mohney et al. 1998, Moll et al. 2001). Also sporadic mutations of *RB1* are frequent in osteosarcomas (Kansara & Thomas 2007). Other syndromes associated with OS are linked to mutations in *ReqQ* DNA helicases, such as the RAPADILINO syndrome, the Rothmund-Thompson syndrome, the Werner syndrome and the Bloom syndrome, all associated with an increased risk for OS (Kansara & Thomas 2007, Siitonen et al. 2009). Diamond-Blackfan anaemia, a hereditary bone marrow failure syndrome, has also been linked to an increased risk for OS (Lipton et al. 2001, Vlachos et al. 2012).

**Table 3** Distribution of osteosarcoma subtypes in Finland (1991-2005) and Norway (1975-2009) according to the WHO classification (Berner et al. 2015b, Fletcher et al. 2013, Sampo et al. 2011)

Subtype	Finland (n=144)	Norway (n=473)	Definition (WHO)
Conventional	73%	71%	An intramedullary high-grade tumour producing osteoid
Osteoblastic	60%	33%	Matrix predominantly osteoid/bone
Chondroblastic	10%	9%	Matrix predominantly chondroid
Fibroblastic	3%	7%	Minimal amounts of osseous matrix
Mixed		20%	-
NOS		2%	-
Telangiectatic	2%	1%	Characterized by large spaces filled with blood with or without septa
Small cell	1%	1%	A high-grade tumour composed of small cells with variable degrees of osteoid production
Low grade central	3%	4%	A low-grade tumour arising from the medullary cavity
Secondary	3% <sup>a</sup>	12% <sup>b</sup>	Usually in Paget's disease or postradiation
Parosteal	6%	4%	A low-grade tumour arising on the surface of bone
Periosteal	6%	<1%	An intermediate-grade chondroblastic OS arising on the surface of bone
High grade surface	-	-	A high-grade OS arising on the surface of bone
OS of the jaw	-	7%	-
NOS	6%	-	-

NOS = not otherwise specified, OS = osteosarcoma, WHO = World Health Organization

<sup>a</sup>All four were postradiation osteosarcomas

<sup>b</sup>Included were Paget's disease and postradiation OS as well as those with other predisposing conditions such as retinoblastoma or Li-Fraumeni syndrome

Chondrosarcoma (CS) is predominantly a disease of adulthood with most patients being older than 40 years at diagnosis (Andreou et al. 2011). Nevertheless, it may rarely also arise in children (Giuffrida et al. 2009). The differential diagnosis between benign lesions, low-grade CS and even high-grade CS is challenging, however, and studies have shown that intra- and interobserver reliability varies from fair to good (SLICED study group 2007, Zamora et al. 2017). Like OS, CS is linked to some hereditary syndromes. Hereditary multiple osteochondromas is an autosomal dominant condition where the patient develops multiple osteochondromas (Stieber & Dormans 2005). Less than 3% of the patients are reported to undergo a malignant transformation of an osteochondroma into a peripheral chondrosarcoma (Czajka & DiCaprio 2015, Wicklund et al. 1995) but in some families the transformation may appear more often (Kivioja et al. 2000). The multiple enchondromas in Ollier disease and Maffucci syndrome are also at risk of undergoing malignant transformation into central chondrosarcoma (Silve & Jüppner 2006, Verdegaal et al. 2011). Transformation occurs in 15-50% of Ollier patients and is even more common in Maffucci syndrome (Verdegaal et al. 2011).

### 2.2.2 Treatment of bone sarcomas other than Ewing sarcoma in children

The treatment of OS with chemotherapy started after chemotherapy had already been tried in treating ES in the 1960s. The first chemotherapeutic agents used to treat disseminated OS with some success were doxorubicin (Cortes et al. 1972) and methotrexate (Jaffe 1972). Encouraging results prompted trials with chemotherapy administration in non-metastatic disease and soon chemotherapy was shown to improve survival as adjuvant therapy to amputation (Cortes et al. 1974, Jaffe et al. 1974). After the remarkably good results of a treatment with a wide/radical surgical resection combined with pre- and post-operative chemotherapy with vincristine, methotrexate, doxorubicin and cyclophosphamide were published (Rosen et al. 1976) and later confirmed (Link et al. 1991), the basis for modern treatment of OS was set.

The three agents that form the core of the chemotherapy treatment are methotrexate, doxorubicin and cisplatin (MAP-treatment) (Isakoff et al. 2015). Much research in the last decades has been directed to improving chemotherapy in OS, with little advancements in survival (Isakoff et al. 2015). The latest and largest international collaboration study, EURAMOS-1, randomized good responders to neoadjuvant chemotherapy to receive MAP or MAP followed by pegylated interferon and poor responders to receive MAP or MAP with ifosfamide and etoposide (Whelan et al. 2015). The results showed no difference in survival between the trial arms, neither in good nor in poor responders (Bielack et al. 2015, Marina et al. 2016).

The principles of surgical treatment of OS and other bone sarcomas in children equal those of ES. The aim of surgery is to achieve wide resection margins, although there are reports indicating that marginal resections hold comparable results (Bertrand et al. 2016, Bispo & de Camargo 2009, Li et al. 2012). Jeys et al. (2017) reported that a resection margin of 2mm or greater predicted a small change for local relapse in OS and with response to neoadjuvant therapy considered, their model was superior to the Enneking classification in predicting local relapse. Chemotherapy, depending on the histological diagnosis, is seldom indicated in bone sarcomas other than OS and ES, and the treatment consists of a wide or radical surgical excision or amputation. Chondrosarcoma is considered resistant to chemo- and radiotherapy (Leddy & Holmes 2014, van Maldegem 2014) and is usually treated with a wide excision. A low-grade tumour may be treated with a curettage and local adjuvant therapy with alcohol, phenol, polymethylmethacrylate or cryoablation with good results (Kim et al. 2015).

### **2.2.3 Prognosis and prognostic factors**

The five-year overall survival of children with OS or CS in Europe and the US has been reported to be approximately 60-70%, and a bit lower for ES (Esiashvili et al. 2008, Eyre et al. 2009b, Mirabello et al. 2009, Stiller et al. 2001, Stiller et al. 2006a). The five-year OAS in other specified or unspecified malignant bone tumours is higher (Stiller et al. 2006a). The survival has not improved markedly since the 1990s (Eyre et al. 2009b, Mirabello et al. 2009, Zaikova et al. 2015). The most important prognostic factor in OS is the presence of metastases at diagnosis, encountered in approximately 20-25% of patients (Berner et al. 2015b, Duchman et al. 2015, Sampo et al. 2011, Zaikova et al. 2015). The five-year OAS of patients with localized high-grade OS is more than 60% whereas it is less than 25% in patients with metastatic disease (Duchman et al. 2015, Zaikova et al. 2015).

Children, adolescents and young adults with osteosarcoma have an improved survival relative to older people (Duchman et al. 2015, Whelan et al. 2012b, Zaikova et al. 2015). Trama et al. (2016) reported children to have higher survival rates than adolescents and young adults in a Europe-wide study. There are, however, studies reporting no difference (Harting et al. 2010) or even inferior survival in children compared with adolescents and adults (Bacci et al. 2006d). The worse survival in older age may be related to different tumour site, size, treatments, tolerance of treatment and chemotherapy response (Berner et al. 2015a, Harting et al. 2010). Males have been reported to have an inferior survival compared with females (Bielack et al. 2002, Duchman et al. 2015, Mirabello et al. 2009, Smeland et al. 2011, Stiller et al. 2006b, Whelan et al. 2012b), but the reported differences in survival rates are typically less than 10% and there are also studies with large materials without any significant differences (Bramer et al. 2009).

Disease-related prognostic factors in localized OS include the site (Bielack et al. 2002, Duchman et al. 2015, Stiller et al. 2006b, Zaikova et al. 2015) and the size (Bacci et al. 2006d, Bielack et al. 2002, Duchman et al. 2015) of the primary tumour. As in ES, the response to neoadjuvant chemotherapy is an important prognostic factor (Bielack et al. 2002, Bramer et al. 2009, Jeys et al. 2017, Smeland et al. 2011, Whelan et al. 2012b). The reported long-term survival rates for axial OS are less than 40%, while they are more than 60% in peripheral tumours (Bielack et al. 2002, Duchman et al. 2015, Harting et al. 2010, Zaikova et al. 2015). The five-year survival rate reported for poor responders is less than 50%, whereas it is more than 70% for good responders (Bielack et al. 2002, Whelan et al. 2012b). Numerous trials have aimed at finding

modified therapies for poor responders but there has been little improvement in the survival (Isakoff et al. 2015). Histological subtype seems to affect survival too, with better results reported for fibroblastic conventional OS, but the differences are not consistent (Bacci et al. 2006d, Duchman et al. 2015, Whelan 2012b). Chondroblastic subtype, more common than osteoblastic subtype in the pelvis, seems to respond poorly to chemotherapy and has a worse prognosis, at least in pelvic locations (Parry et al. 2016). Reports on prognostic effect of elevated alkaline phosphatase are controversial (Bacci et al. 2006d, Smeland et al. 2003).

Treatment-related positive prognostic factors in OS consist of inclusion in a formal trial protocol (Zaikova et al. 2015), completion of the planned chemotherapy (Sampo et al. 2011, Whelan et al. 2012b), and surgery with adequate margins (Bacci et al. 2006d, Berner et al. 2015a, Bertrand et al. 2016, Bielack et al. 2002) and timed according to the treatment plan (Whelan et al. 2012b). Surgery and adequate margins are dependent on the size and site of the primary tumour. Larger tumours more often lead to inadequate margins (Li et al. 2012) and tumours located axially are more often inoperable and treated with RT (Meazza et al. 2014). Even if the margins in some reports are not dependent on tumour location (Li et al. 2012), both size and site of tumour are independent risk factors and may confound the improvement in prognosis associated with the surgery.

Presence of metastases at diagnosis and high grade and axial site of the primary tumour are the main negative prognostic factors in CS (Andreou et al. 2011, Bindiganavile et al. 2015, Giuffrida et al. 2009). Those with low-grade peripheral tumours can have a 10-year survival rate of more than 90%, whereas it is less than 70% for those with axial high-grade tumours (Bindiganavile et al. 2015). The studies have mostly been conducted on adult patients, but they imply that younger patients tend to fare better (Andreou et al. 2011, Giuffrida et al. 2009).

## **2.3 Vertebral column resection and surgical treatment of spinal tumours**

### **2.3.1 Spinal tumours**

A small portion of bone tumours arise in the spine and metastatic lesions are much more common in the spine than primary tumours. More than 60% of all spinal primary tumours in paediatric patients are benign, whereas 20% of the tumours in adults are malignant (Kelley et al. 2007, Weinstein & McLain 1987). Age can be helpful in narrowing diagnoses of spinal lesions (**Table 4**). Less than 5% of the entries to the Leeds Regional Bone Tumour Register in a 42-year period were reported to involve tumours of the spine and less than 20% of them in children (Kelley et al. 2007). Excluding malignant lymphatic tumours, i.e. plasmacytoma/myeloma and lymphoma, the most common malignant primary osseous spinal tumours comprise chordoma, CS, OS and ES (Kelley et al. 2007, Mukherjee et al. 2011, Weinstein & McLain 1987). Chordomas, malignant tumours arising from the embryonic remnants of the notochord, and chondrosarcomas are predominantly encountered in adult patients (Mukherjee et al. 2011). The prognosis of patients with primary osseous spinal tumours is poor, SEER-data reporting five-year survivals of 18-62%, depending on the histology, with osteosarcoma carrying the worst and chordoma the best prognosis (Mukherjee et al. 2011).

### **2.3.2 History of vertebral resections and results in correcting deformities**

Vertebral column resections (VCRs) have been performed from the beginning of the 20<sup>th</sup> century (MacLennan 1922) to correct spinal deformities, i.e. severe scoliosis, when other procedures cannot achieve the necessary correction. The first reported spondylectomies used to resect spinal giant cell tumours were performed at the end of the 1960s (Lievre et al. 1968, Stener & Johnsen 1971). Soon after, spondylectomy was used to cure spinal sarcoma (Stener 1971). All of the procedures were performed using a two-stage operation via anteroposterior (AP) approaches. Although at least one whole vertebra is removed in both types of operations, the procedures differ significantly. A piecemeal removal of the vertebra is not contraindicated in correcting deformities, but in treating malignant spinal neoplasms it is

quite the opposite, resulting in an intralaminar resection and spreading of tumour cells. On the other hand, when removing a spinal tumour, there is usually no need to correct the balance of the spine. The number of resected vertebrae is also decided on a different basis; to resect a tumour, one must remove all affected vertebrae, whereas to correct a deformity, the number of vertebrae to be resected depends on the type of deformity (Smith et al. 2008). Likewise, the levels for fusion are decided based on the deformity (Smith et al. 2008).

**Table 4** Most frequent benign and malignant tumours in the spine according to age. Modified from the table presented by Dormans and Moroz in the Journal of Bone and Joint Surgery (Dormans & Moroz 2007, Fletcher et al. 2013, Kelley et al. 2007, Weinstein & McLain 1987)

<b>Age</b>	<b>Benign</b>	<b>Malignant</b>
0-5 years	Langerhans cell histiocytosis	Leukaemia Neuroblastoma (metastatic) Wilms' tumour (metastatic) Ewing sarcoma
5-10 years	Aneurysmal bone cyst Langerhans cell histiocytosis Nonossifying fibroma Osteoid osteoma	Ewing sarcoma Osteosarcoma
10-20 years	Aneurysmal bone cyst Osteochondroma Osteoid osteoma Osteoblastoma	Chondrosarcoma Ewing sarcoma Osteosarcoma
>20 years	Giant cell tumour	Metastasis Plasmacytoma/myeloma Chordoma Lymphoma Chondrosarcoma

The two-stage AP technique for VCR for spinal deformities was further developed in the 1970s (Leatherman & Dickson 1979). Oncological spinal surgery has also advanced, with development of oncological and surgical staging systems and en bloc resection techniques (Boriani et al. 1997). The latest technical advances have allowed posterior-only approaches in suitable cases, both for total en bloc spondylectomy (TES) (Tomita et al. 1997) and for VCR for spinal deformities (Lenke et al. 2009, Suk et al. 2002, Suk et al. 2005). The new posterior-only techniques are considered advantageous to the AP approach, since the AP approach is more time consuming, requires an intraoperative repositioning of the patient, and carries a risk of iatrogenic injury to vital organs, depending on the level of the operation (Suk et al. 2002). Posterior-only approach is also considered neurologically safer, with circumferential access to neural structures (Lenke et al. 2009). However, no previous studies have compared the anteroposterior and posterior-only approach in children undergoing VCR.

Vertebral column resection is a powerful tool in correcting severe rigid spinal deformities. The curve correction after VCR depends on the type of deformity treated, but the mean correction is usually reported to be approximately 60% in both planes (Iyer et al. 2016, Lenke et al. 2013, Yang et al. 2016). It is also a



technically demanding procedure and carries a high risk for complications. Major complications, such as nerve root injury, vascular or visceral injury and injury to spinal cord or the cauda equina (Glassman 2007) have occurred in more than 20% of VCRs, with 2% of patients suffering a complete cord injury (Iyer et al. 2016, Yang et al. 2016). The rate of reoperations due to complications has been reported to be approximately 5-10%, most of them due to infection (Lenke et al. 2013, Yang et al. 2016) or compression of the cauda equina (Iyer et al. 2016).

Severe spinal deformity is also a deformity of the chest wall, and the level of pulmonary function impairment depends on the magnitude of the deformity (Dreimann et al. 2014, Newton et al. 2005). Patients with untreated severe scoliosis, particularly congenital or early onset types, are subject to increased mortality, largely due to respiratory failure (Pehrsson et al. 1992). On the other hand, treatment of the deformity, whether conservative or operative, helps in avoiding these problems (Pehrsson et al. 2001). Even if pulmonary function deficit already exists, some recovery may be induced with treatment (Pehrsson et al. 2001). Posterior-only procedures not violating the chest wall have resulted in better pulmonary function than anterior approaches (Gitelman et al. 2011). Pulmonary function has been reported to increase after VCR for severe scoliosis in children, but not in adults (Bumpass et al. 2014). Adolescent idiopathic scoliosis seldom progresses to a severe deformity since patients are usually operated on with curves of 50°-55° (Sucato 2010).

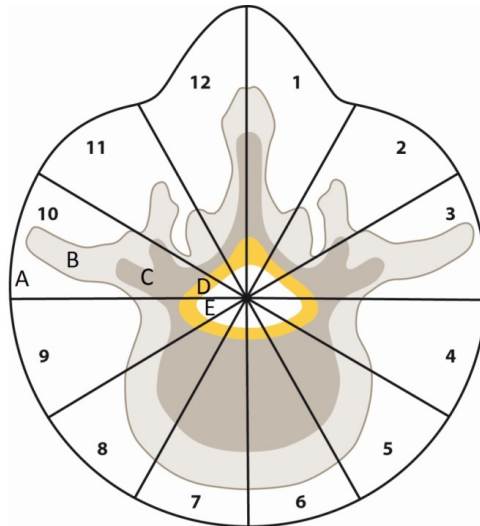
### **2.3.4 Role of surgery in treatment of malignant tumours of the spine**

The complex anatomy of the spine and its close relation to adjacent neural, vascular and visceral structures does not allow the usual techniques and principles, e.g. the staging system of Enneking et al. (1980), to be strictly followed in treating spinal neoplasms. Since many primary malignant tumours of the spine are resistant to RT, surgery is still considered beneficial, at least when wide or even marginal resection is achievable (Mukherjee et al. 2013, Ozaki et al. 2002, Schwab et al. 2012). Sometimes even patients with spinal metastases are considered to benefit from surgery (Kaloostian et al. 2014), and scoring systems for surgical strategies in spinal metastases have been developed (Tomita et al. 2001).


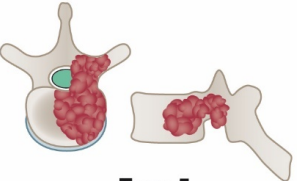
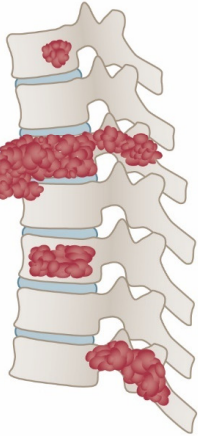
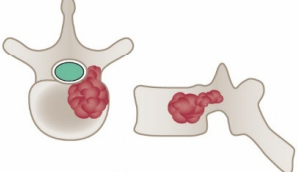
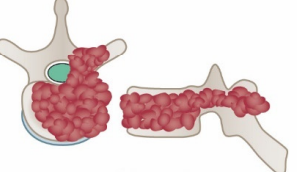
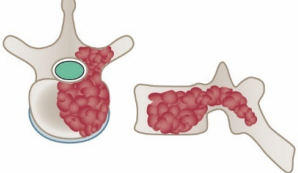
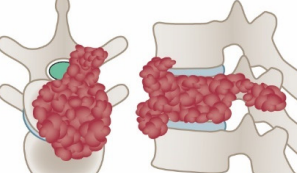
The three main procedures used to achieve en bloc resection in the spine include spondylectomy (or vertebrectomy), sagittal resection and posterior arch resection (Boriani et al. 1997). Surgical staging systems have been developed to help in decision-making; the two most commonly used systems are the Weinstein-Boriani-Biagnini (Boriani et al. 1997) and Tomita (Tomita et al. 1997) staging systems (**Figures 2 and 3**). En bloc spondylectomy can be performed either via a posterior-only approach or a combined anterior and posterior approach, depending on which part of the spinal column is affected and the surgical staging of the tumour (Amendola et al. 2014, Tomita et al. 2006). Basically, one pedicle has to be free of tumour for the tumour to be removed en bloc or the operation will inevitably be intralesional (Boriani et al. 1997, Tomita et al. 1997). Radiation therapy remains a valuable tool in providing sufficient local control in spinal sarcoma, whether combined with surgery or as the sole local therapy (DeLaney et al. 2014).

Successful en bloc resection has been shown to improve survival in chondrosarcoma (Boriani et al. 2000), chordoma (Boriani et al. 2006) and osteosarcoma (Dekutoski et al. 2016). TES may improve prognosis of spinal ES, at least combined to RT (Sewell et al. 2015), but there is still no consensus of the optimal local treatment of spinal ES since radiotherapy is also effective. Neoadjuvant chemotherapy is recommended in spinal ES even if the patient presents with neurological deficit (Mirzaei et al. 2015). As major complications are common, the decision to perform TES should be made by experienced, multidisciplinary teams (Yamazaki et al. 2009).

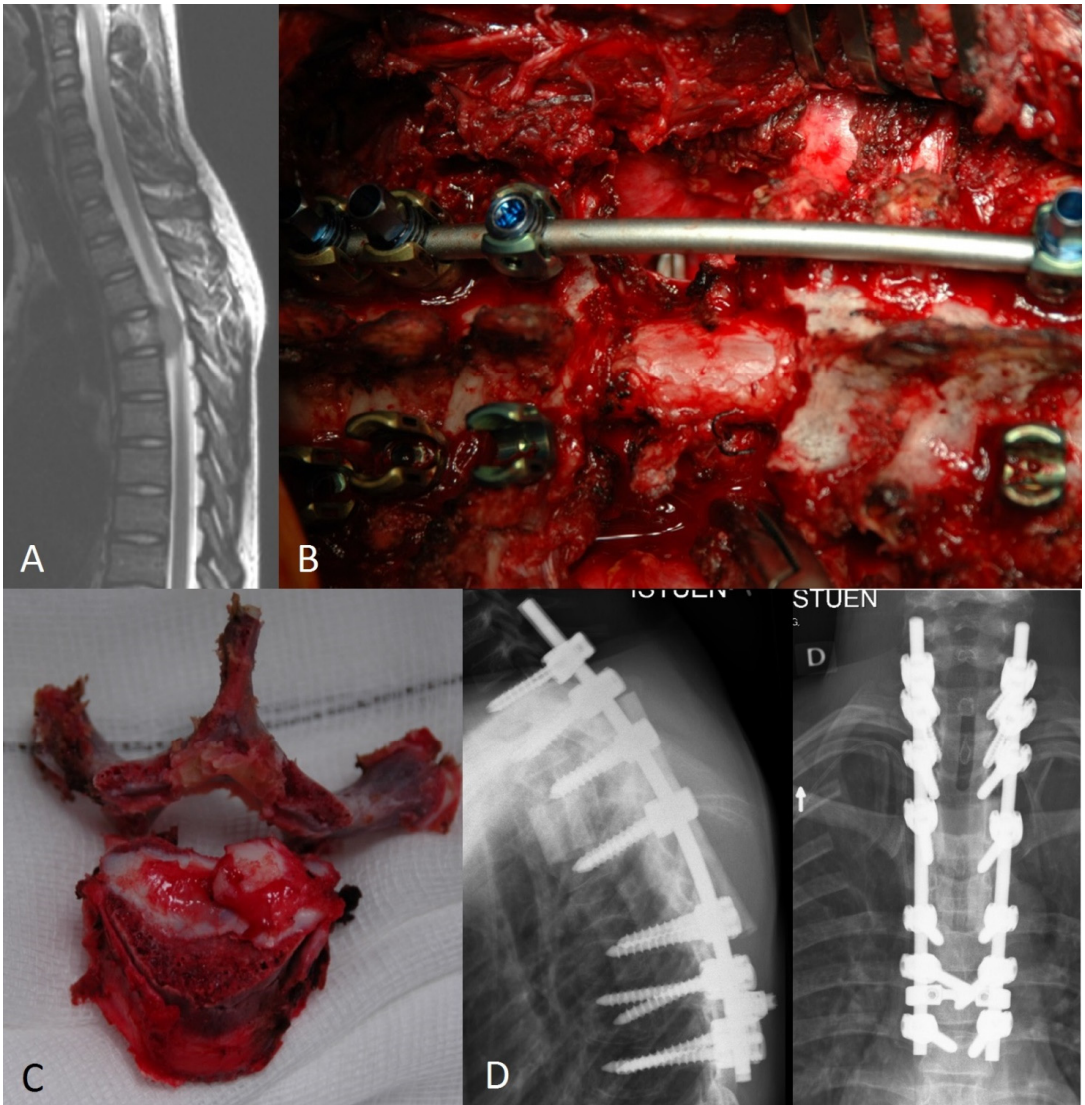
- A: Extraosseus soft tissues
- B: Intraosseus (superficial)
- C: Intraosseus (deep)
- D: Extraosseus (extradural)
- E: Extraosseus (intradural)



**Figure 2** The Weinstein-Boriani-Biagnini (WBB) surgical staging system divides the vertebra into 12 radiculating zones and into five layers. Modified from the figure introduced by Boriani et al. (1997) in Spine (Philadelphia, Pa, 1976).

Intra-compartmental	Extra-compartmental	Multiple
<p><b>Type 1</b> Vertebral body</p> 	<p><b>Type 4</b> Spinal canal extension</p> 	<p><b>Type 7</b></p> 
<p><b>Type 2</b> Pedicle extension</p> 	<p><b>Type 5</b> Paravertebral extension</p> 	
<p><b>Type 3</b> Body - lamina extension</p> 	<p><b>Type 6</b> Adjacent vertebral extension</p> 	

**Figure 3** The Tomita classification divides tumours based on their growth into posterior parts and adjacent extracompartmental tissues. Modified from the figure introduced by Tomita et al. (2006) in the Journal of Orthopaedic Science.



**Figure 4** Total en bloc spondylectomy (TES) for Ewing sarcoma. A) Preoperative magnetic resonance imaging shows the tumour, located in the 4<sup>th</sup> thoracic vertebra and compressing the spinal cord. B) Perioperative image of the total en bloc spondylectomy. The medial heads of the adjacent ribs have been resected, T4 nerve roots ligated and pedicle screws inserted in the adjacent vertebra with a unilateral stabilizing rod applied. C) The resected 4<sup>th</sup> thoracic vertebra in two pieces according to the TES technique. D) Post-operative X-rays of the patient. Courtesy of Professor Ilkka Helenius.

### **3. AIMS OF THE STUDY**

We aimed to evaluate the treatment and outcome of bone and soft tissue Ewing sarcoma in a nationwide, population-based manner in Finland during 1990-2009 and also to establish the five-year survival rates and to assess prognostic factors (Study I). We also evaluated the surgical treatment of patients with axial or peripheral Ewing sarcoma and to report surgical complications (Study II).

Further aims were to estimate the incidence of paediatric bone sarcomas in Finland during 1991-2005, to estimate their ten-year survival rates and to describe possible prognostic factors (Study III).

Finally, we aimed to determine the clinical, radiological and quality-of-life results of patients who had undergone vertebral column resection for paediatric spinal deformity and to compare anteroposterior and posterior-only approaches (Study IV).

## 4. MATERIALS AND METHODS

The core data for studies I-III comprised bone sarcomas reported to the Finnish Cancer Registry during 1991-2006. All sarcoma patients in Finland are treated in the five university hospitals. To search for possible missing cases, to obtain a wider material and to include also soft tissue tumours, all five Finnish university hospitals were contacted and data on bone and soft tissue ES during 1990-2009 were collected for Studies I and II. The university hospitals were also contacted and data on paediatric bone sarcomas during 1991-2005 were gathered to detect possible missing patients for Study III. The Finnish Population Register Centre was used to derive up-to-date survival data on the patients for Studies I-III. The Finnish National Statistics Database was used to obtain population data for calculating incidence rates in Studies III and IV. The data for Study IV were gathered retrospectively from four university hospitals in Finland, identifying all paediatric patients who had undergone a spinal column resection in Finland during 2005-2009. The fifth university hospital was known not to perform such surgery during the study period.

A histological re-evaluation of osteosarcoma patients in Study III had been performed as part of a previous study (Sampo et al. 2011). A histological re-evaluation was not performed for patients with ES or CS; original pathology reports were reviewed instead. Detailed data, not contained in the data of the Finnish Cancer Registry, were gathered from patient medical records for Studies I-III. Tumours of the head, spine, pelvis, rib cage and soft tissues of the trunk were classified as axial and those of the clavicle, scapula and limbs as peripheral. Amputations above the level of wrist or ankle were categorized as major amputations, in contrast to LSS. Size was recorded as the largest diameter of the tumour according to the original pre-neoadjuvant MRI scans and the radiology reports. The incidence rates for Studies III and IV were calculated based on year- and age-specific population data available from the National Statistics Database. Age-standardized incidence rates in Study III were calculated based on the Segi standard world population suggested by Doll et al. (1966).

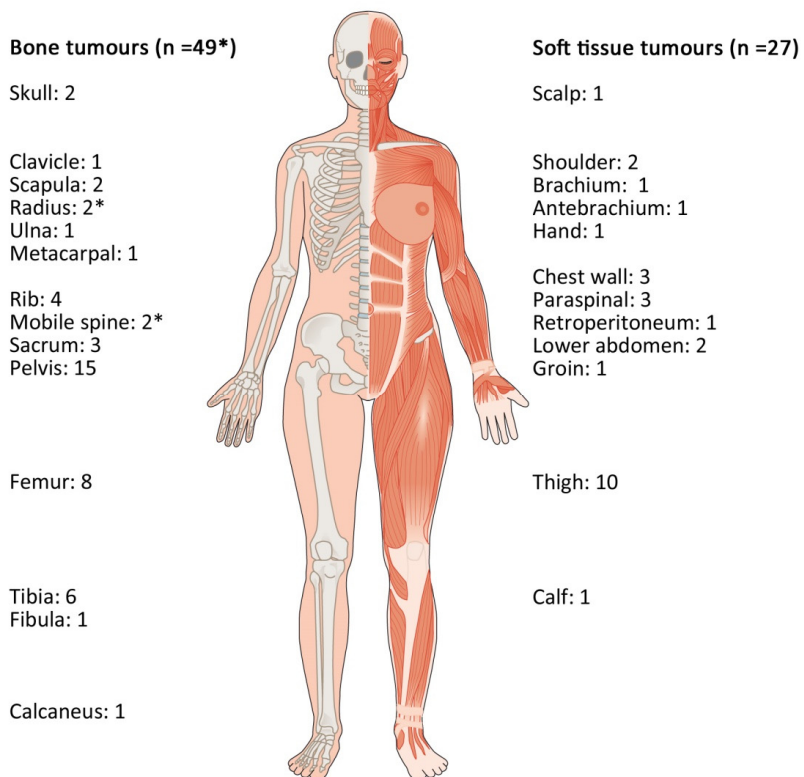
All patients undergoing VCR before the age of 18 years were collected for Study IV. The operations were performed with the anteroposterior (AP) approach, according to Leathermann and Dickson (1979), or using a posterolateral (PL) approach, as described by Lenke et al. (2009). Spinal cord monitoring was performed in all operations to study motor evoked potential, sensory evoked potential and lumbar nerve root electromyography. All patients were examined clinically and radiologically preoperatively and postoperatively at three, six, 12 and 24 months. Radiographs were measured by two independent observers using the Cobb technique (Cobb 1948). Standard preoperative imaging included CT and MRI studies. Scoliosis Research Society-24 questionnaires (Hafer et al. 1999) were used at the final review.

All statistical analyses were performed with different versions of IBM® SPSS® (IBM Corp., Armonk, NY, USA), except for 95% confidence intervals for incidence rates, which were calculated with OpenEpi v. 3.01 and the Mid-P exact test. The  $\chi^2$  and Fisher exact tests were used to examine differences between two groups for nominal variables and Mann-Whitney U test for continuous variables. The Kruskal-Wallis test was used to evaluate differences on continuous variables for multiple groups. Poisson regression was used to analyse the impact of age group, time period of diagnosis or gender on incidence rate in Study III. Kaplan-Meier analysis was used for survival analyses with log rank-test to analyse differences between groups in univariate analysis of nominal variables. The Cox proportional hazards model was used to find survival differences between groups in multivariate analysis and univariate analysis of continuous variables. P-values  $\leq 0.05$  were considered statistically significant. The study was approved by the Joint Ethics Committee of Helsinki University Hospital and by the Ministry of Health and Social Affairs.

## 5. RESULTS

### 5.1 Treatment, survival and prognostic factors in bone and soft tissue Ewing sarcoma in Finland during 1990-2009 (Study I)

Seventy-six patients with a median age of 17.8 years (range 0.1-65.2 years) were included in the final analyses, 25% of them (n=19) having a metastatic disease at diagnosis. There was a male predominance of 1.9:1. Half of the patients had an axial primary tumour and in 49 patients the primary tumour originated from bone (**Figure 5**). Molecular genetic confirmation for ES was found in 78% of the 45 patients tested. Forty-eight of the 57 patients with a localized disease at diagnosis were operated. Ninety-four percent of the resections had at least a marginal surgical margin. Histological response to neoadjuvant chemotherapy was estimated to be good in 71% of those with available data (n=38).



**Figure 5** The location of the primary tumour in Finnish patients diagnosed during 1990-2009. One patient had a disseminated multifocal disease, and one had a tumour in the radius and the lumbar vertebra (\*).

All but one patient with a localized disease received chemotherapy according to international study protocols (Elomaa et al. 2000, Ferrari et al. 2011, Grier et al. 2003). Age at diagnosis affected the chosen chemotherapy protocol: the median ages (interquartile range) were 11.1 years (IQR 3.7) for INT-0091, 18.7 years (IQR 14.9) for ISG/SSG III and 26.3 (IQR 11.8 years) for SSG IX ( $p < 0.001$ ). Thirteen patients received HDCT after a poor histological response to neoadjuvant therapy (n=6) or upon being considered high-risk by the treating physicians. Only one patient estimated to have a good response received HDCT. The main local therapy was RT in six patients but pre- or postoperative RT was administered to 20 patients with localized

disease. Severe immediate toxic complications, besides neutropenic infection, anaemia and thrombocytopenia, were reported in four patients, including renal failure, heart failure, polyneuropathy and delirium. Late adverse effects were reported in 24% of the patients surviving for longer than two years from diagnosis; these included reduced renal function (n=5), cardiomyopathy (n=2) and endocrine impairments (n=7). Only one second malignancy was recorded, a phylloid tumour of the breast.

**Table 5** Prognostic factors of patients with localized or metastatic Ewing sarcoma. Only statistically significant factors in univariate analysis are shown.

Characteristic	n	Univariate analysis		Multivariate analysis	
		HR	95% CI	HR	95% CI
<b>Localized disease</b>	57				
Age at diagnosis in years		1.03	1.00-1.06	0.98	0.92-1.05
Site of primary tumour					
Peripheral	29	1		1	
Axial	28	3.1	1.2-8.0	2.7	0.8-8.8
Surgical resection with at least marginal margins <sup>a</sup>					
Yes	45	1		1	
No	11	2.67	1.0-6.8	1.1	0.3-3.4
Chemotherapy protocol <sup>a,b</sup>					
No chemotherapy	1	-		-	
ISG/SSG IV	1	-		-	
INT-0091	24	1		1	
ISG/SSG III	11	1.4	0.3-7.9	1.4	0.2-7.9
SSG IX	19	4.2	1.3-13.3	5.2	1.0-26.8
<b>Metastatic disease</b>	19				
Neoadjuvant chemotherapy before local therapy <sup>c</sup>					
Yes	11	1		1	
No	3	6.7	1.3-34.3	18.0	1.9-167.2
High-dose chemotherapy <sup>d</sup>					
Yes	9	1		1	
No	8	11.1	2.3-54.2	17.6	1.6-194.6

HR = Hazard ratio for death due to disease, CI = confidence interval

<sup>a</sup>One patient excluded due to death in less than 3 months from diagnosis

<sup>b</sup>The two groups with only one patient excluded from the log rank test

<sup>c</sup>Data available for 14 patients: five did not receive any local therapy

<sup>d</sup>Two patients excluded due to death in less than 3 months from diagnosis

The five-year sarcoma-specific survival of those with metastatic disease was 33% (95% CI 10-50%) and thus significantly poorer than of those with localized disease whose 5-year sarcoma specific survival was 70% (95% CI 58-82%, p=0.001). Their treatment followed the same principles as for localized disease. Only two patients received surgical metastasectomies, while the metastatic sites or the whole body were irradiated in six. Excluding two patients who died in less than three months after diagnosis all received chemotherapy according to international study protocols, most commonly ISG/SSG IV, designed for high-risk patients (Luksch et al. 2012). The primary tumour was operated in ten patients and irradiated in four. Four additional patients received post-operative RT. HDCT was associated with improved survival in metastatic disease.

## 5.2 Surgical treatment, its complications and survival of patients with axial and peripheral bone and soft tissue Ewing sarcoma in Finland during 2000-2009 (Study II)

Fifty-seven patients with a surgically treated ES were included in the study. Twenty-two had axial and 35 peripheral primary tumours with median ages at diagnosis of 14.3 (range 7.9-32.0) and 18.2 (range 0.1-60.1) years, respectively. The disease was metastatic at diagnosis in ten patients, three with axial and seven with peripheral primaries. There was a male predominance in both groups: 2.7:1 in axial and 1.7:1 in peripheral tumours. Axial tumours were located most commonly in the pelvic bones (n=9). The femur and the soft tissues of the thigh were most frequent sites of peripheral tumours (n=8 each).

The operation of 54 patients was intended as curative with an en bloc resection whereas three patients underwent debulking operations, all of them with axial primaries. Eighty-nine percent (n=48/54) of the en bloc resections had non-contaminated surgical margins. The first operation was LSS in 88% of those with pelvic or extremity tumour (n=38/43). Five patients underwent an amputation; four were major amputations. One patient, previously operated with LSS, had a subsequent amputation after a local relapse. One patient underwent a second LSS after a local relapse. Bone reconstruction was carried out in six patients after internal hemipelvectomy, including four allograft bone reconstructions, one endoprosthesis and in one patient a combination of these two. Fifteen patients with peripheral primary tumours required bone reconstruction with endoprostheses (n=7), vascularized fibular grafts (n=5) or bone allografts (n=3). Altogether nine patients underwent ten surgical metastasectomies, six of them for solitary pulmonary, two for vertebral and two for other skeletal metastases.

A total of 15 early surgical complications after the first operation of the primary tumour were recorded in 11 patients, leading to revision surgery in seven cases. The complications were most commonly infections (n=6) and operation site necrosis (n=4), but included two neurological deficits in the lower limb, one of them permanent. Late complications of the first operation of the primary tumour occurred in 14 patients, most commonly related to the bone reconstruction. Revision surgery was performed due to non-union (n=4) or fracture (n=2) of a bone graft or mechanical failure (n=3) or infection (n=1) of a metal endoprosthesis.

The five-year sarcoma-specific survival of this cohort with only operated patients was 78% (95% CI 65-90%) for those with a localized disease and 42% (95% CI 7-77%) for those with a metastatic disease (p=0.043). Axial site of the primary tumour was a risk factor for death due to disease (Hazard ratio 3.9, 95% CI 1.1-13.5) and contamination of surgical margin for local recurrence (Hazard ratio 16.7, 95% CI 2.7-104.2). The five-year LRFS and OAS were both more than 80% if surgical margins were free of tumour cells.

## 5.3 Incidence, treatment, survival and prognostic factors in paediatric and adolescent patients with bone sarcoma in Finland during 1991-2005 (Study III)

Altogether 88 patients with a median age of 13.7 (range 2.5-17.9) years were included in the final analyses with a median follow-up time of 12.2 (range 5.8-20.3) years for survivors. The annual incidence rates of OS, ES and CS per million children were 3.6, 1.2 and 0.3, respectively (Table 6). The incidence rates of bone sarcoma were higher in the age groups 10-14 and 15-17 years than in the age group 0-4 years after adjusting with sex and period of diagnosis (Table 7). The age distributions between patients differed according to histology, with OS and CS patients being generally older than those with ES [median ages in years: 14.2 (range 7.8-17.9), 16.3 (13.9-17.1) and 12.0 (2.5-17.8), respectively p=0.012]. The most frequent location for OS was the femur and for ES it was the pelvis (Figure 6). Ewing sarcoma was located axially more often than OS (p<0.001).



**Table 6** Incidence rates of bone sarcomas in children and adolescents in Finland during 1991-2005

Bone sarcoma type	n	Incidence rate <sup>a</sup>	95% CI
<b>Osteosarcoma</b>			
0-14 years (ASR)	37	2.3	-
0-4 years	0	0	-
5-9 years	8	1.7	0.8-3.2
10-14 years	29	5.9	4.1-8.4
15-17 years	25	8.5	5.6-12.4
All	62	3.6	2.8-4.6
<b>Ewing sarcoma</b>			
0-14 years (ASR)	16	1.1	-
0-4 years	4	0.9	0.3-2.1
5-9 years	2	0.4	0.1-1.4
10-14 years	10	2.0	1.0-3.7
15-17 years	5	1.7	0.6-3.8
All	21	1.2	0.8-1.8
<b>Chondrosarcoma</b>			
0-14 years (ASR)	1	0.1	-
0-4 years	0	0	-
5-9 years	0	0	-
10-14 years	1	0.2	0.0-1.0
15-17 years	4	1.4	0.4-3.3
All	5	0.3	0.1-0.6

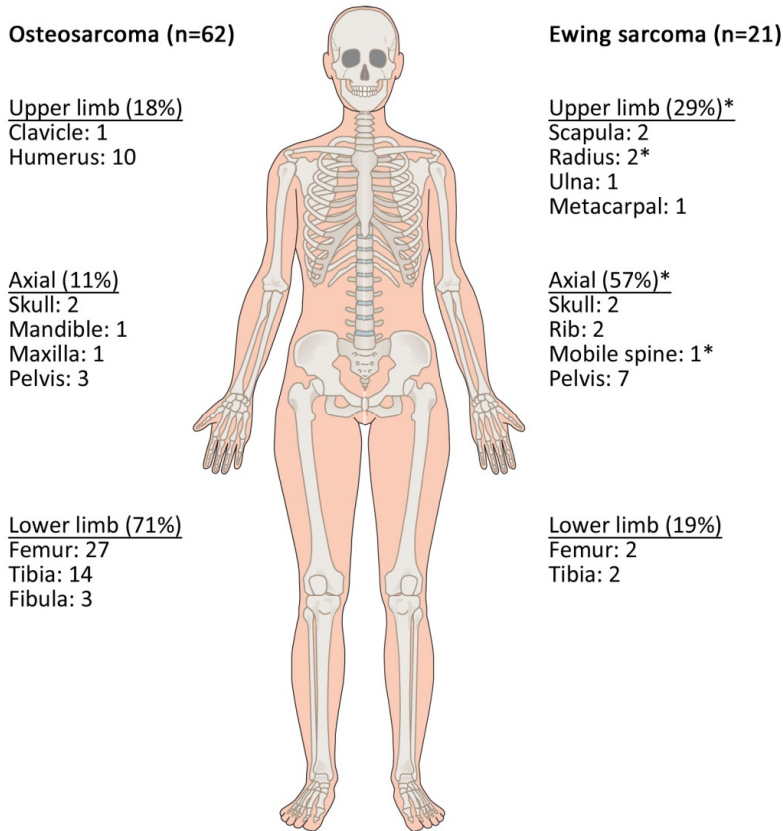
ASR = Age standardised rate (Segi world population), CI = Confidence interval

<sup>a</sup>new cases, per million per year**Table 7** Incidence of bone sarcoma in Finnish children and adolescents according to sex, age group and time of diagnosis

	n	Incidence <sup>a</sup>	95% CI	IRR	95% CI
<b>Patient sex</b>					
Male	48	5.5	4.1-7.2	1	
Female	40	4.8	3.5-6.4	0.9	0.6-1.3
<b>Age group</b>					
0-4 years	4	0.9	0.3-2.1	1	
5-9 years	10	2.1	1.1-3.7	2.4	0.8-7.6
10-14 years	40	8.2	5.9-11.1	9.4	3.4-26.2
15-17 years	34	11.6	8.2-16.0	13.2	4.7-37.2
<b>Time of diagnosis</b>					
1991-1995	25	4.3	2.8-6.2	1	
1996-2000	36	6.3	4.4-5.6	1.4	0.9-2.4
2001-2005	27	4.9	3.3-7.0	1.1	0.6-1.9

CI = Confidence interval, IRR = Incidence rate ratio

<sup>a</sup>New cases per million per year



**Figure 6** Locations of the primary tumours in 62 paediatric osteosarcomas and 21 Ewing sarcomas. One patient had Ewing sarcoma tumours in the radius and the 2<sup>nd</sup> lumbar vertebrae and it was not known which was the primary (\*).

Only two OS patients had low-grade tumours and four had known predisposing hereditary syndromes: Li-Fraumeni syndrome, *Rb* deletion, RAPADILINO and Diamond-Blackfan anaemia (n=1 each). One patient with CS had hereditary multiple osteochondromas. All patients with ES and all except one with OS received chemotherapy; the patient who did not receive chemotherapy had a low-grade tumour. All operated patients with high-grade OS and all but one with ES received neoadjuvant chemotherapy, but two OS patients did not receive adjuvant chemotherapy after operation due to surgical complications and multiple reoperations. The response to neoadjuvant chemotherapy was graded as good in 59% of OS and 67% of ES patients. Seven patients received HDCT for metastatic (n=4) or otherwise high-risk (n=3) OS and nine for metastatic (n=5) or high risk (n=4) ES.

Altogether 79 patients underwent surgery for primary tumour, and resection margins were contaminated in only four. Surgery was limb sparing in 85% of all patients with tumours in the shoulder, pelvis or extremities (n=60/71, after excluding patients with tumours of the hand or foot). Eleven patients underwent a major amputation as the first operation and five had a later amputation. The final limb-sparing rate increased during the study period, from 64% in 1991-1997 to 89% in 1998-2005. The rate of compromised margins in the first operation was the same in both time periods (5.4% vs 4.8%, p=1.00). Five patients with metastatic disease at diagnosis, three with OS and two with ES, had metastasectomies for their solitary pulmonary (n=2) or skeletal metastases (n=3). Thirteen metastasectomies were performed for

pulmonary (n=11) or skeletal (n=2) metastatic relapses of OS, whereas none of the patients with metastatic relapses of ES had a metastasectomy.

The ten-year overall survival was 74% (95% CI 63-85%) for OS, 76% (95% CI 58-94%) for ES and 80% (95% CI 45-100%) for CS. The ten-year overall survival of patients with metastatic OS was significantly worse than of patients with a localized disease [36% (95% CI 8-65%) vs. 82% (95% CI 72-93%),  $p<0.001$ ]. However, there was no difference in 10-year OAS of patients with metastatic or localized ES [80% (95% CI 54-96%) vs. 75% (95% CI 45-100%),  $p=0.868$ ].

Some factors carried a statistically significant effect on event- or disease-specific survival in univariate analysis. Every year of age at diagnosis increased the risk of death due to disease 1.4-fold (95% CI 1.0-2.0) and every 1 cm increment of the greatest diameter of tumour increased the risk for a relapse 1.1-fold (95% CI 1.0-1.2) in localized OS. Surgery of the primary tumours with resection margins free of tumour cells carried a hazard ratio of 0.1 (95% CI 0.01-0.6) compared to those not operated or had contaminated margins in metastatic OS.

#### 5.4 Incidence, radiological and clinical outcomes of vertebral column resection for paediatric spinal deformity (study IV)

Forty-nine patients who had had vertebral column resections were identified, yielding an annual incidence of 8.9 per million children. After excluding single hemivertebral resections (n=25), patients with meningomyelocele (n=6) and those who had spondylectomies for tumours (n=4), 14 patients were included in the final analyses. The annual incidence of full VCR in the treatment of paediatric spinal deformity was 3.5 per million children. The mean age was 12.3 years (range 6.5 to 17.9 years). The deformity types in this group were congenital scoliosis (n=5), neuromuscular scoliosis (n=3), congenital kyphosis (n=2), global kyphosis (n=2), adolescent idiopathic scoliosis (n=1) and secondary scoliosis (n=1). Four patients with congenital scoliosis had undergone previous operations (Table 8). A hybrid instrumentation consisting of thoracic hooks, sublaminar wires and lumbar pedicle screws was used for four patients in the AP and one patient in the PL group. All other procedures were carried out with segmental pedicle screws.

**Table 8** Demographic data of paediatric patients who had vertebral column resection

	Anteroposterior (n=7)	Posterolateral (n=7)
Gender, male/female	4/3	5/2
Age, mean (range), years	13.8 (8.5-18)	12.0 (6.5-18)
Prior surgery, no. of patients	3	1
Instrumentation, hybrid/TPS	4/3	1/6
No. of vertebrae resected, mean (range)	1.1 (1-2)	1.3 (1-2)

TPS= total pedicle screw instrumentation

The median coronal curves were 75° (range 23°-120°) and 28° (range 0°-102°,  $p=53.0$ ) and the median sagittal curves were 60° (range 13°-97°) and 87° (range 67°-122°,  $p=97.0$ ) for the AP and PL groups, respectively. The mean final radiological corrections of the major curves were 54% in the AP group and 60% in the PL group at the two-year follow-up ( $p=0.53$ ). The mean operative time was significantly shorter in the PL group than in the AP group (5h30min vs. 7h54min,  $p=0.002$ ). No difference was present in the mean estimated blood loss (3082 ml in AP and 2329 ml in PL,  $p=0.59$ ) or the mean SRS-24 scores (100 in AP and 102 in PL,  $p=0.72$ ) between the groups.

No surgical site infections were recorded. There was one paraparesis in the AP group due to compression of the spinal cord with full recovery after urgent re-decompression. Also the one peripheral L5 motor deficit in the PL group resolved fully within a few days. Two more patients needed re-operations; one because of junctional kyphosis and a major loss of correction after segmental pedicle screw fixation and one because of pseudoarthrosis and mechanical failure of the hybrid instrumentation. Major loss of correction that was not re-operated occurred altogether in three additional patients: one with junctional kyphosis after pedicle screw instrumentation and two with scoliosis after hybrid fixation. One patient had one-sided, partial lower instrumentation pull-out, but no loss of reduction and fusion occurred without revision surgery.

## 6. DISCUSSION

### 6.1 Treatment and outcome of patients with bone and soft tissue Ewing sarcoma in Finland during 1990-2009. Surgical treatment of patients with axial and peripheral Ewing sarcoma (Studies I and II)

Our studies showed that the five-year event-free and sarcoma-specific survival rates of Finnish patients with bone and soft tissue ES were comparable or better than those reported in other population based studies (Applebaum et al. 2011, Esiashvili et al. 2003, Jawad et al. 2009, Lee et al. 2010, Obata et al. 2007). These previous studies have stated that the single most important negative prognostic factor in ES is the presence of metastases; this was evident also in our material.

The small size of our study population is a key limitation, rendering statistical analysis somewhat uncertain and predisposing our analyses to type II error. Other limitations include a relatively lengthy study time period, lack of histological re-evaluation and incomplete molecular genetic data. The long study time is reflected in the advancement of diagnostic tools, treatment protocols and a change in grading response to neoadjuvant chemotherapy from the system introduced by Huvos (1991) to the one developed by Picci et al. (1997). There were, however, no statistically significant differences in the five-year survival rates between groups of different time periods. The fact that we were unable to retrospectively discriminate marginal resection margins from wide margins is another limitation, affecting the reliability of a comparison between local treatment options. The discrimination was not possible in our material, since most reports on the resection histology did not report the presence of reactive tissue, only the possible contamination by tumour cells.

Major strengths of our studies include a population-based material, with excellent nationwide coverage, combined with detailed patient and follow-up information derived from medical records. Such accuracy is not achieved in purely register-based studies. For example, eight of the 88 patients initially identified from the Finnish Cancer Registry were excluded because of a final diagnosis other than ES, as discovered in the medical records. Also the bone or soft tissue origin of the tumours is uncertain in purely register-based data (Applebaum et al. 2011). Our study confirms the estimation of the proportion of ES arising in soft tissue as roughly one-third of all tumours. Even though racial differences in study populations may be related to the proportion of soft tissue ES (Worch et al. 2010), the proportion is significantly higher than some single-centre studies (Pradhan et al. 2011) have reported.

In contrast to findings of Applebaum et al. (2011) and Cash et al. (2016), there was no difference in the survival rates of those with bone or soft tissue tumours in our data. The prognostic factors that stood out in univariate analysis in those with localized disease included the site of the primary tumour, age at diagnosis and surgical resection with at least marginal margins. These have been reported to be prognostic factors in earlier studies (Bacci et al. 2006c, Cotterill et al. 2000, Duchman et al. 2015, Ferrari et al. 2011, Grier et al. 2003, Lee et al. 2010, Pradhan et al. 2011). The applied chemotherapy protocol seemed also to be influential: patients who were treated according to the SSG IX protocol had inferior survival relative to those treated according to INT-0091 or ISG/SSG III. These factors, however, confounded each other in our material: age affected the chemotherapy protocol and those with peripheral primary tumour more often had surgery with at least a marginal surgical margin. None of the factors retained statistical significance in the multivariate analysis. Age affected the chemotherapy protocol so strongly probably because in Finland, paediatric patients are treated by paediatric haematologists and oncologists, whereas adults are treated by oncologists. The treatment of all patients, however, is decided by multidisciplinary teams.

The size of the primary tumour was not a significant prognostic factor in our material, nor was the response to neoadjuvant chemotherapy. This is in contrast to previous reports (Albergo et al. 2016, Baggi et al. 2006c, Lin et al. 2007, Picci et al. 1997). There were only 11 patients who had localized tumours responding

poorly to neoadjuvant therapy in our material, and six of them received HDCT. The effect of HDCT in high-risk disease is currently being assessed by two prospective international multicentre studies (Euro-EWING 99, Ewing 2008). Our results suggest improved survival in those who receive HDCT for metastatic ES, supporting earlier reports (Ladenstein et al. 2010, McTiernan et al. 2006, Paulussen et al. 1998). As Ladenstein et al. (2010) state, the effect of HDCT should not be overestimated because of a selection bias introduced by the time the patients need to survive to receive therapy; patients with a very aggressive disease have a lower probability of receiving HDCT.

The optimal local treatment is still controversial, as highlighted by a systematic review on ES of bone (Werier et al. 2016). Our studies showed that most patients in Finland underwent surgery of the primary tumour, including those with axial primary tumours and those with metastatic disease. Three patients with axial primary tumours were operated on in a debulking manner. In light of current knowledge, debulking is an inadvisable approach to local therapy; if at least marginal resection margins are not achievable, radiation therapy should be considered (DuBois et al. 2015, La et al. 2006, Schuck et al. 2003). In some cases, RT in a preoperative manner may enable en bloc resection (Schuck et al. 2003). The surgical margins were inadequate in only five of 54 the en bloc resections. Previous reports suggest wide or radical margins to be beneficial compared with marginal or intralesional margins, at least in evading local relapses (Bacci et al. 2006a, DuBois et al. 2015, Ozaki et al. 1996). There are, however, contrary reports stating that a wide margin is not as critical in avoiding local recurrence as chemotherapy response (Lin et al. 2007) and that minimal negative margins may be sufficient, at least in soft tissue ES (Qureshi et al. 2013). It has also been suggested that surgery is beneficial in ES of the thoracic wall, regardless of the surgical margin (Bedetti et al. 2015). Our results showed a clearly inferior LRFS in those with contaminated surgical margins and more than 80% five-year LRFS and OAS in those with uncontaminated surgical margins suggesting that marginal resection margins may be tolerable.

There were no treatment-related deaths in our material. The complications of chemotherapy, excluding neutropenic infections, anaemia and thrombocytopenia, were rare and their rate was expectable in light of previous studies (Elomaa et al. 2000, Ferrari et al. 2011, Grier et al. 2003, Juergens et al. 2006). The rate of late toxic effects, including cardiac and gonadal impairment was not unexpected (Bacci et al. 2004, Ginsberg et al. 2010). Only one second malignancy was encountered, which is less than anticipated (Bacci 2004). The occurrence of more second malignancies in the long term is to be expected, particularly among those who received RT (Ginsberg 2010). As the study of Ginsberg et al. (2010) demonstrates, studies with very long follow-up times are needed to fully understand the increased mortality and morbidity in long-term survivors.

Our results show that complications are common following surgical treatment of ES. The most common early complications result from infection and impaired circulation in the surgical field. The long-term problems with surgery were usually related to mechanical failure and infections in the metal endoprostheses and to bone graft healing. There were non-unions and fractures in both allo- and vascularized autografts. Altogether 11 patients had already been re-operated on due to these problems during follow-up, and more revisions, at least of endoprosthetic reconstructions, are virtually inevitable. Many patients with endoprostheses must undergo multiple revisions and carry an annual 1% risk of periprosthetic infection (Grimer et al. 2016). Grimer et al. (2016) reported that only 18% of their study population of 230 patients had not undergone revision of the original prosthesis during a mean follow-up time of almost 30 years. Biological grafts have been described to have 10-year survival rates of less than 50% (Campanacci 2015, Futani et al. 2006) and composite reconstruction leads to revision in approximately 30% of patients in five years, depending on the anatomical site (Auregan et al. 2016).

## 6.2 Incidence of paediatric bone sarcoma in Finland during 1991-2005. Ten-year survival rates and prognostic factors (Study III)

The incidence rates we established for OS and CS in our study group are similar to those reported in other European countries (Bernier et al. 2015b, Eyre et al. 2009b, Stiller et al. 2006a) and in the US (Mirabello et al. 2009) (Table 9). In contrast, the incidence of ES in Finland was somewhat lower than in other parts of Europe or in the US (Esiashvili et al. 2008, Eyre et al. 2009b, Stiller et al. 2006a, Stiller 2007). Identifying the reasons for this lower incidence was beyond the scope of our study. Eyre et al. (2009b) reported the incidence of ES to have decreased in their British study population during their study time period from 1981 to 2002. Whether there has been a similar decrease in Finland in the time before our study is unknown, but the ASR of 1.26 for ES in the latest time period (1996-2000) reported by Eyre et al. is very close to that seen in our study.

**Table 9** Comparison of incidence rates of paediatric osteosarcoma and Ewing's sarcoma per million children in a population-based data

First author, year	Region	Time period	Patient age, years	n <sup>e</sup>	Incidence, ASR		
					OS	ES	CS
Current study	Finland	1991-2005	0-14	54	2.3	1.1	0.1
			15-17	34	8.5	1.7	1.4
Stiller et al. 2006a	Europe	1988-1997 <sup>c</sup>	0-14	1264	2.8	2.3	0.1
			15-19	439	8.4	4.2	1.3
Eyre et al. 2009b	UK <sup>a</sup>	1996-2002 <sup>d</sup>	0-14	374	2.2	1.3	0.2
Bao et al. 2009	Shanghai	2002-2005	0-14	37	4.8	0.5	-
Van den Berg et al. 2008	The Netherlands	1999-2003	0-18	217	6.8	4.3	0.4
Esiashvili et al. 2008	US	1993-2004 <sup>d</sup>	0-19	487	-	2.7	-
Wiromrat et al. 2012	Thailand <sup>b</sup>	1985-2010	0-19	24	3.1	-	-
			15-19	34	8	-	-
Hung et al. 2014	Taiwan	2003-2010	0-24	449	4.6	0.9	0.5
Mirabello et al. 2009	US	1973-2004	0-24	1855	4.4	-	-

ASR = age-standardized ratio, ACCIS = Automated Childhood Cancer Information System, CS = chondrosarcoma, ES = Ewing sarcoma, OS = osteosarcoma, UK = United Kingdom, US = United States, SEER = Surveillance, Epidemiology, and End Results database

<sup>a</sup>Four registries covering northern England and West Midlands

<sup>b</sup>Khon Khaen Cancer Registry, north-eastern Thailand

<sup>c</sup>The data available only for this time period

<sup>d</sup>The rates from the latest period in the study presented when available

<sup>e</sup>The number of malignant bone tumours included in the study during the represented time period

The major limitation of our study is the limited number of patients. Acquiring larger data would, however, have required lengthening of the study time period even more. This would have induced other difficulties in interpreting the data, since there were major advances in the treatment until 1990s and the diagnostic tools have also developed, as discussed before. The lack of histological re-evaluation of Ewing sarcoma and chondrosarcoma is also a weakness. Likewise, the histological re-evaluation of osteosarcomas is a strength of the study.

The established 10-year survival rates were good compared with those reported previously (Arndt et al. 2007, Esiashvili et al. 2008, Eyre et al. 2009b, Mirabello et al. 2009, Stiller et al. 2001, Stiller et al. 2006a). Metastatic disease was associated with a poor prognosis in OS, but not in ES, which is strongly in contrast

to earlier reports (Cotterill et al. 2000, Esiashvili et al. 2008). There were only five patients with metastatic ES in our material, however, and their 80% 10-year OAS was extremely good. Since all metastatic lesions encountered in imaging studies had not been histologically verified, we can speculate that some of these might not have been true metastases. The prognostic factors in localized disease, with statistical significance in univariate analysis included the size and patient age in OS. These have been previously reported as risk factors, albeit inconsistently (Bacci et al. 2006d, Ferrari et al. 2001). Age as predictor of outcome in OS is not clear since some studies report even inferior survival in younger patients (Bacci et al. 2006d). Harting et al. (2010) reported that age was not an independent risk factor in their study. Only patients aged under 18 years old were included in our study. In a previous study from Finland that included all ages (Sampo et al. (2011) age was reported to be a non-prognostic factor.

The treatment followed guidelines of international collaborative groups, and nearly all OS and ES patients received neoadjuvant and adjuvant chemotherapy with surgery, or RT in ES, of the primary tumour. Since we do not have detailed information on treatments in large register- and population-based reports (Esiashvili et al. 2008, Eyre et al. 2009b, Stiller et al. 2006a), we do not know whether the good survival rates observed in our material correlate with the adequacy of treatments. Previous studies of OS have shown that major deviation from chemotherapy is associated with poor prognosis (Sampo et al. 2011) and that older patients are at a higher risk for not receiving adequate therapy (Berner et al. 2015a).

With improved survival of paediatric bone sarcoma patients over the last decades, largely due to advances in chemotherapy, more attention has been given to functional outcomes. This has led to an increase in limb-sparing procedures, which has been associated with improved functionality (Asknes et al. 2008, Hopyan et al. 2006, Rougraff et al. 1994). The literature on the matter is, however, controversial. Stokke et al. (2015) found no difference in functional or quality-of-life outcome in their recent systematic review and meta-analysis comparing LSS with amputation. However, the site of the tumour, and thus, the level of the amputation were not considered. There are reports of equal functional and quality of life outcomes even after external or internal hemipelvectomy (Beck et al. 2008, Griesser et al. 2012). This does not mean that they are equally good; rather, they are equally poor (Griesser et al. 2012, Jansen et al. 2013), indicating that there is still a strong need for advancements in limb-sparing techniques of the pelvis. The rate of LSS in our material increased from the first half of our study time period to the second half. This did not result in a rise of contaminated resection margins. Even though five patients needed subsequent amputations, the final limb-sparing rate increased. Functional and quality of life outcomes were beyond the scope of our study, so we do not know whether the increase in LSS affected these outcomes. The decision regarding the optimal surgical approach, between LSS and amputation - or between surgery and RT in ES - is a demanding task and must be made individually for each patient, preferentially by a multidisciplinary team (Hosalkar & Dormans 2004). The centralization of surgery from four to three centres during our study time period can be seen as progress since the total annual number of these patients is small and it is difficult to achieve expert knowledge with a very small number of patients.

### **6.3 Clinical, radiological and quality of life results of vertebral column resection for paediatric spinal deformity (Study IV)**

Vertebral column resections are the ultimate surgical tool for correcting severe spinal deformities (Sucato 2010) and with certain modifications, i.e. en bloc resection, can be used to resect malignant spinal tumours (Boriani et al. 1997, Tomita et al. 1997). The resection may be done via AP or a posterior-only approach, but the latter has been reported to be advantageous because it avoids repositioning the patient intraoperatively and shortens the operation time (Lenke et al. 2013). It has also been suggested to possibly diminish blood loss (Suk et al. 2002), but no comparative reports supporting this speculation exist. Our work was the first to compare AP and posterior-only approaches in VCR of paediatric patients with severe spinal deformities. It was also the first to report quality-of-life results of paediatric patients after VCR.



There are some limitations which need to be considered. The study set was retrospective and the patients operated on via AP or PL approaches were not entirely similar regarding the type and magnitude of the deformity and the underlying aetiology. The lack of pulmonary function tests precludes comparison with other studies, reporting improved pulmonary function after VCR (Bumpass et al. 2014). The main limitation of our study is the small number of patients, although we included every Finnish patient during our study time.

The study revealed an annual incidence of 3.5 VCRs for paediatric spinal deformity per million children in Finland. There was no difference in the correction capacity between the two approaches and the 60% correction achieved in the PL group is in line with other reports (Yang et al. 2016). Pulmonary function was outside the scope of our study, but the patient-reported results on quality of life, e.g. pain, self-image and daily activities were assessed by the SRS-24 questionnaire. The results showed high satisfaction at the final follow-up, with none of the patients reporting a total score of less than 92/120 and the majority reporting a score of more than 100/120.

Reduced operation time with the PL approach was evident in our material, and there was a trend suggesting of less blood loss in the PL group (754 ml less), albeit statistically non-significant. This might result from a type II error since the number of patients in our study was quite small; the reduction in mean estimated blood loss was almost a quarter of the blood loss with the AP approach. The mean operation time in our PL group was similar to that reported by Suk et al. (2002) and shorter than that described by Lenke et al. (2009). The estimated blood loss in the PL group was 2329 ml. While this is less than Yang et al. (2016) report in their systematic review, it is significantly more than the 691 ml reported by Lenke et al. (2009) in their material with paediatric patients. These results cannot, however, be directly compared, since almost one-third of the patients included in the study by Lenke et al. (2009) underwent hemivertebral resections in which the operation time was shorter and the estimated blood loss was less. Nevertheless, their results show that it is possible to achieve even less blood loss, but this may result in a longer operation time.

The risk for complications in vertebral column resection is high regardless of the approach (Lenke et al. 2009, Lenke et al. 2010, Lenke et al. 2013, Suk et al. 2002, Suk et al. 2005). The most common complications reported in the literature, depending on the definition of complication, include neurological deficits, infection and respiratory problems (Iyer et al. 2016, Lenke et al. 2013, Yang et al. 2016). There were only two neurological complications in our material, one requiring immediate re-decompression. However, both resolved completely. There were no surgical site infections in our data. Two patients required late revision surgery for major loss of correction: one due to junctional kyphosis and one due to pseudoarthrosis. Our revision rate is comparable to the 22% found by Papadopoulos et al. (2015), who reported the revision rate due to pseudoarthrosis to be 6.6% and due to proximal failure of hybrid instrumentation to be 2.2%. It is more than in the reviews by Iyer et al. (2016) and Yang et al. (2016) but the patient material and the reporting of complications vary among the included studies.

Despite the notable risk for complications, we found that vertebral column resection results in an improved self-image, function, mental health and satisfaction. These findings have been supported by subsequent reports (Lenke et al. 2013). The AP approach is still an option for extremely severe (i.e. > 120°) scoliosis, since it carries the possibility of greater mobilization by adjacent disc excisions. However, the reduced operation time and possibly reduced blood loss with the posterior-only approach make it the primary choice in selective cases.

## 7. CONCLUSIONS

The outcomes in the treatment of Ewing sarcoma in Finland are comparable to European and American standards (Study I). Our results hint that surgical resection with or without additional radiation therapy should be the first option for local therapy in Ewing sarcoma whether the primary tumour is located axially or peripherally whenever at least marginal margins are achieved. If marginal margins are not achievable, definitive radiation therapy is preferable (Studies I and II). High-dose chemotherapy may be beneficial in metastatic and high-risk Ewing sarcoma but more randomised controlled studies are needed to clear the controversies regarding the treatment (Study I).

The incidence rates of osteosarcoma and chondrosarcoma in those less than 18 years of age in Finland are essentially the same as reported for other parts of Europe and for the United States, but the incidence rate of Ewing sarcoma seems to be slightly lower (Study III). The survival rates of paediatric bone sarcoma patients in Finland are good compared with previously reported data from Europe and the United States (Study III).

The annual incidence of vertebral columns resection in Finland is 3.5 per million children. The clinical, radiological and quality-of-life results in these patients are good (Study IV). The posterior-only approach in vertebral column resection seems to offer comparable results and a shorter operation time than the anterior and posterior approach in selective patients in the treatment of severe paediatric spinal deformities (Study IV).

## ACKNOWLEDGEMENTS

This study was carried out at the Comprehensive Cancer Center, Helsinki University Hospital and University of Helsinki and at the Department of Paediatric Orthopaedic Surgery, Turku University Hospital.

First and foremost, I thank my supervisors, Professor Ilkka Helenius and Docent Maija Tarkkanen. Without the continuous help, clinical insights, countless hours spent refining the manuscripts and occasional gentle - but firm - nudges forward, this thesis would never have been finished. Astonishingly, they always found time for me and my questions and responded quickly, even though I know they are both very busy with all the other work at hand. If I could have been as efficient as both of them, it might be that we would have been done with this years ago! I also want to thank them for encouraging me to attend international congresses to exhibit our research project. I am truly privileged to have worked under their supervision.

I thank Docent Minna Laitinen and Docent Olli Lohi, University of Tampere, the referees appointed by the Faculty of Medicine, University of Helsinki, for reviewing the thesis and for their constructive criticism. I also would like to thank Professor Sirpa Leppä for overseeing the progress of the thesis.

I thank all of my co-authors; the positive criticism and expert comments were essential to the completion of this thesis. I owe special thanks to co-authors Mika Sampo, MD, PhD, and Docent Kim Vettenranta, who devoted a great many hours to revising the manuscripts and helping me with them. I also thank Kim for always having time for me and for all of the arrangements made at Tampere University Hospital. Additionally, Co-authors Professor Ulla Pihkala and Docent Sanna-Maria Kivivuori I thank for their vast knowledge and vision in starting the project with Ewing sarcoma.

I sincerely thank the numerous individuals who helped gather data in all five university hospitals. People working at the archives of the Clinic of Oncology and at the archives of the Children's Hospital in Helsinki receive special thanks for arranging all the papers and the room needed to conduct my studies. I also thank my co-authors Docent Pekka Riikonen and Docent Mikko Perkkiö for making the needed arrangements for me to gather data in Kuopio University Hospital, my co-author Docent Aarne Kivioja for the same help in Töölö Hospital and Professors Ari Ristimäki and Willy Serlo for their assistance in Oulu.

I thank the Nona and Kullervo Väre Foundation, the Finnish Foundation for Paediatric Research and the Ensio Hyvärinen fund for financially supporting the study and making it possible for me to take time off my normal work. I also thank Medtronic, Baxter and the University of Helsinki EVO funds for aiding me with congress trip expenditures. I thank Helena Schmidt for superb work with the anatomical drawings and Carol Ann Pelli for editing the language of this thesis.

Simultaneously with this project, I started my specialist training in orthopaedics. I warmly thank my colleagues and co-workers at Hatanpää hospital, Tampere, and at South Karelia Central Hospital, Lappeenranta, for pleasant collaboration over the past few years. I thank all senior surgeons and my fellow trainees for making work enjoyable. Special thanks to fellow orthopaedic residents Lauri, Aapo, Mikko J. and Elisa and orthopaedists Kari, Tatu, Mikko A., Henrik, Pekka, and Matti W. in Lappeenranta for the education, the savvy remarks about postoperative radiographs, the pseudo-philosophical discussions and the laughs in Hällitupa. I also thank vascular surgeons Professor Hannu Savolainen for trying to educate me, particularly in the field of common knowledge, and Eija Saimanen, MD, PhD, for showing me a level of surgical skills and efficiency that I can only aspire to achieve. I thank my bosses in Lappeenranta, Juha Kasurinen, MD, PhD and Docent Antti Hietaranta, for flexibility in work times, allowing me to work on this thesis.

I thank my parents Willy and Kajjaleena and my sisters Hannamari and Heidi for their support and interest in my work. I am also thankful for the time with my late grandmothers Anna and Helmi who now live in my memories. I appreciate the hard work of my grandparents and my parents, which ultimately has led to my

life being in many ways much easier than theirs. I have been taught to aim high and work hard, and that is what I have tried to do.

I thank all of my friends, especially Miika, Jukka, Tommi, Arttu, Tuomas, Roope and Kurt, for giving me a counterbalance to work. I am lucky to have such good friends from medical school, from my school times in Oulu and some from even earlier. I am proud of how we have ended up. For all the fun, the beer and the hardcore punk: thank you! I thank also my friends Josh, Parker, Aaron and Orrin for their hospitality while I visited the States for the SRS congress in 2011 and the discussions that made me rethink my worldview. I am still waiting for them to come visit Finland!

Lastly, and most importantly, I thank my wonderful wife Maija. Without her support and understanding I would never have carried out this project. If there is anything I regret in working towards this thesis, it is the time spent away from her. I trust, though, that we will have more time together and plenty of travels ahead, as I feel travelling has given us much. At times this thesis seemed like a swamp, but then I remembered the time we got out the jungle swamp in Costa Rica and realized that we will surely get through this swamp too. I hope though that this time it is a one-way swamp trip. I am also very grateful to her for our beautiful son Juho, who has lately kept us quite busy at home, for which I am also very grateful! I love you both very much.

## REFERENCES

- Abudu, A., Davies, A.M., Pynsent, P.B., Mangham, D.C., Tillman, R.M., Carter, S.R. & Grimer, R.J. Tumour volume as a predictor of necrosis after chemotherapy in Ewing's sarcoma, *J.Bone Joint Surg.Br.* 1999;81(2):317-322.
- Aisen, A.M., Martel, W., Braunstein, E.M., McMillin, K.I., Phillips, W.A. & Kling, T.F. MRI and CT evaluation of primary bone and soft-tissue tumors, *AJR Am.J.Roentgenol.* 1986;146(4):749-756.
- Aksnes, L.H., Bauer, H.C., Jebsen, N.L., Folleras, G., Allert, C., Haugen, G.S. & Hall, K.S. Limb-sparing surgery preserves more function than amputation: a Scandinavian sarcoma group study of 118 patients. *J.Bone Joint Surg.Br.* 2008;90(6):786-794.
- Albergo, J.I., Gaston, C.L., Laitinen, M., Darbyshire, A., Jeys, L.M., Sumathi, V., Parry, M., Peake, D., Carter, S.R., Tillman, R., Abudu, A.T. & Grimer, R.J. Ewing's sarcoma: only patients with 100% of necrosis after chemotherapy should be classified as having a good response, *Bone Joint J.* 2016;98-B(8):1138-1144.
- Amendola, L., Cappuccio, M., De Iure, F., Bandiera, S., Gasbarrini, A. & Boriani, S. En bloc resections for primary spinal tumors in 20 years of experience: effectiveness and safety, *The Spine Journal* 2014;14(11):2608-2617.
- Andreou, D., Ruppin, S., Fehlbeg, S., Pink, D., Werner, M. & Tunn, P. Survival and prognostic factors in chondrosarcoma: Results in 115 patients with long-term follow-up, *Acta Orthopaedica* 2011;82(6):749-755.
- Angervall, L. & Enzinger, F.M. Extraskeletal neoplasm resembling Ewing's sarcoma, *Cancer* 1975;36(1):240-251.
- Aponte-Tinao, L., Farfalli, G.L., Ritacco, L.E., Ayerza, M.A. & Muscolo, D.L. Intercalary femur allografts are an acceptable alternative after tumor resection, *Clin.Orthop.Relat.Res.* 2012;470(3):728-734.
- Applebaum, M.A., Worch, J., Matthay, K.K., Goldsby, R., Neuhaus, J., West, D.C. & Dubois, S.G. Clinical features and outcomes in patients with extraskeletal Ewing sarcoma, *Cancer* 2011;117(13):3027-3032.
- Armengol, G., Tarkkanen, M., Virolainen, M., Forus, A., Valle, J., Bohling, T., Asko-Seljavaara, S., Blomqvist, C., Elomaa, I., Karaharju, E., Kivioja, A.H., Siimes, M.A., Tukiainen, E., Caballin, M.R., Myklebost, O. & Knuutila, S. Recurrent gains of 1q, 8 and 12 in the Ewing family of tumours by comparative genomic hybridization, *Br.J.Cancer* 1997;75(10):1403-1409.
- Arndt, V., Lacour, B., Steliarova-Foucher, E., Spix, C., Znaor, A., Pastore, G., Stiller, C. & Brenner, H. Up-to-date monitoring of childhood cancer long-term survival in Europe: tumours of the sympathetic nervous system, retinoblastoma, renal and bone tumours, and soft tissue sarcomas, *Ann.Oncol.* 2007;18(10):1722-1733.
- Askin, F.B., Rosai, J., Sibley, R.K., Dehner, L.P. & McAlister, W.H. Malignant small cell tumor of the thoracopulmonary region in childhood: a distinctive clinicopathologic entity of uncertain histogenesis. *Cancer* 1979;43(6):2438-2451.
- Auregan, J.C., Pietton, R., Begue, T., Anract, P. & Biau, D. Effect of anatomic site and irradiation on the rates of revision and infection of allograft-prosthesis composites after resection of a primary bone tumor: a meta-analysis, *Arch.Orthop.Trauma.Surg.* 2016;136(10):1371-1380.
- Bacci, G., Ferrari, S., Longhi, A., Rimondini, S., Versari, M., Zanone, A. & Forni, C. Prognostic significance of serum LDH in Ewing's sarcoma of bone, *Oncol.Rep.* 1999;6(4):807-811.
- Bacci, G., Mercuri, M., Longhi, A., Bertoni, F., Barbieri, E., Donati, D., Giacomini, S., Bacchini, P., Pignotti, E., Forni, C. & Ferrari, S. Neoadjuvant chemotherapy for Ewing's tumour of bone: recent experience at the Rizzoli Orthopaedic Institute, *Eur.J.Cancer* 2002;38(17):2243-2251.
- Bacci, G., Forni, C., Longhi, A., Ferrari, S., Donati, D., De Paolis, M., Barbieri, E., Pignotti, E., Rosito, P. & Versari, M. Long-term outcome for patients with non-metastatic Ewing's sarcoma treated with adjuvant and neoadjuvant chemotherapies. 402 patients treated at Rizzoli between 1972 and 1992, *Eur.J.Cancer* 2004;40(1):73-83.
- Bacci, G., Longhi, A., Barbieri, E., Ferrari, S., Mercuri, M., Briccoli, A., Versari, M., Pignotti, E. & Picci, P. Second malignancy in 597 patients with ewing sarcoma of bone treated at a single institution with

- adjuvant and neoadjuvant chemotherapy between 1972 and 1999, *J.Pediatr.Hematol.Oncol.* 2005;27(10):517-520.
- Bacci, G., Longhi, A., Briccoli, A., Bertoni, F., Versari, M. & Picci, P. The role of surgical margins in treatment of Ewing's sarcoma family tumors: experience of a single institution with 512 patients treated with adjuvant and neoadjuvant chemotherapy, *Int.J.Radiat.Oncol.Biol.Phys.* 2006a;65(3):766-772.
- Bacci, G., Longhi, A., Ferrari, S., Mercuri, M., Barbieri, E., Bertoni, F., Bacchini, P. & Picci, P. Pattern of relapse in 290 patients with nonmetastatic Ewing's sarcoma family tumors treated at a single institution with adjuvant and neoadjuvant chemotherapy between 1972 and 1999, *Eur.J.Surg.Oncol.* 2006b;32(9):974-979.
- Bacci, G., Longhi, A., Ferrari, S., Mercuri, M., Versari, M. & Bertoni, F. Prognostic factors in non-metastatic Ewing's sarcoma tumor of bone: an analysis of 579 patients treated at a single institution with adjuvant or neoadjuvant chemotherapy between 1972 and 1998. *Acta Oncol.* 2006c;45(4):469-475.
- Bacci, G., Longhi, A., Versari, M., Mercuri, M., Briccoli, A. & Picci, P. Prognostic factors for osteosarcoma of the extremity treated with neoadjuvant chemotherapy, *Cancer* 2006d;106(5):1154-1161.
- Bailly, R.A., Bosselut, R., Zucman, J., Cormier, F., Delattre, O., Roussel, M., Thomas, G. & Ghysdael, J. DNA-binding and transcriptional activation properties of the EWS-FLI-1 fusion protein resulting from the t(11;22) translocation in Ewing sarcoma, *Mol.Cell.Biol.* 1994;14(5):3230-3241.
- Balamuth, N.J. & Worner, R.B. Ewing's sarcoma, *Lancet Oncol* 2010;11(2):184-192.
- Barker, L.M., Pendergrass, T.W., Sanders, J.E. & Hawkins, D.S. Survival after recurrence of Ewing's sarcoma family of tumors, *J.Clin.Oncol.* 2005;23(19):4354-4362.
- Beck, L.A., Einertson, M.J., Winemiller, M.H., DePompolo, R.W., Hoppe, K.M. & Sim, F.F. Functional outcomes and quality of life after tumor-related hemipelvectomy, *Phys.Ther.* 2008;88(8):916-927.
- Bedetti, B., Wiebe, K., Ranft, A., Aebert, H., Schmidt, J., Jurgens, H. & Dirksen, U. Local control in Ewing sarcoma of the chest wall: results of the EURO-EWING 99 trial, *Ann.Surg.Oncol.* 2015;22(9):2853-2859.
- Berner, K., Hall, K.S., Monge, O.R., Weedon-Fekjær, H., Zaikova, O. & Bruland, Ø.S. Prognostic factors and treatment results of high-grade osteosarcoma in norway: a scope beyond the "classical" patient, *Sarcoma* 2015a;2015516843.
- Berner, K., Johannesen, T.B., Berner, A., Haugland, H.K., Bjerkehagen, B., Bohler, P.J. & Bruland, O.S. Time-trends on incidence and survival in a nationwide and unselected cohort of patients with skeletal osteosarcoma, *Acta Oncol.* 2015b;54(1):25-33.
- Berner, K., Johannesen, T.B. & Bruland, Ø.S. Clinical Epidemiology of Low-Grade and Dedifferentiated Osteosarcoma in Norway during 1975 and 2009, *Sarcoma* 2015c;2015917679.
- Berenthal, N.M., Schwartz, A.J., Oakes, D.A., Kabo, J.M. & Eckardt, J.J. How long do endoprosthetic reconstructions for proximal femoral tumors last? *Clin.Orthop.Relat.Res.* 2010;468(11):2867-2874.
- Bertrand, T.E., Cruz, A., Binitie, O., Cheong, D. & Letson, G.D. Do Surgical Margins Affect Local Recurrence and Survival in Extremity, Nonmetastatic, High-grade Osteosarcoma? *Clin Orthop Relat Res* 2016;474(3):677.
- Bhatia, S., Krailo, M.D., Chen, Z., Burden, L., Askin, F.B., Dickman, P.S., Grier, H.E., Link, M.P., Meyers, P.A., Perlman, E.J., Rausen, A.R., Robison, L.L., Vietti, T.J. & Miser, J.S. Therapy-related myelodysplasia and acute myeloid leukemia after Ewing sarcoma and primitive neuroectodermal tumor of bone: A report from the Children's Oncology Group, *Blood* 2007;109(1):46-51.
- Bielack, S.S. & Carrle, D. State-of-the-art approach in selective curable tumors: bone sarcoma, *Ann.Oncol.* 2008;19 Suppl 7vii155-60.
- Bielack, S.S., Kempf-Bielack, B., Delling, G., Exner, G.U., Flege, S., Helmke, K., Kotz, R., Salzer-Kuntschik, M., Werner, M., Winkelmann, W., Zoubek, A., Jürgens, H., Winkler, K. & for the Cooperative German-Austrian-Swiss Osteosarcoma Study Group Prognostic Factors in High-Grade Osteosarcoma of the Extremities or Trunk: An Analysis of 1,702 Patients Treated on Neoadjuvant Cooperative Osteosarcoma Study Group Protocols, *Journal of Clinical Oncology* 2002;20(3):776-790.
- Bielack, S.S., Smeland, S., Whelan, J.S., Marina, N., Jovic, G., Hook, J.M., Krailo, M.D., Gebhardt, M., Pápai, Z., Meyer, J., Nadel, H., Randall, R.L., Deffenbaugh, C., Nagarajan, R., Brennan, B., Letson, G.D., Teot, L.A., Goorin, A., Baumhoer, D., Kager, L., Werner, M., Lau, C.C., Sundby Hall, K., Gelderblom, H., Meyers, P., Gorlick, R., Windhager, R., Helmke, K., Eriksson, M., Hoogerbrugge, P.M., Schomberg, P.,

- Tunn, P., Kühne, T., Jürgens, H., van den Berg, H., Böhling, T., Picton, S., Renard, M., Reichardt, P., Gerss, J., Butterfass-Bahloul, T., Morris, C., Hogendoorn, P.C.W., Seddon, B., Calaminus, G., Michelagnoli, M., Dhooge, C., Sydes, M.R. & Bernstein, M. Methotrexate, Doxorubicin, and Cisplatin (MAP) Plus Maintenance Pegylated Interferon Alfa-2b Versus MAP Alone in Patients With Resectable High-Grade Osteosarcoma and Good Histologic Response to Preoperative MAP: First Results of the EURAMOS-1 Good Response Randomized Controlled Trial, *Journal of Clinical Oncology* 2015;33(20):2279-2287.
- Bindiganavile, S., Han, I., Yun, J.Y. & Kim, H.S. Long-term Outcome of Chondrosarcoma: A Single Institutional Experience, *Cancer.Res.Treat.* 2015;47(4):897-903.
- Bispo, R.Z.J. & de Camargo, O.P. Prognostic Factors in the Survival of Patients Diagnosed with Primary Non-Metastatic Osteosarcoma with a Poor Response to Neoadjuvant Chemotherapy, *Clinics* 2009;64(12):1177-1186.
- Bloem, J.L., Taminiou, A.H., Eulderink, F., Hermans, J. & Pauwels, E.K. Radiologic staging of primary bone sarcoma: MR imaging, scintigraphy, angiography, and CT correlated with pathologic examination, *Radiology* 1988;169(3):805-810.
- Boriani, S., Amendola, L., Corghi, A., Cappuccio, M., Bandiera, S., Ferrari, S., Picci, R., Difiore, M. & Gasbarrini, A. Ewing's sarcoma of the mobile spine, *Eur.Rev.Med.Pharmacol.Sci.* 2011;15(7):831-839.
- Boriani, S., Bandiera, S., Biagini, R., Bacchini, P., Boriani, L., Cappuccio, M., Chevalley, F., Gasbarrini, A., Picci, P. & Weinstein, J.N. Chordoma of the mobile spine: fifty years of experience, *Spine (Phila Pa.1976)* 2006;31(4):493-503.
- Boriani, S., De Iure, F., Bandiera, S., Campanacci, L., Biagini, R., Di Fiore, M., Bandello, L., Picci, P. & Bacchini, P. Chondrosarcoma of the mobile spine: report on 22 cases, *Spine (Phila Pa.1976)* 2000;25(7):804-812.
- Boriani, S., Weinstein, J.N. & Biagini, R. Primary bone tumors of the spine. Terminology and surgical staging, *Spine (Phila Pa.1976)* 1997;22(9):1036-1044.
- Bougeard, G., Sesboué, R., Baert-Desurmont, S., Vasseur, S., Martin, C., Tinat, J., Brugières, L., Chompret, A., Paillerets, B.B., Stoppa-Lyonnet, D., Bonaïti-Pellié, C. & Frébourg, T. Molecular basis of the Li-Fraumeni syndrome: an update from the French LFS families, *Journal of Medical Genetics* 2008;45(8):535-538.
- Boyer, C.W., Brickner, T.J. & Perry, R.H. Ewing's sarcoma. Case against surgery, *Cancer* 1967;20(10):1602-1606.
- Bramer, J.A.M., van Linge, J.H., Grimer, R.J. & Scholten, R.J. Prognostic factors in localized extremity osteosarcoma: a systematic review, *Eur.J.Surg.Oncol.* 2009;35(10):1030.
- Brasme, J. Time to diagnosis of Ewing tumors in children and adolescents is not associated with metastasis or survival: a prospective multicenter study of 436 patients, *J.Clin.Oncol.* 2014;32(18):1935.
- Brosjö, O. & Bauer, H.C. Diagnostic procedures and surgical treatment of bone sarcomas. Experience from the Scandinavian Sarcoma Group and Karolinska Hospital, *Acta Orthop.Scand.Suppl.* 2004;75(311):57-61.
- Bumpass, D.B., Lenke, L.G., Bridwell, K.H., Stallbaumer, J.J., Kim, Y.J., Wallendorf, M.J., Min, W.K. & Sides, B.A. Pulmonary function improvement after vertebral column resection for severe spinal deformity, *Spine (Phila Pa.1976)* 2014;39(7):587-595.
- Burdach, S., Jurgens, H., Peters, C., Nurnberger, W., Mauz-Korholz, C., Korholz, D., Paulussen, M., Pape, H., Dilloo, D. & Koscielniak, E. Myeloablative radiochemotherapy and hematopoietic stem-cell rescue in poor-prognosis Ewing's sarcoma, *J.Clin.Oncol.* 1993;11(8):1482-1488.
- Burningham, Z., Hashibe, M., Spector, L. & Schiffman, J.D. The epidemiology of sarcoma, *Clin.Sarcoma Res.* 2012;2(1):14-3329-2-14.
- Bus, M.P., Dijkstra, P.D., van de Sande, M.A., Taminiou, A.H., Schreuder, H.W., Jutte, P.C., van der Geest, I.C., Schaap, G.R. & Bramer, J.A. Intercalary allograft reconstructions following resection of primary bone tumors: a nationwide multicenter study, *J.Bone Joint Surg.Am.* 2014;96(4):e26.
- Campanacci, D.A., Dursky, S., Totti, F., Frenos, F., Scoccianti, G., Beltrami, G. & Capanna, R. Osteoarticular Allografts in Paediatric Bone Tumor Reconstruction of the Knee, *J.Biol.Regul.Homeost.Agents* 2015;29(4 Suppl):111-119.
- Cancer Therapy Evaluation Program, Common Toxicity Criteria, Version 2.0. DCTD, NCI, NIH, DHHS, 1998

- Cash, T., McIlvaine, E., Krailo, M.D., Lessnick, S.L., Lawlor, E.R., Laack, N., Sorger, J., Marina, N., Grier, H.E., Granowetter, L., Womer, R.B. & DuBois, S.G. Comparison of clinical features and outcomes in patients with extraskeletal versus skeletal localized Ewing sarcoma: A report from the Children's Oncology Group, *Pediatr.Blood Cancer*. 2016;63(10):1771-1779.
- Chen, S., Yang, L., Pu, F., Lin, H., Wang, B., Liu, J. & Shao, Z. High Birth Weight Increases the Risk for Bone Tumor: A Systematic Review and Meta-Analysis, *International Journal of Environmental Research and Public Health* 2015;12(9):11178-11195.
- Cipriano, C.A., Gruzinova, I.S., Frank, R.M., Gitelis, S. & Virkus, W.W. Frequent complications and severe bone loss associated with the repiphysis expandable distal femoral prosthesis, *Clin.Orthop.Relat.Res*. 2015;473(3):831-838.
- Cobb, J.R. Outline for the study of scoliosis, *Am Acad Orthop Surg Instr Course Lect*. 1948;5261-275.
- Cortes, E.P., Holland, J.F., Wang, J.J. & Sinks, L.F. Doxorubicin in disseminated osteosarcoma, *Jama* 1972;221(10):1132-1138.
- Cortes, E.P., Holland, J.F., Wang, J.J., Sinks, L.F., Blom, J., Senn, H., Bank, A. & Glidewell, O. Amputation and Adriamycin in Primary Osteosarcoma, *N.Engl.J.Med*. 1974;291(19):998-1000.
- Cotterill, S.J., Ahrens, S., Paulussen, M., Jurgens, H.F., Voute, P.A., Gadner, H. & Craft, A.W. Prognostic factors in Ewing's tumor of bone: analysis of 975 patients from the European Intergroup Cooperative Ewing's Sarcoma Study Group. *J.Clin.Oncol*. 2000;18(17):3108-3114.
- Cotterill, S.J., Wright, C.M., Pearce, M.S., Craft, A.W. & UKCCSG/MRC Bone Tumour Working Group Stature of young people with malignant bone tumors, *Pediatr.Blood Cancer*. 2004;42(1):59-63.
- Czajka, C.M. & DiCaprio, M.R. What is the Proportion of Patients With Multiple Hereditary Exostoses Who Undergo Malignant Degeneration? *Clin Orthop Relat Res* 2015;473(7):2355.
- Dagher, R., Pham, T.A., Sorbara, L., Kumar, S., Long, L., Bernstein, D., Mackall, C., Raffeld, M., Tsokos, M. & Helman, L. Molecular confirmation of Ewing sarcoma, *J.Pediatr.Hematol.Oncol*. 2001;23(4):221-224.
- Dahlin, D.C., Coventry, M.B. & Scanlon, P.W. Ewing's sarcoma. A critical analysis of 165 cases, *J.Bone Joint Surg.Am*. 1961;43-A185-192.
- D'cruze, L., Dutta, R., Rao, S., R, A., Varadarajan, S. & Kuruvilla, S. The role of immunohistochemistry in the analysis of the spectrum of small round cell tumours at a tertiary care centre, *J.Clin.Diagn.Res*. 2013;7(7):1377-1382.
- de Alava, E. & Gerald, W.L. Molecular biology of the Ewing's sarcoma/primitive neuroectodermal tumor family, *J.Clin.Oncol*. 2000;18(1):204-213.
- Dekutoski, M.B., Clarke, M.J., Rose, P., Luzzati, A., Rhines, L.D., Varga, P.P., Fisher, C.G., Chou, D., Fehlings, M.G., Reynolds, J.J., Williams, R., Quraishi, N.A., Germscheid, N.M., Sciubba, D.M., Gokaslan, Z.L., Boriani, S. & AOSpine Knowledge Forum Tumor Osteosarcoma of the spine: prognostic variables for local recurrence and overall survival, a multicenter ambispective study, *J.Neurosurg.Spine* 2016;25(1):59-68.
- DeLaney, T.F., Liebsch, N.J., Pedlow, F.X., Adams, J., Weyman, E.A., Yeap, B.Y., Depauw, N., Nielsen, G.P., Harmon, D.C., Yoon, S.S., Chen, Y.L., Schwab, J.H. & Hornicek, F.J. Long-term results of Phase II study of high dose photon/proton radiotherapy in the management of spine chordomas, chondrosarcomas, and other sarcomas, *J.Surg.Oncol*. 2014;110(2):115-122.
- Delattre, O., Zucman, J., Melot, T., Garau, X.S., Zucker, J.M., Lenoir, G.M., Ambros, P.F., Sheer, D., Turc-Carel, C. & Triche, T.J. The Ewing family of tumors--a subgroup of small-round-cell tumors defined by specific chimeric transcripts, *N.Engl.J.Med*. 1994;331(5):294-299.
- Denbo, J.W., Zhu, L., Srivastava, D., Stokes, D.C., Srinivasan, S., Hudson, M.M., Ness, K.K., Robison, L.L., Neel, M., Rao, B., Navid, F., Davidoff, A.M. & Green, D.M. Long-term pulmonary function after metastasectomy for childhood osteosarcoma: a report from the St Jude lifetime cohort study, *J.Am.Coll.Surg*. 2014;219(2):265-271.
- Doll, R., Payne, P. & Waterhouse, J. (eds) *Cancer Incidence in Five Continents: A Technical Report*, SpringerVerlag (for UICC), Berlin 1966.
- Dormans, J.P. & Moroz, L. Infection and tumors of the spine in children, *J.Bone Joint Surg.Am*. 2007;89 Suppl 179-97.



- Dotan, A., Dadia, S., Bickels, J., Nirkin, A., Flusser, G., Issakov, J., Neumann, Y., Cohen, I., Ben-Arush, M., Kollender, Y. & Meller, I. Expandable endoprosthesis for limb-sparing surgery in children: long-term results, *J.Child.Orthop.* 2010;4(5):391-400.
- Dreimann, M., Hoffmann, M., Kossow, K., Hitzl, W., Meier, O. & Koller, H. Scoliosis and chest cage deformity measures predicting impairments in pulmonary function: a cross-sectional study of 492 patients with scoliosis to improve the early identification of patients at risk, *Spine (Phila Pa.1976)* 2014;39(24):2024-2033.
- DuBois, S.G., Krailo, M.D., Gebhardt, M.C., Donaldson, S.S., Marcus, K.J., Dormans, J., Shamberger, R.C., Sailer, S., Nicholas, R.W., Healey, J.H., Tarbell, N.J., Randall, R.L., Devidas, M., Meyer, J.S., Granowetter, L., Womer, R.B., Bernstein, M., Marina, N. & Grier, H.E. Comparative evaluation of local control strategies in localized Ewing sarcoma of bone: A report from the Children's Oncology Group, *Cancer* 2015;121(3):467-475.
- Duchman, K.R., Gao, Y. & Miller, B.J. Prognostic factors for survival in patients with high-grade osteosarcoma using the Surveillance, Epidemiology, and End Results (SEER) Program database, *Cancer Epidemiol* 2015;39(4):593.
- Eckardt, J.J., Kobo, J.M., Kelley, C.M., Ward WG, S., Asavamongkolkul, A., Wirganowicz, P.Z., Yang, R.S. & Eilber, F.R. Expandable endoprosthesis reconstruction in skeletally immature patients with tumors, *Clin.Orthop.Relat.Res.* 2000;(373)(373):51-61.
- Edge, S.B., Byrd, D.R., Carducci, M.A., Compton, C.C., Fritz, A.G., Greene, F. & Trotti, A. (eds) American Joint Committee on Cancer (AJCC). *Cancer Staging Manual*, 7th edn, Springer, New York 2009.
- El Weshi, A., Allam, A., Ajarim, D., Al Dayel, F., Pant, R., Bazarbashi, S. & Memon, M. Extraskelatal Ewing's sarcoma family of tumours in adults: analysis of 57 patients from a single institution, *Clin.Oncol.(R.Coll.Radiol)* 2010;22(5):374-381.
- Elomaa, I., Blomqvist, C.P., Saeter, G., Akerman, M., Stenwig, E., Wiebe, T., Bjork, O. & Alvegard, T.A. Five-year results in Ewing's sarcoma. The Scandinavian Sarcoma Group experience with the SSG IX protocol, *Eur.J.Cancer* 2000;36(7):875-880.
- Enneking, W.F., Spanier, S.S. & Goodman, M.A. A system for the surgical staging of musculoskeletal sarcoma, *Clin.Orthop.Relat.Res.* 1980;top(153):106-120.
- Esiashvili, N., Goodman, M. & Marcus, R.B., Jr Changes in incidence and survival of Ewing sarcoma patients over the past 3 decades: Surveillance Epidemiology and End Results data, *J.Pediatr.Hematol.Oncol.* 2008;30(6):425-430.
- ESMO/European Sarcoma Network Working Group Bone sarcomas: ESMO Clinical Practice Guidelines for diagnosis, treatment and follow-up, *Ann.Oncol.* 2014;25 Suppl 3iii113-23.
- Euro EWING 2012, EudraCT number: 2012-002107-17. Available: <https://www.clinicaltrialsregister.eu> [2015, 10/23].
- Ewing 2008, EudraCT Number: 2008-003658-13. Available: <https://www.clinicaltrialsregister.eu> [2015, 10/23].
- Ewing, J. Diffuse endothelioma of bone. *Proc NY Pathol Soc* 1921;2117-24.
- Eyre, R., Feltbower, R.G., Mubwandarikwa, E., Eden, T.O. & McNally, R.J. Epidemiology of bone tumours in children and young adults, *Pediatr.Blood Cancer.* 2009a;53(6):941-952.
- Eyre, R., Feltbower, R.G., Mubwandarikwa, E., Jenkinson, H.C., Parkes, S., Birch, J.M., Eden, T.O., James, P.W., McKinney, P.A., Pearce, M.S. & McNally, R.J. Incidence and survival of childhood bone cancer in northern England and the West Midlands, 1981-2002, *Br.J.Cancer* 2009b;100(1):188-193.
- Farfalli, G.L., Albergo, J.I., Ritacco, L.E., Ayerza, M.A., Muscolo, D.L. & Aponte-Tinao, L.A. Oncologic and clinical outcomes in pelvic primary bone sarcomas treated with limb salvage surgery, *Musculoskelet.Surg.* 2015;
- Ferrari, S., Bertoni, F., Mercuri, M., Picci, P., Giacomini, S., Longhi, A. & Bacci, G. Predictive factors of disease-free survival for non-metastatic osteosarcoma of the extremity: an analysis of 300 patients treated at the Rizzoli Institute, *Ann.Oncol.* 2001;12(8):1145-1150.
- Ferrari, S., Luksch, R., Hall, K.S., Fagioli, F., Prete, A., Tamburini, A., Tienghi, A., DiGirolamo, S., Paioli, A., Abate, M.E., Podda, M., Cammelli, S., Eriksson, M. & Brach del Prever, A. Post-relapse survival in patients with Ewing sarcoma, *Pediatr.Blood Cancer.* 2015;62(6):994-999.

- Ferrari, S., Sundby Hall, K., Luksch, R., Tienghi, A., Wiebe, T., Fagioli, F., Alvegard, T.A., Brach Del Prever, A., Tamburini, A., Alberghini, M., Gandola, L., Mercuri, M., Capanna, R., Mapelli, S., Prete, A., Carli, M., Picci, P., Barbieri, E., Bacci, G. & Smeland, S. Nonmetastatic Ewing family tumors: high-dose chemotherapy with stem cell rescue in poor responder patients. Results of the Italian Sarcoma Group/Scandinavian Sarcoma Group III protocol, *Ann.Oncol.* 2011;22(5):1221-1227.
- Fidler, M.M., Frobisher, C., Guha, J., Wong, K., Kelly, J., Winter, D.L., Sugden, E., Duncan, R., Whelan, J., Reulen, R.C. & Hawkins, M.M. Long-term adverse outcomes in survivors of childhood bone sarcoma: the British Childhood Cancer Survivor Study, *Br.J.Cancer* 2015;112(12):1857-1865.
- Fletcher, C.D.M., Hogendoorn, P.C., Mertens, F. & Bridge, J. (eds) WHO Classification of Tumours of Soft Tissue and Bone., 4th ed. edn, IARC Press, Lyon, France 2013.
- Foulon, S., Brennan, B., Gaspar, N., Dirksen, U., Jeys, L., Cassoni, A., Claude, L., Seddon, B., Marec-Berard, P., Whelan, J., Paulussen, M., Streitbuerger, A., Oberlin, O., Juergens, H., Grimer, R. & Le Deley, M.C. Can postoperative radiotherapy be omitted in localised standard-risk Ewing sarcoma? An observational study of the Euro-E.W.I.N.G group, *Eur.J.Cancer* 2016;61128-136
- Friend, S.H., Bernards, R., Rogelji, S., Weinberg, R.A., Rapaport, J.M., Albert, D.M. & Dryja, T.P. A human DNA segment with properties of the gene that predisposes to retinoblastoma and osteosarcoma, *Nature* 1986;323(6089):643-646.
- Fröstad, B., Tani, E., Brosjo, O., Skoog, L. & Kogner, P. Fine needle aspiration cytology in the diagnosis and management of children and adolescents with Ewing sarcoma and peripheral primitive neuroectodermal tumor, *Med.Pediatr.Oncol.* 2002;38(1):33-40.
- Frouge, C., Vanel, D., Coffre, C., Couanet, D., Contesso, G. & Sarrazin, D. The role of magnetic resonance imaging in the evaluation of Ewing sarcoma. A report of 27 cases, *Skeletal Radiol.* 1988;17(6):387-392.
- Futani, H., Minamizaki, T., Nishimoto, Y., Abe, S., Yabe, H. & Ueda, T. Long-term follow-up after limb salvage in skeletally immature children with a primary malignant tumor of the distal end of the femur, *J.Bone Joint Surg.Am.* 2006;88(3):595-603.
- Gaspar, N., Hawkins, D.S., Dirksen, U., Lewis, I.J., Ferrari, S., Le Deley, M.C., Kovar, H., Grimer, R., Whelan, J., Claude, L., Delattre, O., Paulussen, M., Picci, P., Sundby Hall, K., van den Berg, H., Ladenstein, R., Michon, J., Hjorth, L., Judson, I., Luksch, R., Bernstein, M.L., Marec-Berard, P., Brennan, B., Craft, A.W., Womer, R.B., Juergens, H. & Oberlin, O. Ewing Sarcoma: Current Management and Future Approaches Through Collaboration, *J.Clin.Oncol.* 2015;33(27):3036-3046.
- Gaspar, N., Rey, A., Berard, P.M., Michon, J., Gentet, J.C., Tabone, M.D., Roche, H., Defachelles, A.S., Lejars, O., Plouvier, E., Schmitt, C., Bui, B., Boutard, P., Taque, S., Munzer, M., Vannier, J.P., Plantaz, D., Entz-Werle, N. & Oberlin, O. Risk adapted chemotherapy for localised Ewing's sarcoma of bone: the French EW93 study, *Eur.J.Cancer* 2012;48(9):1376-1385.
- Gatta, G., Botta, L., Rossi, S., Aareleid, T., Bielska-Lasota, M., Clavel, J., Dimitrova, N., Jakab, Z., Kaatsch, P., Lacour, B., Mallone, S., Marcos-Gragera, R., Minicozzi, P., Sanchez-Perez, M.J., Sant, M., Santaquilani, M., Stiller, C., Tavilla, A., Trama, A., Visser, O., Peris-Bonet, R. & EURO CARE Working Group Childhood cancer survival in Europe 1999-2007: results of EURO CARE-5--a population-based study, *Lancet Oncol.* 2014;15(1):35-47.
- Ginsberg, J.P., Goodman, P., Leisenring, W., Ness, K.K., Meyers, P.A., Wolden, S.L., Smith, S.M., Stovall, M., Hammond, S., Robison, L.L. & Oeffinger, K.C. Long-term survivors of childhood Ewing sarcoma: report from the childhood cancer survivor study, *J.Natl.Cancer Inst.* 2010;102(16):1272-1283.
- Gitelman, Y., Lenke, L.G., Bridwell, K.H., Auerbach, J.D. & Sides, B.A. Pulmonary function in adolescent idiopathic scoliosis relative to the surgical procedure: a 10-year follow-up analysis, *Spine (Phila Pa.1976)* 2011;36(20):1665-1672.
- Giuffrida, A.Y., Burgueno, J.E., Koniaris, L.G., Gutierrez, J.C., Duncan, R. & Scully, S.P. Chondrosarcoma in the United States (1973 to 2003): An Analysis of 2890 Cases from the SEER Database, *Journal of Bone & Joint Surgery - American Volume* 2009;91-A(5):1063-1072.
- Glassman, S.D., Hamill, C.L., Bridwell, K.H., Schwab, F.J., Dimar, J.R. & Lowe, T.G. The impact of perioperative complications on clinical outcome in adult deformity surgery, *Spine (Phila Pa.1976)* 2007;32(24):2764-2770.

- Goyal, S., Roscoe, J., Ryder, W.D., Gattamaneni, H.R. & Eden, T.O. Symptom interval in young people with bone cancer, *Eur.J.Cancer* 2004;40(15):2280-2286.
- Granowetter, L., Womer, R., Devidas, M., Krailo, M., Wang, C., Bernstein, M., Marina, N., Leavey, P., Gebhardt, M., Healey, J., Shamberger, R.C., Goorin, A., Miser, J., Meyer, J., Arndt, C.A., Sailer, S., Marcus, K., Perlman, E., Dickman, P. & Grier, H.E. Dose-intensified compared with standard chemotherapy for nonmetastatic Ewing sarcoma family of tumors: a Children's Oncology Group Study, *J.Clin.Oncol.* 2009;27(15):2536-2541.
- Grier, H.E., Krailo, M.D., Tarbell, N.J., Link, M.P., Fryer, C.J., Pritchard, D.J., Gebhardt, M.C., Dickman, P.S., Perlman, E.J., Meyers, P.A., Donaldson, S.S., Moore, S., Rausen, A.R., Vietti, T.J. & Miser, J.S. Addition of ifosfamide and etoposide to standard chemotherapy for Ewing's sarcoma and primitive neuroectodermal tumor of bone. *N.Engl.J.Med.* 2003;348(8):694-701.
- Griesser, M.J., Gillette, B., Crist, M., Pan, X., Muscarella, P., Scharschmidt, T. & Mayerson, J. Internal and external hemipelvectomy or flail hip in patients with sarcomas: quality-of-life and functional outcomes, *Am.J.Phys.Med.Rehabil.* 2012;91(1):24-32.
- Grimer, R.J., Aydin, B.K., Wafa, H., Carter, S.R., Jeys, L., Abudu, A. & Parry, M. Very long-term outcomes after endoprosthetic replacement for malignant tumours of bone, *Bone Joint J* 2016;98-B(6):857-864.
- Haeusler, J., Ranft, A., Boelling, T., Gosheger, G., Braun-Munzinger, G., Vieth, V., Burdach, S., van den Berg, H., Juergens, H. & Dirksen, U. The value of local treatment in patients with primary, disseminated, multifocal Ewing sarcoma (PDMES), *Cancer* 2010;116(2):443-450.
- Haer, T.R., Gorup, J.M., Shin, T.M., Homel, P., Merola, A.A., Grogan, D.P., Pugh, L., Lowe, T.G. & Murray, M. Results of the Scoliosis Research Society instrument for evaluation of surgical outcome in adolescent idiopathic scoliosis. A multicenter study of 244 patients, *Spine (Phila Pa.1976)* 1999;24(14):1435-1440.
- Ham, S.J., Schraffordt Koops, H., Veth, R.P., van Horn, J.R., Molenaar, W.M. & Hoekstra, H.J. Limb salvage surgery for primary bone sarcoma of the lower extremities: long-term consequences of endoprosthetic reconstructions, *Ann.Surg.Oncol.* 1998;5(5):423-436.
- Harimaya, K., Oda, Y., Matsuda, S., Tanaka, K., Chuman, H. & Iwamoto, Y. Primitive neuroectodermal tumor and extraskeletal Ewing sarcoma arising primarily around the spinal column: report of four cases and a review of the literature, *Spine (Phila Pa.1976)* 2003;28(19):E408-12.
- Harting, M.T., Lally, K.P., Andrassy, R.J., Vaporciyan, A.A., Cox, C.S.J., Hayes-Jordan, A. & Blakely, M.L. Age as a prognostic factor for patients with osteosarcoma: an analysis of 438 patients, *J.Cancer Res.Clin.Oncol.* 2010;136(4):561.
- Hartley, A.L., Birch, J.M., McKinney, P.A., Teare, M.D., Blair, V., Carrette, J., Mann, J.R., Draper, G.J., Stiller, C.A. & Johnston, H.E. The Inter-Regional Epidemiological Study of Childhood Cancer (IRESCC): case control study of children with bone and soft tissue sarcomas, *Br.J.Cancer* 1988;58(6):838-842.
- Hillmann, A., Hoffmann, C., Gosheger, G., Rodl, R., Winkelmann, W. & Ozaki, T. Tumors of the pelvis: complications after reconstruction, *Arch.Orthop.Trauma.Surg.* 2003;123(7):340-344.
- Hobusch, G.M., Lang, N., Schuh, R., Windhager, R. & Hofstaetter, J.G. Do patients with ewing's sarcoma continue with sports activities after limb salvage surgery of the lower extremity? *Clin.Orthop.Relat.Res.* 2015;473(3):839-846.
- Honoki, K., Stojanovski, E., McEvoy, M., Fujii, H., Tsujiuchi, T., Kido, A., Takakura, Y. & Attia, J. Prognostic significance of p16 INK4a alteration for Ewing sarcoma: a meta-analysis, *Cancer* 2007;110(6):1351-1360.
- Hopyan, S., Tan, J.W., Graham, H.K. & Torode, I.P. Function and upright time following limb salvage, amputation, and rotationplasty for pediatric sarcoma of bone, *J.Pediatr.Orthop.* 2006;26(3):405-408.
- Hosalkar, H.S. & Dormans, J.P. Limb sparing surgery for pediatric musculoskeletal tumors, *Pediatr.Blood Cancer.* 2004;42(4):295-310.
- Huang, H.Y., Illei, P.B., Zhao, Z., Mazumdar, M., Huvos, A.G., Healey, J.H., Wexler, L.H., Gorlick, R., Meyers, P. & Ladanyi, M. Ewing sarcomas with p53 mutation or p16/p14ARF homozygous deletion: a highly lethal subset associated with poor chemoresponse, *J.Clin.Oncol.* 2005;23(3):548-558.
- Hum, L., Kreiger, N. & Finkelstein, M.M. The relationship between parental occupation and bone cancer risk in offspring, *Int.J.Epidemiol.* 1998;27(5):766-771.

- Hung, G.Y., Horng, J.L., Yen, H.J., Yen, C.C., Chen, W.M., Chen, P.C., Wu, H.T. & Chiou, H.J. Incidence patterns of primary bone cancer in taiwan (2003-2010): a population-based study, *Ann.Surg.Oncol.* 2014;21(8):2490-2498.
- Hustu, H.O., Pinkei, D. & Pratt, C.B. Treatment of clinically localized Ewing's sarcoma with radiotherapy and combination chemotherapy, *Cancer* 1972;30(6):1522-1527.
- Huvos, A. (ed) *Bone tumors: Diagnosis, treatment and prognosis.*, 2nd edn, W.B.Saunders, Philadelphia 1991.
- Isakoff, M.S., Bielack, S.S., Meltzer, P. & Gorlick, R. Osteosarcoma: Current Treatment and a Collaborative Pathway to Success, *Journal of Clinical Oncology* 2015;33(27):3029-3035.
- Iyer, S., Nemani, V.M. & Kim, H.J. A Review of Complications and Outcomes following Vertebral Column Resection in Adults, *Asian Spine J.* 2016;10(3):601-609.
- Jaffe, N. Recent advances in the chemotherapy of metastatic osteogenic sarcoma, *Cancer* 1972;30(6):1627-1631.
- Jaffe, N., Frei, E., Traggis, D. & Bishop, Y. Adjuvant Methotrexate and Citrovorum-Factor Treatment of Osteogenic Sarcoma, *N.Engl.J.Med.* 1974;291(19):994-997.
- Jahnukainen, K., Kallio, P., Koivusalo, A. & Saarinen-Pihkala, U.M. High-dose Thiotepa as Consolidation Therapy With Autologous Hematopoietic Stem Cell Transplantation for High-risk Ewing Family Tumors: Single-institution Experience, *J.Pediatr.Hematol.Oncol.* 2015;37(7):536-542.
- Jansen, J.A., van de Sande, M.A. & Dijkstra, P.D. Poor long-term clinical results of saddle prosthesis after resection of periacetabular tumors, *Clin.Orthop.Relat.Res.* 2013;471(1):324-331.
- Jawad, M.U., Cheung, M.C., Min, E.S., Schneiderbauer, M.M., Koniaris, L.G. & Scully, S.P. Ewing sarcoma demonstrates racial disparities in incidence-related and sex-related differences in outcome: an analysis of 1631 cases from the SEER database, 1973-2005, *Cancer* 2009;115(15):3526-3536.
- Jeon, I.S., Davis, J.N., Braun, B.S., Sublett, J.E., Rousel, M.F., Denny, C.T. & Shapiro, D.N. A variant Ewing's sarcoma translocation (7;22) fuses the EWS gene to the ETS gene ETV1, *Oncogene* 1995;10(6):1229-1234.
- Jeys, L.M., Grimer, R.J., Carter, S.R. & Tillman, R.M. Periprosthetic infection in patients treated for an orthopaedic oncological condition, *J.Bone Joint Surg.Am.* 2005;87(4):842-849.
- Jeys, L.M., Kulkarni, A., Grimer, R.J., Carter, S.R., Tillman, R.M. & Abudu, A. Endoprosthetic reconstruction for the treatment of musculoskeletal tumors of the appendicular skeleton and pelvis, *J.Bone Joint Surg.Am.* 2008;90(6):1265-1271.
- Juergens, C., Weston, C., Lewis, I., Whelan, J., Paulussen, M., Oberlin, O., Michon, J., Zoubek, A., Juergens, H. & Craft, A. Safety assessment of intensive induction with vincristine, ifosfamide, doxorubicin, and etoposide (VIDE) in the treatment of Ewing tumors in the EURO-E.W.I.N.G. 99 clinical trial, *Pediatr.Blood Cancer.* 2006;47(1):22-29.
- Kaloostian, P.E., Zadnik, P.L., Etame, A.B., Vrionis, F.D., Gokaslan, Z.L. & Sciubba, D.M. Surgical management of primary and metastatic spinal tumors, *Cancer Control* 2014;21(2):133-139.
- Kansara, M. & Thomas, D.M. Molecular pathogenesis of osteosarcoma, *DNA Cell Biol.* 2007;26(1):1.
- Kelley, S.P., Ashford, R.U., Rao, A.S. & Dickson, R.A. Primary bone tumours of the spine: a 42-year survey from the Leeds Regional Bone Tumour Registry, *European Spine Journal* 2006;16(3):405-409.
- Kim, S., Ott, H.C., Wright, C.D., Wain, J.C., Morse, C., Gaissert, H.A., Donahue, D.M., Mathisen, D.J. & Lanuti, M. Pulmonary resection of metastatic sarcoma: prognostic factors associated with improved outcomes, *Ann.Thorac.Surg.* 2011;92(5):1780-6; discussion 1786-7.
- Kim, W., Han, I., Kim, E.J., Kang, S. & Kim, H.S. Outcomes of curettage and anhydrous alcohol adjuvant for low-grade chondrosarcoma of long bone, *Surg.Oncol.* 2015;24(2):89.
- Kivioja, A., Ervasti, H., Kinnunen, J., Kaitila, I., Wolf, M. & Böhling, T. Chondrosarcoma in a family with multiple hereditary exostoses, *Bone & Joint Journal* 2000;82-B(2):261-266.
- Klein, M.J. "Chapter 17 - Ewing Sarcoma" in *Bone and Soft Tissue Pathology*, eds. A.L. Folpe & C.Y. Inwards. W.B. Saunders, Philadelphia 2010 p. 367-378.
- Klijanienko, J., Couturier, J., Bourdeaut, F., Freneaux, P., Ballet, S., Brisse, H., Lagace, R., Delattre, O., Pierron, G., Vielh, P., Sastre-Garau, X. & Michon, J. Fine-needle aspiration as a diagnostic technique in

- 50 cases of primary Ewing sarcoma/peripheral neuroectodermal tumor. Institut Curie's experience, *Diagn.Cytopathol.* 2012;40(1):19-25.
- Knutson, G.A. Anatomic and functional leg-length inequality: A review and recommendation for clinical decision-making. Part I, anatomic leg-length inequality: prevalence, magnitude, effects and clinical significance, *Chiropractic & Osteopathy* 2005;1311-11.
- Kolb, E.A., Kushner, B.H., Gorlick, R., Laverdiere, C., Healey, J.H., LaQuaglia, M.P., Huvos, A.G., Qin, J., Vu, H.T., Wexler, L., Wolden, S. & Meyers, P.A. Long-term event-free survival after intensive chemotherapy for Ewing's family of tumors in children and young adults, *J.Clin.Oncol.* 2003;21(18):3423-3430.
- Kopp, L.M., Hu, C., Rozo, B., White-Collins, A., Huh, W.W., Yarborough, A., Herzog, C.E. & Hingorani, P. Utility of bone marrow aspiration and biopsy in initial staging of Ewing sarcoma, *Pediatr.Blood Cancer.* 2015;62(1):12-15.
- Kovar, H. Dr. Jekyll and Mr. Hyde: The Two Faces of the FUS/EWS/TAF15 Protein Family, *Sarcoma* 2011;2011837474.
- Krieg, A.H., Mani, M., Speth, B.M. & Stalley, P.D. Extracorporeal irradiation for pelvic reconstruction in Ewing's sarcoma. *J.Bone Joint Surg.Br.* 2009;91(3):395-400.
- La, T.H., Meyers, P.A., Wexler, L.H., Alektiar, K.M., Healey, J.H., Laquaglia, M.P., Boland, P.J. & Wolden, S.L. Radiation therapy for Ewing's sarcoma: results from Memorial Sloan-Kettering in the modern era, *Int.J.Radiat.Oncol.Biol.Phys.* 2006;64(2):544-550.
- Ladenstein, R., Lasset, C., Pinkerton, R., Zucker, J.M., Peters, C., Burdach, S., Pardo, N., Dallorso, S. & Coze, C. Impact of megatherapy in children with high-risk Ewing's tumours in complete remission: a report from the EBMT Solid Tumour Registry, *Bone Marrow Transplant.* 1995;15(5):697-705.
- Ladenstein, R., Potschger, U., Le Deley, M.C., Whelan, J., Paulussen, M., Oberlin, O., van den Berg, H., Dirksen, U., Hjorth, L., Michon, J., Lewis, I., Craft, A. & Jurgens, H. Primary disseminated multifocal Ewing sarcoma: results of the Euro-EWING 99 trial, *J.Clin.Oncol.* 2010;28(20):3284-3291.
- Laitinen, M., Parry, M., Albergo, J.I., Jeys, L., Sumathi, V. & Grimer, R. Outcome of Pelvic Bone Sarcomas in Children, *J.Pediatr.Orthop.* 2016;
- Lawlor, E.R. & Sorensen, P.H. Twenty Years on: What Do We Really Know about Ewing Sarcoma and What Is the Path Forward? *Crit.Rev.Oncog.* 2015;20(3-4):155-171.
- Le Deley, M.C., Paulussen, M., Lewis, I., Brennan, B., Ranft, A., Whelan, J., Le Teuff, G., Michon, J., Ladenstein, R., Marec-Berard, P., van den Berg, H., Hjorth, L., Wheatley, K., Judson, I., Juergens, H., Craft, A., Oberlin, O. & Dirksen, U. Cyclophosphamide compared with ifosfamide in consolidation treatment of standard-risk Ewing sarcoma: results of the randomized noninferiority Euro-EWING99-R1 trial, *J.Clin.Oncol.* 2014;32(23):2440-2448.
- Leatherman, K.D. & Dickson, R.A. Two-stage corrective surgery for congenital deformities of the spine, *J.Bone Joint Surg.Br.* 1979;61-B(3):324-328.
- Leddy, L.R. & Holmes, R.E. Chondrosarcoma of bone, *Cancer Treat.Res.* 2014;162117.
- Lee, J., Hoang, B.H., Ziogas, A. & Zell, J.A. Analysis of prognostic factors in Ewing sarcoma using a population-based cancer registry, *Cancer* 2010;116(8):1964-1973.
- Lenke, L.G., Newton, P.O., Sucato, D.J., Shuffelbarger, H.L., Emans, J.B., Sponseller, P.D., Shah, S.A., Sides, B.A. & Blanke, K.M. Complications after 147 consecutive vertebral column resections for severe pediatric spinal deformity: a multicenter analysis, *Spine (Phila Pa.1976)* 2013;38(2):119-132.
- Lenke, L.G., O'Leary, P.T., Bridwell, K.H., Sides, B.A., Koester, L.A. & Blanke, K.M. Posterior vertebral column resection for severe pediatric deformity: minimum two-year follow-up of thirty-five consecutive patients, *Spine (Phila Pa.1976)* 2009;34(20):2213-2221.
- Lenke, L.G., Sides, B.A., Koester, L.A., Hensley, M. & Blanke, K.M. Vertebral column resection for the treatment of severe spinal deformity, *Clin.Orthop.Relat.Res.* 2010;468(3):687-699.
- Letourneau, P.A., Shackett, B., Xiao, L., Trent, J., Tsao, K.J., Lally, K. & Hayes-Jordan, A. Resection of pulmonary metastases in pediatric patients with Ewing sarcoma improves survival, *J.Pediatr.Surg.* 2011;46(2):332-335.
- Lewis, V.O. Limb salvage in the skeletally immature patient, *Curr.Oncol.Rep.* 2005;7(4):285-292.

- Li, X., Moretti, V.M., Ashana, A.O. & Lackman, R.D. Impact of close surgical margin on local recurrence and survival in osteosarcoma, *Int.Orthop.* 2012;36(1):131-137.
- Lievre, J.A., Darcy, M., Pradat, P., Camus, J.P., Benichou, C., Attali, P. & Joublin, M. Giant cell tumor of the lumbar spine; total spondylectomy in 2 states, *Rev.Rhum.Mal.Osteoartic.* 1968;35(3):125-130.
- Lin, P.P., Jaffe, N., Herzog, C.E., Costelloe, C.M., Deavers, M.T., Kelly, J.S., Patel, S.R., Madewell, J.E., Lewis, V.O., Cannon, C.P., Benjamin, R.S. & Yasko, A.W. Chemotherapy response is an important predictor of local recurrence in Ewing sarcoma, *Cancer* 2007;109(3):603-611.
- Link, M.P., Goorin, A.M., Horowitz, M., Meyer, W.H., Belasco, J., Baker, A., Ayala, A. & Shuster, J. Adjuvant chemotherapy of high-grade osteosarcoma of the extremity. Updated results of the Multi-Institutional Osteosarcoma Study, *Clin Orthop Relat Res* 1991;(270):8.
- Lipton, J.M., Federman, N., Khabbaze, Y., Schwartz, C.L., Hilliard, L.M., Clark, J.I. & Vlachos, A. Osteogenic Sarcoma Associated With Diamond-Blackfan Anemia: A Report From the Diamond-Blackfan Anemia Registry, *Journal of Pediatric Hematology/Oncology* 2001;23(1):.
- Ludwig, J.A. Ewing sarcoma: historical perspectives, current state-of-the-art, and opportunities for targeted therapy in the future, *Curr.Opin.Oncol.* 2008;20(4):412-418.
- Luksch, R., Tienghi, A., Hall, K.S., Fagioli, F., Picci, P., Barbieri, E., Gandola, L., Eriksson, M., Ruggieri, P., Daolio, P., Lindholm, P., Prete, A., Bisogno, G., Tamburini, A., Grignani, G., Abate, M.E., Podda, M., Smeland, S. & Ferrari, S. Primary metastatic Ewing's family tumors: results of the Italian Sarcoma Group and Scandinavian Sarcoma Group ISG/SSG IV Study including myeloablative chemotherapy and total-lung irradiation, *Ann.Oncol.* 2012;23(11):2970-2976.
- MacLennan, A. Scoliosis, *Bmj* 1922;2865-866.
- Malkin, D., Li, F., Strong, L., Fraumeni, J., Nelson, C., Kim, D., Kassel, J., Gryka, M., Bischoff, F., Tainsky, M. & et, a. Germ line p53 mutations in a familial syndrome of breast cancer, sarcomas, and other neoplasms, *Science* 1990;250(4985):1233-1238.
- Marcove, R.C., Mike, V., Hajek, J.V., Levin, A.G. & Hutter, R.V. Osteogenic sarcoma under the age of twenty-one. A review of one hundred and forty-five operative cases, *J.Bone Joint Surg.Am.* 1970;52(3):411-423.
- Marina, N.M., Smeland, S., Bielack, S.S., Bernstein, M., Jovic, G., Krailo, M.D., Hook, J.M., Arndt, C., van den Berg, H., Brennan, B., Brichard, B., Brown, K.L., Butterfass-Bahloul, T., Calaminus, G., Daldrup-Link, H.E., Eriksson, M., Gebhardt, M.C., Gelderblom, H., Gerss, J., Goldsby, R., Goorin, A., Gorlick, R., Grier, H.E., Hale, J.P., Hall, K.S., Harges, J., Hawkins, D.S., Helmke, K., Hogendoorn, P.C., Isakoff, M.S., Janeway, K.A., Jurgens, H., Kager, L., Kuhne, T., Lau, C.C., Leavey, P.J., Lessnick, S.L., Mascarenhas, L., Meyers, P.A., Mottl, H., Nathrath, M., Papai, Z., Randall, R.L., Reichardt, P., Renard, M., Safwat, A.A., Schwartz, C.L., Stevens, M.C., Strauss, S.J., Teot, L., Werner, M., Sydes, M.R. & Whelan, J.S. Comparison of MAPIE versus MAP in patients with a poor response to preoperative chemotherapy for newly diagnosed high-grade osteosarcoma (EURAMOS-1): an open-label, international, randomised controlled trial, *Lancet Oncol.* 2016;17(10):1396-1408.
- McTiernan, A., Driver, D., Michelagnoli, M.P., Kilby, A.M. & Whelan, J.S. High dose chemotherapy with bone marrow or peripheral stem cell rescue is an effective treatment option for patients with relapsed or progressive Ewing's sarcoma family of tumours, *Ann.Oncol.* 2006;17(8):1301-1305.
- Meazza, C., Luksch, R., Daolio, P., Podda, M., Luzzati, A., Gronchi, A., Parafioriti, A., Gandola, L., Collini, P., Ferrari, A., Casanova, M., Terenziani, M., Spreafico, F., Polastri, D., Biassoni, V., Schiavello, E., Pecori, E. & Massimino, M. Axial skeletal osteosarcoma: a 25-year monoinstitutional experience in children and adolescents, *Med.Oncol.* 2014;31(4):875.
- Meyers, P.A., Krailo, M.D., Ladanyi, M., Chan, K.W., Sailer, S.L., Dickman, P.S., Baker, D.L., Davis, J.H., Gerbing, R.B., Grovas, A., Herzog, C.E., Lindsley, K.L., Liu-Mares, W., Nachman, J.B., Sieger, L., Wadman, J. & Gorlick, R.G. High-dose melphalan, etoposide, total-body irradiation, and autologous stem-cell reconstitution as consolidation therapy for high-risk Ewing's sarcoma does not improve prognosis, *J.Clin.Oncol.* 2001;19(11):2812-2820.
- Mirabello, L., Pfeiffer, R., Murphy, G., Daw, N.C., Patino-Garcia, A., Troisi, R.J., Hoover, R.N., Douglass, C., Schuz, J., Craft, A.W. & Savage, S.A. Height at diagnosis and birth-weight as risk factors for osteosarcoma, *Cancer Causes Control* 2011;22(6):899-908.

- Mirabello, L., Troisi, R.J. & Savage, S.A. Osteosarcoma incidence and survival rates from 1973 to 2004: data from the Surveillance, Epidemiology, and End Results Program, *Cancer* 2009;115(7):1531-1543.
- Mirzaei, L., Kaal, S.E., Schreuder, H.W. & Bartels, R.H. The Neurological Compromised Spine Due to Ewing Sarcoma. What First: Surgery or Chemotherapy? Therapy, Survival, and Neurological Outcome of 15 Cases With Primary Ewing Sarcoma of the Vertebral Column, *Neurosurgery* 2015;77(5):718-24; discussion 724-5.
- Mohney, B.G., Robertson, D.M., Schomberg, P.J. & Hodge, D.O. Second nonocular tumors in survivors of heritable retinoblastoma and prior radiation therapy, *Am.J.Ophthalmol.* 1998;126(2):269-277.
- Moll, A.C., Imhof, S.M., Schouten-Van Meeteren, A.Y., Kuik, D.J., Hofman, P. & Boers, M. Second primary tumors in hereditary retinoblastoma: a register-based study, 1945-1997: is there an age effect on radiation-related risk? *Ophthalmology* 2001;108(6):1109-1114.
- Monument, M.J., Johnson, K.M., Grossmann, A.H., Schiffman, J.D., Randall, R.L. & Lessnick, S.L. Microsatellites with macro-influence in ewing sarcoma, *Genes (Basel)* 2012;3(3):444-460.
- Mukherjee, D., Chaichana, K.L., Gokaslan, Z.L., Aaronson, O., Cheng, J.S. & McGirt, M.J. Survival of patients with malignant primary osseous spinal neoplasms: results from the Surveillance, Epidemiology, and End Results (SEER) database from 1973 to 2003, *J.Neurosurg.Spine* 2011;14(2):143-150.
- Mukherjee, D., Chaichana, K.L., Parker, S.L., Gokaslan, Z.L. & McGirt, M.J. Association of surgical resection and survival in patients with malignant primary osseous spinal neoplasms from the Surveillance, Epidemiology, and End Results (SEER) database, *Eur.Spine J.* 2013;22(6):1375-1382.
- Murphey, M.D., Senchak, L.T., Mambalam, P.K., Logie, C.I., Klassen-Fischer, M.K. & Kransdorf, M.J. From the radiologic pathology archives: ewing sarcoma family of tumors: radiologic-pathologic correlation, *Radiographics* 2013;33(3):803-831.
- Musco, D.L., Ayerza, M.A., Aponte-Tinao, L. & Farfalli, G. Allograft reconstruction after sarcoma resection in children younger than 10 years old, *Clin.Orthop.Relat.Res.* 2008;466(8):1856-1862.
- Newman, E.N., Jones, R.L. & Hawkins, D.S. An evaluation of [F-18]-fluorodeoxy-D-glucose positron emission tomography, bone scan, and bone marrow aspiration/biopsy as staging investigations in Ewing sarcoma, *Pediatr.Blood Cancer.* 2013;60(7):1113-1117.
- Newton, P.O., Faro, F.D., Gollogly, S., Betz, R.R., Lenke, L.G. & Lowe, T.G. Results of preoperative pulmonary function testing of adolescents with idiopathic scoliosis. A study of six hundred and thirty-one patients, *J.Bone Joint Surg.Am.* 2005;87(9):1937-1946.
- Novakovic, B., Fears, T.R., Horowitz, M.E., Tucker, M.A. & Wexler, L.H. Late effects of therapy in survivors of Ewing's sarcoma family tumors, *J.Pediatr.Hematol.Oncol.* 1997;19(3):220-225.
- Nystrom, L.M. & Morcuende, J.A. Expanding endoprosthesis for pediatric musculoskeletal malignancy: current concepts and results, *Iowa Orthop.J.* 2010;30:141-149.
- Obata, H., Ueda, T., Kawai, A., Ishii, T., Ozaki, T., Abe, S., Tanaka, K., Tsuchiya, H., Matsumine, A., Yabe, H. & Japanese Musculoskeletal Oncology Group Clinical outcome of patients with Ewing sarcoma family of tumors of bone in Japan: the Japanese Musculoskeletal Oncology Group cooperative study, *Cancer* 2007;109(4):767-775.
- Oberlin, O., Deley, M.C., Bui, B.N., Gentet, J.C., Philip, T., Terrier, P., Carrie, C., Mechinaud, F., Schmitt, C., Babin-Boilletot, A., Michon, J. & French Society of Paediatric Oncology. Prognostic factors in localized Ewing's tumours and peripheral neuroectodermal tumours: the third study of the French Society of Paediatric Oncology (EW88 study), *Br.J.Cancer* 2001;85(11):1646-1654.
- Ogura, K., Miyamoto, S., Sakuraba, M., Fujiwara, T., Chuman, H. & Kawai, A. Intercalary reconstruction after wide resection of malignant bone tumors of the lower extremity using a composite graft with a devitalized autograft and a vascularized fibula, *Sarcoma* 2015;2015:861575.
- Owens, C., Abbott, L.S. & Gupta, A.A. Optimal management of Ewing sarcoma family of tumors: recent developments in systemic therapy, *Paediatr.Drugs* 2013;15(6):473-492.
- Ozaki, T. Diagnosis and treatment of Ewing sarcoma of the bone: a review article, *J.Orthop.Sci.* 2015;20(2):250-263.
- Ozaki, T., Hillmann, A., Hoffmann, C., Rube, C., Blasius, S., Dunst, J., Jurgens, H. & Winkelmann, W. Significance of surgical margin on the prognosis of patients with Ewing's sarcoma. A report from the Cooperative Ewing's Sarcoma Study, *Cancer* 1996;78(4):892-900.

- Ozaki, T., Flege, S., Liljenqvist, U., Hillmann, A., Delling, G., Salzer-Kuntschik, M., Jürgens, H., Kotz, R., Winkelmann, W. & Bielack, S.S. Osteosarcoma of the spine, *Cancer* 2002;94(4):1069-1077.
- Papadopoulos, E.C., Boachie-Adjei, O., Hess, W.F., Sanchez Perez-Grueso, F.J., Pellise, F., Gupta, M., Lonner, B., Paonessa, K., Faloon, M., Cunningham, M.E., Kim, H.J., Mendelow, M., Sacramento, C., Yazici, M. & Foundation of Orthopedics and Complex Spine, New York, NY Early outcomes and complications of posterior vertebral column resection, *Spine J.* 2015;15(5):983-991.
- Parry, M.C., Laitinen, M., Albergo, J., Jeys, L., Carter, S., Gaston, C.L., Sumathi, V. & Grimer, R.J. Osteosarcoma of the pelvis, *Bone Joint J.* 2016;98-B(4):555-563.
- Paulussen, M., Ahrens, S., Burdach, S., Craft, A., Dockhorn-Dworniczak, B., Dunst, J., Fröhlich, B., Winkelmann, W., Zoubek, A. & Jurgens, H. Primary metastatic (stage IV) Ewing tumor: survival analysis of 171 patients from the EICESS studies. European Intergroup Cooperative Ewing Sarcoma Studies, *Ann.Oncol.* 1998;9(3):275-281.
- Paulussen, M., Ahrens, S., Dunst, J., Winkelmann, W., Exner, G.U., Kotz, R., Amann, G., Dockhorn-Dworniczak, B., Harms, D., Müller-Weihrich, S., Welte, K., Kornhuber, B., Janka-Schaub, G., Gobel, U., Treuner, J., Voute, P.A., Zoubek, A., Gardner, H. & Jurgens, H. Localized Ewing tumor of bone: final results of the cooperative Ewing's Sarcoma Study CESS 86, *J.Clin.Oncol.* 2001a;19(6):1818-1829.
- Paulussen, M., Ahrens, S., Lehnert, M., Taeger, D., Hense, H.W., Wagner, A., Dunst, J., Harms, D., Reiter, A., Henze, G., Niemeyer, C., Gobel, U., Kremens, B., Folsch, U.R., Aulitzky, W.E., Voute, P.A., Zoubek, A. & Jurgens, H. Second malignancies after ewing tumor treatment in 690 patients from a cooperative German/Austrian/Dutch study, *Ann.Oncol.* 2001b;12(11):1619-1630.
- Paulussen, M., Craft, A.W., Lewis, I., Hackshaw, A., Douglas, C., Dunst, J., Schuck, A., Winkelmann, W., Kohler, G., Poremba, C., Zoubek, A., Ladenstein, R., van den Berg, H., Hunold, A., Cassoni, A., Spooner, D., Grimer, R., Whelan, J., McTiernan, A., Jurgens, H. & European Intergroup Cooperative Ewing's Sarcoma Study-92 Results of the EICESS-92 Study: two randomized trials of Ewing's sarcoma treatment--cyclophosphamide compared with ifosfamide in standard-risk patients and assessment of benefit of etoposide added to standard treatment in high-risk patients, *J.Clin.Oncol.* 2008;26(27):4385-4393.
- Peersman, B., Vanhoenacker, F.M., Heyman, S., Van Herendael, B., Stam, M., Brys, P., Verstraete, K.L., Samson, I., Sybers, J., Van Dyck, P., Parizel, P.M. & De Schepper, A.M. Ewing's sarcoma: imaging features, *Jbr-Btr* 2007;90(5):368-376.
- Pehrsson, K., Bake, B., Larsson, S. & Nachemson, A. Lung function in adult idiopathic scoliosis: a 20 year follow up, *Thorax* 1991;46(7):474-478.
- Pehrsson, K., Danielsson, A. & Nachemson, A. Pulmonary function in adolescent idiopathic scoliosis: a 25 year follow up after surgery or start of brace treatment, *Thorax* 2001;56(5):388-393.
- Perouli, E., Chrysikopoulos, H., Vlachos, A., Koskinas, A., Batistatou, A. & Polyzoidis, K. Imaging findings in paraspinous extra osseous Ewing sarcoma, *Jbr-Btr* 2006;89(6):310-312.
- Peter, M., Magdelenat, H., Michon, J., Melot, T., Oberlin, O., Zucker, J.M., Thomas, G. & Delattre, O. Sensitive detection of occult Ewing's cells by the reverse transcriptase-polymerase chain reaction, *Br.J.Cancer* 1995;72(1):96-100.
- Picci, P., Bohling, T., Bacci, G., Ferrari, S., Sangiorgi, L., Mercuri, M., Ruggieri, P., Manfrini, M., Ferraro, A., Casadei, R., Benassi, M.S., Mancini, A.F., Rosito, P., Cazzola, A., Barbieri, E., Tienghi, A., Brach del Prever, A., Comandone, A., Bacchini, P. & Bertoni, F. Chemotherapy-induced tumor necrosis as a prognostic factor in localized Ewing's sarcoma of the extremities. *J.Clin.Oncol.* 1997;15(4):1553-1559.
- Picci, P., Rougraff, B.T., Bacci, G., Neff, J.R., Sangiorgi, L., Cazzola, A., Baldini, N., Ferrari, S., Mercuri, M. & Ruggieri, P. Prognostic significance of histopathologic response to chemotherapy in nonmetastatic Ewing's sarcoma of the extremities, *J.Clin.Oncol.* 1993;11(9):1763-1769.
- Pishas, K.I. & Lessnick, S.L. Recent advances in targeted therapy for Ewing sarcoma, *F1000res* 2016;510.12688/f1000research.8631.1. eCollection 2016.
- Pollock, B.H., Krischer, J.P. & Vietti, T.J. Interval between symptom onset and diagnosis of pediatric solid tumors, *J.Pediatr.* 1991;119(5):725-732.
- Potratz, J., Dirksen, U., Jurgens, H. & Craft, A. Ewing sarcoma: clinical state-of-the-art, *Pediatr.Hematol.Oncol.* 2012;29(1):1-11.



- Pradhan, A., Grimer, R.J., Spooner, D., Peake, D., Carter, S.R., Tillman, R.M., Abudu, A. & Jeys, L. Oncological outcomes of patients with Ewing's sarcoma: is there a difference between skeletal and extra-skeletal Ewing's sarcoma? *J.Bone Joint Surg.Br.* 2011;93(4):531-536.
- Pritchard, D.J., Dahlin, D.C., Dauphine, R.T., Taylor, W.F. & Beabout, J.W. Ewing's sarcoma. A clinicopathological and statistical analysis of patients surviving five years or longer. *J.Bone Joint Surg.Am.* 1975;57(1):10-16.
- Quelle, D.E., Zindy, F., Ashmun, R.A. & Sherr, C.J. Alternative reading frames of the INK4a tumor suppressor gene encode two unrelated proteins capable of inducing cell cycle arrest, *Cell* 1995;83(6):993-1000.
- Qureshi, S.S., Laskar, S., Kembhavi, S., Talole, S., Chinnaswamy, G., Vora, T., Ramadwar, M., Desai, S., Khanna, N., Muckaden, M.A. & Kurkure, P. Extraskelatal Ewing sarcoma in children and adolescents: impact of narrow but negative surgical margin, *Pediatr.Surg.Int.* 2013;29(12):1303-1309.
- Rabitsch, K., Maurer-Ertl, W., Pirker-Fruhauf, U., Wibmer, C. & Leithner, A. Intercalary reconstructions with vascularised fibula and allograft after tumour resection in the lower limb, *Sarcoma* 2013;2013160295.
- Racano, A., Pazonis, T., Farrokhyar, F., Deheshi, B. & Ghert, M. High infection rate outcomes in long-bone tumor surgery with endoprosthetic reconstruction in adults: a systematic review, *Clin.Orthop.Relat.Res.* 2013;471(6):2017-2027.
- Raciborska, A., Bilska, K., Rychlowska-Pruszyńska, M., Drabko, K., Chaber, R., Pogorzala, M., Polczynska, K., Godzinski, J., Rodriguez-Galindo, C. & Wozniak, W. Internal hemipelvectomy in the management of pelvic Ewing sarcoma - are outcomes better than with radiation therapy? *J.Pediatr.Surg.* 2014;49(10):1500-1504.
- Randall, R.L., Lessnick, S.L., Jones, K.B., Gouw, L.G., Cummings, J.E., Cannon-Albright, L. & Schifman, J.D. Is There a Predisposition Gene for Ewing's Sarcoma? *J.Oncol.* 2010;2010397632.
- Rasper, M., Jabar, S., Ranft, A., Jurgens, H., Amler, S. & Dirksen, U. The value of high-dose chemotherapy in patients with first relapsed Ewing sarcoma, *Pediatr.Blood Cancer.* 2014;61(8):1382-1386.
- Reinus, W.R. & Gilula, L.A. Radiology of Ewing's sarcoma: Intergroup Ewing's Sarcoma Study (IESS), *Radiographics* 1984;4(6):929-944.
- Rodriguez-Galindo, C., Billups, C.A., Kun, L.E., Rao, B.N., Pratt, C.B., Merchant, T.E., Santana, V.M. & Pappo, A.S. Survival after recurrence of Ewing tumors: the St Jude Children's Research Hospital experience, 1979-1999, *Cancer* 2002;94(2):561-569.
- Rosen, G., Murphy, M.L., Huvos, A.G., Gutierrez, M. & Marcove, R.C. Chemotherapy, en bloc resection, and prosthetic bone replacement in the treatment of osteogenic sarcoma, *Cancer* 1976;37(1):1-11.
- Rougraff, B.T., Simon, M.A., Kneisl, J.S., Greenberg, D.B. & Mankin, H.J. Limb salvage compared with amputation for osteosarcoma of the distal end of the femur. A long-term oncological, functional, and quality-of-life study, *J.Bone Joint Surg.Am.* 1994;76(5):649-656.
- Sailer, S.L., Harmon, D.C., Mankin, H.J., Truman, J.T. & Suit, H.D. Ewing's sarcoma: surgical resection as a prognostic factor, *Int.J.Radiat.Oncol.Biol.Phys.* 1988;15(1):43-52.
- Sainsbury, D.C., Liu, E.H., Alvarez-Veronesi, M.C., Ho, E.S., Hopyan, S., Zuker, R.M. & Borschel, G.H. Long-term outcomes following lower extremity sarcoma resection and reconstruction with vascularized fibula flaps in children, *Plast.Reconstr.Surg.* 2014;134(4):808-820.
- Sampo, M., Koivikko, M., Taskinen, M., Kallio, P., Kivioja, A., Tarkkanen, M. & Bohling, T. Incidence, epidemiology and treatment results of osteosarcoma in Finland - a nationwide population-based study, *Acta Oncol.* 2011;50(8):1206-1214.
- Schleiermacher, G., Peter, M., Oberlin, O., Philip, T., Rubie, H., Mechinaud, F., Sommelet-Olive, D., Landman-Parker, J., Bours, D., Michon, J., Delattre, O. & Societe Francaise d'Oncologie Pediatrique. Increased risk of systemic relapses associated with bone marrow micrometastasis and circulating tumor cells in localized ewing tumor, *J.Clin.Oncol.* 2003;21(1):85-91.
- Schrager, J., Patzer, R.E., Mink, P.J., Ward, K.C. & Goodman, M. Survival outcomes of pediatric osteosarcoma and Ewing's sarcoma: a comparison of surgery type within the SEER database, 1988-2007, *J.Registry Manag.* 2011;38(3):153-161.
- Schuck, A., Ahrens, S., Paulussen, M., Kuhlen, M., Konemann, S., Rube, C., Winkelmann, W., Kotz, R., Dunst, J., Willich, N. & Jurgens, H. Local therapy in localized Ewing tumors: results of 1058 patients treated in the CESS 81, CESS 86, and EICESS 92 trials. *Int.J.Radiat.Oncol.Biol.Phys.* 2003;55(1):168-177.

- Schuh, R., Panotopoulos, J., Puchner, S.E., Willegger, M., Hobusch, G.M., Windhager, R. & Funovics, P.T. Vascularised or non-vascularised autologous fibular grafting for the reconstruction of a diaphyseal bone defect after resection of a musculoskeletal tumour, *Bone Joint J.* 2014;96-B(9):1258-1263.
- Schuz, J., Kaatsch, P., Kaletsch, U., Meinert, R. & Michaelis, J. Association of childhood cancer with factors related to pregnancy and birth, *Int.J.Epidemiol.* 1999;28(4):631-639.
- Schwab, J., Gasbarrini, A., Bandiera, S., Boriani, L., Amendola, L., Picci, P., Ferrari, S. & Boriani, S. Osteosarcoma of the mobile spine, *Spine (Phila Pa.1976)* 2012;37(6):E381-6.
- Schwartz, B., Benadjaoud, M.A., Clero, E., Haddy, N., El-Fayech, C., Guibout, C., Teinturier, C., Oberlin, O., Veres, C., Pacquement, H., Munzer, M., N'guyen, T.D., Bondiau, P.Y., Berchery, D., Laprie, A., Hawkins, M., Winter, D., Lefkopoulos, D., Chavaudra, J., Rubino, C., Diallo, I., Benichou, J. & de Vathaire, F. Risk of second bone sarcoma following childhood cancer: role of radiation therapy treatment, *Radiat.Environ.Biophys.* 2014;53(2):381-390.
- Sewell, M.D., Tan, K.A., Quraishi, N.A., Preda, C., Varga, P.P. & Williams, R. Systematic Review of En Bloc Resection in the Management of Ewing's Sarcoma of the Mobile Spine with Respect to Local Control and Disease-Free Survival, *Medicine (Baltimore)* 2015;94(27):e1019.
- Sharrocks, A.D. The ETS-domain transcription factor family, *Nat.Rev.Mol.Cell Biol.* 2001;2(11):827-837.
- Sheffield, N.C., Pierron, G., Klughammer, J., Datlinger, P., Schonegger, A., Schuster, M., Hadler, J., Surdez, D., Guillemot, D., Lapouble, E., Freneaux, P., Champigneulle, J., Bouvier, R., Walder, D., Ambros, I.M., Hutter, C., Sorz, E., Amaral, A.T., de Alava, E., Schallmoser, K., Strunk, D., Rinner, B., Liegl-Atzwanger, B., Huppertz, B., Leithner, A., de Pinieux, G., Terrier, P., Laurence, V., Michon, J., Ladenstein, R., Holter, W., Windhager, R., Dirksen, U., Ambros, P.F., Delattre, O., Kovar, H., Bock, C. & Tomazou, E.M. DNA methylation heterogeneity defines a disease spectrum in Ewing sarcoma, *Nat.Med.* 2017;23(3):386-395.
- Shibuya, R., Matsuyama, A., Nakamoto, M., Shiba, E., Kasai, T. & Hisaoka, M. The combination of CD99 and NKX2.2, a transcriptional target of EWSR1-FLI1, is highly specific for the diagnosis of Ewing sarcoma, *Virchows Arch.* 2014;465(5):599-605.
- Shing, D.C., McMullan, D.J., Roberts, P., Smith, K., Chin, S.F., Nicholson, J., Tillman, R.M., Ramani, P., Cullinane, C. & Coleman, N. FUS/ERG gene fusions in Ewing's tumors, *Cancer Res.* 2003;63(15):4568-4576.
- Siitonen, H.A., Sotkasiira, J., Biervliet, M., Benmansour, A., Capri, Y., Cormier-Daire, V., Crandall, B., Hannula-Jouppi, K., Hennekam, R., Herzog, D., Keymolen, K., Lipsanen-Nyman, M., Miny, P., Plon, S.E., Riedl, S., Sarkar, A., Vargas, F.R., Verloes, A., Wang, L.L., Kääriäinen, H. & Kestilä, M. The mutation spectrum in RECQL4 diseases, *European Journal of Human Genetics* 2008;17(2):151-158.
- Silve, C. & Jüppner, H. Ollier disease, *Orphanet Journal of Rare Diseases* 2006;137-37.
- Skeletal Lesions Interobserver Correlation among Expert Diagnosticians (SLICED) Study Group Reliability of histopathologic and radiologic grading of cartilaginous neoplasms in long bones, *J.Bone Joint Surg.Am.* 2007;89(10):2113-2123.
- Skrzynski, M.C., Biermann, J.S., Montag, A. & Simon, M.A. Diagnostic accuracy and charge-savings of outpatient core needle biopsy compared with open biopsy of musculoskeletal tumors, *J.Bone Joint Surg.Am.* 1996;78(5):644-649.
- Slater, O. & Shipley, J. Clinical relevance of molecular genetics to paediatric sarcomas, *J.Clin.Pathol.* 2007;60(11):1187-1194.
- Smeland, S., Bruland, O.S., Hjorth, L., Brosjo, O., Bjerkehagen, B., Osterlundh, G., Jakobson, A., Hall, K.S., Monge, O.R., Bjork, O. & Alvegaard, T.A. Results of the Scandinavian Sarcoma Group XIV protocol for classical osteosarcoma: 63 patients with a minimum follow-up of 4 years, *Acta Orthop.* 2011;82(2):211-216.
- Smeland, S., Muller, C., Alvegaard, T.A., Wiklund, T., Wiebe, T., Bjork, O., Stenwig, A.E., Willen, H., Holmstrom, T., Folleras, G., Brosjo, O., Kivioja, A., Jonsson, K., Monge, O. & Saeter, G. Scandinavian Sarcoma Group Osteosarcoma Study SSG VIII: prognostic factors for outcome and the role of replacement salvage chemotherapy for poor histological responders, *Eur.J.Cancer* 2003;39(4):488-494.
- Smith, J.S., Wang, V.Y. & Ames, C.P. Vertebral column resection for rigid spinal deformity, *Neurosurgery* 2008;63(3 Suppl):177-182.

- Sorensen, P.H., Lessnick, S.L., Lopez-Terrada, D., Liu, X.F., Triche, T.J. & Denny, C.T. A second Ewing's sarcoma translocation, t(21;22), fuses the EWS gene to another ETS-family transcription factor, ERG, *Nat.Genet.* 1994;6(2):146-151.
- Stahl, M., Ranft, A., Paulussen, M., Bolling, T., Vieth, V., Bielack, S., Gortitz, I., Braun-Munzinger, G., Harges, J., Jurgens, H. & Dirksen, U. Risk of recurrence and survival after relapse in patients with Ewing sarcoma, *Pediatr.Blood Cancer.* 2011;57(4):549-553.
- Statistics Finland. Available: [http://stat.fi/tup/tilastotietokannat/index\\_en.html](http://stat.fi/tup/tilastotietokannat/index_en.html). Last update 12.8.2016.
- Stener, B. Total spondylectomy in chondrosarcoma arising from the seventh thoracic vertebra, *J.Bone Joint Surg.Br.* 1971;53(2):288-295.
- Stener, B. & Johnsen, O.E. Complete removal of three vertebrae for giant-cell tumour, *J.Bone Joint Surg.Br.* 1971;53(2):278-287.
- Stieber, J.R. & Dormans, J.P. Manifestations of hereditary multiple exostoses, *J.Am.Acad.Orthop.Surg.* 2005;13(2):110.
- Stillier, C.A., Bielack, S.S., Jundt, G. & Steliarova-Foucher, E. Bone tumours in European children and adolescents, 1978-1997. Report from the Automated Childhood Cancer Information System project. *Eur.J.Cancer* 2006a;42(13):2124-2135.
- Stillier, C.A., Craft, A.W., Corazziari, I. & EUROCORE Working, G. Survival of children with bone sarcoma in Europe since 1978: results from the EUROCORE study. *Eur.J.Cancer* 2001;37(6):760-766.
- Stillier, C.A. International patterns of cancer incidence in adolescents, *Cancer Treat.Rev.* 2007;33(7):631-645.
- Stillier, C.A., Passmore, S.J., Kroll, M.E., Brownbill, P.A., Wallis, J.C. & Craft, A.W. Patterns of care and survival for patients aged under 40 years with bone sarcoma in Britain, 1980-1994, *Br.J.Cancer* 2006b;94(1):22-29.
- Stokke, J., Sung, L., Gupta, A., Lindberg, A. & Rosenberg, A.R. Systematic review and meta-analysis of objective and subjective quality of life among pediatric, adolescent, and young adult bone tumor survivors, *Pediatr.Blood Cancer.* 2015;62(9):1616-1629.
- Stout, A.P. A tumor of the ulnar nerve, *Proc NY Pathol Soc* 1918;122-12.
- Sucato, D.J. Management of severe spinal deformity: scoliosis and kyphosis, *Spine (Phila Pa.1976)* 2010;35(25):2186-2192.
- Suk, S.I., Chung, E.R., Lee, S.M., Lee, J.H., Kim, S.S. & Kim, J.H. Posterior vertebral column resection in fixed lumbosacral deformity, *Spine (Phila Pa.1976)* 2005;30(23):E703-10.
- Suk, S.I., Kim, J.H., Kim, W.J., Lee, S.M., Chung, E.R. & Nah, K.H. Posterior vertebral column resection for severe spinal deformities, *Spine (Phila Pa.1976)* 2002;27(21):2374-2382.
- Tomita, K., Kawahara, N., Baba, H., Tsuchiya, H., Fujita, T. & Toribatake, Y. Total en bloc spondylectomy. A new surgical technique for primary malignant vertebral tumors, *Spine (Phila Pa.1976)* 1997;22(3):324-333.
- Tomita, K., Kawahara, N., Kobayashi, T., Yoshida, A., Murakami, H. & Akamaru, T. Surgical strategy for spinal metastases, *Spine (Phila Pa.1976)* 2001;26(3):298-306.
- Tomita, K., Kawahara, N., Murakami, H. & Demura, S. Total en bloc spondylectomy for spinal tumors: improvement of the technique and its associated basic background, *J.Orthop.Sci.* 2006;11(1):3-12.
- Traina, F., Errani, C., Toscano, A., Pungetti, C., Fabbri, D., Mazzotti, A., Donati, D. & Faldini, C. Current concepts in the biopsy of musculoskeletal tumors, *J.Bone Joint Surg.Am.* 2015;97(1):e7.
- Trama, A., Botta, L., Foschi, R., Ferrari, A., Stiller, C., Desandes, E., Maule, M.M., Merletti, F., Gatta, G. & EUROCORE-5 Working Group Survival of European adolescents and young adults diagnosed with cancer in 2000-07: population-based data from EUROCORE-5, *Lancet Oncol.* 2016;17(7):896-906.
- Treasure, T., Fiorentino, F., Scarci, M., Moller, H. & Utley, M. Pulmonary metastasectomy for sarcoma: a systematic review of reported outcomes in the context of Thames Cancer Registry data, *BMJ Open* 2012;2(5):10.1136/bmjopen-2012-001736. Print 2012.
- Treglia, G., Salsano, M., Stefanelli, A., Mattoli, M.V., Giordano, A. & Bonomo, L. Diagnostic accuracy of (1)(8)F-FDG-PET and PET/CT in patients with Ewing sarcoma family tumours: a systematic review and a meta-analysis, *Skeletal Radiol.* 2012;41(3):249-256.

- Tsagkozis, P., Brosjo, O. & Bauer, H.C. Reconstruction with modular megaprotheses for sarcomas of the lower extremity, *Orthopedics* 2015;38(5):e401-6.
- Turc-Carel, C., Philip, I., Berger, M.P., Philip, T. & Lenoir, G.M. Chromosome study of Ewing's sarcoma (ES) cell lines. Consistency of a reciprocal translocation t(11;22)(q24;q12), *Cancer Genet.Cytogenet.* 1984;12(1):1-19.
- Turc-Carel, C., Aurias, A., Mugneret, F., Lizard, S., Sidaner, I., Volk, C., Thiery, J.P., Olschwang, S., Philip, I., Berger, M.P., Philip, T., Lenoir, G.M. & Mazabraud, A. Chromosomes in Ewing's sarcoma. I. An evaluation of 85 cases and remarkable consistency of t(11;22)(q24;q12), *Cancer Genet.Cytogenet.* 1988;32(2):229-238.
- Valery, P.C., Holly, E.A., Sleight, A.C., Williams, G., Kreiger, N. & Bain, C. Hernias and Ewing's sarcoma family of tumours: a pooled analysis and meta-analysis, *Lancet Oncol.* 2005;6(7):485-490.
- Valery, P.C., Williams, G., Sleight, A.C., Holly, E.A., Kreiger, N. & Bain, C. Parental occupation and Ewing's sarcoma: pooled and meta-analysis, *Int.J.Cancer* 2005;115(5):799-806.
- van den Berg, H., Kroon, H.M., Slaar, A. & Hogendoorn, P. Incidence of biopsy-proven bone tumors in children: a report based on the Dutch pathology registration "PALGA", *J.Pediatr.Orthop.* 2008;28(1):29-35.
- van Maldegem, A.,M. Comprehensive analysis of published studies involving systemic treatment for chondrosarcoma of bone between 2000 and 2013, *Clin Sarcoma Res* 2014;411.
- Verdegaal, S.H.M., Bovée, J.,V.M.G., Pansuriya, T.C., Grimer, R.J., Ozger, H., Jutte, P.C., San Julian, M., Biau, D.J., van der Geest, I.,C.M., Leithner, A., Streitbürger, A., Klenke, F.M., Guoin, F.G., Campanacci, D.A., Marec-Berard, P., Hogendoorn, P.C.W., Brand, R. & Taminiau, A.H.M. Incidence, Predictive Factors, and Prognosis of Chondrosarcoma in Patients with Ollier Disease and Maffucci Syndrome: An International Multicenter Study of 161 Patients, *Oncologist* 2011;16(12):1771-1779.
- Vlachos, A., Rosenberg, P.S., Atsidaftos, E., Alter, B.P. & Lipton, J.M. Incidence of neoplasia in Diamond Blackfan anemia: a report from the Diamond Blackfan Anemia Registry, *Blood* 2012;119(16):3815-3819.
- Völker, T., Denecke, T., Steffen, I., Misch, D., Schonberger, S., Plotkin, M., Ruf, J., Furth, C., Stover, B., Hautzel, H., Henze, G. & Amthauer, H. Positron emission tomography for staging of pediatric sarcoma patients: results of a prospective multicenter trial, *J.Clin.Oncol.* 2007;25(34):5435-5441.
- Weinstein, J.N. & McLain, R.F. Primary tumors of the spine, *Spine (Phila Pa.1976)* 1987;12(9):843-851.
- Weistein, J.S., Goldsby, R.E. & O'Donnell, R.J. Oncologic approaches to pediatric limb preservation, *J.Am.Acad.Orthop.Surg.* 2005;13(8):544-554.
- Werier, J., Yao, X., Caudrelier, J., Di Primio, G., Ghert, M., Gupta, A.A., Kandel, R. & Verma, S. A systematic review of optimal treatment strategies for localized Ewing's sarcoma of bone after neo-adjuvant chemotherapy, *Surg.Oncol.* 2016;25(1):16-23.
- Whelan, J., McTiernan, A., Cooper, N., Wong, Y.K., Francis, M., Vernon, S. & Strauss, S.J. Incidence and survival of malignant bone sarcomas in England 1979-2007, *Int.J.Cancer* 2012a;131(4):E508-17.
- Whelan, J.S., Jinks, R.C., McTiernan, A., Sydes, M.R., Hook, J.M., Trani, L., Uscinska, B., Bramwell, V., Lewis, I.J., Nooij, M.A., van Glabbeke, M., Grimer, R.J., Hogendoorn, P.C., Taminiau, A.H. & Gelderblom, H. Survival from high-grade localised extremity osteosarcoma: combined results and prognostic factors from three European Osteosarcoma Intergroup randomised controlled trials, *Ann.Oncol.* 2012b;23(6):1607-1616.
- Wicklund, C.L., Pauli, R.M., Johnston, D. & Hecht, J.T. Natural history study of hereditary multiple exostoses, *Am.J.Med.Genet.* 1995;55(1):43.
- Widhe, B. & Widhe, T. Initial symptoms and clinical features in osteosarcoma and Ewing sarcoma. *J.Bone Joint Surg.Am.* 2000;82(5):667-674.
- Widhe, B., Widhe, T. & Bauer, H.C. Ewing sarcoma of the rib--initial symptoms and clinical features: tumor missed at the first visit in 21 of 26 patients, *Acta Orthop.* 2007;78(6):840-844.
- Wilkins, R.M., Pritchard, D.J., Omer, E.B. & Unni, K.K. Ewing's sarcoma of bone. Experience with 140 patients, *Cancer* 1986;58(11):2551-2555.
- Winn, D.M., Li, F.P., Robison, L.L., Mulvihill, J.J., Daigle, A.E. & Fraumeni, J.F., Jr A case-control study of the etiology of Ewing's sarcoma, *Cancer Epidemiol.Biomarkers Prev.* 1992;1(7):525-532.

- Wiromrat, P., Jetsrisuparb, A., Komvilaisak, P., Sirichativapee, W., Kamsa-Ard, S. & Wiangnon, S. Incidence and survival rates among pediatric osteogenic sarcoma cases in Khon Kaen, Thailand, 1985-2010, *Asian Pac.J.Cancer.Prev.* 2012;13(9):4281-4284.
- Wong, F., Boice, J.D., Abramson, D.H., Tarone, R.E., Kleinerman, R.A., Stovall, M., Goldman, M.B., Seddon, J.M., Tarbell, N., Fraumeni, J.F. & Li, F.P. Cancer incidence after retinoblastoma: Radiation dose and sarcoma risk, *Jama* 1997;278(15):1262-1267.
- Worch, J., Matthay, K.K., Neuhaus, J., Goldsby, R. & DuBois, S.G. Ethnic and racial differences in patients with Ewing sarcoma, *Cancer* 2010;116(4):983-988.
- Wunder, J.S., Paulian, G., Huvos, A.G., Heller, G., Meyers, P.A. & Healey, J.H. The histological response to chemotherapy as a predictor of the oncological outcome of operative treatment of Ewing sarcoma, *J.Bone Joint Surg.Am.* 1998;80(7):1020-1033.
- Yamazaki, T., McLoughlin, G.S., Patel, S., Rhines, L.D. & Fourney, D.R. Feasibility and safety of en bloc resection for primary spine tumors: a systematic review by the Spine Oncology Study Group, *Spine (Phila Pa.1976)* 2009;34(22 Suppl):S31-8.
- Yang, C., Zheng, Z., Liu, H., Wang, J., Kim, Y.J. & Cho, S. Posterior vertebral column resection in spinal deformity: a systematic review, *Eur.Spine J.* 2016;25(8):2368-2375.
- Zaikova, O., Sundby Hall, K., Styring, E., Eriksson, M., Trovik, C.S., Bergh, P., Bjerkehagen, B., Skorpil, M., Weedon-Fekjær, H. & Bauer, H.C.F. Referral patterns, treatment and outcome of high-grade malignant bone sarcoma in Scandinavia-SSG Central Register 25 years' experience, *J.Surg.Oncol.* 2015;112(8):853-860.
- Zamora, T., Urrutia, J., Schweitzer, D., Amenabar, P.P. & Botello, E. Do Orthopaedic Oncologists Agree on the Diagnosis and Treatment of Cartilage Tumors of the Appendicular Skeleton? *Clin.Orthop.Relat.Res.* 2017 ePub ahead of print, DOI 10.1007/s11999-017-5276-y

## ORIGINAL PUBLICATIONS

**Article I** "Ewing's sarcoma family of tumors in Finland during 1990 - 2009: A population-based study" reproduced with permission of Taylor & Francis [published in *Acta Oncologica*, 2013; 52: 767-775, available online: <http://www.tandfonline.com/doi/full/10.3109/0284186X.2012.728714>]

**Article II** "Surgically treated patients with axial and peripheral Ewing's sarcoma family of tumours: A population based study in Finland during 1990–2009" reproduced with permission of Elsevier [published in *Eur J Surg Oncol*. 2015 Jul;41(7):893-8, available online: <http://dx.doi.org/10.1016/j.ejso.2015.02.010>].

**Article III** "Incidence, treatment and survival of paediatric patients with bone sarcomas in Finland from 1991 to 2005" reproduced with permission of Wiley [published in *Acta Paediatr*. 2015 Jul;104(7):738-45, available online: <http://onlinelibrary.wiley.com/doi/10.1111/apa.12986/abstract>]

**Article IV** "The incidence and outcomes of vertebral column resection in paediatric patients: a population-based, multicentre, follow-up study" pre-published version reproduced with permission and copyright © of the British Editorial Society of Bone and Joint Surgery [*J Bone Joint Surg Br*. 2012 Jul;94(7):950-5, available online: <http://www.bjj.boneandjoint.org.uk/content/94-B/7/950>].