

University of Nebraska - Lincoln
DigitalCommons@University of Nebraska - Lincoln

Uniformed Services University of the Health
Sciences

U.S. Department of Defense

2016

False-negative direct immunofluorescence testing in vancomycin-induced linear IgA bullous dermatosis: a diagnostic pitfall

Aubrey E. Winn
Uniformed Services University of the Health Sciences

Erin L. Spillane
Womack Army Medical Center

Dave J. Peterson
Womack Army Medical Center

Leonard C. Sperling
Uniformed Services University of the Health Sciences

Jon H. Meyerle
Uniformed Services University of the Health Sciences

Follow this and additional works at: <http://digitalcommons.unl.edu/usuhs>

Winn, Aubrey E.; Spillane, Erin L.; Peterson, Dave J.; Sperling, Leonard C.; and Meyerle, Jon H., "False-negative direct immunofluorescence testing in vancomycin-induced linear IgA bullous dermatosis: a diagnostic pitfall" (2016). *Uniformed Services University of the Health Sciences*. 185.
<http://digitalcommons.unl.edu/usuhs/185>

This Article is brought to you for free and open access by the U.S. Department of Defense at DigitalCommons@University of Nebraska - Lincoln. It has been accepted for inclusion in Uniformed Services University of the Health Sciences by an authorized administrator of DigitalCommons@University of Nebraska - Lincoln.

Letter to the Editor

False-negative direct immunofluorescence testing in vancomycin-induced linear IgA bullous dermatosis: a diagnostic pitfall

Keywords: false-negative, direct immunofluorescence testing, linear IgA bullous dermatosis, vancomycin, repeat biopsy

To the Editor,

Linear IgA bullous dermatosis (LAD) is an acquired immunobullous dermatosis that relies on direct immunofluorescence (DIF) testing showing linear deposition of immunoglobulin IgA along the basement membrane of the epidermis for diagnosis¹. We present a case that highlights the utility of repeating the DIF testing when initial immunofluorescence findings do not support the clinical findings of drug-induced LAD or contradict the histopathologic findings in routinely stained sections.

A 74-year-old African-American female with renal insufficiency and a stage four sacral

decubitus ulcer was hospitalized for new-onset periodic fevers following a surgical repair with flap closure. Her admitting team instituted broad-spectrum antibiotics, to include vancomycin, ciprofloxacin, piperacillin-tazobactam and meropenem. The primary team observed a rash four days into the start of the antibiotic regimen and consulted dermatology for further guidance.

Examination by a dermatologist revealed broad, erythematous, edematous discrete and coalescing plaques involving the neck, trunk and proximal anterior shoulders (Fig. 1). Areas of discrete vesicles were noted to involve

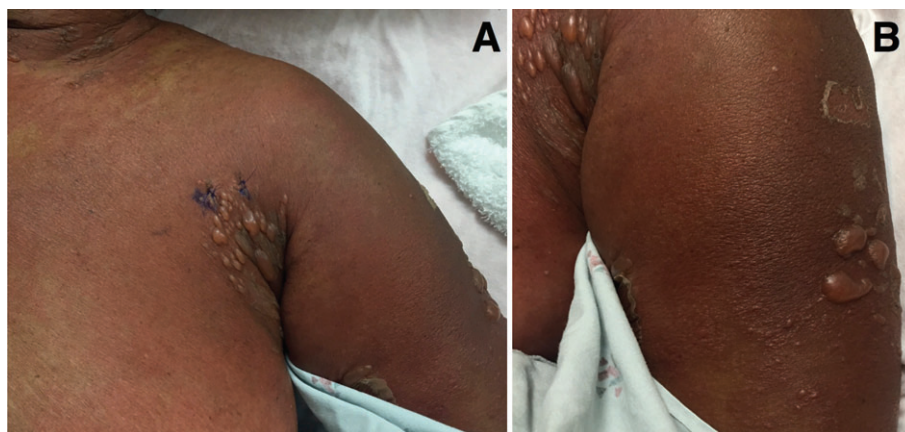


Fig. 1. Photographs taken at the time of presentation to consulting dermatologist. Note the grouping of tense blisters. Images taken at patient's (A) left axillary fold region and (B) left shoulder.

flexural regions of the patient's neck and axilla. Mucosal surfaces, as well as the patient's face, back and distal extremities were spared. Widespread epidermal loss and skin tenderness were absent.

The consulting dermatologist favored a drug eruption with early Stevens Johnson syndrome (SJS) and LAD included in the differential diagnosis. While SJS was considered, the patient lacked skin tenderness as well as mucosal involvement, and the rapid time course to onset after starting the antibiotics was not consistent with SJS. LAD was favored because the patient was on vancomycin, the most common offending medication for drug-induced LAD. However, an adverse reaction to other concomitant drugs was considered. Cessation of antibiotics was advised pending biopsy results. Two perilesional punch biopsies showed a sub-epidermal split characterized by a neutrophilic infiltrate and pustule formation. The histopathologic differential diagnosis included bullous urticaria, bullous lupus, Sweets syndrome or LAD. Surprisingly, initial DIF staining was negative, with no reactants to IgA, IgG, IgM or C3 observed.

LAD remained on the clinical differential in light of the patient's clinical and histopathologic findings. The negative DIF result, however, did not support this diagnosis, and, owing to the patient's interval clinical progression, she was transferred to a burn unit as a precaution in the event that her eruption progressed.

The patient's skin exam subsequently stabilized, with no further progression of vesicle formation and all mucosal surfaces remained spared. As the rash had not worsened, the patient was transferred back to the medicine ward. A repeat biopsy for DIF was obtained from peri-lesional skin in an involved area on the left anterior shoulder. The second DIF, processed at the same lab as the first biopsy, revealed prominent linear IgA deposition along the dermal–epidermal junction, establishing the diagnosis of drug-induced LAD (Fig. 2).

It is noted that the patient's history of renal disease may have contributed to the initial negative DIF result due to an altered immune response leading to consumption of complement proteins and immunoglobulins. Alternatively, the initial biopsy site may have missed the active inflammation along the dermal–epidermal junction observed in LAD.

In drug-induced LAD, cessation of the medication responsible is often sufficient to stop

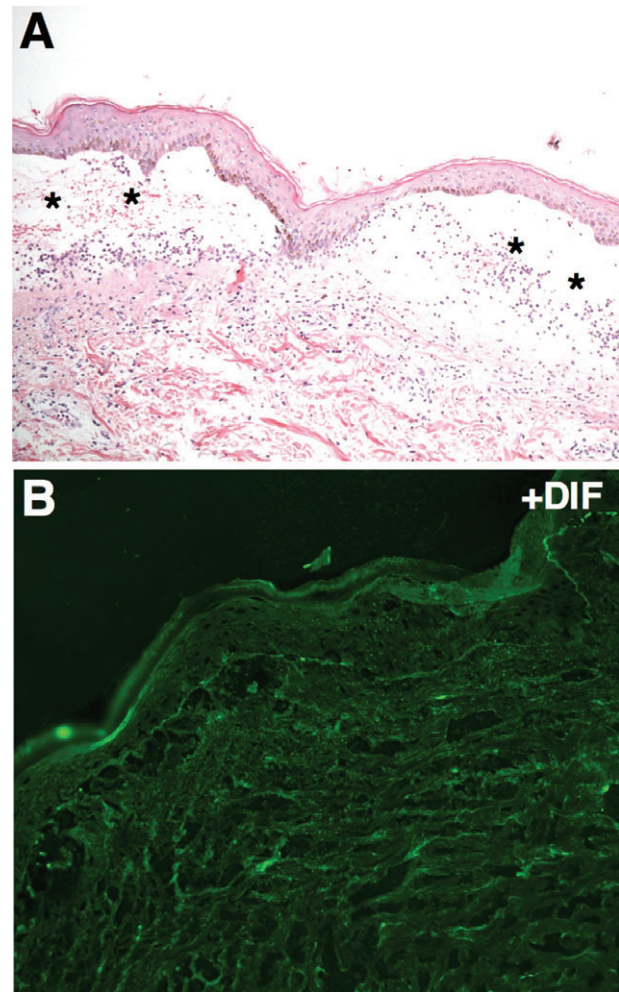


Fig. 2. A) Hematoxylin and eosin staining of biopsy tissue. Note the sub-epidermal split indicated by asterisks. B) Positive direct immunofluorescence (DIF) staining observed along dermal–epidermal junction; IgA deposition was observed along the roof of the blister.

progression². In our patient, supportive care with a topical steroid (triamcinolone 0.1% ointment) was started as the vancomycin, the most probable drug culprit, was discontinued. The patient's symptoms improved and the bullae resolved completely with only superficial post-inflammatory hyperpigmentation.

Little is reported in the literature regarding false negative DIF testing based on biopsy site. Our case highlights the utility of a second biopsy when an initial DIF is negative. In addition, it underscores that a false negative DIF result can occur depending on the biopsy location, confounding immune dysregulation, or tissue quality and a second biopsy should be considered if initial findings are negative.

Letter to the Editor

Disclaimer

The views expressed in this article are those of the author and do not necessarily reflect the official policy or position of the Department of Defense, or the US Government. The authors are military service members or employees of the US Government. Title 17, USC, § 105 provides that 'Copyright protection under this title is not available for any work of the United States Government.' Title 17, USC, § 101 defines a US Government work as a work prepared by a military service member or employee of the US Government as part of that person's official duties.

Aubrey E. Winn, MD¹

Erin L. Spillane, MD²

Dave J. Peterson, DO³

Leonard C. Sperling, MD¹

Jon H. Meyerle, MD¹

¹Department of Dermatology
Uniformed Services
University of the Health Sciences
Bethesda, MD, USA

²Department of Dermatology
Womack Army Medical Center
Fort Bragg, NC, USA

³Department of Pathology
Womack Army Medical Center
Fort Bragg, NC, USA

e-mail: jon.meyerle@usuhs.edu

References

1. Lo Schiavo A, Ruocco E, Branciocco G, Caccavale S, Ruocco V, Wolf R. Bullous pemphigoid: etiology, pathogenesis, and inducing factors: facts and controversies. *Clin Dermatol* 2013; 31: 391.
2. Tashima S, Konishi K, Koga H, Hashimoto T. A case of vancomycin-induced linear IgA bullous dermatosis with circulating IgA antibodies to the NC16a domain of BP180. *Int J Dermatol* 2014; 53: e207.