

University of Nebraska - Lincoln  
**DigitalCommons@University of Nebraska - Lincoln**

---

Uniformed Services University of the Health  
Sciences

U.S. Department of Defense

---

2016

# Thoracoscopically-assisted doxycycline sclerotherapy for a microcystic thoracoabdominal lymphatic malformation in a 3-month-old patient

Alexander Nissen

*Uniformed Services University of the Health Sciences*

A. Francois Trappey III

*San Antonio Military Medical Center*

Mary Edwards

*San Antonio Military Medical Center*

Follow this and additional works at: <https://digitalcommons.unl.edu/usuhs>

---

Nissen, Alexander; Trappey, A. Francois III; and Edwards, Mary, "Thoracoscopically-assisted doxycycline sclerotherapy for a microcystic thoracoabdominal lymphatic malformation in a 3-month-old patient" (2016). *Uniformed Services University of the Health Sciences*. 168.

<https://digitalcommons.unl.edu/usuhs/168>

This Article is brought to you for free and open access by the U.S. Department of Defense at DigitalCommons@University of Nebraska - Lincoln. It has been accepted for inclusion in Uniformed Services University of the Health Sciences by an authorized administrator of DigitalCommons@University of Nebraska - Lincoln.



# Thoracoscopically-assisted doxycycline sclerotherapy for a microcystic thoracoabdominal lymphatic malformation in a 3-month-old patient



Alexander Nissen<sup>a</sup>, A. Francois Trappey III<sup>b</sup>, Mary Edwards<sup>b,\*</sup>

<sup>a</sup> Uniformed Services University of the Health Sciences (USUHS), USA

<sup>b</sup> San Antonio Military Medical Center (SAMMC), USA

## ARTICLE INFO

### Article history:

Received 11 October 2015

Accepted 14 December 2015

### Key words:

Lymphatic malformation

Sclerotherapy

Thoracoscopy

## ABSTRACT

Here we report successful thoracoscopic-assisted sclerotherapy of a large, prenatally diagnosed microcystic thoracoabdominal lymphatic malformation in a 3-month-old infant born at 38 weeks gestational age. Compression of the inferior vena cava and aortic displacement was demonstrated on imaging. Treatment options include medical management, percutaneous sclerotherapy, or surgical resection. The latter options were complicated by the location of this lesion. Therefore, sclerotherapy under direct visualization via thoracoscopy was performed with near resolution of the lesion after one treatment. This is the first description of treatment of a lymphatic malformation via this approach reported in the literature.

Published by Elsevier Inc. This is an open access article under the CC BY-NC-ND license (<http://creativecommons.org/licenses/by-nc-nd/4.0/>).

## 1. Case description

A routine second trimester ultrasound at 20 weeks gestational age disclosed a large posterior mediastinal mass in a male fetus during an otherwise uncomplicated pregnancy. This was followed by term delivery at 38 + 1 weeks gestational age. Abdominal ultrasound on day of life 1 confirmed the presence of a large, well circumscribed, “spongy” appearing mass in the posterior mediastinum (Fig. 1). Further characterization with MRI (Fig. 2a) and contrast CT scan showed the mass to be in the left pleural space, extending across the posterior mediastinum, and through the aortic hiatus of the diaphragm into the retroperitoneum. The lesion displaced the aorta posteriorly and rightward, the esophagus anteriorly, and significantly compressed the inferior vena cava. Lack of an appreciable feeding artery or vein, or involvement of neural foramina were additional findings most consistent with a microcystic lymphatic malformation.

The patient was asymptomatic without signs of infection, venous congestion, or ascites. Additionally, there was no respiratory or feeding difficulty noted and the patient was discharged with close interval follow-up. A repeat ultrasound at 1 month of age

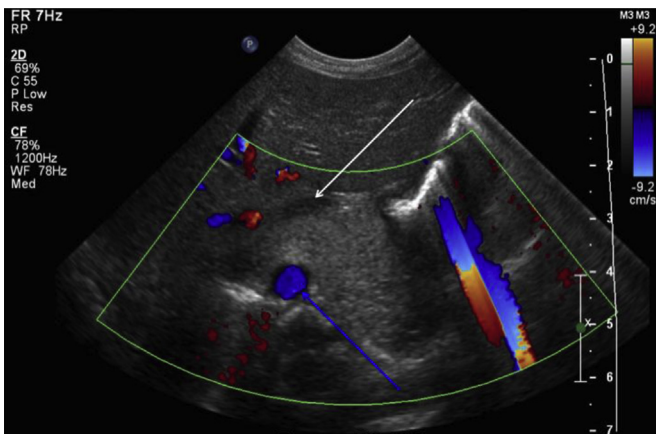
confirmed that the mass had not significantly changed in size, echotexture, or displacement of surrounding structures.

Although the patient remained asymptomatic, the compression of the vena cava and displacement of the aorta by this lymphatic malformation were concerning, as in the event of hemorrhage or infection, compression by mass effect could potentially be lethal. Resection was considered, but given the potential for a large chylothorax, enthusiasm for this as first line treatment was limited. The proximity of this lymphatic malformation to critical thoracoabdominal structures raised concern for iatrogenic injury during percutaneous sclerotherapy. The decision was made to perform sclerotherapy under thoracoscopic visualization with a plan for resection if this was not successful.

The patient was given 25 mg/kg cefazolin in addition to 0.1 mg/kg dexamethasone preoperatively to mitigate the risk of post-operative swelling and vascular occlusion. The operation was performed via a left-sided thoracoscopic approach with the patient 45° up from prone. One 5 mm thoracoscopic port was placed at the 6th intercostal space in the midaxillary line. After introduction of CO<sub>2</sub> pneumothorax to 6 mm Hg, a thoracoscope was introduced and the mass immediately identified in the posterior mediastinum. A 22 gauge spinal needle was inserted directly through the chest wall at the 8th intercostal space in the posterior axillary line. Attempts to aspirate the lymphatic malformation were unsuccessful, likely due to its microcystic nature. 30 mL of

\* Corresponding author.

E-mail address: [mary.j.edwards.mil@mail.mil](mailto:mary.j.edwards.mil@mail.mil) (M. Edwards).



**Fig. 1.** Abdominal ultrasound on day of life 1 shows a heterogeneously microcystic structure surrounding the aorta (blue arrow, with vascular flow) and compressing the retrohepatic vena cava (white arrow).

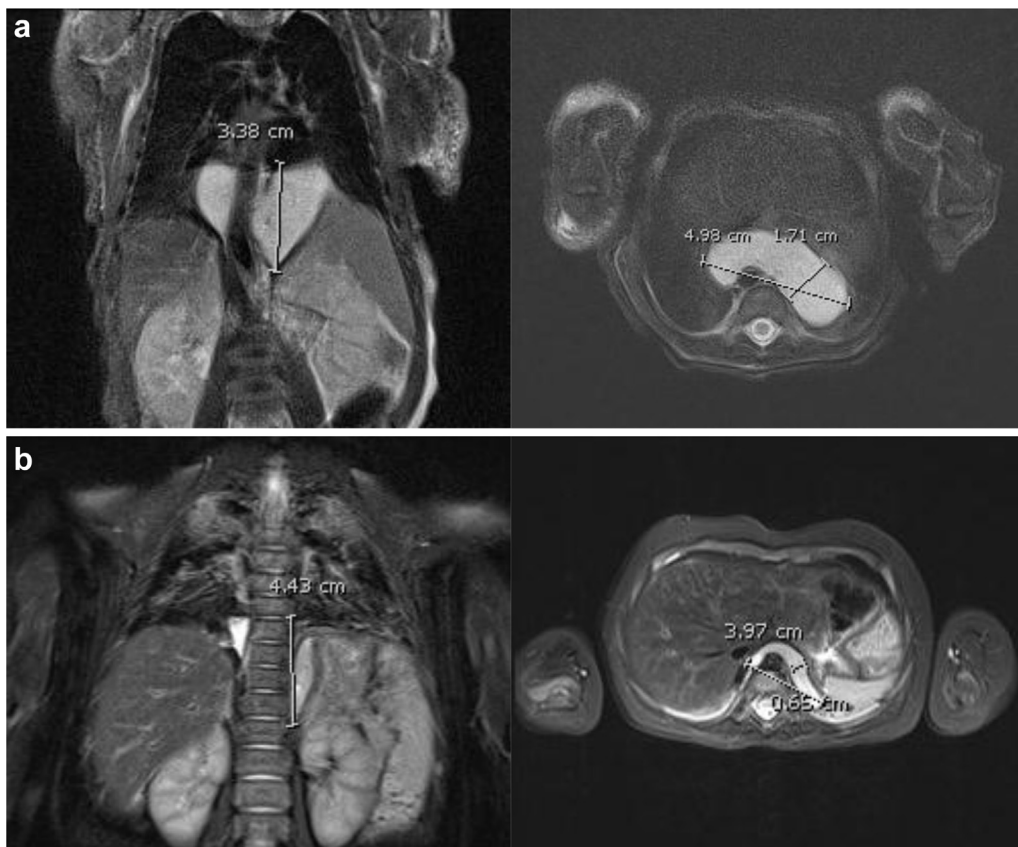
a doxycycline 10 mg/mL solution was added to 7 mL of 0.25% bupivacaine. A total dose of 83 mg, or 11 mg/kg of the doxycycline was administered intra-lesionally in 4 sites in 10 mL aliquots. An 8-French pigtail catheter was placed through the trocar site and removed the following day. The patient tolerated the procedure well, required no narcotics post operatively and began breastfeeding the night of surgery. He was discharged home after 36 h of monitoring, doing well and without symptoms.

At his 2 and 4-week post-op follow-up appointments the patient continued to do well. Follow-up MRI at 6 weeks post-op showed significant reduction in size of the lymphatic malformation as well as resolution of the vascular compression and displacement, without evidence of effusion or ascites (Fig. 2b). The parents elected not to proceed with further sclerotherapy given the significant response.

## 2. Discussion

Congenital lymphatic malformations arise from dysembryogenesis of the lymphatic system in utero and include a wide array of pathologic and clinical manifestations. Pathologically these can be characterized as combined lymphovascular malformations, isolated cystic malformations, and congenital lymphedema. Using the 2014 ISSVA classification system, this patient's lesion is most likely a benign lymphatic malformation without additional syndrome-associated anomaly [1]. Isolated cystic lymphatic malformations are further classified as macrocystic, microcystic, or combined.

The combined incidence of lymphatic anomalies and lymphedema in children is well less than 1%, roughly 0.14% by one report though there is a paucity of literature addressing the true epidemiology of these lesions [2]. There is no male vs. female predilection, with ratio of approximately 1:1. Symptoms, complications, and to some extent prognosis, are primarily related to anatomical location and extent of involvement therein, with 45–52% occurring in head and neck, followed by axilla, mediastinum, retroperitoneum, and groin [3]. Large isolated thoracoabdominal



**Fig. 2.** Representative (a) pre and (b) post-sclerotherapy coronal and axial T2 fat suppressed MRI with contrast showing dramatic improvement after a single thoracoscopy-guided injection of doxycycline.

lymphatic malformations as described in the case above are exceedingly rare [2,4].

Large cystic lesions are often diagnosed prenatally upon 2nd trimester US, as in this case, and may influence the location and timing of delivery. Still, the majority remain diagnosed at birth [3]. On ultrasonography, chyle is typically anechoic or hypoechoic. MRI will allow better visualization of deep anatomic extent, and will show perivascular T2 hyperintensity surrounding the aorta or iliac vessels [5,6]. Macrocystic lesions tend to show multiple septations on ultrasound with cysts of varying size compared to microcystic lesions, which are more uniform appearing as in our patient's case [3].

The natural history of lymphatic malformations rarely involves spontaneous resolution, most tend to grow with the patient if not intervened upon [3,7]. Unmanaged growth of lymphatic malformations carries risk for infection, internal hemorrhage, lymphatic or chylous leak, with additional risk of flow redirection or recurrence following operative intervention [3,8,9].

Therapeutic interventions vary depending on location, symptoms, and active or potential complications, with an increasing trend toward nonoperative management up front using sclerotherapy or medical management. Single agent medical management with sirolimus shows the most promising results, used for various lymphovascular malformations, though this remains associated with leukopenia and other systemic toxicities [10]. Percutaneous sclerotherapy remains the most commonly used non-surgical management technique for lymphatic malformations. Microcystic lesions are less responsive to sclerotherapy than their macrocystic counterparts, and may require additional laser ablation or surgery [3,11,12]. Doxycycline, bleomycin, and OK-432 are the most commonly used agents, and may require multiple injections for maximal resolution depending on lesion size and complexity [8,9,11–18].

Primary resection is often anatomically difficult due to location, proximity to critical structures, and lesions whose extent does not respect fascial planes, further elevating their level of anatomic complexity. For these reasons surgical resection may often be followed by leak, recurrence, or redirection of lymphatic congestion. Preoperative considerations include whether resection is being performed for functional compromise, cosmesis, or both, and to what extent either will be improved by the initial procedure versus a staged approach to resection [3].

The most common post-operative complications of large thoracoabdominal lymphatic malformations are re-accumulation, and leak with chylothorax or chylous ascites, which carries significant potential morbidity in small infants [19]. Lymphatic malformations often grow with associated ectatic veins, which may lead to spontaneous or traumatic internal hemorrhage. Infection, either iatrogenic or due transient bacteremia may prove difficult to treat [3,18].

In this case, the decision to perform sclerotherapy under thoracoscopic guidance was made after considering the risks of all treatment options, to include expectant management, in an asymptomatic patient. As the response to one treatment resulted in resolution of the compression of the great vessels, the parents opted for close follow-up only after a single treatment. He has been followed for several months and continues to well, without evidence of re-accumulation on ultrasound.

### 3. Conclusion

We present a case of successful management of a microcystic posterior mediastinal and retroperitoneal lymphatic malformation treated with a single dose of doxycycline sclerotherapy injected under thoracoscopic guidance.

### References

- [1] Dasgupta R, Fishman SJ. ISSVA classification. *Semin Pediatr Surg* 2014;23(4): 158–61.
- [2] Tasnadi G. Epidemiology and etiology of congenital vascular malformations. *Semin Vasc Surg* 1993;6(4):200–3.
- [3] Elluru RG, Balakrishnan K, Padua HM. Lymphatic malformations: diagnosis and management. *Semin Pediatr Surg* 2014;23(4):178–85.
- [4] Faul JL, Berry GJ, Colby TV, Ruoss SJ, Walter MB, Rosen GD, et al. Thoracic lymphangiomas, lymphangiectasis, lymphangiomatosis, and lymphatic dysplasia syndrome. *Am J Respir Crit Care Med* 2000;161(3 Pt 1): 1037–46.
- [5] Liu NF, Lu Q, Jiang ZH, Wang CG, Zhou JG. Anatomic and functional evaluation of the lymphatics and lymph nodes in diagnosis of lymphatic circulation disorders with contrast magnetic resonance lymphangiography. *J Vasc Surg* 2009;49(4):980–7.
- [6] Rajebi MR, Chaudry G, Padua HM, Dillon B, Yilmaz S, Arnold RW, et al. Intranodal lymphangiography: feasibility and preliminary experience in children. *J Vasc Interv Radiol* 2011;22(9):1300–5.
- [7] Xavier C, Emil S. Spontaneous resolution of lymphatic and venous malformations. *Eur J Pediatr Surg* 2010;20(5):342–5.
- [8] Balakrishnan K, Menezes MD, Chen BS, Magit AE, Perkins JA. Primary surgery vs primary sclerotherapy for head and neck lymphatic malformations. *JAMA Otolaryngol Head Neck Surg* 2014;140(1):41–5.
- [9] Churchill P, Otal D, Pemberton J, Ali A, Flageole H, Walton JM. Sclerotherapy for lymphatic malformations in children: a scoping review. *J Pediatr Surg* 2011;46(5):912–22.
- [10] Lackner H, Karastaneva A, Schwinger W, Benesch M, Sovinz P, Seidel M, et al. Sirolimus for the treatment of children with various complicated vascular anomalies. *Eur J Pediatr* Dec 2015;174(12):1579–84.
- [11] Farnooosh S, Don D, Koempel J, Panossian A, Anselmo D, Stanley P. Efficacy of doxycycline and sodium tetradecyl sulfate sclerotherapy in pediatric head and neck lymphatic malformations. *Int J Pediatr Otorhinolaryngol* 2015;79(6): 883–7.
- [12] Burrows PE, Mitri RK, Alomari A, Padua HM, Lord DJ, Sylvia MB, et al. Percutaneous sclerotherapy of lymphatic malformations with doxycycline. *Lymphat Res Biol* 2008;6(3–4):209–16.
- [13] Cahill AM, Nijs E, Ballah D, Rabinowitz D, Thompson L, Rintoul N, et al. Percutaneous sclerotherapy in neonatal and infant head and neck lymphatic malformations: a single center experience. *J Pediatr Surg* 2011;46(11): 2083–95.
- [14] Jamal N, Ahmed S, Miller T, Bent J, Brook A, Parikh S, et al. Doxycycline sclerotherapy for pediatric head and neck macrocystic lymphatic malformations: a case series and review of the literature. *Int J Pediatr Otorhinolaryngol* 2012;76(8):1127–31.
- [15] Shergill A, John P, Amaral JG. Doxycycline sclerotherapy in children with lymphatic malformations: outcomes, complications and clinical efficacy. *Pediatr Radiol* 2012;42(9):1080–8.
- [16] Motz KM, Nickley KB, Bedwell JR, Yadav B, Guzzetta PC, Oh AK, et al. OK432 versus doxycycline for treatment of macrocystic lymphatic malformations. *Ann Otol Rhinol Laryngol* 2014;123(2):81–8.
- [17] Ghaffarpour N, Petrini B, Svensson LA, Boman K, Wester T, Claesson G. Patients with lymphatic malformations who receive the immunostimulant OK-432 experience excellent long-term outcomes. *Acta Paediatr* 14 Jul 2015;104(11): 1169–73.
- [18] Perkins JA, Manning SC, Tempero RM, Cunningham MJ, Edmonds Jr JL, Hoffer FA, et al. Lymphatic malformations: review of current treatment. *Otolaryngol Head Neck Surg* 2010;142(6):795–803. 803.e1.
- [19] Chen W, Adams D, Patel M, Gupta A, Dasgupta R. Generalized lymphatic malformation with chylothorax: long-term management of a highly morbid condition in a pediatric patient. *J Pediatr Surg* 2013;48(3): e9–12.