

HISTOLOGICAL CHANGES ON TESTES OF MICE ADMINISTERED WITH DIFFERENT CONCENTRATIONS OF *Cosmos caudatus* ETHANOLIC EXTRACT

MARYSIA JULIUS BOOH, NOORAAIN HASHIM, DZULSUHAIMI DAUD
and NUR HILWANI ISMAIL*

*School of Biological Sciences, Faculty of Applied Science,
Universiti Teknologi MARA, 40450 Shah Alam, Selangor, Malaysia*

**E-mail: hilwani@salam.uitm.edu.my*

ABSTRACT

The histological changes of testes of mice were assessed after 28 days treatment with different concentrations of *Cosmos caudatus* ethanolic extract (50, 125, 500 and 1000 mg/kg). Testicular tissues were fixed in 10% formalin, embedded in paraffin wax and cut for histological study. The qualitative assessment of histological changes of the testes showed different degrees of thickness and density of seminiferous tubules as rated according to the following scales: 1, thin and low density of seminiferous tubules; 2, moderately thick and moderately dense seminiferous tubules; 3, thick and dense seminiferous tubules. Scale 3 was observed in testes of mice treated with 500 and 1000 mg/kg b wt., scale 2 in group treated with 50 mg/kg b.wt. and scale 1 in group treated with 125 mg/kg b wt. of the extract. The total percentage of condensed seminiferous tubules (seminiferous tubules without lumen) is highest in the testes of mice from 500 mg/kg b wt. (52.5%) and the lowest from 125 mg/kg b wt. (26.3%). Both groups from 500 and 1000 mg/kg b wt. showed significant results ($p < 0.05$) which the thickness of the seminiferous tubules increased as compared with the control group of mice. Hence, the higher concentration of *C. caudatus* gave better effects on spermatogenic activity of the testes of mice, as revealed by the density and thickness of the seminiferous tubules.

Key words: *Cosmos caudatus*, Spermatogenic cells, Testes, Seminiferous tubules

INTRODUCTION

Cosmos caudatus, or locally known as “ulam raja” (Norzalina and Ong, 1999) is used as salad and usually eaten raw in Malay’s cuisine (Ahmed *et al.*, 2012). The consumption of *C. caudatus* is based on daily basis in which it is included in daily meals. Recent studies suggest that *C. caudatus* have potent anti-oxidant properties which are believed to alleviate general health and enhance blood circulation (Shui *et al.*, 2005; Hassan, 2006; Bodeker, 2009). This plant also is enriched with source of bioactive compounds that include phenolics, flavonoids, carbohydrates, minerals, proteins and vitamins that increase this plant’s nutritional value (Faridah *et al.*, 2003; Faridah *et al.*, 2006; Hassan *et al.*, 2012; Hamidun *et al.*, 2014). Pharmacological review on this medicinal plant revealed that besides an antioxidant effect, it also exhibited anti-bacterial, antifungal, antidiabetic

activities as well as anti-osteoporosis and antihypertensive effects (Hamidun *et al.*, 2014).

The previous acute toxicity study conducted on male rats showed the aqueous extract of *C. caudatus* can cause acute hepatotoxicity when *C. caudatus* consumed in high doses (Norazlina *et al.*, 2013; Hamidun *et al.*, 2014). However, the study conducted on acute and subacute toxicity studies of ethanolic extract of *C. caudatus* leaf in Sprague Dawley rats demonstrated that the plant gave the lowest toxicity effects and had displayed high safety margin since the experimental animals could tolerated up to 5000 mg/kg body weight of the extract orally (Amna *et al.*, 2013). The effects of *C. caudatus* on dynamic and cellular bone histomorphometry in ovariectomized rats also has been studied and it showed that the *C. caudatus* at 500mg/kg b wt. may be an alternative treatment in restoring bone damage that may occur in post-menopausal women (Mohamed *et al.*, 2013).

Since this plant gave different toxicity effects on different biological parameters, thus, the present study was carried out to assess the histological

* To whom correspondence should be addressed.

changes of testes of mice, emphasizing on the qualitative and quantitative analyses of the seminiferous tubules thickness (μm) of the mice administered by different concentrations (50, 125, 500 and 1000 mg/kg b wt.) of *C. caudatus* ethanolic extract.

MATERIALS AND METHODS

Animals

The total number of animals used in this study was 25 male mice. They were divided into five groups with five mice per group. The animals used were sexually matured male mice (7-8 weeks old) weighing 22-32 g. Mice were sacrificed by cervical dislocation after 28 days of treatment with different concentrations of *C. caudatus* ethanolic extract (50, 125, 500 and 1000 mg/kg b wt. /day). All protocols involving handling and animal experimentation were approved by the Committee of Animal Research and Ethic, UiTM CARE (Ref No. 24/2013).

Histological studies

Following cervical dislocation, testes of each mouse including those of the control group were removed, trimmed off extraneous and fragments of testicular tissues and were fixed in 10% formalin. Fixed testes were embedded in paraffin wax and cut for histological study. The sections were observed using inverted microscope. The qualitative assessment of histological changes on mice testes showed differing degree of thickness and were rated according to different scales: 1, thin and low density of seminiferous tubules (<30% of seminiferous tubule (ST) consists of spermatogenic cells); 2, moderately thick and moderately dense seminiferous tubules (>30% of ST consists of spermatogenic cells); 3, thick and dense seminiferous tubules (>50% of ST consists of spermatogenic cells).

Statistical analysis

One-way Analysis of Variance (ANOVA) including post hoc test and descriptive were conducted using SPSS software, Version 20.0. The difference in the mean values was considered significant at $p < 0.05$.

RESULTS AND DISCUSSION

The observation of 500 and 1000 mg/kg b wt. treated groups have shown scale 3, whilst 50 mg/kg b wt. treated group showed scale 2 and 125 mg/kg b wt. treated group showed scale 1. The histological results are shown in Figure 1. Table 1 shows the total percentages of the densely packed seminiferous tubules in all of the treatment groups per histological

slide viewed under 200x total magnification. The total percentages of densely packed seminiferous tubule (seminiferous tubules without lumen) was highest in the testes of mice from 500 mg/kg b wt. treated group (52.5%), and the lowest was from 125 mg/kg b wt. treated group (26.3%). Ten seminiferous tubules were randomly selected from each slide to measure its thickness of each testes from different treatment groups. Figure 2 shows the seminiferous tubules thickness (μm) in all treatment groups. Mice treated with 500 and 1000 mg/kg of *C. caudatus* showed that the seminiferous thickness are significantly thicker ($p < 0.05$) than the control group, and mice treated with 125 mg/kg *C. caudatus* have thinner seminiferous tubules as compared to the control even it gave no significant result. The results obtained from this study showed that *C. caudatus* ethanolic extract on higher concentrations (500 and 1000 mg/kg) gave better histological changes on the testes. The effects of *C. caudatus* on sperm quality of mice, *Mus musculus* were previously investigated in which we used the same concentrations as 50 mg/kg b wt, 125 mg/kg b wt, 500 mg/kg b wt and 1000 mg/kg b wt of the extract. It was revealed that all of the concentrations used have no negative effects on sperm quality, instead at higher concentrations (500 and 1000 mg/kg b wt) better quality of sperm were produced. These included total motility, sperm count and sperm viability assessment (Marysia *et al.*, 2015). As *C. caudatus* is known for its potent anti-oxidant properties (Amalia *et al.*, 2012) this property enables it to scavenge free radicals and therefore reduce oxidative stress (Reihani and Azhar, 2012). Recently, radical-scavenging activities of compounds isolated from this plant have been reported (Faridah *et al.*, 2003). The radical-scavengers are able to get rid of the excessive amount of free reactive oxygen species which can disrupt sperm function and thus, diminishing the quality of the sperm. This supports the findings which revealed the better assessment of histological changes on testes when the mice were treated with 500 mg/kg b wt. and 1000 mg/kg b wt. of *C. caudatus* ethanolic extract. In this study, although the lower concentrations of the extract showed much lower data values on the qualitative and quantitative assessment as compared to the control group, nevertheless the results on the statistical analysis of the thickness of the seminiferous tubules has showed no significant difference. Meanwhile at 125 mg/kg extract, the experimental animals gave much lower values in all the three parameters discussed. The intercellular space of the seminiferous tubules in lower treatment groups are much wider as compared to the higher concentration treatment groups (Fig. 1: B,C). This suggests that the spermatogenesis is disrupted at both of the lower

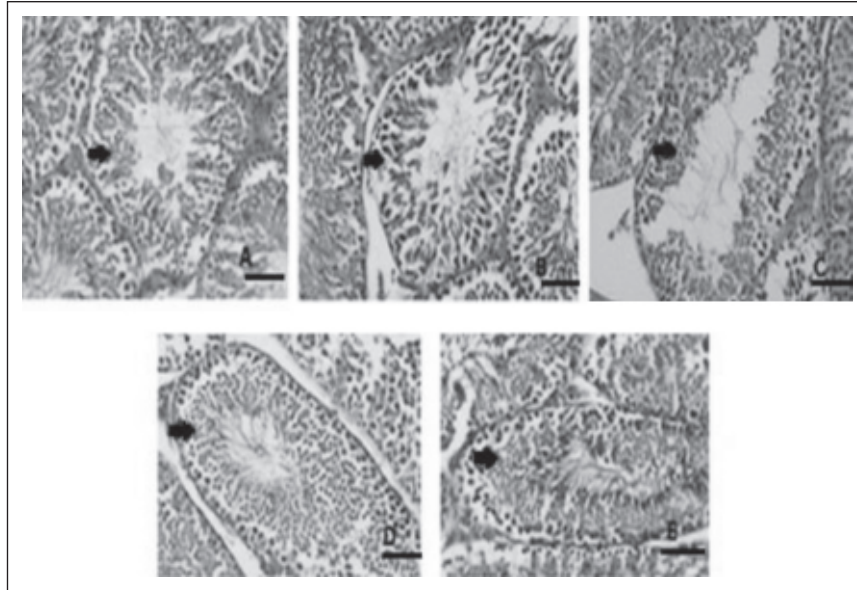


Fig. 1. The degree of thickness of seminiferous tubules in different treatment groups (Arrow heads showed the seminiferous tubules); (A) Control Group (>40% of ST consists of spermatogenic cells) (B) 50 mg/kg b wt. (>30% of ST consists of spermatogenic cells) (C) 125 mg/kg b wt. (<30% of ST consists of spermatogenic cells) (D) 500 mg/kg b wt. (>50% of ST consists of spermatogenic cells) (E) 1000 mg/kg b wt. (>50% of ST consists of spermatogenic cells) Scale bar = 25 μ m, 200x Total Magnification.

Table 1. Total percentage of the densely packed seminiferous tubules in all treatment groups supplemented with *C. caudatus* ethanolic extracts

Treatment group	Number of densely packed seminiferous tubules	Total Number of seminiferous tubules	%
Control	136	298	45.6
50 mg/kg	143	406	35.2
125 mg/kg	96	365	26.3
500 mg/kg	189	360	52.5
1000 mg/kg	145	286	50.7

All data values shows no significant difference ($p>0.05$)

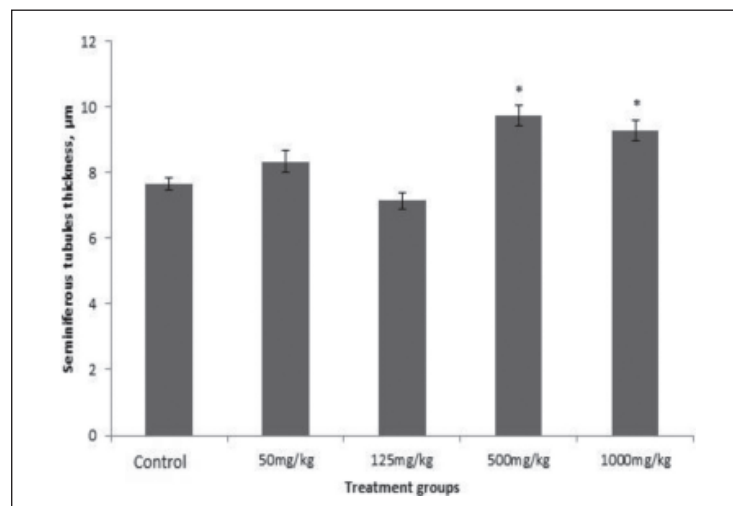


Fig. 2. The seminiferous tubules thickness (μ m) in all treatment groups (n=5),
* Significant difference at ($p<0.05$)

concentration used, especially for 125 mg/kg b wt. of extract. As spermatogenesis is a complex biological process of cellular transformation that produces male haploid germ cells from diploid spermatogonial stem cells (Creasy, 1997), it is obvious that the production of spermatozoa among mice treated with 125mg/kg was very low and the seminiferous tubules seem were atrophied. However, the phase at which the disruption begins is yet to be determined.

CONCLUSIONS

The higher concentration of *C. caudatus* ethanolic extract have better effect on testes of mice, especially in the thickness of seminiferous tubules and may contribute to produce better sperm quality. Further study on using 125 mg/kg b wt. of the extract of *C. caudatus* ethanolic extract is recommended to investigate its capability in sperm production and its quality, specifically as the result obtained from this treatment group was much lower than the control group.

ACKNOWLEDGEMENTS

The study was financed by Fundamental Research Grant Scheme (600-RMI/FRGS 5/3 (64/2013)) and Research Acculturation Grant Scheme (600-RMI/RAGS 5/3 (8/2012)) from Ministry of Education, Malaysia.

REFERENCES

- Ahmed, M., Faridah, A., Alfi, K., Maulidiani, H., Khozirah, S., Young, H.C. & Lajis, N.H. 2012. H-NMR-based metabolomics approach to understanding the drying effects on the phytochemicals in *Cosmos caudatus*. *Food Research International*. **49**: 763-770.
- Amalia, L., Kusnandar, A., Sukrasno, Fidrianny, I. & Inggriani, R. 2012. Antihypertensive potency of wild *Cosmos* (*Cosmos caudatus* Kunth, Asteraceae) leaf extract. *Journal of Pharmaceutical and Toxicological Methods*. **7(8)**: 359-368.
- Bodeker, G. 2009. Health and beauty from the rainforest: Malaysian traditions of Ramuan. Kuala Lumpur.
- Creasy, D.M. 1997. Evaluation of testicular toxicity in safety evaluation studies: the appropriate use of spermatogenic staging. *Toxicologic Pathology*. **25(2)**:119-131.
- Faridah, A., Lajis, N.H., Israf, D.A., Khozirah, S., Umi Kalsom, Y. 2006. Antioxidant and nitric oxide inhibition activities of selected Malay traditional vegetables. *Food Chemistry* **95**: 566-573.
- Faridah, A., Shaari, K., Lajis, N.H., Israf, D.A. & Umi Kalsom, Y. 2003. Antioxidative and radical scavenging properties of the constituents isolated from *Cosmos caudatus* kunth. *Natural Product Science*. **9**: 245-248.
- Farah Amna, O., Nooraain, H., Noriham, A., Azizah, A.H. & Nurul Husna, R. 2013. Acute and oral subacute toxicity study of ethanolic extract of *Cosmos caudatus* leaf in Sprague Dawley rats. *International Journal of Bioscience, Biochemistry, Bioinformatics*. **3(4)**: 301-305.
- Hamidun, B., Syarul, N.B., Siti, N.B., Noriha, M.A. & Normah, M.N. 2014. *Cosmos caudatus* kunth: A traditional medicinal herb. *Global J. of Pharm.* **8(3)**: 420-426.
- Hassan, S.A., Mijin, S., Yusoff, U.K., Ding, P. & Wahab, P.E.M. 2012. Nitrate, ascorbic acid, mineral and antioxidant activities of *Cosmos caudatus* in response to organic and mineral-based fertilizer rates. *Mol. Diversity Perservation Intern. J.* **17(7)**: 7843-7853.
- Hassan, W.E. 2006. *Healing herbs of Malaysia*. Kuala Lumpur: Federal Land Development Agency. ISBN 978-983-99544-2-5.
- Marysia, J.B., Nooraain, H., Nur Hilwani, I., Dzulsuhaimi, D., Nurdiana, S. & Mohd, F.Z.R.Y. 2015. Effects of *Cosmos caudatus* on sperm quality of mice, *Mus musculus*. *Malays. Appl. Biol.* **44(1)**: 87-91.
- Mohamed, N., Zulaikha, S., Elvy Suhana, M.R. & Norliza, M. 2013. The Effects of *Cosmos caudatus* on Structural Bone Histomorphometry in Ovariectomized Rats. *BioMed Central Research Notes*. **6**: 239.
- Norazlina, M., Ehsan, S.Z., Noor' Adilah, K., Lee, C.P., Farhana, F., Derick, P., Ima-Nirwana, S., Nazrun, A.S. & Norliza, M. 2013. Acute toxicity study of *Cosmos caudatus* on biochemical parameters in male rats. *Sains Malaysiana*. **42(9)**: 1247-1251.
- Ong, H.C. & Norazlina, J. 1999. Malay herbal medicine in Gemencheh, Negeri Sembilan, Malaysia. *Fitoterapia*. **7(1)**: 10-14.
- Reihani, S.F.S. & Azhar, M.E. 2012. Antioxidant activity and total phenolic content in aqueous extracts of selected traditional malay salads (ulam). *International Food Research Journal*. **19(4)**: 1439-1444.
- Shui, G., Leong, L.P. & Shih, P.W. 2005. Rapid screening and characterisation of antioxidants of *Cosmos caudatus* using liquid chromatography coupled with mass spectrometry. *J. of Chroma. B: Tech. in the Biomed. and Life Sciences*. **827(1)**: 127-138.