

Case Report

Huge Adenomyotic Cyst in Pregnancy

Raimi ZH, Ng BK (✉), Omar MH, Lim PS

Department of Obstetrics and Gynaecology, Faculty of Medicine, Universiti Kebangsaan Malaysia Medical Centre, Jalan Yaacob Latif, Bandar Tun Razak, 56000 Cheras, Kuala Lumpur, Malaysia.

Abstract

Adenomyotic cyst is a rare variant of adenomyosis. It is believed to arise from repeated focal haemorrhages resulting in cystic spaces filled with altered blood products. We present a rare case of a huge adenomyotic cyst in a 27-year-old primigravida, who was in her first trimester, complaining of sudden lower abdominal pain. Diagnostic laparoscopy performed to rule out other cause of acute abdomen. Her pregnancy went on smoothly. She delivered a baby girl of 2.82 kg via vaginal delivery at 39 weeks. Diagnosis and management of this rare clinical entity were reviewed and discussed.

Keywords: Abdominal pain, adenomyosis, adenomyotic cyst, diagnostic laparoscopy, pregnancy

Correspondence:

Ng Beng Kwang, Department of Obstetrics and Gynaecology, Faculty of Medicine, Universiti Kebangsaan Malaysia Medical Centre, Jalan Yaacob Latif, Bandar Tun Razak, 56000 Cheras, Kuala Lumpur, Malaysia. Tel: +603-91455949 Fax: +603-91456672 Email: nbk_9955@yahoo.com/ nbk9955@ppukm.ukm.edu.my

Date of submission: 14 July, 2016

Date of acceptance: 30 Sept, 2016

Introduction

Cystic lesions within the uterus are uncommon (1,2). Uterine cysts are classified into 2 main groups: congenital and acquired. Congenital cysts derived from Mullerian anomalies like non-communicating rudimentary horn (3). Acquired cysts include cystic adenomyosis (4,5) and cystic degeneration of uterine fibroid (6). Adenomyotic cyst, cystic adenomyosis or cystic adenoma is a rare variant of adenomyosis (7). Its occurrence was attributed to repeated focal haemorrhages resulting in cystic spaces filled with altered blood products. We present a case of a huge adenomyotic cyst in a 27-year-old primigravida, who was in her first trimester, complaining of sudden lower abdominal pain. Diagnostic laparoscopy performed to rule out other cause of acute abdomen. Her pregnancy progressed well till 39 weeks gestation and she delivered a baby girl weighing 2.82 kg via vaginal delivery. Diagnosis and management of this rare clinical entity were reviewed and discussed.

Case Report

A 27-year-old primigravida at 5 weeks period of amenorrhoea presented with lower abdominal pain for one-week duration. There was no vomiting, vaginal bleeding or symptoms suggestive of urinary tract infection. Pre pregnancy, she had secondary dysmenorrhoea that was relieved by oral analgesia. There was no other significant medical or family history. She had appendectomy done 10 years ago. Upon examination, she was not pale or tachycardic. Abdominal examination revealed a tender lower abdomen with a pelvic mass corresponded to a 24 weeks sized gravid uterus. Transabdominal scan confirmed an intrauterine pregnancy. The gestational sac measured 17.8 mm (5 weeks +3 days) with presence of yolk sac (Fig. 1a). There was a cystic mass seen measuring 14.3 x 10.1 cm (Fig. 1b). Her haemoglobin was 12.5g/dl. In view of persistent pain and suspected twisted ovarian cyst, she was counseled for diagnostic laparoscopy.

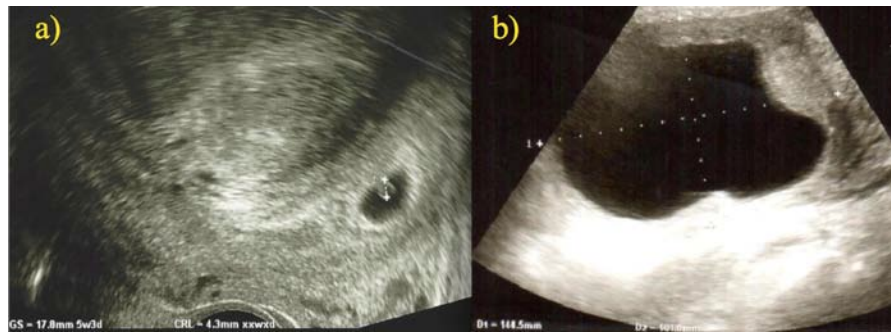


Figure 1: a) Transabdominal scan confirmed an intrauterine pregnancy. The gestational sac measured 17.8 mm (5 weeks +3 days) with presence of yolk sac, b) there was a cystic mass seen measuring 14.3 x 10.1 cm.

An enlarged uterus of 24 weeks size was found during the diagnostic laparoscopy. Both fallopian tubes and ovaries were normal. Laparoscopic drainage was assisted with ultrasound scan of the fundal uterine cyst revealed chocolate material around 100 cc. Her post-operative recovery was uneventful. She remained asymptomatic and her pregnancy progressed well. The uterine cystic mass was smaller in size post aspiration and it remained the same till delivery. She had an uneventful spontaneous vaginal delivery at 39 weeks and delivered a baby girl weighing 2.82 kg. Upon 2 months postpartum, the uterus was just palpable at 12 weeks size but it progressively increased to 24 weeks size at 6 months postpartum. She remained asymptomatic. Patient was counseled for surgical intervention but still considering.

Discussion

Uterine cysts are uncommon in gynaecologic practice. Owing to the rare occasion of this pathology, the typical symptoms of dysmenorrhoea and pelvic pain, and its closed proximity to the ovary, it can be mistaken as endometriotic cyst. Four distinct type of adenomyosis had been reported by Pistofidis et al. in which diffuse lesion was the most common type (54.5%) followed by nodular (28%), sclerotic (13%) and lastly cystic adenomyosis (4.5%) (7). Juvenile cystic adenomyosis (JCA) commonly occurred in a younger patient (8) and might also be due to congenital defect in Mullerian duct. Takeuchi et al. proposed diagnosis of JCA based on the following criteria: 1) age less than 30 years; 2) cystic lesion more than 10mm and covered by hypertrophic uterine myometrium; and 3) symptoms of dysmenorrhoea (2). Whereas, adult type was found in older patient with history of previous uterine surgery such as caesarean section, myomectomy and curettage (9,10).

Obtaining a correct diagnosis is challenging due to its rarity and the patient was pregnant. This patient presented in first trimester with acute abdominal pain.

Working diagnosis at that time was an ovarian accident as the cystic mass was found to be in closed proximity with the posterior uterine wall. Other differentials diagnoses include cystic degeneration of uterine fibroid, uterine bicornuate with haematometra and endometriosis (11,12).

Transvaginal or transabdominal ultrasound scan is usually the first choice of imaging modality when assessing a pregnant woman. Unfortunately, the precise diagnosis of cystic adenomyosis is not always feasible. Accurate sonographic localisation of the cystic lesion in relation to myometrium and endometrial cavity can be strenuous. Thus, some cases were mistaken as endometriotic cyst (13) or uterine anomalies (11). Other imaging modalities such as Computed Tomography scan was limited in pregnant women in view of radiation risk. Whereas, use of Magnetic Resonance Imaging (MRI) was found to be superior with higher degree of certainty in diagnosing adenomyosis (14). However, diagnostic laparoscopy was chosen instead of MRI in view of severe abdominal pain.

Huge adenomyotic cysts are rare. The average size of adenomyotic cyst was 31 mm in diameter (range 25-42 mm) (2). Koga et al. reported a giant cystic adenomyosis measuring 17 x 11 x 8 cm in a 37 year old woman who presented with menorrhagia. The patient was treated with four vaginal cyst aspiration then gonadotrophin releasing hormone (15). She underwent hysterectomy subsequently due to persistent symptoms.

Treatment of adenomyotic cyst depends on patient's age, severity of symptoms, location and size of the cyst, wish for future pregnancy and risk of malignancy. Medical therapy with combined oral contraceptive pills or GnRH analogue only allows short-term symptomatic relief and shrinkage of the lesion (2). Surgical excision remained as a preferred choice. In younger patients, conservative procedure in

the form of laparoscopic excision should be offered but this requires certain level of expertise. As adenomyotic tissue grows deeply into the uterine musculature, excision of an adenomyotic lesion can be difficult as compared to removal of fibroid. Improvement of symptoms post-operatively was remarkable and recurrence risk is low (2).

As in our patient, diagnostic laparoscopy revealed a huge uterine cyst, in which aspiration was performed. As she was pregnant, we did not proceed for further intervention. Though no complete excision was made, she had a favourable pregnancy and labour outcome.

Conclusion

Although no specimen was sent for histopathological assessment, the cyst resembled an adenomyotic cyst based on patient's clinical symptoms, ultrasound features and the diagnostic laparoscopy finding of enlarged uterus with chocolate fluid aspirated. Awareness of this condition is important for timely and accurate diagnosis followed by appropriate intervention.

References

1. Cucinella G, Billone V, Pitruzzella I, Lo Monte AI, Palumbo VD, Perino A. Adenomyotic cyst in a 25-year-old woman: case report. *J Minim Invasive Gynecol* 2013; 20(6): 894-8.
2. Takeuchi H, Kitade M, Kikuchi I, Kumakiri J, Kuroda K, Jinushi M. Diagnosis, laparoscopic management, and histopathologic findings of juvenile cystic adenoma: a review of nine cases. *Fertil Steril* 2010; 94(3): 862-8.
3. Singh P, Gupta R, Das B, Bajaj SK, Misra R. Midtrimester spontaneous torsion of unruptured gravid rudimentary horn: Presurgical diagnosis on magnetic resonance imaging. *J Obstet Gynecol Res* 2015; 41(9): 1478-82.
4. Brosens I, Gordts S, Habiba M, Benagiano G. Uterine cystic adenomyosis: A disease of younger women. *J Pediatr Adolesc Gynecol* 2015; 28(6): 420-6.
5. Tahlan A, Nanda A, Mohan H. Uterine adenomyoma: a clinicopathologic review of 26 cases and review of the literature. *Int J Gynecol Pathol* 2006; 25(4): 361-5.
6. Peng K, Jiang LY, Teng SW, Wang PH. Degenerative leiomyoma of the cervix: atypical clinical presentation and an unusual finding. *Taiwan J Obstet Gynecol* 2016; 55(2): 293-5.
7. Pistofidis G, Makrakis E, Koukoura O, Bardis N, Balinagos P, Anaf V. Distinct types of uterine adenomyosis based on laparoscopic and histopathologic criteria. *Clin Exp Obstet Gynecol* 2014; 41(2): 113-8.
8. Branguinho MM, Marques AL, Leite HB, Silva IS. Juvenile cystic adenomyoma. *BMJ Case Rep* 2012; 2012. pii: bcr2012007006.
9. Kim MJ. A case of cystic adenomyoma of the uterus after complete abortion without transcervical curettage. *Obstet Gynecol Sci* 2014; 57(2): 176-9.
10. Wang JH, Wu RJ, Xu KH, Lin J. Single large cystic adenomyoma of the uterus after cornual pregnancy and curettage. *Fertil Steril* 2007; 88(4): 965-7.
11. Pontrelli G, Bounous VE, Scarperi S, Minelli L, Di Spiezio Sardo A, Florio P. Rare case of giant cystic adenoma mimicking a uterine malformation, diagnosed and treated by hysteroscopy. *J Obstet Gynaecol Res* 2015; 41(8): 1300-4.
12. Bailleux M, Bernard JP, Benachi A, Deffieux X. Ovarian endometriosis during pregnancy: a case series of 53 endometriomas. *Eur J Obstet Gynecol Reprod Biol* 2015; pii: S0301-2115(15)00342-5.
13. Koukoura O, Kapsalaki E, Daponte A, Pistofidis G. Laparoscopic treatment of a large uterine cystic adenomyosis in a young patient. *BMJ Case Rep* 2015; 2015. pii: bcr2015210358.
14. Leyendecker G, Bilgicyildirim A, Inacker M, et al. Adenomyosis and endometriosis. Re-visiting their association and further insights into the mechanisms of auto-traumatisation. An MRI study. *Arch Gynecol Obstet* 2015; 291(4): 917-32.
15. Koga K, Osuga Y, Hiroi H, et al. Images in reproductive medicine. A case of giant cystic adenomyosis. *Fertil Steril* 2006; 85(3): 748-9.