

Case Report

Velamentous Cord Insertion: A Rare Cause of Emergency Caesarean Section

Raimi Z, Ng BK (✉), Abdul Kadir AK, Lim PS

Department of Obstetrics and Gynaecology, Faculty of Medicine, Universiti Kebangsaan Malaysia Medical Centre, Jalan Yaacob Latif, Bandar Tun Razak, 56000 Cheras, Kuala Lumpur, Malaysia.

Abstract

Pregnancies complicated with velamentous cord insertion (VCI) are at risk of adverse perinatal outcome. Placental and umbilical cord assessment should be performed during routine obstetric ultrasound. We report a case of velamentous cord insertion that was not identified antenatally. A 28-year-old primigravida at 40 weeks gestation presented in active phase of labour. Intrapartum, cardiotocography (CTG) tracing was pathological. Thus, decision was made for emergency caesarean section and a velamentous cord insertion was found. Despite a favourable outcome, this case highlighted the importance of antenatal diagnosis of VCI and thus preventing catastrophic outcome.

Keywords: Adverse outcome, antenatal diagnosis, perinatal, ultrasound, velamentous cord

Correspondence:

Ng Beng Kwang, Department of Obstetrics and Gynaecology, Faculty of Medicine, Universiti Kebangsaan Malaysia Medical Centre, Jalan Yaacob Latif, Bandar Tun Razak, 56000 Cheras, Kuala Lumpur, Malaysia. Tel: +603-91455949 Fax: +603-91456672 Email: nbk_9955@yahoo.com / nbk9955@ppukm.ukm.edu.my

Date of submission: 11 May, 2016

Date of acceptance: 29 Sept, 2016

Introduction

The umbilical cord usually inserts into the centre of placenta. Velamentous cord insertion (VCI) is an uncommon, abnormal placental cord insertion located at the edge of placental disk. The umbilical vessels course between the membranes before reaching the placenta (1). Pregnancies complicated with VCI are at risk of adverse maternal outcome such as preterm labour, abruptio placenta, vasa praevia, manual removal of placenta and post partum haemorrhage; and adverse perinatal outcome such as abnormal fetal heart tracing, low Apgar score, neonatal intensive unit admission as well as neonatal death (2-7). We report a case of undiagnosed velamentous cord insertion. The patient underwent emergency caesarean section for abnormal CTG suggestive of fetal distress. Despite favourable maternal and neonatal outcomes, this case highlighted the importance of antenatal diagnosis of VCI and thus preventing hazardous complication particularly vasa praevia, fetal exsanguination and fetal death.

Case Report

A 28-year-old primigravida at 40 weeks gestation was admitted in latent phase of labour. She had a dating scan done at 11 weeks gestation, which confirmed her pregnancy. Her antenatal follow-ups were uneventful. She had a total of 4 ultrasound scans done at 11, 21, 30 and 40 weeks which, showed satisfactory fetal growth. The placenta was located at posterior upper segment with no abnormalities detected.

During her active phase of labour, fetal wellbeing was monitored with continuous CTG. The CTG tracing was noted to be pathological at four hours in active phase of labour with baseline tachycardia, poor variability and variable deceleration, which suggestive of fetal distress (Fig. 1). Her cervical os remained at 5cm dilatation and moderate meconium stained liquor was noted. In view of CTG was consistent with signs of fetal distress and remote from fully dilated os, patient was subjected for emergency caesarean section for immediate delivery. The procedure was uneventful.

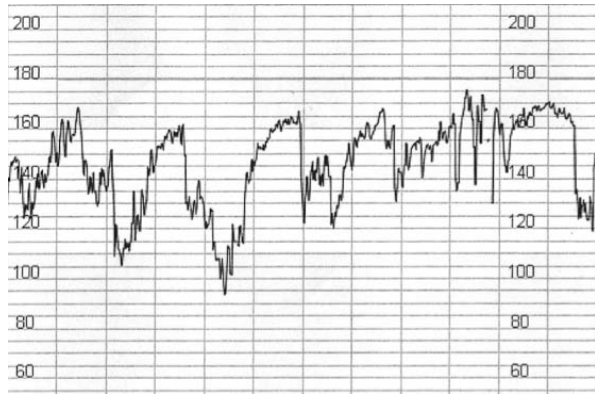


Figure 1: Cardiotocographic tracing showed atypical variable deceleration

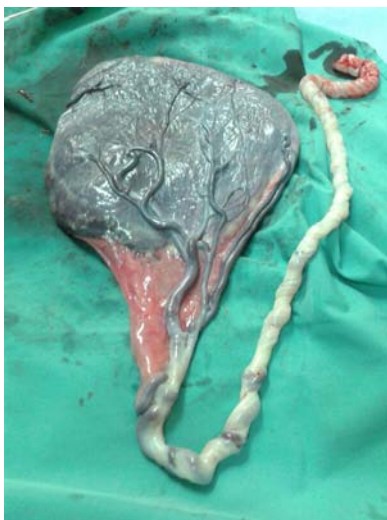

Figure 2: Placenta with velamentous cord insertion

A healthy baby boy weighing 3.4 kg was born with cord pH of 7.32. Velamentous cord insertion with vessels, approximated 10 cm in length, traversing in between the membranes was observed (Fig. 2).

Discussion

The reported incidence of VCI was around 0.2-0.6 per 1000 pregnancies (4,8). Its pathogenesis was not well established. However, it was more commonly found in placenta praevia, assisted reproductive conception and multiple pregnancies (6,8,9). There was no identifiable risk factor found in our patient. As previously reported, pregnancies complicated with VCI are at risk of adverse maternal and perinatal outcomes. Fetal distress was the complication that was observed in our case. Routine systematic identification of abnormal cord insertion was suggested as part of an important prenatal ultrasound evaluation especially for patient counseling purposes.

Though VCI can develop at late gestation, most cases of VCI could be identified as early as 11-14 weeks (10) and with the colour Doppler imaging of umbilical vessels at 18-20 weeks gestation, the diagnosis of VCI could be made in almost 99.8% cases (11). The mean duration required for the identification of cord insertion during ultrasound scan was reported to be one minute. The sensitivity, specificity, positive predictive value and negative predictive value for diagnosis of VCI were 100%, 99.8%, 83% and 100% respectively (11). However, routine inspection of placental cord insertion is not a standard practice in singleton pregnancy as recommended by International Society of Ultrasound in Obstetrics and Gynecology (ISUOG) (12). Thus, it was not routinely examined during our antenatal scan.

Abnormal fetal heart rate was frequently observed in VCI. During first stage of labour, variable deceleration was noted in 34.5% of cases. This was significantly higher as compared to those without VCI (11.7%, $p < 0.0001$) (13) but there was no significant different in second stage of labour (14). Other study found that risk of emergency caesareans section was doubled in women with VCI compared to those without VCI (15.3% vs. 8.3%, $p = 0.001$) (5). VCI is distinguished by membranous umbilical vessels at the placental site. Due to lack of protection from Wharton's jelly, these vessels are therefore prone to compression and kinking. This will result in subsequent reduction of blood flow and fetal heart rate abnormalities in the CTG as showed in our case.

Conclusion

With the identification of high-risk pregnancy, which includes abnormal placental cord insertion, a safer delivery can be provided. Thus, effort should be made to ascertain the diagnosis of VCI prenatally in order to minimise any catastrophic outcome. Despite the favourable outcome in this case, we highlighted the importance of early diagnosis and thus reduce adverse maternal and perinatal outcome. Nevertheless, a large prospective randomised controlled trial is needed to ascertain the benefits of routine inspection of placental cord insertion during antenatal scan.

References

1. Hasegawa J, Matsuoka R, Ichizuka K, Sekizawa A, Okai T. Ultrasound diagnosis and management of umbilical cord abnormalities. *Taiwan J Obstet Gynecol* 2009; 48(1): 23-7.

2. Yerlikaya G, Pils S, Springer S, Chalubinski K, Ott J. Velamentous cord insertion as a risk factor for obstetric outcome: a retrospective case-control study. *Arch Gynecol Obstet* 2016; 293(5): 975-81.
3. Ebbing C, Kiserud T, Johnsen SL, Albrechtsen S, Rasmussen S. Third stage of labor risks in velamentous and marginal cord insertion: a population-based study. *Acta Obstet Gynecol Scand* 2015; 94(8): 878-83.
4. Raisanen S, Georgiadis L, Harju M, Keski-Nisula L, Heinonen S. Risk factors and adverse pregnancy outcomes among births affected by velamentous umbilical cord insertion: a retrospective population-based register study. *Eur J Obstet Gynecol Reprod Biol* 2012; 165(2): 231-4.
5. Ebbing C, Kiserud T, Johnsen SL, Albrechtsen S, Rasmussen S. Prevalence, risk factors and outcomes of velamentous and marginal cord insertions: a population-based study of 634741 pregnancies. *PLoS One* 2013; 8(7): e70380.
6. Baumfeld Y, Gutvirtz G, Shoham I, Sheiner E. Fetal heart rate patterns of pregnancies with vasa previa and velamentous cord insertion. *Arch Gynecol Obstet* 2016; 293(2): 361-7.
7. Esakoff TF, Cheng YW, Snowden JM, Tran SH, Shaffer BL, Caughey AB. Velamentous cord insertion: is it associated with adverse perinatal outcomes? *J Matern Fetal Neonatal Med* 2015; 28(4): 409-12.
8. Ruiter L, Kok N, Limpens J, et al. Incidence of and risk factors for vasa praevia: a systematic review. *BJOG* 2016; 123(8): 1278-87.
9. Hasegawa J, Iwasaki S, Matsuoka R, Ichizuka K, Sekizawa A, Okai T. Velamentous cord insertion caused by oblique implantation after in vitro fertilization and embryo transfer. *J Obstet Gynaecol Res* 2011; 37(11): 1698-701.
10. Sepulveda W. Velamentous insertion of the umbilical cord: a first-trimester sonographic screening study. *J Ultrasound Med* 2006; 25(8): 963-8.
11. Nomiyama M, Toyota Y, Kawano H. Antenatal diagnosis of velamentous umbilical cord insertion and vasa previa with color Doppler imaging. *Ultrasound Obstet Gynecol* 1988; 12(6): 426-9.
12. Salomon LJ, Alfirevic Z, Bilardo CM, et al. ISUOG Practice Guidelines: performance of the first-trimester fetal ultrasound scan. *Ultrasound Obstet Gynecol* 2013; 41(1): 102-13.
13. Hasegawa J, Matsuoka R, Ichizuka K, Nakamura M, Sekizawa A, Okai T. Do fetal heart rate deceleration patterns during labor differ between various umbilical cord abnormalities? *J Perinata Med* 2009; 37(3): 276-80.
14. Hasegawa J, Matsuoka R, Ichizuka K, et al. Atypical variable deceleration in the first stage of labor is a characteristic fetal heart-rate pattern for velamentous cord insertion and hypercoiled cord. *J Obstet Gynaecol Res* 2009; 35(1): 35-9.