



CASE REPORT

Surgical treatment of Paget's disease of the vulva using Mohs micrographic surgery, followed by vulvar reconstruction using the "lotus petal" suprafascial flap

Antoni Llueca^{1,2,*}, José Luis Herráiz^{1,2}, Yasmine Maazouzi², Dolores Piquer², Carmen Medina², Ana Pitarch²

¹ Department of Medicine, University Jaume I (UJI), Castellón, Spain

² Multidisciplinary Unit for Abdominal Pelvic Oncology Surgery (MUAPOS), University General Hospital of Castellón, Spain

Abstract: Vulvar Paget's disease is an extramammary manifestation of Paget's disease, a cutaneous neoplasm that clinically appears as sharply defined erythematous plaques with irregular borders that usually affect apocrine gland-bearing skin. Extramammary Paget's disease (EMPD) of the vulva can remain undiagnosed for years and could be associated with multifocal neoplasms. The current gold standard for the treatment of vulvar EMPD is surgical excision and the Mohs micrographic surgery is the preferred technique used in evaluating the margins of the specimen. The reconstruction of the vulva using suprafascial flaps reduces hospitalization time and complications rate.

Keywords: vulvar Paget's disease; Mohs micrographic surgery; lotus petal suprafascial skin flap

Citation: Llueca A, Herráiz JL, Maazouzi Y, Piquer D, Medina C, *et al.* Surgical treatment of Paget's disease of the vulva using Mohs micrographic surgery, followed by vulvar reconstruction using the "Lotus Petal" suprafascial flap. *Adv Mod Oncol Res* 2016; 2(3): 211–214; <http://dx.doi.org/10.18282/amor.v2.i4.111>.

*Correspondence to: Antoni Llueca, Multidisciplinary Unit for Abdominal Pelvic Oncology Surgery (MUAPOS), University General Hospital of Castellón, University Jaume I (UJI), Castellón, Spain; antonillueca@gmail.com

Received: 18th January 2016; **Accepted:** 19th February 2016; **Published Online:** 29th July 2016

Introduction

Vulvar Paget's disease is an extramammary manifestation of Paget's disease, a cutaneous neoplasm that clinically appears as sharply defined erythematous plaques with irregular borders that usually affect apocrine gland-bearing skin. Extramammary Paget's disease (EMPD) of the vulva tends to remain undiagnosed for years as it is typically misdiagnosed as contact dermatitis, seborrheic dermatitis, tinea cruris, inverse psoriasis, or Bowen's disease^[1]. EMPD most commonly affects postmenopausal Caucasian women and accounts for less than 1% of vulvar malignancies. Although rare, it should be considered in the differential diagnosis of any chronic dermatitis of the perineum^[1,2].

While the current gold standard for the treatment of vulvar EMPD is surgical excision, with Mohs micrographic surgery being the preferred technique, recent

scientific publications have proposed the use of imiquimod 5% (applied topically) as an alternative for primary EMPD^[3,4]. However, such case reports typically have limited follow-ups compared to classical surgical resection studies^[5]. This paper reports the case of a 67-year-old woman with primary vulvar Paget's disease, who was subjected to Mohs micrographic surgery, followed by vulvar reconstruction using the "Lotus Petal" suprafascial flap.

Case Report

A 67-year-old woman presenting a bilateral vulvar erythematous lesion with areas of lichenification since 2012 was diagnosed with lichen sclerosus et atrophicus (LSA) and treated with topical corticosteroids. The patient reported fluctuating alleviation over the years but the intense pruritus and vulvar lesion persisted. A superficial biopsy of the vulvar lesion was then performed,

resulting in the diagnosis of extramammary Paget's disease (Figure 1). A subsequent immunohistochemical profile was performed, revealing a positive result for cytokeratin 7 (CK7) and carcinoembryonic antigen (CEA), while negative for S100. There were no pathological findings in either the abdominal and pelvic computed tomography (CT) scan or the mammography. The patient underwent a vulvectomy using the Mohs micrographic surgical technique, performed by an experienced gynecologic surgeon.

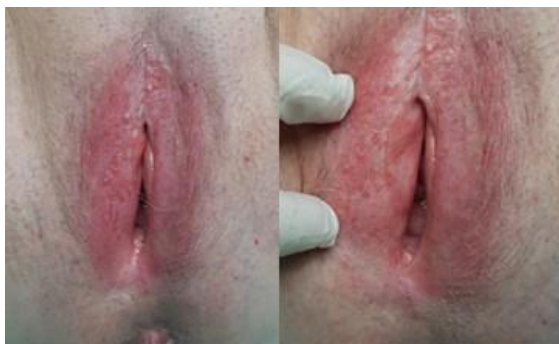

Figure 1. Preoperative image of the lesion

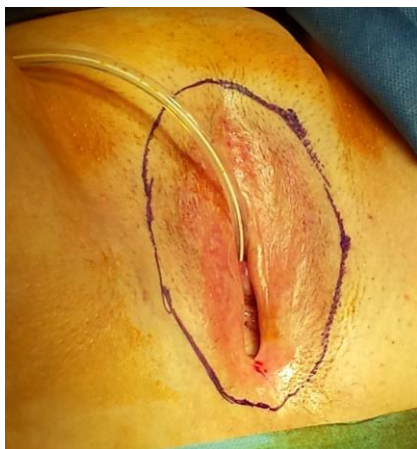

Figure 2. Preoperative marking of the resection margins

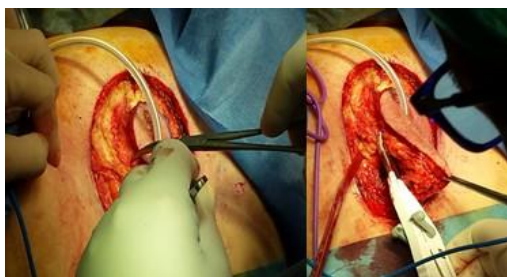


Figure 3. Radical vulvectomy

Description of surgical procedure

The area of the vulva to be excised was first delimited, taking into account surgical margins of 3 cm (Figure 2). The vulvectomy was then performed using a monopolar and bipolar electro-surgical device and the biopsy specimen was sent to pathology for an intraoperative study (Figures 3 and 4). It was concluded that there was an absence of tumor cells in the biopsy specimen. The surgeon then proceeded with designing the suprafascial flap (i.e., in the form of a "lotus petal") as shown in Figure 5 and carried out the vulvoperineal reconstruction. The gluteal-fold flaps were drawn and adapted to the size of the defect (Figure 5). The flap, including the deep fascia, was then raised towards the defect and inserted inside the latter (Figure 6). Finally, the skin closure was completed in two layers. The final result showed no open defects (Figure 7).

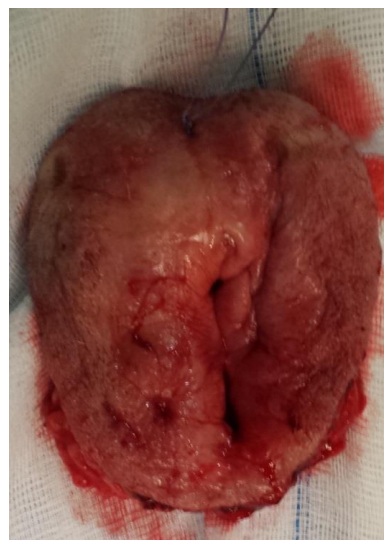

Figure 4. The biopsy specimen was sent intraoperatively to pathology for urgent analysis in order to determine whether or not the margins were affected

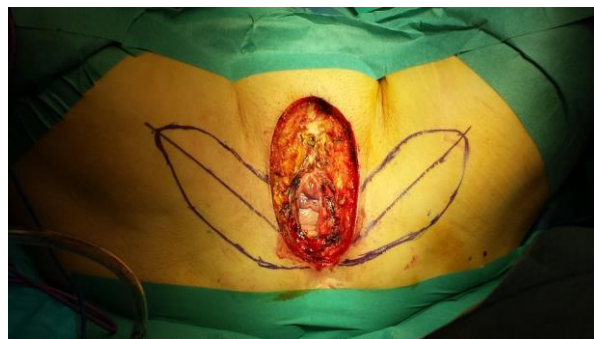

Figure 5. The designing of the suprafascial flap, in the form of a lotus petal

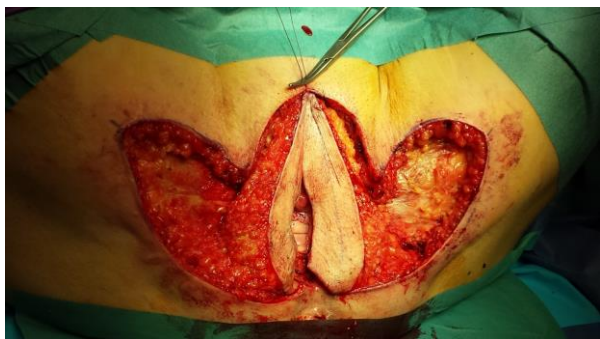

Figure 6. The flaps are fitted inside the defect

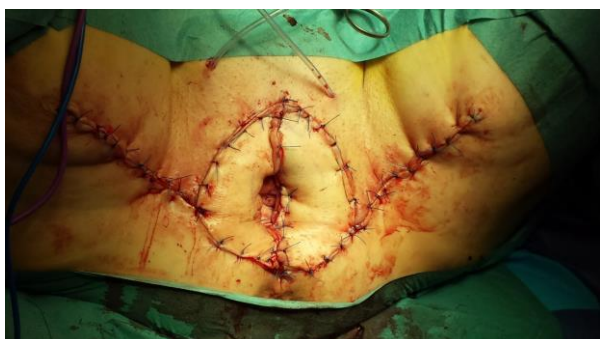

Figure 7. Skin closure performed in two layers

Postoperative follow-up

The patient presented no complications post-surgery and was discharged a week later in order to avoid unnecessary movements that might affect the healing process of the surgical wound. A follow-up session took place three weeks later for a post-operative examination and suture removal. The final pathologic analysis of the biopsy specimen revealed a multifocal vulvar Paget's disease, with surgical margins free of tumor as confirmed during the surgery. The patient returned after six weeks for a post-operative follow-up examination and is currently asymptomatic. The result is shown in [Figure 8](#).

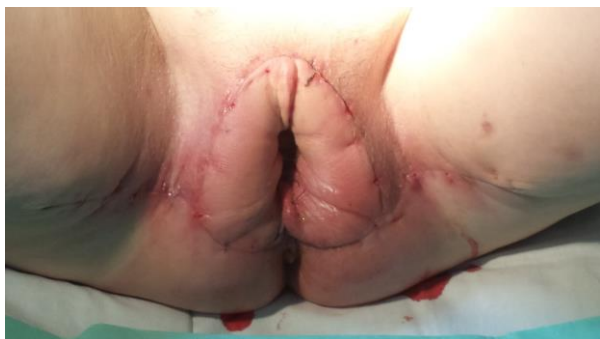

Figure 8. Results three weeks after the surgery

Results

The patient is currently asymptomatic and will return for a clinical evaluation every six months. The follow-up session includes biomarker studies (CEA), as well as an annual abdominal and pelvic CT scans, owing to the high risk of local and/or systemic recurrence of Paget's disease.

Discussion

Paget's disease of the vulva is a rare neoplasm that tends to recur locally. The vulva remains the most frequently affected site, involving as high as 65% of EMPD cases^[6]. Crocker described the first case of EMPD in 1889, in which a lesion affecting the penis and scrotum was identical to the nipples' disease described by Paget in 1874^[7]. Paget's disease of the vulva is sub-classified based on the origin of the altered cells: Type 1 – primary vulvar cutaneous origin; Type 2 – originating from an underlying anal or rectal adenocarcinoma; and Type 3 – originating from bladder adenocarcinoma^[8]. Vulvar EMPD most commonly affects post-menopausal Caucasian women, although there has been a recent report involving a premenopausal woman^[9].

The clinical diagnosis of EMPD is difficult owing to the non-specific characteristics of the disease, with the most common symptom being the manifestation of intense pruritus associated with the appearance of an erythematous plaque with or without lichenification. It is usually multifocal and may appear as normal skin, thus potentially hindering the establishment of resection margins^[10]. A skin biopsy of the lesion is mandatory, especially when the pruritus persists despite medical treatment.

Upon clinical suspicion of EMPD, a full body skin examination as well as a lymph node evaluation should be performed owing to the risk of underlying malignancy that may appear in 12%–33% of cases^[6]. In addition to an abdominal and pelvic CT scan, as well as a skin biopsy, appropriate evaluations which include Papanicolaou smear, breast examination, and analysis of fecal occult blood are required. Further examinations such as colonoscopy and cystoscopy are required if the aforementioned analyses are not satisfactory^[2]. As there were no other pathological outcomes apart from the vulvar lesion, our patient did not undergo the last two procedures.

As for the treatment of vulvar EMPD, surgical excision remains the gold standard, with Mohs micrographic surgery being the preferred technique. It offers the most reliable margin control, adequate tissue preservation, and has the lowest recurrence rates (16%–28%)^[11,12]. However, it is not as highly effective when the disease is clinically asymptomatic and has a skin texture of normal appearance^[2]. With respect to the EMPD prognosis

in general, it is limited by the multifocal nature of EMPD^[8]. Topical treatment using imiquimod 5% has been reported in the past few years with varying results, occasionally yielding remissions in small tumors and in recurrent cases^[3,4,13]. However, there is a need for larger controlled trials to accurately determine the efficacy, as well as the safety of the imiquimod 5% cream^[3,4].

In this report, our team demonstrated the “lotus petal” suprafascial skin flap technique, as described by Ragoowansi *et al.*^[14], which is a simple procedure that can be carried out immediately after a radical vulvectomy. This generally improves the aesthetic results as the scar is hidden in a natural crease, and reduces both the rate of complications and the length of hospital stay^[15].

Author designations

Antoni Lluca, MD, PhD; José Luis Herráiz, MD; Yasmine Maazouzi, MD; Dolores Piquer, MD; Carmen Medina, MD; Ana Pitarch, MD

Conflict of interest

The authors declare no potential conflict of interest with respect to the research, authorship, and/or publication of this article.

References

- Gavriilidis P, Chrysanthopoulos K, Gerasimidou D. Extramammary Paget's disease of the vulva. *BMJ Case Rep* 2013; 2013: bcr2013200623. doi: 10.1136/bcr-2013-200623.
- Lebwohl MG, Heymann WR, Berth-Jones J, Coulson I. *Treatment of skin disease*. 4th ed. Churchill Livingstone, London: Saunders; 2013.
- Anton C, Luiz AVC, Carvalho FM, Baracat EC, Carvalho JP. Clinical treatment of vulvar Paget's disease: A case report. *Clinics* 2011; 66(6): 1109–1111. doi: 10.1590/S1807-59322011000600033.
- Feldmeyer L, Kerl K, Kamarashev J, De Viragh P, French L. Treatment of vulvar Paget disease with topical imiquimod: A case report and review of the literature. *J Dermatol Case Rep* 2011; 5(3): 42–46. doi: 10.3315/jdcr.2011.1073.
- O'Connor WJ, Lim KK, Zalla MJ, Gagnot M, Otley CC, *et al.* Comparison of Mohs micrographic surgery and wide excision for extramammary Paget's disease. *Dermatol Surg* 2003; 29(7): 723–727. doi: 10.1046/j.1524-4725.2003.29184.x.
- Chanda JJ. Extramammary Paget's disease: Prognosis and relationship to internal malignancy. *J Am Acad Dermatol* 1985; 13(6): 1009–1014. doi: 10.1016/S0190-9622(85)70254-X.
- Crocker HR. Paget's disease affecting the scrotum and penis. *Trans Pathol Soc London* 1889; 40: p. 187–191.
- Amorim AG, Mendes BBF, Ferreira RN, Filho AC. Paget disease of the vulva: Diagnosis by immunohistochemistry. *Case Rep Dermatol Med* 2015; 2015: 1–5. doi: 10.1155/2015/162483.
- Asmouki H, Oumouloud R, Aboufalah A, Soummani A, Marrat A. Paget's disease of the vulva in premenopausal woman treated with only surgery: A case report. *Case Rep Oncol Med* 2012; 2012: 1–4. doi: 10.1155/2012/854827.
- Lopes Filho LL, Lopes IMRS, Lopes LRS, Enokihara MMSS, Michalany AO, *et al.* Mammary and extramammary Paget's disease. *An Bras Dermatol* 2015; 90(2): 225–231. doi: 10.1590/abd1806-4841.20153189.
- Boehringer A, Leiter U, Metzler G, Moehrle M, Garbe C, *et al.* Extramammary Paget's disease: Extended subclinical growth detected using three-dimensional histology in routine paraffin procedure and course of the disease. *Dermatol Surg* 2011; 37(10): 1417–1426. doi: 10.1111/j.1524-4725.2011.02091.x.
- Hendi A, Brodland D, Zitelli J. Extramammary Paget's disease: Surgical treatment with Mohs micrographic surgery. *J Am Acad Dermatol* 2004; 51(5): 767–773. doi: 10.1016/j.jaad.2004.07.004.
- Jim On SC, Izumi AK. Extramammary Paget disease: Failure to respond to topical imiquimod 5%. *J Am Acad Dermatol* 2011; 65(3): 656–657. doi: 10.1016/j.jaad.2010.04.035.
- Ragoowansi R, Yü N, Niranjana NS. Immediate vulvar and vaginal reconstruction using the gluteal-fold flap: Long-term results. *Br J Plast Surg* 2004; 57(5): 406–410. doi: 10.1016/j.bjps.2004.02.022.
- Herráiz Roda JL, Lluca Abella JA, Maazouzi Y, Bouché Babiloni A, Cañete Mota A, *et al.* Vulvar reconstruction in vulvar cancer: “Lotus petal” suprafascial flap. *Gynecol Surg* 2015; 13: 51–55. doi: 10.1007/s10397-015-0911-7.