

2014

Toad (Anura: Bufonidae) Limb Abnormalities from an Aquatic Site in Scott, Pulaski County, Arkansas

C. S. Thigpen


Arkansas State University, christopher.thigpen@smail.astate.edu

D. Beard

S. E. Trauth

Arkansas State University

Follow this and additional works at: <http://scholarworks.uark.edu/jaas>

 Part of the [Animal Studies Commons](#), and the [Terrestrial and Aquatic Ecology Commons](#)

Recommended Citation

Thigpen, C. S.; Beard, D.; and Trauth, S. E. (2014) "Toad (Anura: Bufonidae) Limb Abnormalities from an Aquatic Site in Scott, Pulaski County, Arkansas," *Journal of the Arkansas Academy of Science*: Vol. 68 , Article 18.

Available at: <http://scholarworks.uark.edu/jaas/vol68/iss1/18>

This article is available for use under the Creative Commons license: Attribution-NoDerivatives 4.0 International (CC BY-ND 4.0). Users are able to read, download, copy, print, distribute, search, link to the full texts of these articles, or use them for any other lawful purpose, without asking prior permission from the publisher or the author.

This Article is brought to you for free and open access by ScholarWorks@UARK. It has been accepted for inclusion in Journal of the Arkansas Academy of Science by an authorized editor of ScholarWorks@UARK. For more information, please contact scholar@uark.edu, ccmiddle@uark.edu.

Toad (Anura: Bufonidae) Limb Abnormalities from an Aquatic Site in Scott, Pulaski County, Arkansas

C.S. Thigpen^{1*}, D. Beard² and S.E. Trauth¹

¹Department of Biological Sciences, Arkansas State University, State University, AR 72467-0599

²12306 Willow Lane, Scott, AR 72142

Correspondence: christopher.thigpen@smail.astate.edu

Running Title: Toad (Anura: Bufonidae) Limb Abnormalities from an Aquatic Site in Scott, Pulaski County, Arkansas

Abstract

We collected and examined 16 Fowler's toads, *Anaxyrus fowleri*, and one dwarf American toad, *Anaxyrus americanus charlesmithi*, in central Arkansas in 2011. Collection was initiated by observation of abnormal toads. Toads were euthanized, measured, photographed, and deposited in the Arkansas State University herpetological collection. Several toads were radiographed. We found various abnormalities in both forelimbs and hindlimbs and on both sides of the body. The causes of the abnormalities remain unknown and will require further studies to determine if the environment is imperiled.

Introduction

Studies on amphibian limb abnormalities have recently become common in the field of amphibian conservation. These abnormalities can vary from limb malformations to complete limb absence. Many stressors can cause similar responses and a singular cause that links the array of abnormalities is not known. Instead the several known causes of these abnormalities appear to have variable effects.

Although research has led to a better understanding of the abnormalities, there is a lack of knowledge of the causes and implications of the deformities (Blaustein and Johnson 2003). Lannoo (2008) believes many sources, both natural and artificial, ranging from fish excrement to overcrowding, are significant when pinpointing causes of the abnormalities.

Herein, we present an observational investigation of abnormalities in Fowler's toads (*Anaxyrus fowleri*) and dwarf American toads (*Anaxyrus americanus charlesmithi*) from a site in south central Arkansas. This is intended to describe the abnormalities and allow for future studies to determine potential causes.

Materials and Methods

Seventeen toads of varying sizes were collected by hand in Scott, Arkansas (Pulaski County) (34°38'03.19"N, 92°07'58.95"W) and sent to Arkansas State University for processing. The random collection was opportunistic and non-exhaustive. The site (Fig. 1) was around an in ground swimming pool in a residential neighborhood, bordered by several lakes with forest areas and many agricultural plots. The site was not chosen, and the collection was initiated by the property owner (D. Beard) when abnormal toads were observed. The toads were euthanized in a dilute chlorobutanol solution. Fixation was done in a 10% v/v neutral buffered formalin solution. All toads were then photographed, given museum tags, and placed in 70% v/v ethanol.

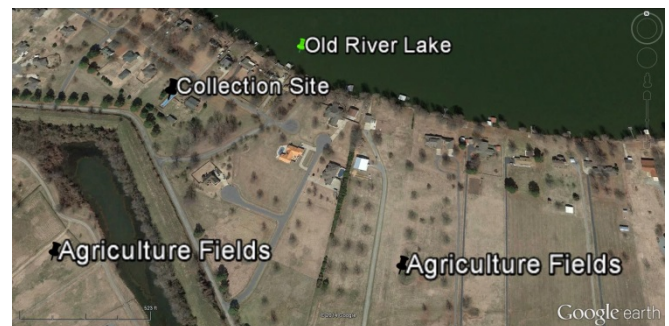

Figure 1. Map of collection site near Scott (Pulaski Co., Arkansas).

Results

Thirteen toads of the 17 collected exhibited some abnormality. Most (92.3%) abnormalities affected the limbs. A list of common abnormalities of the limbs adapted from Lannoo (2008) was used as a basis for identification of the abnormalities (Table 1). Limb abnormalities varied among the toads and were found

Toad (Anura: Bufonidae) Limb Abnormalities from an Aquatic Site in Scott, Pulaski County, Arkansas

in both adult and sub adult toads (maximum SVL was 75 mm; minimum SVL was 27 mm).

Table 1. Common amphibian limb abnormalities from Lannoo (2008).

Abnormality	Description
Amelia	Missing limb
Ectromelia	Missing limb segments
Polydactyly	Extra digits
Ectrodactyly	Complete absence of digit including metatarsal bone
Skin Webbing	Band of skin crossing a joint

Table 2 documents all abnormalities observed and gives a short description of location and affected area.

One of the 5 toads that did not exhibit any limb abnormalities did appear to have a slightly above average curvature of the sacral hump (seen in Fig. 1a), but it was not radiographed or considered suspicious. The other 4 toads that were collected did not exhibit any noteworthy malformation or abnormality and are not presented in any of the following tables or figures.

Photographs of toads can be seen in Figure 2. Figure 3 shows radiographs and photographs of some of the abnormal toads.

Discussion

The abnormalities presented do not have a known cause as of yet. We can speculate, however, to the causes of some of the abnormalities.

The trematode parasite *Ribeiroia ondatrae* is frequently associated with limb abnormalities in anurans, but usually affects the hind limbs. Johnson et al. (2001) found that infections of *R. ondatrae* in *Bufo (Anaxyrus) boreas* tadpoles induced severe limb malformations ranging from supernumerary limbs to complete limb absence. In 2002, Johnson et al. linked *R. ondatrae* infection to amphibian malformations in the western United States. In 9 species of amphibians from 4 states, they found that the parasite caused both forelimb and hind limb malformations of varying degrees. Although many believe the parasite is the culprit behind most abnormalities, others disagree.

In a study of wood frogs, Eaton et al. (2004) found abnormalities associated with *R. ondatrae*, but found

no evidence, i.e. cysts, linking the parasite with the abnormalities and instead suggested that sublethal predation was a primary cause for the abnormalities. Because limbs develop outside the body, abnormalities in hind limbs of anurans ranging from missing digits to missing limbs may be linked to sublethal predation (Ballengée and Sessions 2009, Bowerman et al. 2010). Ballengée and Sessions (2009) attribute the abnormalities to dragonfly nymphs and Bowerman et al. (2010) attribute abnormalities to sticklebacks. Others believe pollution is to blame.

Table 2. Observed abnormality and description

Abnormality	Description
Superimposition	Third toe on left foot perpendicular to 2nd toe
Ectromelia	Right forelimb and hindlimb missing distal elements
Oligodactyly	Left hand missing 4th toe and distal portion of 3rd toe
Oligodactyly and skin webbing	Right foot missing 3 medial toes and two lateral toes fused
Ectromelia	Elements below proximal half of right radioulna absent
Adactyly	All toes on right foot absent
Ectrodactyly	All metatarsals and phalanges on left hand absent
Skin webbing	Medial toes on right hand fused
Skin webbing and oligodactyly	Second, third, and fourth toe fused on right hand and 2nd and 3rd toe missing distal phalanges
Amelia	Entire right forelimb missing
Bilateral Ectromelia	Distal portions of both forelimbs missing
Bilateral Ectromelia	Elements distal to proximal portion of humeri missing
Kyphosis	Above average convex curvature of the sacral hump

Pesticides, herbicides and other chemical compounds used for agriculture have been suggested as the direct or indirect cause of some amphibian malformations (Ouellet et al. 1997, McCallum 1999, Taylor et al. 2005). Reeves et al. (2008) found that skeletal abnormalities increased with proximity to roads in wood frogs in Alaska and suggested that multiple factors from vehicles, pollution, and predator community shifts may cause the increase in abnormalities. Reeves et al. (2010) discussed multiple stressors that may increase likelihood of abnormalities such as radiation, pollution, and predation. The cutaneous fusion observed in some of the toads may be linked to the trematode parasite *Ribeiroia* that has been found by Johnson et al. (2001) to cause skin webbing in western toads. Missing digits and kyphosis could be caused by injury from sublethal predation. Other abnormalities such as partial limbs or ectromelia of the hind limbs may also be caused by sublethal predation. Ouellet et al. (1997) and Lannoo (2008) believe hindlimb deformities can be attributed to agricultural chemicals such as pesticides and fertilizers.




Figure 2. Toads in A with abnormal curvature of sacral hump (a) and ectrodactyly of right hand (b). Toads in B with superimposed toe (a), ectromelia of right forelimb (b) and right hindlimb (c), and oligodactyly (d)

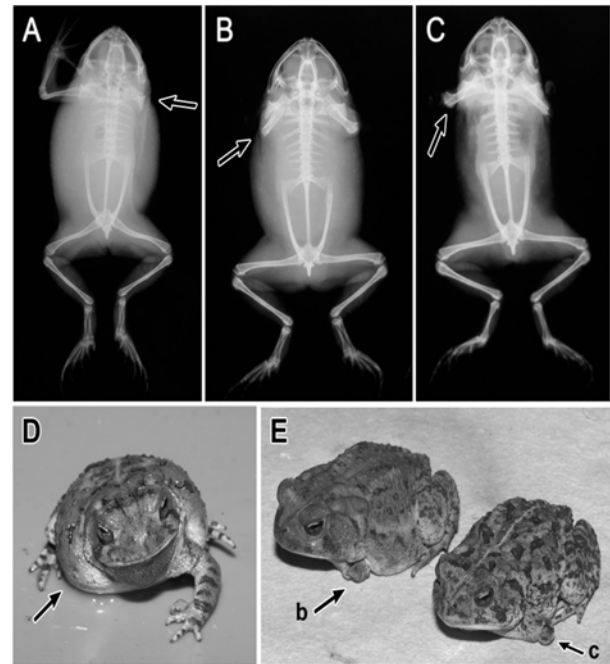


Figure 3. Radiographs showing amelia (A), and bilateral ectromelia (B and C). Photographs D and E are the corresponding toads for radiographs A,B, and C. Missing and partial limbs shown in photographs D and E (b and c).

Acknowledgments

Authorization of toad collection was granted by a collecting permit from the Arkansas Game and Fish Commission. We would like to thank Mike Lannoo for his contribution in determination of abnormalities and production of radiographs. This study was conducted under established protocols set by the IACUC at Arkansas State University. All specimens were deposited into the Arkansas State University Herpetological Collection and are labeled using museum coding numbers (31724, 31725, 31782-31786, 31794, 31800-31808).

Literature Cited

- Ballenguee B and SK Sessions.** 2009. Explanation for missing limbs in deformed amphibians. *Journal of Experimental Zoology (Molecular and Developmental Evolution)* 312B:1-10.
- Blaustein AR and PTJ Johnson.** 2003. The complexity of deformed amphibians. *Frontiers in Ecology and the Environment* 1:87-94.

Toad (Anura: Bufonidae) Limb Abnormalities from an Aquatic Site in Scott, Pulaski County, Arkansas

- Bowerman J, PTJ Johnson and T Bowerman.** 2010. Sublethal predators and their injured prey: linking aquatic predators and severe limb abnormalities in amphibians. *Ecology* 91:242-251.
- Eaton BR, S Eaves, C Stevens, A Puchniak and CA Paszkowski.** 2004. Deformity levels in wild populations of the wood frog (*Rana sylvatica*) in three ecoregions of western Canada. *Journal of Herpetology* 38:283-287.
- Johnson PTJ, KB Lunde, RW Haight, J Bowerman and AR Blaustein.** 2001. *Ribeiroia ondatrae* (Trematoda: Digenea) infection induces severe limb malformations in western toads (*Bufo boreas*). *Canadian Journal of Zoology* 79:370-379.
- Johnson PTJ, KB Lunde, EM Thurman, EG Ritchie, SN Wray, DR Sutherland, JM Kapfer, et al.** 2002. Parasite (*Ribeiroia ondatrae*) infection linked to amphibian malformations in the western United States. *Ecological Monographs* 72:151-168.
- Lannoo M.** 2008. Malformed frogs the collapse of aquatic ecosystems. 1st ed. University of California Press, Berkeley. 270 p.
- McCallum ML.** 1999. *Rana sphenoccephala* (southern leopard frog) malformities found in Illinois with behavioral notes. *Transactions of the Illinois State Academy of Science* 92:257-264.
- Ouellet M, J Bonin, J Rodrigue, JL DesGranges and S Lair.** 1997. Hindlimb deformities (ectromelia, ectrodactyly) in free-living anurans from agricultural habitats. *Journal of Wildlife Diseases* 33:95-104.
- Reeves MK, CL Dolph, H Zimmer, RS Tjeerdema and KA Trust.** 2008. Road proximity increases risk of skeletal abnormalities in wood frogs from national wildlife refuges in Alaska. *Environmental Health Perspectives* 116:1009-1014.
- Reeves MK, P Jensen, CL Dolph, M Holyoak and KA Trust.** 2010. Multiple stressors and the cause of amphibian abnormalities. *Ecological Monographs* 80:423-440.
- Taylor B, D Skelly, LK Demarchis, MD Slade, D Galusha and PM Rabinowitz.** 2005. Proximity to pollution sources and risk of amphibian limb malformation. *Environmental Health Perspectives* 113:1497-1501.