

An unusual location of gouty panniculitis

A case report

David Martin, MD^{a,*}, Gaëtan-Romain Joliat, MD^a, Pierre Fournier, MD^a, Christophe Brunel, MD^b, Nicolas Demartines, MD^{a,*}, Olivier Gié, MD^a

Abstract

Rationale: Gouty panniculitis, characterised by the deposition of monosodium urate crystals in subcutaneous tissue, is a rare clinical manifestation of gout.

Patient concerns: The case of a 67-year-old man is reported, who presented an erythematous nodule on the upper part of the right buttock suspicious for an abscess. This was in the context of chemotherapy for non-Hodgkin's lymphoma.

Diagnoses: Histopathologic examination demonstrated gouty panniculitis.

Interventions: Because infection was suspected, an incision was performed. The lesion was found to be densely calcified and friable, without purulent discharge. Therefore, a surgical en-bloc resection was performed.

Outcomes: The wound healed slowly initially due to a combination of malnutrition, chemotherapy and infection. A wound infection with *Enterococcus faecium* was treated with antibiotic therapy (carbapenem for seven days) and local therapy. At 6-week follow up the wound showed good granulation tissue and was healing well by secondary intention. The patient was instructed to continue anti-hyperuricaemic treatment.

Lessons subsections: In patients known to have long-standing hyperuricaemia and gout with nonspecific subcutaneous erythematous nodules, gouty panniculitis should be considered.

Abbreviation: MSU = monosodium urate.

Keywords: gouty tophi, monosodium urate crystals, panniculitis, surgery

1. Introduction

Gout is an inflammatory arthritis caused by the deposits of monosodium urate (MSU) crystals in the synovial fluid, and associated with hyperuricaemia. First described by the Egyptians in 2640 BC, gout has afflicted mankind for centuries.^[1] McCarty and Lee Hollander demonstrated the presence of MSU crystals in the synovial fluid of gouty patients in 1961.^[1,2] The prevalence of gout is reported to be approximately 1%, and is rising in the western world due to dietary factors.^[3] The incidence increases with age and is higher among men (ratio 4:1).^[1] The definitive diagnosis of gout is best established by demonstration of MSU crystals in synovial fluid or biopsy.^[4] The tophus is the cardinal feature of advanced gout. Microscopically, tophi are chronic granuloma-like structures containing collections of MSU crystals surrounded by inflammatory cells and connective tissue.^[4,5]

Tophi usually are found in the periarticular tissues, including tendons and ligaments, and particularly around the olecranon process, knee joint, forearm, Achilles tendon, and helix of the ear.^[6] These lesions typically first form in cooler parts of the body, due to the physicochemical properties of sodium urate but many unusual localizations have been described, like head and neck, skin, viscera, bones, nerves, and axial skeleton.^[7,8]

The current report presents a case of buttock gouty panniculitis, which is an unusual clinical manifestation of gout.

2. Case report

A 67-year-old man underwent chemotherapy for non-Hodgkin lymphoma (diffuse large B-cell lymphoma). During his inpatient stay for chemotherapy, the patient developed painful tumor on the upper part of the right buttock. On physical examination, an erythematous 3-cm mobile nodule was palpable in the subcutaneous plane containing 2 yellow-white circular structures (Fig. 1). Differential diagnosis included abscess, infected sebaceous or epidermal cyst, and calcinosis cutis. Because infection was suspected, an incision was performed under local anesthesia (Fig. 2). The lesion was found to be densely calcified and friable, without purulent discharge. Therefore, a surgical en-bloc resection was performed in the operating room and fixed in formaldehyde. Neither bacteriological nor mycological analysis was undertaken. Histopathology revealed a gouty tophus with the presence of dystrophic calcification and amorphous nodular eosinophilic deposits surrounded by granulomatous inflammation and a fibrous pseudo-capsule (Fig. 3). These findings were confined to the deep dermis and subcutaneous tissue, which was consistent with the diagnosis of gouty panniculitis. The patient was known to suffer from gout for several years, and was on

Editor: Dan Lipsker.

The authors have no conflicts of interest to disclose.

^a Department of Visceral Surgery, ^b Institute of Pathology, University Hospital CHUV, Lausanne, Switzerland.

* Correspondence: Nicolas Demartines, Department of Visceral Surgery, University Hospital CHUV, 1011 Lausanne, Switzerland (e-mail: demartines@chuv.ch).

Copyright © 2017 the Author(s). Published by Wolters Kluwer Health, Inc. This is an open access article distributed under the Creative Commons Attribution-NoDerivatives License 4.0, which allows for redistribution, commercial and non-commercial, as long as it is passed along unchanged and in whole, with credit to the author.

Medicine (2017) 96:16(e6733)

Received: 12 November 2016 / Received in final form: 3 April 2017 / Accepted: 6 April 2017

<http://dx.doi.org/10.1097/MD.0000000000006733>

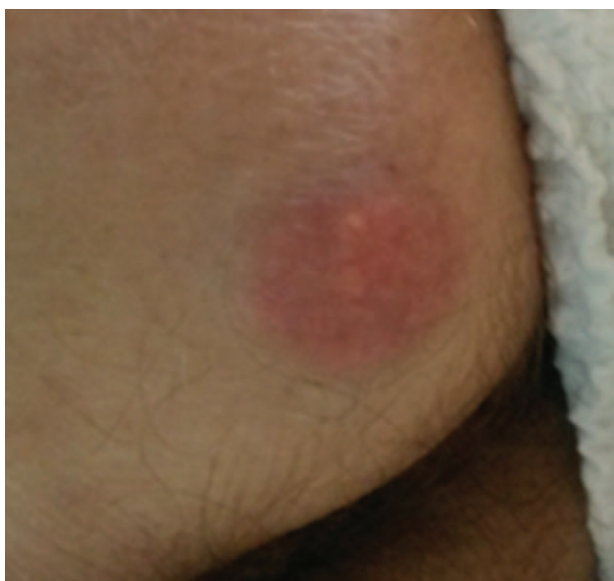

Figure 1. Painful erythematous 3-cm nodule on the right buttock containing 2 yellow-white circular structures.

allopurinol treatment (300mg daily), with normal serum uric acid level (230 μmol/L, normal range 202–416 μmol/L). A postoperative CT scan after the last chemotherapy cycle showed the presence of calcium deposits (same density as the femoral bone) in a similar gouty tophus on the opposite buttock without signs of infection (Fig. 4). The wound healed slowly initially due to a combination of malnutrition, chemotherapy, and infection. A wound infection with *Enterococcus faecium* was treated with antibiotic therapy (carbapenem for 7 days) and local therapy. At 6-week follow-up the wound showed good granulation tissue and was healing well by secondary intention. The patient was instructed to continue anti-hyperuricaemic treatment.

The Regional Committee for Medical and Health Research Ethics did not require ethical approval for reporting individual cases. Written informed consent was obtained from the patient

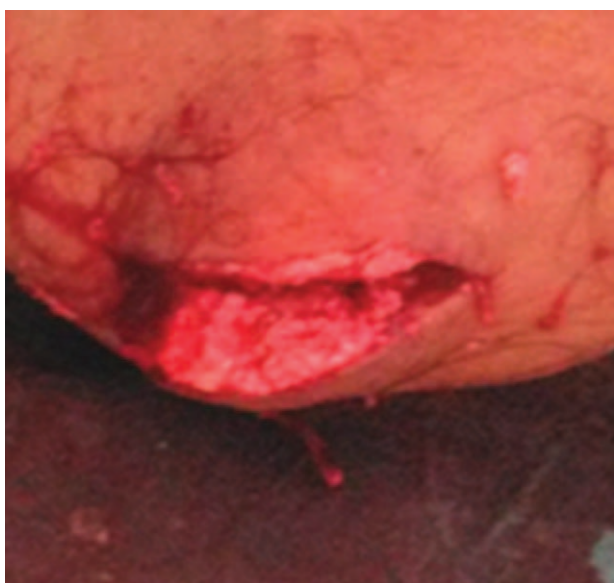

Figure 2. After incision: densely calcified and friable nodule.

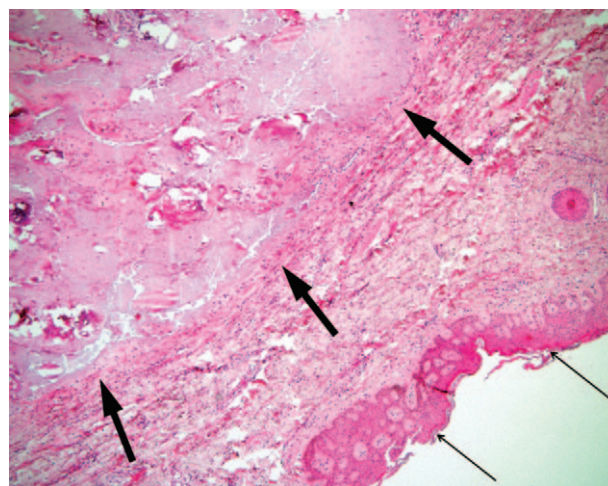


Figure 3. (Magnification ×40): orthokeratotic hyperkeratosis of the epidermis (thin arrows). The deep dermis shows amorphous and acellular deposits containing dystrophic microcalcifications surrounded by a paucicellular fibrous capsule (thick arrows).

for the publication of this case report and its accompanying images.

3. Discussion

Gouty panniculitis belongs to differential diagnosis in gout patients with subcutaneous tissue lesions of any location. It represents an unusual clinical manifestation of gout, characterized by the deposition of MSU crystals in the lobular hypodermis.^[9,10] It is an extremely rare presentation, and to date, less than 10 cases are reported in the literature.^[11] The pathophysiology is presently poorly understood. Ochoa et al^[10] suggested that localized inflammatory changes in the lobular subcutaneous tissue may be triggered and perpetuated by disruption of the arterial blood supply by MSU crystals and microtrauma of the terminal capillary wall and adipose tissue, thus rendering tissue vulnerable to deposits. Serum uric acid levels seem not to be directly related to the development of gouty panniculitis, especially in diabetics or alcoholics.^[12] On physical examination, patients present with erythematous, irregular, and deep indurated subcutaneous nodules, causing pain or tenderness. These clinical findings may precede or appear subsequently to articular tophaceous gout.^[1] The differential diagnosis includes a wide spectrum of clinical disorders like cellulitis, cutaneous abscess, systemic lupus erythematosus, dermatomyo-

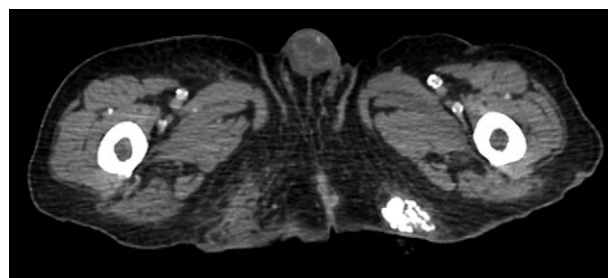

Figure 4. CT scan showing the presence of calcium deposits on the left buttock (same density as the femoral bone). CT = computed tomography.

sitis, calcinosis cutis, rheumatoid arthritis, and malignancies such as lymphomas or leukaemias localized in the lobular subcutaneous tissue.^[13,14] Appropriate exploration of a panniculitis should include bacteriological and mycological cultures to rule out any underlying infection, especially in the context of recent chemotherapy. This was unfortunately not performed in this case as this diagnosis was not suspected intraoperatively. Some fungic infections have been reported to mimic gouty panniculitis.^[15]

Histologically, panniculitis is characterized by adipocyte necrosis, inflammatory infiltrate with polymorphonuclear leukocytes, and the presence of eosinophilic amorphous material in the subcutaneous tissue.^[11] The ideal fixative for preservation of gout crystals in the dermis or subcutaneous tissues is alcohol because the crystals are dissolved in formalin.^[14] However, most histological specimens are fixed in formalin, especially when the diagnosis of gout is not suspected, resulting in dissolution of urate crystals leaving behind a nonspecific pale amorphous area, as in the present case. It should also be noted that the presence of dystrophic calcium deposits in tophi or gouty panniculitis is not typical, but may be observed in older lesions.^[16]

Imaging tools (conventional x-ray, ultrasound, computed tomography, and magnetic resonance imaging) can aid in establishing the correct diagnosis, when histology is unable to do so, and also permit assessing the burden of inflammatory and structural disease.^[17] In this case, a CT scan was performed in the context of oncological monitoring and showed the presence of calcium deposits (same density as the femoral bone) in a similar gouty tophus on the opposite buttock. In fact, a dystrophic calcinosis cutis would have the same radiological aspect, and the CT scan would not have been able to make the diagnosis if the contralateral lesion had not been resected.

There is no specific therapy for gouty panniculitis. However, antihyperuricaemic therapies may have a role, in addition to low-dose steroids to control pain and inflammation.^[10,11] Surgical resection is an option in cases refractory to medical treatment or where the diagnosis is in doubt.^[1]

4. Conclusion

Subcutaneous tissues may be affected by inflammatory processes due to hyperuricaemia and gout. Gouty panniculitis should be

considered in patients known to have long-standing hyperuricaemia and gout with nonspecific subcutaneous erythematous nodules. Medical treatment is the treatment of choice, but patients may also be successfully treated with surgery in refractory or uncertain cases.

References

- [1] Gaviria JL, Ortega VG, Gaona J, et al. Unusual dermatological manifestations of gout: review of literature and a case report. *Plast Reconstr Surg Glob Open* 2015;3:e445.
- [2] Marson P, Pasero G. Some historical remarks on microcrystalline arthritis (gout and chondrocalcinosis). *Reumatismo* 2011;63:199–206.
- [3] Luk AJ, Simkin PA. Epidemiology of hyperuricemia and gout. *Am J Manag Care* 2005;11(15 suppl):S435–442.
- [4] Purohit MB, Purohit TM, Tandon RK. FNAC of gouty tophi—a case report. *Indian J Pathol Microbiol* 2006;49:42–3.
- [5] Chhana A, Dalbeth N. The gouty tophus: a review. *Curr Rheumatol Rep* 2015;17:19.
- [6] Gupta A, Rai S, Sinha R, et al. Tophi as an initial manifestation of gout. *J Cytol* 2009;26:165–6.
- [7] Forbess LJ, Fields TR. The broad spectrum of urate crystal deposition: unusual presentations of gouty tophi. *Semin Arthritis Rheum* 2012;42:146–54.
- [8] McCarty DJ. Gout without hyperuricemia. *JAMA* 1994;271:302–3.
- [9] Snider AA, Barsky S. Gouty panniculitis: a case report and review of the literature. *Cutis* 2005;76:54–6.
- [10] Ochoa CD, Valderrama V, Mejia J, et al. Panniculitis: another clinical expression of gout. *Rheumatol Int* 2011;31:831–5.
- [11] Weberschock T, Gholam P, Hartschuh W, et al. Gouty panniculitis in a 68-year-old man: case report and review of the literature. *Int J Dermatol* 2010;49:410–3.
- [12] Rege J, Shet T, Naik L. Fine needle aspiration of tophi for crystal identification in problematic cases of gout. A report of two cases. *Acta Cytol* 2000;44:433–6.
- [13] Requena L, Sanchez Yus E. Panniculitis Part II. Mostly lobular panniculitis. *J Am Acad Dermatol* 2001;45:325–61.
- [14] Weaver J, Somani N, Bauer TW, et al. Simple non-staining method to demonstrate urate crystals in formalin-fixed, paraffin-embedded skin biopsies. *J Cutan Pathol* 2009;36:560–4.
- [15] Colmenero I, Alonso-Sanz M, Casco F, et al. Cutaneous aspergillosis mimicking pancreatic and gouty panniculitis. *J Am Acad Dermatol* 2012;67:789–91.
- [16] Dalinka MK, Melchior EL. Soft tissue calcifications in systemic disease. *Bull N Y Acad Med* 1980;56:539–63.
- [17] Chowalloor PV, Siew TK, Keen HI. Imaging in gout: a review of the recent developments. *Ther Adv Musculoskelet Dis* 2014;6:131–43.