

Contemporary outbreaks of different avipoxviruses in Humboldt penguins of wild animal park Planckendael and in chickens of commercial poultry farms in Belgium

Gelijktijdige uitbraken van verschillende avipoxvirussen bij humboldtpinguïns in dierenpark Planckendael en bij kippen van commerciële pluimveebedrijven in België

¹V.R.A.P. Reddy, ²F. Vercammen, ¹I. Trus, ¹H.J. Nauwynck

¹Department of Virology, Parasitology and Immunology, Laboratory of Virology, Faculty of Veterinary Medicine, Ghent University, Salisburylaan 133, B-9820 Merelbeke, Belgium

²Centre for Research and Conservation-Royal Zoological Society of Antwerp, Koningin Astridplein 26, B-2018 Antwerp, Belgium

Reddy.Vishwanatha@ugent.be

ABSTRACT

In the present study, the first outbreak of a penguinpox virus (PPV) in Humboldt penguins (*Spheniscus humboldti*) and four outbreaks of fowlpox virus (FPV) in layer chickens are reported. Clinically, cutaneous wart-like growths were observed around the eyes in four juvenile Humboldt penguins and cutaneous nodular lesions in the comb, wattles, around the eyes and other unfeathered skin parts of layer chickens. Histopathology (FPV and PPV), electron microscopy (PPV), virus isolation (FPV) and PCR amplification (FPV and PPV) confirmed that both isolates were avipoxviruses (APVs). According to the phylogenetic analysis of the partial P4b core protein gene, the Belgian Humboldt PPV clustered with sequences of free-range (domestic and synanthrope bird species) and wild bird species of the United States and Europe (99 - 100% homology), and all four Belgian FPV isolates clustered with FPV isolates of chickens, turkeys, canary and FPV attenuated live vaccines from all over the world (100% homology).

SAMENVATTING

In de huidige studie worden de eerste uitbraak van een pinguïnpokkenvirus (PPV) bij humboldtpinguïns (*Spheniscus humboldti*) en een aantal uitbraken van pluimveepokkenvirus (FPV) bij legkippen beschreven. Huidgezwollen zoals wratten werden waargenomen ter hoogte van de ogen bij vier jonge humboldtpinguïns en cutane nodulaire laesies op de kam, lellen en op onbevederde huid alsook rond de ogen van legkippen. Histopathologie (FPV en PPV), elektronenmicroscopie (PPV), virusisolatie (FPV) en PCR-amplificatie (FPV en PPV) bevestigden dat beide isolaten behoren tot het genus avipoxvirus (APV). Volgens de fylogenetische analyse van het P4b-kerneiwitgen kunnen enerzijds de Belgische humboldt PPV's gegroepeerd worden met sequenties van vrije uitloop en wilde vogelsoorten van de Verenigde Staten en Europa (99-100% homologie) en anderzijds alle Belgische FPV-isolaten geclusterd worden met FPV-isolaten van kippen, kalkoenen, kanaries (scharrel- en wilde dieren) en verzwakte levende vaccins uit de hele wereld (100% homologie).

INTRODUCTION

Poxviruses in birds are classified within the family *Poxviridae*, subfamily *Chordopoxvirinae* and genus *Avipoxvirus* (APV) (<http://www.ictvonline.org>). APVs are the largest and most complex viruses known. Like other poxviruses, APVs are oval to brick-shaped enveloped viruses, which measure about 270 × 350 nm. APVs contain a linear double stranded DNA with

260,000 to 375,000 nucleotides, which encode more than 250 proteins (Gubser et al., 2004; Jarmin et al., 2006). APVs are known to infect at least 278 of the approximately 9,800 bird species. However, it is believed that all avian species are susceptible (Kane et al., 2012; Karstad, 1971; Van Riper and Forrester, 2007). At present, ten species are officially accepted under the genus *Avipoxvirus* (<http://www.ictvonline.org>), but most probably, many more unnamed APV

Table 1. Avian poxvirus outbreaks in Belgium during the period 2012 -2014: description and virus detection.

Identification	Date	Affected animals	Vaccination history	Gross lesions on CAMs		PCR		
				Pock lesions	Thickening	Material for DNA extraction	Result	GenBank accession number
14PL151	04/09/2014	Humboldt penguin	Not vaccinated	–	Not observed	Tissue lesions	+	KT343756
12PL020	11/01/2012	Chicken	Not vaccinated	+	Severe	Tissue lesions	+	KT343757*
12PL386	22/11/2012	Chicken	Vaccinated	+	Severe	Tissue lesions	+	KT343757*
12PL401	13/12/2012	Chicken	Not vaccinated	+	Severe	Tissue lesions	+	KT343757*
13PL034	07/02/2013	Chicken	Not vaccinated	+	Severe	Tissue lesions	+	KT343757*

*The nucleotide sequences of all FPV isolates were identical, hence a single nucleotide sequence was submitted (KT343757) to GenBank.

species or strains exist, as new isolates are continuously discovered from a wide variety of avian species (Boyle, 2007; Gyuranecz et al., 2013).

APVs are highly contagious and are transmitted via arthropod vectors or by direct contact with infectious particles or birds (Kane et al., 2012). Information on the pathogenesis of APV infections is usually derived from the prototype fowlpox virus (FPV), which infects chickens and turkeys. The FPV is a slowly spreading virus, which may lead to proliferative lesions that result in the formation of wart-like projections on the unfeathered parts of the body (cutaneous form) or fibrino-necrotic and proliferative lesions in the mucous membrane of the upper respiratory and digestive tracts (diphtheritic form) (Tripathy and Reed, 2003). The mortality rate is higher in the diphtheritic form than in the cutaneous form, and can reach up to 50% in young birds (Tripathy and Reed, 2003). Mortality rates are higher in canaries and finches (80 to 100%) than in chickens and turkeys (Weli and Tryland, 2011).

Worldwide, APV infections cause huge economic losses in poultry industry by lower body growth, drop in egg production and higher mortality (Gyuranecz et al., 2013; Tripathy and Reed, 2003). The effects of APV on wild bird species are also severe. APV infection in wild birds may lead to increased predation on the affected birds, trauma, secondary infections and death (Gyuranecz et al., 2013; Kane et al., 2012). APVs are risk factors for the decline of bird species in various islands and archipelagos, and conservation of endangered bird species. APV-infected, wild migratory birds pose a risk for zoos and aviaries (Gyuranecz et al., 2013).

Penguins are aquatic, flightless birds, living mainly on the southern hemisphere of the earth, especially in Antarctica. Based on the integrated taxonomic information system (ITIS), 19 species of penguins exist worldwide. Penguins are kept in captivity for exhibition, especially Humboldt penguins (*S. humboldti*). At present, most penguin species are threatened, according to the international union for conservation of nature. Infectious diseases are one of the important reasons for the vulnerability of penguin populations.

Earlier, poxvirus infections have been reported in penguin species of South Africa (*S. demersus*), Brazil, Argentina and islands of South America and North America (*S. magellanicus*). The poxvirus infection has also been observed in Humboldt (*S. humboldti*) and Gentoo penguins (*Pygoscelis papua*). In addition, the pox-like wart growth has been reported in Rockhopper (*Eudyptes chrysocome*) and Galapagos penguins (*Spheniscus mendiculus*) (Carulei et al., 2009; Gyuranecz et al., 2013; Kane et al., 2012; Niemeyer et al., 2013; Offerman et al., 2014).

The traditional laboratory diagnosis of APV is carried out by histopathologic examination, electron microscopy, virus isolation on chorioallantoic membrane (CAM) and serological analysis. In the last 15 years, molecular biological techniques like polymerase chain reaction (PCR) have been used for routine diagnosis. The partial P4b core protein gene of 578-base pairs (bp) is a highly conserved pan-genus marker of APVs and is commonly used for diagnosis (Gyuranecz et al., 2013; Huw Lee and Hwa Lee, 1997; Lüschoew et al., 2004; Manarolla et al., 2010; Niemeyer et al., 2013).

In Belgium, APV outbreaks have been rarely reported. However, in the period 2012 – 2014, an outbreak in four juvenile Humboldt penguins (*S. humboldti*) in wild animal park Planckendael and four outbreaks in Belgian commercial layer chickens were observed. Hence, the aim of the present study was to investigate these APV cases. The following laboratory investigations and examinations were performed: histopathology, electron microscopy, virus isolation and genetic characterization of the partial P4b core protein gene (pan-genus marker of APVs).

MATERIALS AND METHODS

Description of APV outbreaks

During the period from January 11th 2012 to September 4th 2014, a total of five APV outbreaks were recorded in the Flanders region of Belgium. One out-

break in four juvenile Humboldt penguins (*S. humboldti*) at the wild animal park Planckendael and four outbreaks in commercial poultry farms (Table 1).

Case history – penguins

A total of 71 Humboldt penguins (*S. humboldti*) (63 adults [26 males and 37 females] and 8 juveniles [6 males and 2 females]) were housed in wild animal park Planckendael, Flanders, Belgium. The adult penguins were born in zoos in Belgium, the Netherlands, France, the UK, Czech Republic, Germany, Sweden and Switzerland. On August 20th 2014, one male juvenile Humboldt penguin showed cutaneous wart-like lesions of \pm 2 mm diameter on the eyelids and subsequently, in another two male and one female juvenile penguins (Figure 1). Lesions were not observed in other skin parts of the infected juvenile Humboldt penguins. The penguins had not been vaccinated against avian pox. The infected juvenile Humboldt penguins were completely recovered on September 25th 2014.

Case history – fowl

Four outbreaks of pox disease occurred in layer chickens of commercial poultry farms during the period 2012 - 2013 in Flanders, Belgium. The veterinarian observed mainly cutaneous pox lesions in the comb, wattles, around the eyes and unfeathered skin parts of chickens of commercial layers. The detailed histories of the individual outbreaks were not recorded. According to the clinical lesions and hosts involved, fowlpox was considered as etiological agent. Vaccination against FPV was only performed on one (12PL 386) of the four farms (live attenuated vaccine) (Table 1).

The collected lesions of both penguins and chickens were submitted to the Laboratory of Virology, Faculty of Veterinary Medicine, Ghent University for diagnosis.

Histopathology

For histopathological examination, the lesions of the penguins and chickens were fixed in 10% buffered formalin and further embedded in paraffin, sectioned at 4 μ m and stained with hematoxylin and eosin.

Electron microscopy

The poxvirus in the crust lesion of the first infected male juvenile penguin was visualized with negative staining electron microscopy using 1% phosphotungstic acid.

Virus isolation on CAM

The tissue lesions of the penguin outbreak and all four chicken outbreaks were stored at -70°C until use. Twenty-percent-tissue homogenates were prepared and centrifuged from one penguin isolate and all four chicken isolates. Hundred μ l of the supernatant of the tissue homogenate was inoculated on the CAM of ten-days-old, embryonated SPF eggs. The inoculated eggs were incubated at 37°C for seven days and then examined for pocks on the CAM. Five passages were performed for the penguin sample and one passage was performed for all four chicken samples.

DNA extraction and PCR amplification

DNA was extracted from 200 μ l of a 20% suspension of lesions from affected penguins and chickens,

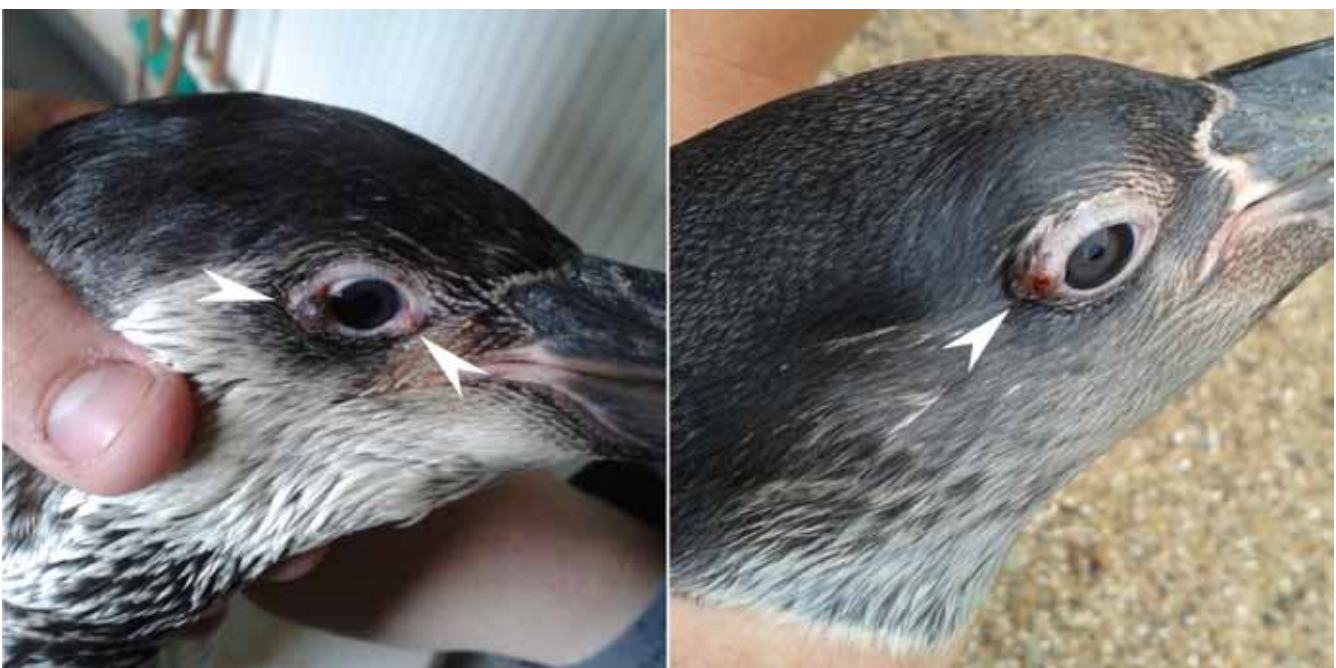

Figure 1. Nodular wart-like lesions on the eyelids of Humboldt penguins (*S. Humboldtii*) at wild animal park Planckendael, Belgium.

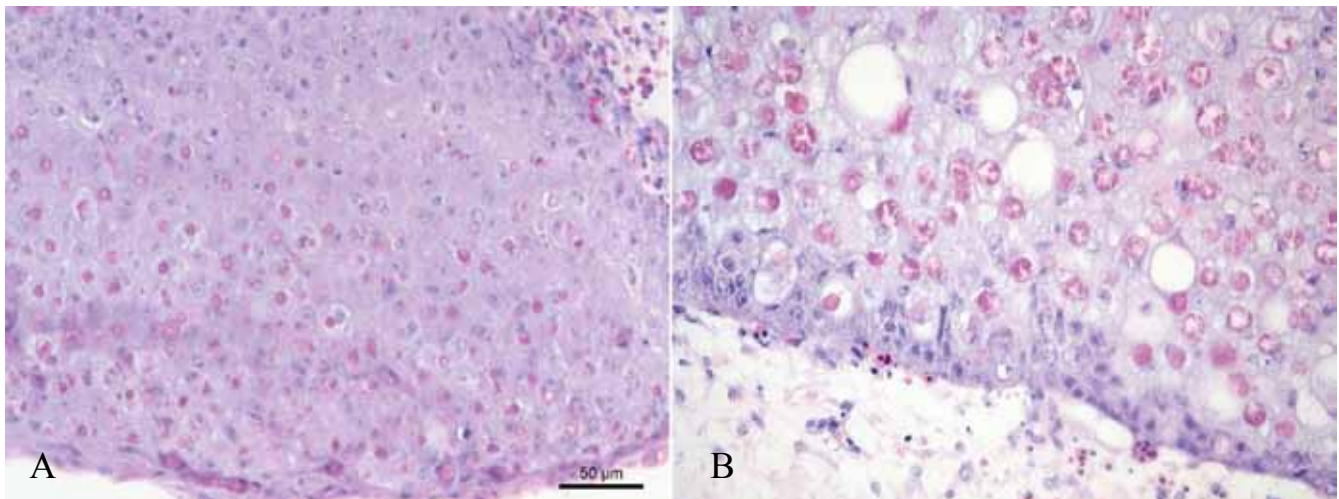


Figure 2A. Cutaneous crust lesions in a Humboldt penguin and 2B. chicken showing distended cytoplasm in epithelial cells with ballooning degeneration and large intracytoplasmic eosinophilic inclusions surrounded by a clear halo, consistent with Bollinger bodies. Hematoxylin and eosin staining.

and CAM of chickens using the QIAamp DNA Mini kit (Qiagen, Hilden, Germany) following the manufacturer's guidelines with a final DNA elution volume of 60 μ l. The DNA concentration was measured by NanoDrop ND-1000 Spectrophotometer (NanoDrop Technologies, USA) and DNA samples were stored at -80°C until analysis. PCR was performed using Agilent's Herculase II fusion DNA polymerase (Agilent Technologies, Inc., Santa Clara, CA, USA). DNA amplification was carried out in a final volume of 50 μ l PCR reaction mixtures containing 10 μ l of 5X Herculase II reaction buffer, 0.5 μ l of 25 mM each deoxynucleoside triphosphate (dNTP) mix, 0.5 μ l Herculase fusion DNA polymerase, 1.25 μ l of each forward (10 μ M) and reverse primers (10 μ M), 5 μ l of dimethyl sulphoxide (DMSO), 10 μ l of template DNA and 21.5 μ l of nuclease-free water.

The APV specific PCR was performed using a primer pair described by Huw Lee and Hwa Lee (1997) based on partial P4b sequence of FPV strain HP444 (forward primer: 5'-CAGCAGGTGCTAAACAA-CAA-3'; reverse primer: 5'-CGGTAGCTTAACGCC-GAATA-3'). Amplification was performed after initial denaturation for two minutes at 95°C for 35 cycles, and consisted of 15 seconds denaturation at 95°C , one minute annealing at 55°C , and 30 seconds extension at 72°C . A final extension step was performed for 15 minutes at 72°C . Then, 5 μ l of the amplified PCR products were separated by 2% agarose gel electrophoresis and stained with ethidium bromide. PCR products of P4b gene with the specific size were purified by Macherey-Nagel kit (Macherey-Nagel GmbH, Duren, Germany), and both strands were sequenced by GATC Biotech AG (Konstanz, Germany).

Phylogenetic analysis of partial P4b gene sequence

Multiple sequence alignments were performed (primer sequences were excluded) using the ClustalW plug-in in the MEGA software version 5.2.2, followed

by manual editing (Tamura et al., 2011). Phylogenetic trees were constructed using the maximum-likelihood method. The substitution model was determined for partial P4b gene. The bootstrap values were determined from 1000 replicates of the original data. Nucleotide sequence identities were determined using the p-distance model. The partial P4b sequence of the Humboldt penguins and the chickens were compared to 90 sequences of different avian species.

GenBank accession number

The partial nucleotide sequence of the 4b core protein gene of juvenile Humboldt PPV was deposited in the GenBank database with accession number KT343756 (Table 1). The partial nucleotide sequences of the 4b core protein gene of the Belgian FPV isolates were identical, and therefore, a single nucleotide sequence was submitted to the GenBank with accession number KT343757 (Table 1).

RESULTS

Outbreak investigation

The present study was based on the pox lesions collected from juvenile Humboldt penguins of wild animal park Planckendael (one outbreak) and laying hens of commercial poultry farms (four outbreaks) during routine diagnostics through the period 2012 - 2014 in Belgium.

Histopathology

The histopathological evaluation of the skin lesions of both penguins and chickens revealed evidently swollen cells, which were characterized by large intracytoplasmic, pale eosinophilic inclusion bodies surrounded by a clear halo (Bollinger bodies) (Figure 2).

Electron microscopy

The electron microscopy revealed oval and brick shaped virus particles from a male juvenile penguin crust lesion. The morphology of the virus particles was consistent with APV.

Virus isolation on CAM

Macroscopically, the CAMs inoculated with the penguin samples did not show typical pock lesions even after five passages. All the chicken samples gave typical pock lesions on the CAMs after the first passage (Table 1).

PCR, sequencing and phylogenetic analysis of partial P4b gene

APV specific DNA was detected in the infected penguin and chicken samples. The size of the amplified products of the partial P4b gene was in agreement with the size (578bp) of the FPV published nucleotide sequences in GenBank (Lüschow et al., 2004; Manarolla et al., 2010). The Tamura's 3-parameter model with gamma distribution sites was used for the construction of a maximum likelihood phylogenetic tree of the partial 4b gene (Figure 3). According to the phylogenetic classification of Jarmin et al. (2006), the partial P4b gene sequence of the Belgian Humboldt (*S. humboldti*) poxvirus was grouped into clade B and the fowlpox virus into clade A. The partial P4b gene sequence of Belgian *S. humboldti* PPV clustered (cluster 1) with many poxvirus sequences of wild bird species of the USA and Europe in subclade B1 (100% homology). The partial P4b sequences of poxviruses from the *S. humboldti* penguin of Wisconsin zoo, the common bullfinch of a Belgian zoo and aviaries and the canary Fort Dodge vaccine were other important sequences of cluster1 of subclade B1 (100 - 99% homology). According to the partial P4b gene sequence, the poxviruses from *S. magellanicus* (Brazil and Argentina) and *S. demersus* (South Africa) penguins did not cluster (subclade A2, A3 and B1 [cluster 3]) with the poxvirus of the Belgian *S. humboldti* penguins (< 89 % homology). The partial P4b gene sequences of the Belgian fowlpox viruses clustered all together and also with the worldwide turkey, canary and fowl pox sequences, and most of the commercially available attenuated fowlpox vaccine (Diftosec CT [Merial], Nobilis Variole W [Intervet], Websters [Fort Dodge] and TAD pocken VAC) sequences in subclade A1 (100% homology).

DISCUSSION

In this study, the first outbreak of PPV in Humboldt penguins of wild animal park Planckendael, Belgium, and four outbreaks of FPV in chickens of Belgian commercial poultry farms are reported. Fur-

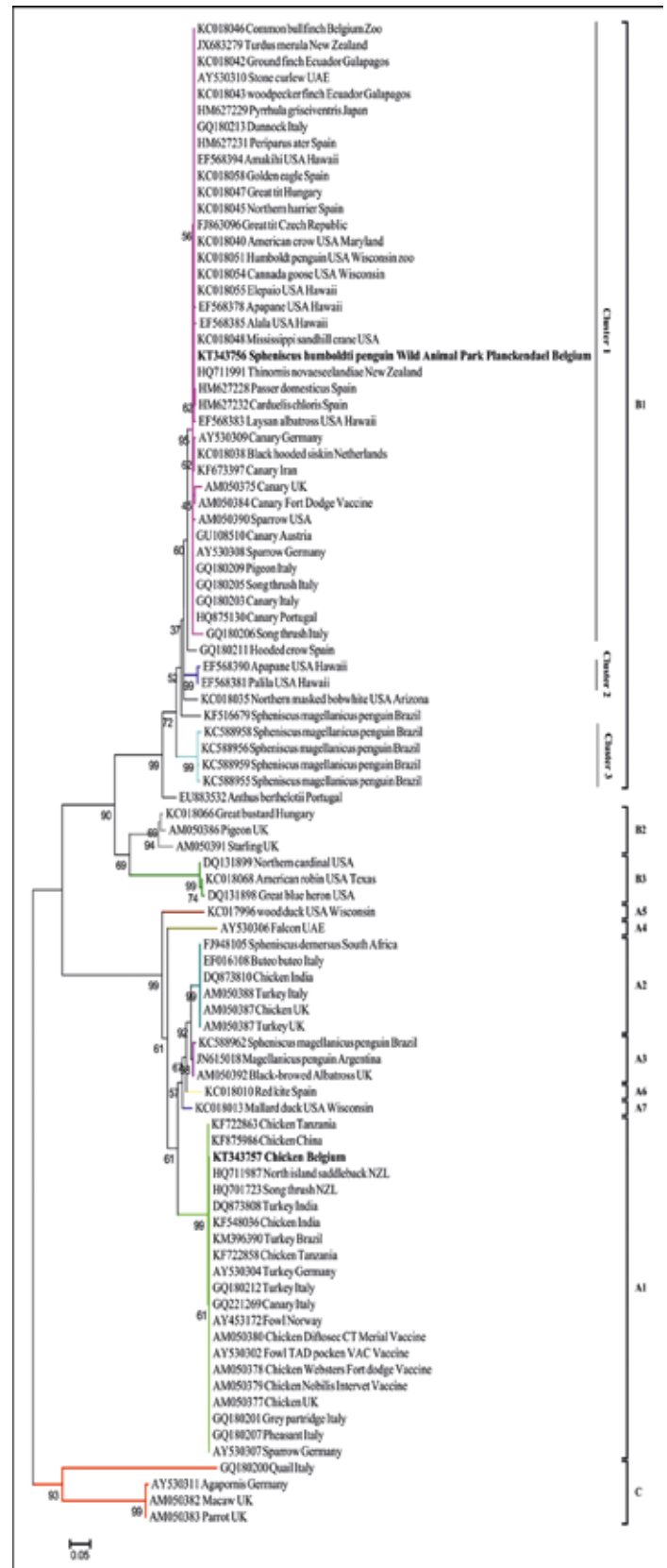


Figure 3. Maximum likelihood phylogenetic tree based on the pan-genus marker partial P4b core protein gene. Boot strap values (n = 1000 replicates) of <70% are not shown. Humboldt penguin and fowlpox partial P4b sequences (bold) were obtained during this study and aligned with 90 avian poxvirus sequences representing 11 different clades (A1, A2, A3, A4, A5, A6, A7, B1, B2, B3 and C) available in GenBank.

ther, the partial P4b gene sequence of PPV and FPV were phylogenetically characterized.

In the juvenile Humboldt penguins and the chickens, typical, cutaneous pox lesions were observed. The pox lesions of the penguins and chickens were consistent with other published reports of pox cases (Hansen, 1999; Kane et al., 2012; Rampin et al., 2007; Van Riper and Forrester, 2007; Weli and Tryland, 2011). The clinical observations were confirmed by histopathological examination and evaluation (PPV and FPV), electron microscopy (PPV) and virus isolation on the CAM of embryonated eggs (FPV). Even after five passages, no lesions were observed with material from the juvenile Humboldt penguins. The absence of pock lesions or less growth has been commonly observed in some of the APV strains, mainly from wild bird species (Krone et al., 2004; Manarolla et al., 2010; Tripathy and Reed, 2003).

The partial P4b gene amplification products of the expected size (578bp) were obtained from both the penguin and chicken samples in this study confirming the value of this PCR for APV infections (Gyuranecz et al., 2013; Ha et al., 2013; Huw Lee and Hwa Lee, 1997; Lüschoew et al., 2004; Manarolla et al., 2010; Niemeyer et al., 2013). According to the phylogenetic analysis of the partial P4b gene, the majority of APVs can be separated into three major clades: A (fowlpox virus), B (canarypox virus) and C (psittacinepox virus) (Gyuranecz et al., 2013; Jarmin et al., 2006). In the narrowest sense, subclade A1 is formed by fowlpox viruses and subclade B1 strictly comprises the canary poxviruses, which are further differentiated into three clusters (Gyuranecz et al., 2013; Niemeyer et al., 2013).

Based on the partial P4b gene sequence, the Belgian Humboldt PPV (*S. Humboldti*) was grouped in cluster 1 under subclade B1. Poxvirus of *S. Humboldti* was not grouped with poxviruses of *S. magellanicus* and *S. demersus*. It is possible that the poxviruses of subclade B1, cluster 1, may not be able to infect the *S. magellanicus* and *S. demersus* penguin species and vice versa (Carulei et al., 2009; Gyuranecz et al., 2013; Kane et al., 2012; Niemeyer et al., 2013; Offerman et al., 2014).

Although the poxvirus induced lesions completely healed in the *S. Humboldti* penguins of Planckendael wild animal park, it is important to discover and eliminate the source of the poxvirus infection in Planckendael wild animal park. The PPV outbreak occurred in August 2014, summer season in Belgium. This timing is in line with earlier APV outbreaks, where APV has been observed in penguins and great tits of Argentina and the UK, in the summer season (Kane et al., 2012; Lawson et al., 2012). There are two important factors that could contribute to the seasonal outbreak of APVs. During the summer period, the arthropod vectors may have mechanically transmitted the virus from infected wild and free-range birds to the penguins (Lawson et al., 2012). Otherwise, the car-

rier wild migratory birds may have directly transmitted infection to the penguins, as they passed over the Planckendael wild animal park. Based on the danger of cross species jumps of APVs, more surveillance and epidemiological studies should be performed on APVs in free-range and wild bird species in the natural avifauna of Belgium.

Infections with FPV are recurrently appearing in poultry farms of Europe (Lüschoew et al., 2004). Based on the partial P4b gene sequences, all the FPV isolates of Belgium were clustered in subclade A1 (100% nucleotide homology). In this subclade A1, FPV isolates of chickens, turkeys, canaries, and attenuated live vaccines from all over the world were present (Ha et al., 2013; Lüschoew et al., 2004; Manarolla et al., 2010). This indicates that FPV entered Belgium in the past, leading to current outbreaks.

At present, attenuated live vaccines are available against fowlpox, canarypox, pigeonpox and quailpox, but not against penguinpox. Although the vaccines have contributed to the prevention of pox disease in the different species, it is not known to what degree the currently available vaccines may give protection in Belgian penguin species.

In this study, one of the FPV outbreaks was observed in the vaccinated flock. There are many reasons for vaccination failure in fowlpox disease outbreaks. One of the important reasons is the drop of vaccination efficacy, and it is associated with the integration of reticuloendotheliosis virus (REV) into the FPV genome (Davidson et al., 2008; Fatunmbi and Reed, 1996; Singh et al., 2000; Tadese et al., 2008). Several authors have reported that the REV integration into the FPV genome has contributed to the increase of virulence in field outbreaks (Fatunmbi and Reed, 1996; Garcia et al., 2003). Thus, genetic characterization of the REV region is important to understand the pathogenesis and the virulence factors of the PPV and FPV isolates of the present study.

Even though the pan-genus marker partial P4b gene has been commonly used for phylogenetic analysis and classification of APVs, it is yet not understood whether certain amino acid sequences of the P4b gene products may be involved in host tropism and specificity. Host tropism and specificity determinants of APVs may be very complex because the genome size is large (260 to 365 kb) and complex in nature. More investigations on the whole genome sequences of emerging APVs may provide interesting information on the host tropism and specificity.

In conclusion, the present study exemplifies that a rapid and precise diagnostic approach easily leads to the identification of re-emerging poxviruses. Due to the frequent recurrence of APV infections, it is worth studying the molecular and cellular basis of the induction of lesions in penguin and fowlpox viruses both in vitro and in vivo. Better insights will pave the way to develop strategies for minimizing the formation of proliferative pox lesions.

ACKNOWLEDGEMENTS

This research was supported by the Indian Council of Agricultural Research (ICAR, Pusa, New Delhi-110012 (29-1/2009-EQR/Edn)). Vishwanatha Reddy and Hans Nauwynck are members of the BELVIR consortium (IAP, phase VII) sponsored by Belgian Science Policy Office (BELSPO). The authors acknowledge Lieve Sys and Magda De Keyzer for their excellent technical assistance.

CONFLICTS OF INTEREST

The authors declare no conflict of interest.

REFERENCES

- Boyle, D.B. (2007). Genus avipoxvirus, In: Andrews, B.M., Axel, S., Olaf, W. (Editors). *Poxviruses*. Basel, Switzerland, 217-251.
- Carulei, O., Douglass, N., Williamson, A.L., (2009). Phylogenetic analysis of three genes of Penguinpox virus corresponding to Vaccinia virus G8R (VLTF-1), A3L (P4b) and H3L reveals that it is most closely related to Turkeypox virus, Ostrichpox virus and Pigeonpox virus. *Virology Journal* 6, 52.
- Davidson, I., Shkoda, I., Perk, S., (2008). Integration of the reticuloendotheliosis virus envelope gene into the poultry fowlpox virus genome is not universal. *Journal of General Virology* 89, 2456-2460.
- Fatunmbi, O.O., Reed, W.M., (1996). Evaluation of a commercial modified live virus fowl pox vaccine for the control of "variant" fowl poxvirus infections. *Avian Diseases* 40, 582-587.
- Garcia, M., Narang, N., Reed, W.M., Fadly, A.M., (2003). Molecular characterization of reticuloendotheliosis virus insertions in the genome of field and vaccine strains of fowl poxvirus. *Avian Diseases* 47, 343-354.
- Gubser, C., Hué, S., Kellam, P., Smith, G.L., (2004). Poxvirus genomes: a phylogenetic analysis. *Journal of General Virology* 85, 105-117.
- Gyuranecz, M., Foster, J.T., Dán, Á., Ip, H.S., Egstad, K.F., Parker, P.G., Higashiguchi, J.M., Skinner, M.A., Höfle, U., Kreizinger, Z., Dorrestein, G.M., Solt, S., Sós, E., Kim, Y.J., Uhart, M., Pereda, A., González-Hein, G., Hidalgo, H., Blanco, J.M., Erdélyi, K., (2013). Worldwide phylogenetic relationship of avian poxviruses. *Journal of Virology* 87, 4938-4951.
- Ha, H.J., Alley, M., Howe, L., Gartrell, B., (2013). Evaluation of the pathogenicity of avipoxvirus strains isolated from wild birds in New Zealand and the efficacy of a fowlpox vaccine in passerines. *Veterinary Microbiology* 165, 268-274.
- Hansen, W. (1999). General field procedures and diseases of birds, In: Friend M., J.C., F. (Editors) *Field Manual of Wildlife Diseases*. Madison, Wisconsin, 163-170.
- Huw Lee, L., Hwa Lee, K., (1997). Application of the polymerase chain reaction for the diagnosis of fowl poxvirus infection. *Journal of Virological Methods* 63, 113-119.
- Jarmin, S., Manvell, R., Gough, R.E., Laidlaw, S.M., Skinner, M.A., (2006). Avipoxvirus phylogenetics: identification of a PCR length polymorphism that discriminates between the two major clades. *Journal of General Virology* 87, 2191-2201.
- Kane, O.J., Uhart, M.M., Rago, V., Pereda, A.J., Smith, J.R., Van Buren, A., Clark, J.A., Boersma, P.D., (2012). Avian pox in Magellanic Penguins (*Spheniscus magellanicus*). *Journal of Wildlife Diseases* 48, 790-794.
- Karstad, L. (1971). Pox, In: Davis J.W., A.R.C.K.L., Trainer D.O. (Editors). *In Infectious and Parasitic Disease of Wild Birds*. Iowa State University Press, Ames, Iowa, 34-41.
- Krone, O., Essbauer, S., Wibbelt, G., Isa, G., Rudolph, M., Gough, R.E., (2004). Avipoxvirus infection in peregrine falcons (*Falco peregrinus*) from a reintroduction programme in Germany. *Veterinary Record* 154, 110-113.
- Lawson, B., Lachish, S., Colvile, K.M., Durrant, C., Peck, K.M., Toms, M.P., Sheldon, B.C., Cunningham, A.A., (2012). Emergence of a novel avian pox disease in British tit species. *PLoS One* 7, e40176.
- Lüschow, D., Hoffmann, T., Hafez, H.M., (2004). Differentiation of avian poxvirus strains on the basis of nucleotide sequences of 4b gene fragment. *Avian Diseases* 48, 453-462.
- Manarolla, G., Pisoni, G., Sironi, G., Rampin, T., (2010). Molecular biological characterization of avian poxvirus strains isolated from different avian species. *Veterinary Microbiology* 140, 1-8.
- Niemeyer, C., Favero, C.M., Kolesnikovas, C.K., Bhering, R.C., Brandão, P., Catão-Dias, J.L., (2013). Two different avipoxviruses associated with pox disease in Magellanic penguins (*Spheniscus magellanicus*) along the Brazilian coast. *Avian Pathology* 42, 546-551.
- Offerman, K., Carulei, O., van der Walt, A.P., Douglass, N., Williamson, A.L., (2014). The complete genome sequences of poxviruses isolated from a penguin and a pigeon in South Africa and comparison to other sequenced avipoxviruses. *BMC Genomics* 15, 463.
- Rampin, T., Pisoni, G., Manarolla, G., Gallazzi, D., Sironi, G., (2007). Epornitic of avian pox in common buzzards (*Buteo buteo*): virus isolation and molecular biological characterization. *Avian Pathology* 36, 161-165.
- Singh, P., Kim, T.J., Tripathy, D.N., (2000). Re-emerging fowlpox: evaluation of isolates from vaccinated flocks. *Avian Pathology* 29, 449-455.
- Tadese, T., Fitzgerald, S., Reed, W.M., (2008). Detection and differentiation of re-emerging fowlpox virus (FWPV) strains carrying integrated reticuloendotheliosis virus (FWPV-REV) by real-time PCR. *Veterinary Microbiology* 127, 39-49.
- Tamura, K., Peterson, D., Peterson, N., Stecher, G., Nei, M., Kumar, S., (2011). MEGA5: molecular evolutionary genetics analysis using maximum likelihood, evolutionary distance, and maximum parsimony methods. *Molecular Biology and Evolution* 28, 2731-2739.
- Tripathy, D.N., Reed, W.M. (2003). Poxvirus, In: Saif, Y.M.B., H.J. Glisson, J.R. Fadly, A.M. McDougald, L.R. Swayne, D.E. (Editors). *In Diseases of Poultry*. Iowa State University Press, Ames, Iowa, 253-269.
- Van Riper, C., Forrester, D.J. (2007). Avian Pox, In: Thomas N., H.B., Atkinson C.A. (Editors). *In Infectious and Parasitic Diseases of Wild Birds*. Blackwell Publishing Professional, Ames, Iowa, 131-176.
- Weli, S.C., Tryland, M., (2011). Avipoxviruses: infection biology and their use as vaccine vectors. *Virology Journal* 8, 49.