

Case 14398

Dysbaric osteonecrosis of the humerus

Magdalena Posadzy¹, Nicolas De Vos^{2, 3}, Filip Vanhoenacker^{2, 3, 4}

1. W. Dega Orthopaedic and Rehabilitation University Hospital, Karol Marcinkowski University of Medical Sciences; Poznan, Poland

2. Ghent University Hospital, Department of Radiology; De Pintelaan 185, 9000 Ghent, Belgium

3. AZ Sint-Maarten Duffel-Mechelen, Department of Radiology; Leopoldstraat 2, 2800 Mechelen, Belgium

4. University Hospital Antwerp, Department of Radiology; Wilrijkstraat 10, 2650 Antwerp, Belgium; Email: filip.vanhoenacker@telenet.be
University Hospital Antwerp

Section: Musculoskeletal System

Published: 2017, Jan. 31

Patient: 42 year(s), male

Clinical History

A 42-year-old recreational diver presented with progressive pain at the right shoulder two hours following diving. History of recent trauma was denied.

Imaging Findings

Plain radiographs revealed no abnormalities (Fig. 1). Magnetic resonance (MR) arthrography of the right shoulder 4 weeks after the onset of pain was requested in order to exclude rotator cuff disease and bone marrow disease. MR revealed an irregular aspect of the articular side of the supraspinatus tendon (Fig. 2A). MRI also showed an extensive area of abnormal bone marrow within the proximal diaphysis of the humerus, with extension into the humeral head (Fig. 2B, Fig. 3A and B). Coronal T1-weighted images (T1-WI) of the right humerus (Fig. 3) showed a peripheral rim of low signal intensity (SI) surrounding a central zone similar to fat. On coronal fat suppressed T2-WI

(Fig. 4A and B), the peripheral borders were strongly hyperintense. Coronal T2-WI (Fig. 5) showed a double-line sign consisting of a hyperintense rim centrally surrounded by a hypointense rim peripherally. There was no soft tissue involvement.

Discussion

Based on the imaging findings and clinical history of the patient, diagnosis of dysbaric osteonecrosis (DON) was made.

DON is a manifestation of decompression illness (DCI). Other commonly used terms are Caisson disease, the bends, and diver's disease. DON results from nitrogen gas bubble formation following an excessive drop in atmospheric pressure, in divers during rapid ascent, or in pilots after urgent increase of altitude [1].

DON usually affects fatty-marrow containing long bones, particularly the proximal third of the humerus and tibia and distal third of the femur [2]. This can be explained by the fact that nitrogen is more soluble in fat [3]. Obstruction of intramedullary sinusoids by gas bubbles results in blood stasis, ischemia and bone necrosis causing joint pain (acute type I of DCI). Furthermore intramedullary pressure changes may aggravate venous stasis [3]. In type II of DCI, neurologic, pulmonary and circulatory symptoms predominate.

Clinical information is crucial to make a final diagnosis as imaging of DON is not different from other causes of bone infarcts.

Plain radiography lacks sensitivity for early detection of DON. Typical radiographic findings include increased bone density, subarticular crescent sign and geographically delineated bone infarcts with sclerotic borders. These findings are only visible after weeks or months and represent late, irreversible lesions.

MRI is the preferred technique for early diagnosis. Devascularized areas tend to form well-demarcated lesions with a characteristic serpiginous geographic pattern [4]. Typically, a peripheral double-line sign is seen on T2-WI, consisting of an inner rim of high SI surrounded by an outer rim of low SI. It was initially explained by an inflammatory response around the central ischemic core resulting in a hyperintense inner zone of hyperemic granulation tissue and a hypointense outer rim of reactive sclerosis [5]. Alternatively, the double line sign may be caused by a chemical shift artefact, explaining reversal of these alternating hypointense and hyperintense rims. The central part of osteonecrotic bone marrow may have a variable SI. Most often, due to mummification of dead fatty marrow, the SI resembles fat on all pulse sequences, although edematous or fibrotic changes may occur [4].

Scintigraphy is sensitive to detect early ischemic bone marrow changes, its low specificity hampers its usefulness in diagnosing DON.

The prognosis depends upon early diagnosis and prompt treatment, consisting of hyperbaric oxygen therapy in a recompression chamber. This has been applied twice in our patient with complete resolution of pain within 1 week following treatment.

Final Diagnosis

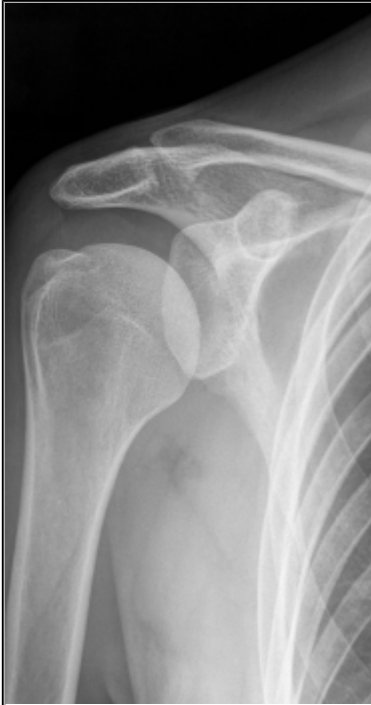Dysbaric osteonecrosis of humerus

Differential Diagnosis List

Other causes of osteonecrosis (microscopic fat emboli; haemoglobinopathies - sickle cell disease; focal clotting due to procoagulant abnormalities; corticosteroids intake; Gaucher disease; pancreatitis; radiation-induced osteonecrosis), Cartilaginous tumours (enchondroma; chondrosarcoma), Septic necrosis in acute osteomyelitis

Figures

Figure 1 Radiograph



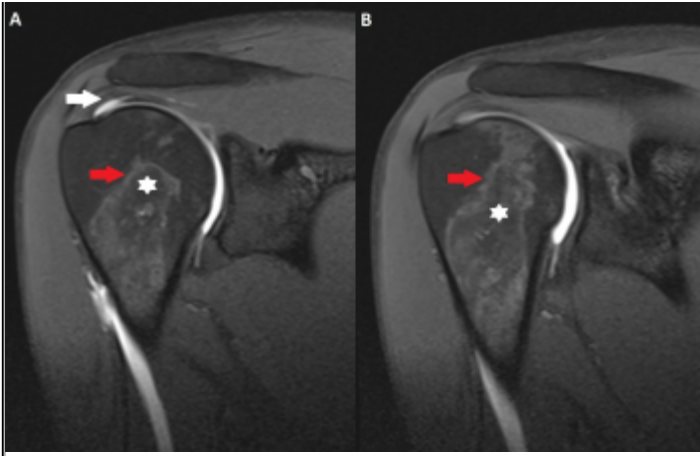
Anteroposterior (AP) radiograph of the right shoulder with the humerus in external rotation shows no abnormalities.

© Vanhoenacker FM, Department of Radiology, AZ Sint-Maarten, Mechelen, Belgium

Area of Interest: Musculoskeletal bone;
Imaging Technique: Conventional radiography;
Procedure: Education;
Special Focus: Trauma;

Figure 2 MR arthrography, fs T1-WI



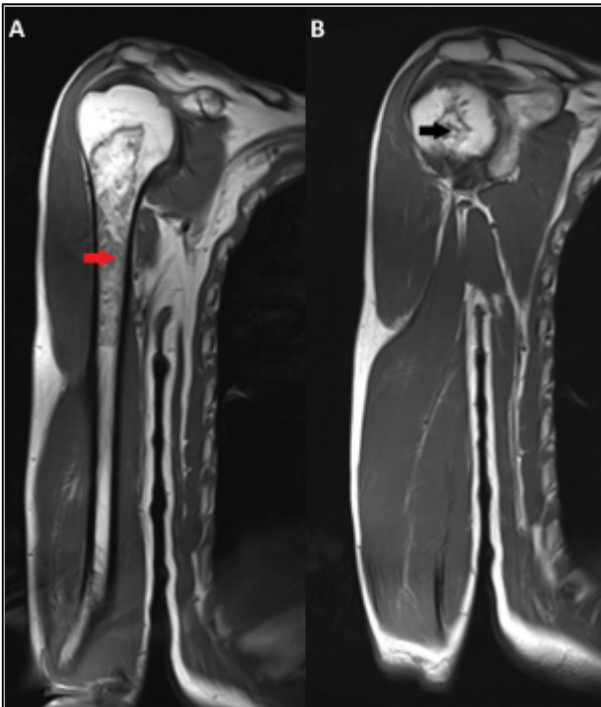


MR arthrography, coronal fs T1-WI (A and B): irregularity in the supraspinatus (white arrow), bone marrow abnormalities in the humerus, with low SI centrally (white asterisk) and intermediate to high SI peripherally (red arrow).

© Vanhoenacker FM, Department of Radiology, AZ Sint-Maarten, Mechelen, Belgium

Area of Interest: Musculoskeletal bone;
 Imaging Technique: MR;
 Procedure: Arthrography;
 Special Focus: Tissue characterisation;

Figure 3 Coronal T1-WI MR Images

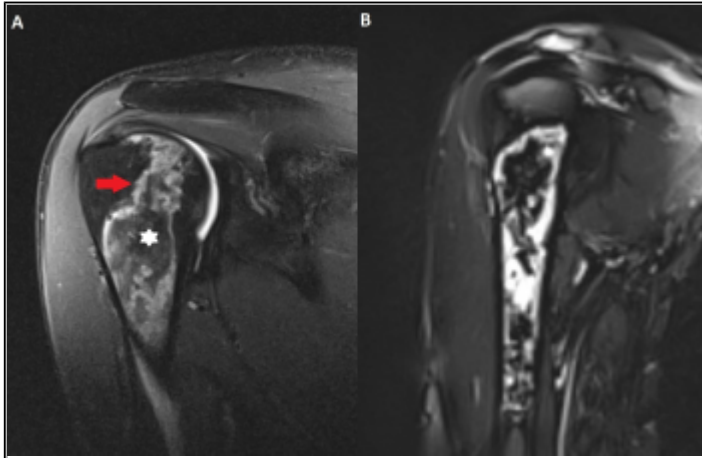


Coronal T1-WI (A and B): intramedullary lesion with geographical borders within the proximal diaphysis (red arrow), with epiphyseal extension (black arrow).

© Vanhoenacker FM, Department of Radiology, AZ Sint-Maarten, Mechelen, Belgium

Area of Interest: Musculoskeletal bone;
 Imaging Technique: MR;
 Procedure: Arthrography;
 Special Focus: Tissue characterisation;

Figure 4 MR arthrography, fs T2-WI

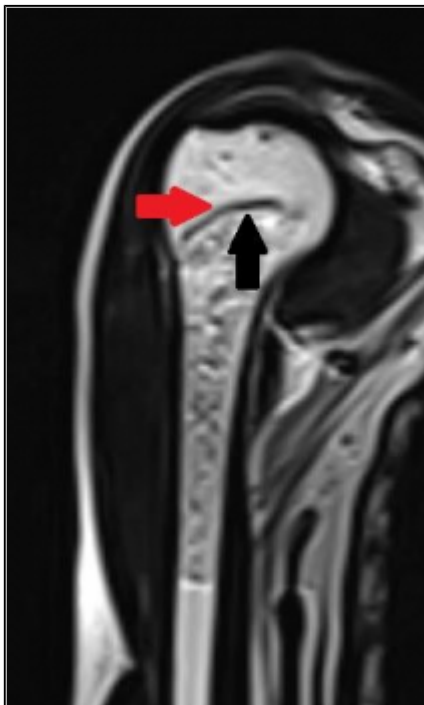


MR arthrography, coronal fs T2-WI (A and B): the peripheral borders are strongly hyperintense (red arrow), while the center of the lesion remains hypointense (white asterisk).

© Vanhoenacker FM, Department of Radiology, AZ Sint-Maarten, Mechelen, Belgium

Area of Interest: Musculoskeletal bone;
Imaging Technique: MR;
Procedure: Arthrography;
Special Focus: Tissue characterisation;

Figure 5 MR arthrography, T2-WI



MR arthrography, coronal T2-WI: double-line sign with inner hyperintense rim (black arrow) and outer hypointense rim (red arrow).

© Vanhoenacker FM, Department of Radiology, AZ Sint-Maarten, Mechelen, Belgium

Area of Interest: Musculoskeletal bone;
Imaging Technique: MR;
Procedure: Arthrography;

References

- [1] Kumierska A, Ga P, Szymaski M et al (2013) Multifocal, bone manifestation of decompression sickness in a pilot: a case report *Medycyna Pracy* 64(2): 273-279
- [2] Cimsit M, Ilgezdi S, Cimsit C et al (2007) Dysbaric osteonecrosis in experienced dive masters and instructors *Aviation, Space, and Environmental Medicine* 78(12): 1150-1154
- [3] Hutter CD (2000) Dysbaric osteonecrosis : a reassessment and hypothesis. *Medical Hypotheses* Med Hypotheses 54(4):585-590
- [4] Helms CA, Major NM, Anderson MW et al (2009) *Musculoskeletal MRI, 3rd Edn*
- [5] Zurlo JV (1999) The Double-Line sign *Radiology* 212(2):541-542

Citation

Magdalena Posadzy¹, Nicolas De Vos^{2, 3}, Filip Vanhoenacker^{2, 3, 4}

1. W. Dega Orthopaedic and Rehabilitation University Hospital, Karol Marcinkowski University of Medical Sciences; Poznan, Poland

2. Ghent University Hospital, Department of Radiology; De Pintelaan 185, 9000 Ghent, Belgium

3. AZ Sint-Maarten Duffel-Mechelen, Department of Radiology; Leopoldstraat 2, 2800 Mechelen, Belgium

4: University Hospital Antwerp, Department of Radiology; Wilrijkstraat 10, 2650 Antwerp, Belgium; Email:filip.vanhoenacker@telenet.be (2017, Jan. 31)

Dysbaric osteonecrosis of the humerus {Online}

URL: <http://www.eurorad.org/case.php?id=14398>