



Title	Does reduced-port laparoscopic surgery for medically uncontrolled ulcerative colitis do more harm than good?
Author(s)	Homma, Shigenori; Kawamata, Futoshi; Shibasaki, Susumu; Kawamura, Hideki; Takahashi, Norihiko; Taketomi, Akinobu
Citation	Asian journal of endoscopic surgery, 9(1), 24-31 <a href="https://doi.org/10.1111/ases.12250">https://doi.org/10.1111/ases.12250</a>
Issue Date	2016-02
Doc URL	<a href="http://hdl.handle.net/2115/64443">http://hdl.handle.net/2115/64443</a>
Rights	This is the peer reviewed version of the following article: Homma, S., Kawamata, F., Shibasaki, S., Kawamura, H., Takahashi, N. and Taketomi, A. (2016), Does reduced-port laparoscopic surgery for medically uncontrolled ulcerative colitis do more harm than good?. Asian J Endosc Surg, 9: 24–31, which has been published in final form at <a href="http://dx.doi.org/10.1111/ases.12250">http://dx.doi.org/10.1111/ases.12250</a> . This article may be used for non-commercial purposes in accordance with Wiley Terms and Conditions for Self-Archiving.
Type	article (author version)
File Information	AsianJEndoscSurg9_24.pdf



[Instructions for use](#)

**Original Article****Does the reduced port laparoscopic surgery for medically uncontrolled ulcerative colitis do more harm than good ?**

Shigenori Homma, Futoshi Kawamata, Susumu Shibasaki, Hideki Kawamura, Norihiko Takahashi, Akinobu Taketomi

Hokkaido University Graduate School of Medicine, Department of Gastroenterological Surgery I, Sapporo, Japan

**Address correspondence to:**

Shigenori Homma, M.D.

North 15, West 7, Kita-ku, Sapporo 060-8638, Japan

**Fax number:** +81-11-706-7515

**Tel number:** +81-11-706-5927

**E-mail address:** [homma.s@nifty.com](mailto:homma.s@nifty.com)

Futoshi Kawamata, M.D.

North 15, West 7, Kita-ku, Sapporo 060-8638, Japan

**Fax number:** +81-11-706-7515

**Tel number:** +81-11-706-5927

**E-mail address:** [k-futoshi@cotton.ocn.ne.jp](mailto:k-futoshi@cotton.ocn.ne.jp)

These authors contributed equally to this work

**Running title:** Reduced port surgery for UC

**Key words:** laparoscopic surgery, SILS, ulcerative colitis

**Word count:** 3037 words

## **Abstract**

**Introduction:** Reduced port laparoscopic surgery is a novel minimally invasive surgery. However, the reduced port surgery for ulcerative colitis (UC) remains controversial. Here, we describe the clinical outcomes of single-incision plus one additional port laparoscopic surgery (SILS+1) for medically uncontrolled UC.

**Methods:** Between May 2011 and September 2014, 10 UC patients underwent SILS+1 port surgery. All procedures were performed with the use of a SILS port and a 5-mm or 12-mm port placed at the planned ileostomy site.

**Results:** The median age was 32.0 years (range, 22–53 years). Six patients underwent 2-stage SILS+1 port restorative proctocolectomy with ileal pouch anal anastomosis (IPAA), 2 patients underwent SILS+1 total proctocolectomy, and the remaining 2 patients underwent SILS+1 subtotal colectomy (STC) with subsequent three-stage SILS+1 IPAA. The median operative time and estimated blood loss were 363.1 min (range, 253–465 min) and 29.0 mL (range, 0–100 mL), respectively. There were no conversions or additional ports required. In patients who underwent a previous SILS+1 STC, SILS+1 IPAA was performed successfully in 1 patient 6 months after the previous surgery. There were no intra-abdominal adhesions, and no extra wounds were necessary because the previous stoma site was used to access the SILS port. The median postoperative period was 24 months, during which time 5 patients had their ileostomies closed. No patients reported occasional minor daily soiling and the need to wear a pad.

**Conclusion:** Reduced port laparoscopic surgery for medically uncontrolled UC is a feasible and safe procedure when performed by skilled surgeons.

## **Introduction**

Despite significant advances in the medical treatment of ulcerative colitis (UC), surgery remains the definitive cure after the failure of medical management (1, 2), and a restorative procedure with the creation of an ileal pouch anal anastomosis (IPAA) is the standard surgical treatment choice for UC. Compared with open surgery, laparoscopic total proctocolectomy (TPC)-IPAA might result in earlier return of flatus and resumption of diet, less intraoperative blood loss compared with open surgery, and no differences in overall complication rate, pouch function, or quality of life (3-8). Moreover, minimally invasive procedures are particularly appealing to this patient group owing to their young age and poor general condition, which is typically worsened by the aggressive medical treatments.

Single-incision laparoscopic surgery (SILS) and reduced port laparoscopic surgery (RPLS) have been used in urologic, gynecologic, general, and colorectal surgery, demonstrating even greater cosmetic benefits than conventional multiport laparoscopic surgery (CLS) (9, 10). Specifically for colorectal surgery, SILS has been associated with improved cosmesis and enhanced recovery due to less postoperative pain (11, 12). However, the acceptance of SILS for surgical management of UC has been quite challenging, potentially owing to the presence of fistulizing disease, abscesses, cachexia, recurrent disease, and compromised healing capacity in many patients following the administration of immunosuppressive drugs (13). The use of CLS for patients with UC also remains difficult as a result of intense inflammation leading to colonic distension and the high risk of bleeding and accidental perforation (8). Moreover, from a technical point of view, the disadvantages of SILS are a loss of triangulation, interference between the instruments and the scope and the surgeon's arm and the scope, and obstruction of the operative fields due to parallel placement of the instruments. These challenges with SILS are more evident with UC, especially when performing proctocolectomy.

Current evidence for the reduced port surgery and the use of SILS for UC are limited, and its application for severe UC remains controversial (14). However, potential advantages include decreased perioperative pain, faster recovery, and superior cosmesis, compared with CLS [15]. Adding a port to SILS (SILS+1) may bridge the gap between CLS and SILS, and the use of SILS port incision as the ileostomy site may represent a minimally invasive approach that results in a scarless procedure.

We began performing SILS+1 port surgery in May 2011. Here, we describe the clinical outcomes of SILS+1 port surgery as reduced port surgery in 10 patients with medically uncontrolled UC.

## **Materials and Methods**

### **Patient selection**

Informed consent was waived by the hospital ethics review board. Data of all patients who underwent SILS+1 port surgery (n = 10) between May 2011 and September 2014 were collected from the database of the Department of Gastroenterological Surgery I, Hokkaido University Graduate School of Medicine. This database includes patient demographic factors (age, sex, and body mass index [BMI]), preoperative medical treatment (including use and dose of steroids equivalent to prednisolone and of immunosuppressive agents), cytapheresis, American Society of Anesthesiologists (ASA) score, use of ileostomy, operative time, estimated blood loss, return of bowel function, length of hospital stay, and complications.

### **Operative procedures**

Procedures were performed by the same surgeon (SH) who had experience with more than 700 laparoscopic colorectal resection procedures and more than 100 SILS for colorectal

diseases. Good exposure of the operating field was obtained by changing the Trendelenburg position and the lateral tilt of the table. For the first 2 cases, the SILS™ port (Covidien Ltd., Hamilton, Bermuda) with 3 in-built trocars was used through a 2.5-cm intra-umbilical incision, and a 12-mm port was placed in the right iliac fossa at the ileostomy site (Fig. 1a). However, to perform a more scarless procedure, we changed the port sites in the remaining 8 cases (Patients 3 to Patients 10), as follows: the SILS port was positioned at the site of the proposed temporally right iliac-fossa ileostomy (2.5-cm incision), and an additional 5-mm trocar was inserted in the umbilicus (Fig. 1b).

All procedures were performed using a 5-mm standard definition flexible scope, ultrasonic-activated scissors (Harmonic ACE™, Ethicon EndoSurgery Inc., Blue Ash, Cincinnati, OH), activating laparoscopic coagulating shears (LigaSure™; Covidien Ltd.), and straight and curved graspers (Roticulator Endo Grasp; Covidien Ltd.). The dissection began at the rectum mobilization. The root of the inferior mesenteric artery was located, and the mesentery of the sigmoid colon and rectum was detached using a medial approach (Fig. 2a). The posterior side of the rectum was dissected between the mesorectum and the hypogastric nerve fascia to preserve the hypogastric nerves and pelvic plexus. The sigmoid colon and rectum were completely mobilized to the level of the levator ani muscle. Next, the descending colon was mobilized from the sigmoid to the splenic flexure by sequentially dividing the lateral attachments and separating the Gerota's fascia and Toldt's fascia with blunt dissection (Fig. 2b). The operative field then shifted to the right colon. The ileocecal vessels were preserved to maintain an adequate blood supply to the ileal pouch. The end of the ileum was cut using Endo-GIA staplers (Covidien Ltd.), and the ascending colon was mobilized to the hepatic flexure using a retroperitoneal approach (Fig. 2c). The hepatocolic ligament was moved down, and the transverse mesocolon and greater omentum were divided to mobilize the transverse colon. Transanal mucosectomy was performed above the dentate

line, and the circumferential muscular layer of the rectum was transected using an Echelon™ 60 Endopath stapling device (Ethicon Endo Surgery, Cincinnati, OH, USA) or a two firings of linear cutting roticulating stapler (EndoGIA, 45 mm purple cartridge, Covidien). Then, a total colectomy was performed (Fig. 2d). In the first two cases, the mobilized proctocolectomy specimen was delivered transanally following a rectal mucosectomy. The specimen was delivered through the SILS port in the remaining 8 cases.

A 10-cm J pouch was created extracorporeally with a linear cutter stapler and returned via the ileostomy site. A pouch-anal anastomosis was performed intracorporeally with an EEA circular stapler (Ethicon Endo Surgery) (n = 4) (Fig. 2e) or a hand-sutured technique (n = 2). The pouch was pulled down in the latter two cases using a transanal forceps. Great care was taken to ensure that the mesentery was not twisted. The diverting loop ileostomy was created at the right iliac fossa at the port site. Finally, the pelvic drain was brought out through the umbilical port site (Fig. 1d).

## **Results**

### **Patient characteristics**

The demographic characteristics of the patients are presented in Table 1. The median age was 32.0 years (range, 22–53 years), and the median BMI was 20.9 kg/m<sup>2</sup> (range, 17.4–27.3 kg/m<sup>2</sup>). The median ASA score was 2.8 (range, 2–3), and the total steroid dose was 1.0–93.0 g. Five patients received infliximab therapy, and 5 patients underwent cytapheresis. Medical intractability was the most common indication for surgery.

### **Surgical findings and short-term outcomes**

Of the 10 patients with UC who underwent SILS+1 port surgery (Fig. 3), 6 patients underwent 2-stage SILS+1 IPAA, 2 patients underwent SILS+1 TPC because of coexisting

rectal cancer (Patient 4) and chronic renal failure requiring hemodialysis (Patient 8), and the remaining 2 patients underwent SILS+1 subtotal colectomy (STC), with the subsequent IPAA performed laparoscopically (three-stage SILS+1 IPAA).

Perioperative results are provided in Table 2. To achieve full transection of the proximal rectum, 2 firings of 45 mm EndoGIA were needed for 8 cases, and only 2 cases were used Echelon™ 60 Endopath stapling device. Supplemental Fig. 1a shows circumferential muscular layer of the rectum was transected using an Echelon™ 60 Endopath stapling device, and supplemental Fig. 1b shows the length of remnant rectum. The median operative time was 363.1 min (range, 253–465 min), and the median estimated blood loss was 29.0 mL (range, 0–100 mL). None of the patients required the addition of other ports, and there were no conversions to either a conventional laparoscopic or an open procedure. There were no intraoperative complications, such as bowel perforation or massive bleeding, and the median time to return of bowel function was 1 day. Postoperative complications included one patient with methicillin-resistant *Staphylococcus aureus* (MRSA) enteritis, which resolved with conservative management. The median length of hospital stay was 20.7 days (range, 7–29 days). Figure 1d shows the postoperative view of a patient who underwent SILS+1 IPAA.

### **Operative technique following previous SILS +1 port subtotal colectomy**

In 2 patients who had undergone a previous SILS+1 STC, SILS+1 IPAA was performed successfully in 1 patient 6 months after the previous surgery (Patient 6). There were no intra-abdominal adhesions, and no extra wounds were necessary because the previous stoma site was used to access the SILS port. Moreover, the mesentery was fully pulled down into the pelvis when we created the J pouch and performed a pouch-anal anastomosis. The operative time was 214 min, and the estimated blood loss was 0 mL.



## **Functional outcomes and short-term results**

The median postoperative period was 24 months, during which time 5 patients had their ileostomies closed after verification of anastomotic healing. No patients reported occasional minor daily soiling, the need to wear a pad, or occasional nocturnal incontinence.

## **Discussion**

In the present study, the specific surgical procedure for each patient (SILS+1 IPAA, SILS+1 TPC, or SILS+1 STC with subsequent three-stage SILS+1 IPAA) was chosen based on the preoperative disease severity and intraoperative short colonoscopy (Table 1). Given the observed peri- and post-operative results, we consider that SILS+1 port surgery is an acceptable procedure for UC with regards to operation time, recovery, morbidity, length-of-stay, and safety.

The present median operative time and estimated blood loss were 363.1 min (range, 253–465 min) and 29.0 mL (range, 0–100 mL), respectively, while the reported operative time and blood loss in conventional laparoscopic surgery for UC were 181–440 min and 80–140 mL respectively(6, 15, 16). The time to return of bowel function (median 1 day) and length of hospital stay (median, 20.7 days; range, 7–29 days) were acceptable.

Recently, more efforts have been made to reduce the number of ports and Table 3 showed SILS approach to IPAA, TPC and STC for UC patients(10, 13-15, 17). However, these data are preliminary, with only few cases of SILS for UC published to date and this approach is not yet generally accepted as a standard procedure. In our study, new finding is that we had changed the port sites as follows: the SILS port was positioned at the site of the proposed temporally right iliac-fossa ileostomy (2.5-cm incision), and an additional 5-mm trocar was inserted in the umbilicus. This ports setting is different from other studies that SILS port

was used through a 2.5-cm intra-umbilical incision, and a 12-mm port was placed in the right iliac fossa. In this study, we discovered that umbilical pain was extremely reduced compared to 2.5-cm intra-umbilical incision (data not shown), and patients who underwent this procedure were extremely satisfied with their nearly invisible scars, one behind the stoma and one at the umbilicus. Moreover, a three-stage approach is preferred in particularly debilitated UC patients. There are 5 studies that report the outcome of RPLS, however these reports were only one or two-stage approach. We selected procedures by patient's preoperative disease severity. In patients who underwent a previous SILS+1 STC, SILS+1 IPAA was performed successfully 6 months after the previous surgery without the need for extra wounds and the ability to fully pull down the mesentery into the pelvis because there was no adhesion in the abdomen caused by the previous surgery. This was also new finding because, there were no intra-abdominal adhesions, and no extra wounds were necessary because the previous stoma site was used to access the SILS port.

Despite the potential for improved short-term outcomes with SILS in patients with UC, compared with CLS (10, 14, 17, 18), the use of the SILS port alone is not feasible because the mobilization of the cecum and terminal ileum is challenging with the operative field immediately under the SILS port and the tip of the laparoscopic stapler can be bent to a maximum of only 45°, making it difficult to transect the lower rectum with sufficient distal margins from the umbilicus port. In the present study, we added one supportive port to solve this problem, and none of the patients required the addition of other ports, suggesting that one additional port is technically sufficient to perform restorative proctocolectomy with IPAA. Through the use of an additional port, parallel placement of the instruments is possible without interference between the scope and the surgeon's dominant hand, thus providing all of the benefits of CLS(19).

Recent studies demonstrated that both Harmonic Ace and Ligasure provide surgeons

ergonomy, and no significant differences were shown in operating time and complications(20). However, Harmonic Ace performed better in terms of charring and sticking compared with Ligasure which denatures collagen and elastin of vessels and connective tissue(21). It is documented that Harmonic Ace produces minimal lateral thermal spread when dissecting near vital structure(22). It is important for the surgeons who treated UC patients to be acquainted with properties of this device in order to handling severely inflamed tissues and optimize safety during surgery. We herein use Harmonic Ace more frequently for UC patients.

Previous studies have reported the preoperative use of steroids and immunosuppressive therapies to be an independent risk factor for complications after IPAA (23, 24); however, in the present study, the use of preoperative immunosuppressive therapies, such as tacrolimus or azathioprine, did not affect the occurrence of short-term complications. Additionally, with the absence of wounds during SILS+1 total colectomy and ileostomy, wound infection and incisional hernia are not likely possible complications of this otherwise major surgery. Postoperative complications included only one patient with MRSA enteritis, which resolved with conservative management.

Recently, D'Hondt et al reported that SILS sigmoidectomy was associated with better mental status compared to conventional multiport laparoscopic sigmoidectomy(25). Patients who underwent the SILS+1 port surgery had a nearly invisible umbilical scar (the SILS port was inserted at the site of the ileostomy), which might result in better postoperative mental status, because only two barely perceptible scars are produced, one behind the stoma and one at the umbilicus. All of the present patients were satisfied with the small skin incision, and the degree of satisfaction was very high during the post-discharge outpatient visits (data not shown). To make a definitive conclusion about this suggestion, an assessment of quality of life (including mental status) would be required.

Therefore, SILS+1 port surgery for UC is acceptable because of the cosmetic benefit for

young patients with benign disease.

This study has some limitations. First, the patient group was small, and the procedures were performed by the same specialist surgeon. We consider RPLS for UC is a challenging surgery and not yet generally accepted as standard procedure. To perform this procedure successfully, surgeons should have experience with more than 500 laparoscopic colorectal resection procedures and more than 50 SILS for colorectal diseases and have experience with and knowledge of patients with UC. The procedure is difficult and technically demanding and requires lots of concentration. The secret of RPLS for UC lies in learning conventional laparoscopic surgery first(26) and the feasibility of SILS+1 port surgery should be determined with additional patients with UC. Second, we did not compare the outcomes between CLS and SILS+1 port laparoscopic surgery. However, we recently reported that the postoperative neutrophil count with SILS+1 laparoscopy-assisted anterior resection (SILS+1-AR) was lower than with conventional laparoscopy-assisted anterior resection (C-AR) for rectal cancer (11); furthermore, a significant difference in body temperature was observed in the SILS+1-AR group on postoperative day 1, indicating less inflammation. This less inflammation caused by RPLS is new avenues for a true minimally invasive approach to inflammatory bowel disease patients. Finally, this approach is not appropriate for conditions requiring emergency attention, such as fulminant colitis, perforation, toxic megacolon, and major hemorrhage.

In conclusion, in selected patients treated by skilled surgeons, SILS+1 port surgery as reduced port surgery for UC is a feasible and safe procedure. To perform this procedure successfully, surgeons should be experienced in laparoscopic colorectal resection procedures and have experience with and knowledge of patients with UC. Additional studies are needed to compare the operative time, convalescence, and outcomes of SILS+1 port surgery with those of CLS, open surgery, and robotic surgery.

**Acknowledgments:** The authors declare no conflicts of interest in association with this manuscript and the authors declare no grant support. The contributions of authors are as follows. Conception and design: All authors contributed to the conception and design. Acquisition of data: All authors contributed to the acquisition of data. Analysis and interpretation of data: Futoshi Kawamata, Shigenori Homma, and Susumu Shibasaki. Drafting the article or revising it critically for important intellectual content: Futoshi Kawamata, Shigenori Homma, and Akinobu Taketomi. All authors had approval of the version to be published.

## References

1. Jarnerot G, Hertervig E, Friis-Liby I et al. Infliximab as rescue therapy in severe to moderately severe ulcerative colitis: a randomized, placebo-controlled study. *Gastroenterology*. 2005;128(7):1805-11.
2. Rutgeerts P, Sandborn WJ, Feagan BG et al. Infliximab for induction and maintenance therapy for ulcerative colitis. *N Engl J Med*. 2005;353(23):2462-76.
3. Fichera A, Silvestri MT, Hurst RD et al. Laparoscopic restorative proctocolectomy with ileal pouch anal anastomosis: a comparative observational study on long-term functional results. *J Gastrointest Surg*. 2009;13(3):526-32.
4. Zoccali M, Fichera A. Minimally invasive approaches for the treatment of inflammatory bowel disease. *World J Gastroenterol*. 2012;18(46):6756-63.
5. Causey MW, Stoddard D, Johnson EK et al. Laparoscopy impacts outcomes favorably following colectomy for ulcerative colitis: a critical analysis of the ACS-NSQIP database. *Surg Endosc*. 2013;27(2):603-9.
6. Kawamura J, Hasegawa S, Kawada K et al. Feasibility and safety of laparoscopic total proctocolectomy with ileal pouch-anal anastomosis for severe ulcerative colitis. *Asian J Endosc Surg*. 2013;6(4):271-8.
7. Hata K, Kazama S, Nozawa H et al. Laparoscopic surgery for ulcerative colitis: a review of the literature. *Surg Today*. 2014.
8. Wu XJ, He XS, Zhou XY et al. The role of laparoscopic surgery for ulcerative colitis: systematic review with meta-analysis. *Int J Colorectal Dis*. 2010;25(8):949-57.
9. Ahmed K, Wang TT, Patel VM et al. The role of single-incision laparoscopic surgery in abdominal and pelvic surgery: a systematic review. *Surg Endosc*. 2011;25(2):378-96.
10. Geisler DP, Kirat HT, Remzi FH. Single-port laparoscopic total proctocolectomy with ileal pouch-anal anastomosis: initial operative experience. *Surg Endosc*. 2011;25(7):2175-8.
11. Kawamata F, Homma S, Minagawa N et al. Comparison of Single-Incision Plus One Additional Port Laparoscopy-assisted Anterior Resection with Conventional Laparoscopy-assisted Anterior Resection for Rectal Cancer. *World J Surg*. 2014.
12. Bucher P, Pugin F, Morel P. Transumbilical single incision laparoscopic sigmoidectomy for benign disease. *Colorectal Dis*. 2010;12(1):61-5.
13. Fichera A, Zoccali M, Gullo R. Single incision ("scarless") laparoscopic total abdominal colectomy with end ileostomy for ulcerative colitis. *J Gastrointest Surg*. 2011;15(7):1247-51.

14. Gash KJ, Goede AC, Kaldowski B et al. Single incision laparoscopic (SILS) restorative proctocolectomy with ileal pouch-anal anastomosis. *Surg Endosc.* 2011;25(12):3877-80.
15. Nagpal AP, Soni H, Haribhakti S. Hybrid Single-incision Laparoscopic Restorative Proctocolectomy with Ileal Pouch Anal Anastomosis for Ulcerative Colitis. *Indian J Surg.* 2010;72(5):400-3.
16. Gu J, Stocchi L, Remzi FH et al. Total abdominal colectomy for severe ulcerative colitis: does the laparoscopic approach really have benefit? *Surg Endosc.* 2014;28(2):617-25.
17. Chatzizacharias NA, Torrente F, Brennan M et al. Single port laparoscopic subtotal colectomy and ileostomy in an adolescent with ulcerative colitis. *J Crohns Colitis.* 2012;6(10):1031-3.
18. Vestweber B, Galetin T, Lammerting K et al. Single-incision laparoscopic surgery: outcomes from 224 colonic resections performed at a single center using SILS. *Surg Endosc.* 2013;27(2):434-42.
19. Lim SW, Kim HJ, Kim CH et al. Umbilical incision laparoscopic colectomy with one additional port for colorectal cancer. *Tech Coloproctol.* 2013;17(2):193-9.
20. Tsamis D, Natoudi M, Arapaki A et al. Using Ligasure or Harmonic Ace(R) in Laparoscopic Sleeve Gastrectomies? A Prospective Randomized Study. *Obes Surg.* 2014.
21. Milsom J, Trencheva K, Monette S et al. Evaluation of the safety, efficacy, and versatility of a new surgical energy device (THUNDERBEAT) in comparison with Harmonic ACE, LigaSure V, and EnSeal devices in a porcine model. *J Laparoendosc Adv Surg Tech A.* 2012;22(4):378-86.
22. Hotta T, Takifuji K, Yokoyama S et al. Literature review of the energy sources for performing laparoscopic colorectal surgery. *World J Gastrointest Surg.* 2012;4(1):1-8.
23. Ferrante M, D'Hoore A, Vermeire S et al. Corticosteroids but not infliximab increase short-term postoperative infectious complications in patients with ulcerative colitis. *Inflamm Bowel Dis.* 2009;15(7):1062-70.
24. Yang Z, Wu Q, Wang F et al. Meta-analysis: effect of preoperative infliximab use on early postoperative complications in patients with ulcerative colitis undergoing abdominal surgery. *Aliment Pharmacol Ther.* 2012;36(10):922-8.
25. D'Hondt M, Pottel H, Devriendt D et al. SILS sigmoidectomy versus multiport laparoscopic sigmoidectomy for diverticulitis. *JLS.* 2014;18(3).
26. Dalton SJ, Ghosh A, Greenslade GL, Dixon AR. Laparoscopic colorectal surgery - why would you not want to have it and, more importantly, not be trained in it? A consecutive series of 500 elective resections with anastomoses. *Colorectal Dis.* 2011;13(2):144-9.

## Figure Captions

**Fig. 1** a: Port setting. 2.5-cm transumbilical incision was made, and the SILS port was inserted into a single umbilical incision. 12-mm port was inserted in right lower quadrant of the abdomen. b,c: The SILS port was positioned at the site of the proposed temporally right iliac-fossa ileostomy (2.5-cm incision) and an additional 5-mm trocar was inserted in the umbilicus. d: Postoperative view of a patient with SILS +1 port IPAA. The diverting loop ileostomy was created at the right iliac fossa at the port site and the pelvic drain was brought out through the umbilical port site.

**Fig. 2** a: Root of the inferior mesenteric artery was recognized, mesentery of sigmoid colon and rectum was detached from medial side approach. b: Splenic flexure and left colon dissection. c: Right colon was dissected from retroperitoneal approach. d: Specimen extracted from the SILS port site. e: Ileal pouch-anal anastomosis was performed intracorporeally with a EEA circular stapler. The pelvic drain was brought out through the umbilical port site.

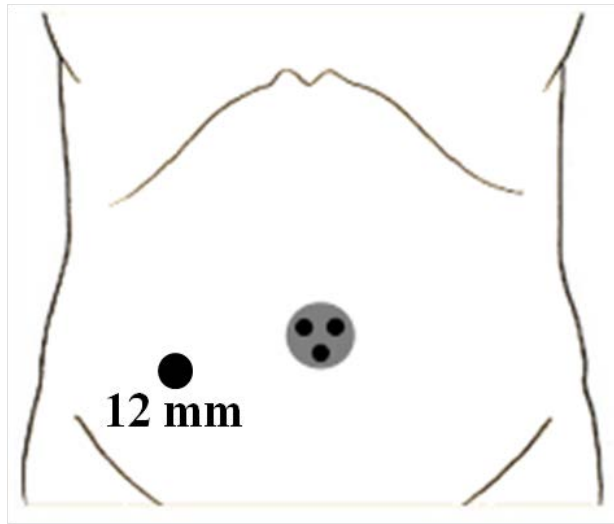
**Fig. 3** Surgical approaches for 10 cases of UC studied. IPAA; laparoscopic total proctocolectomy with ileal pouch-anal anastomosis, STC; laparoscopic subtotal colectomy, TPC; laparoscopic total proctocolectomy

**Supplemental Fig. 1** a: Circumferential muscular layer of the rectum was transected using an Echelon<sup>TM</sup> 60 Endopath stapling device. b: The data of length of remnant rectum.



# Figure 1

a



b

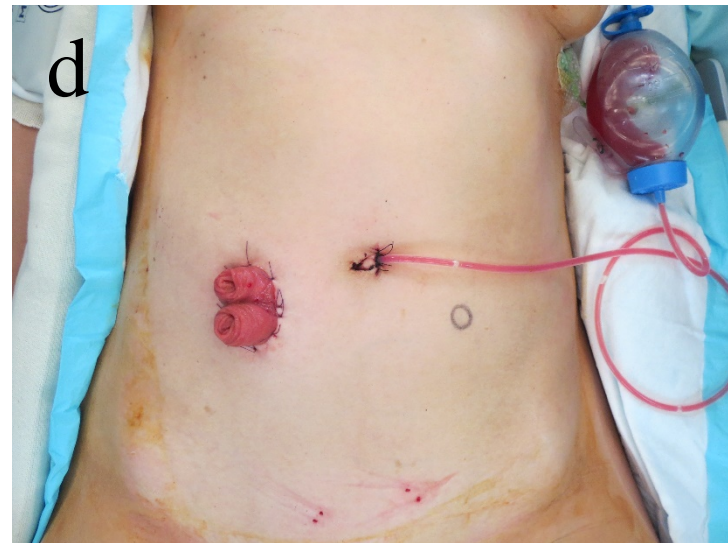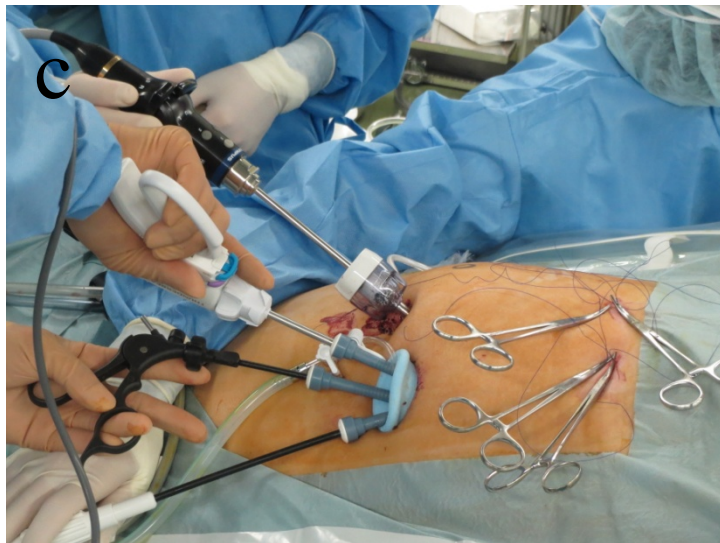
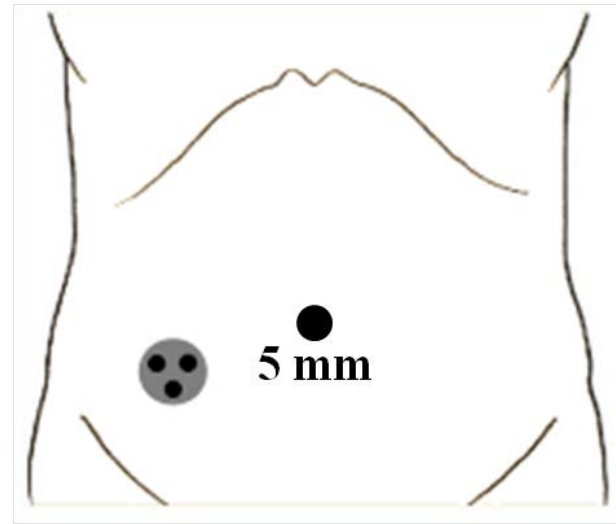


Figure 2

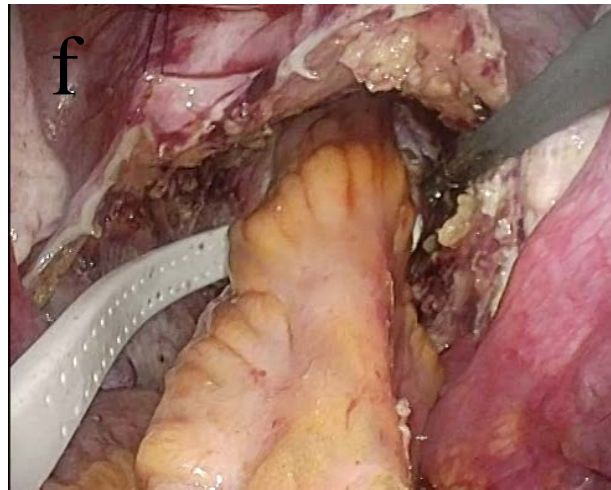
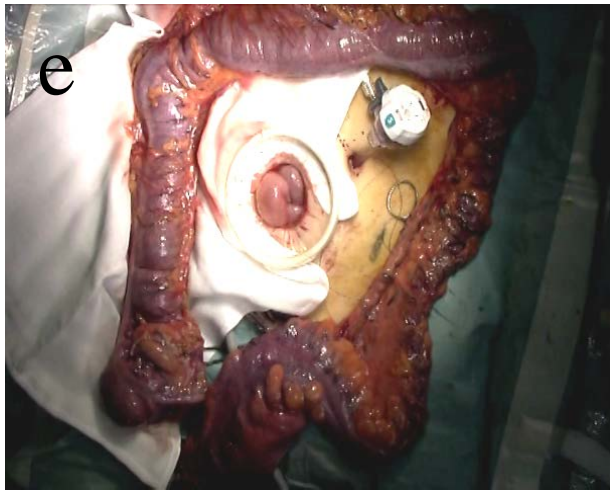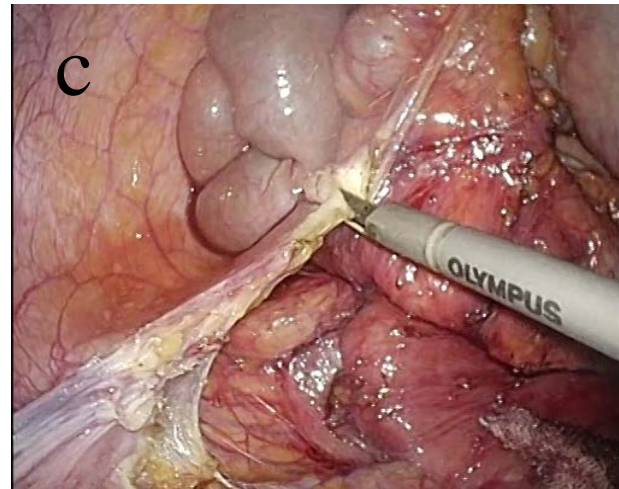
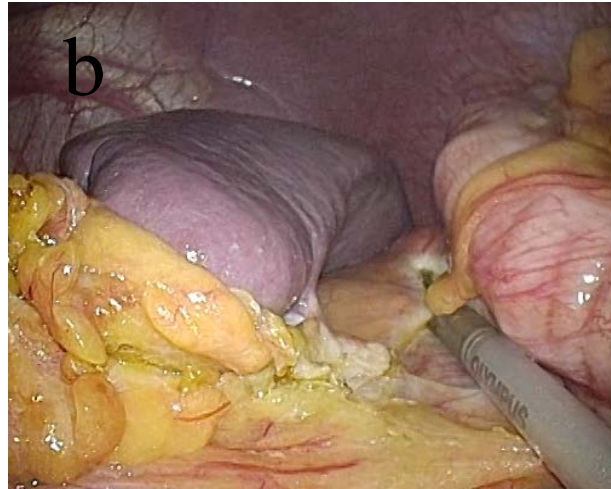

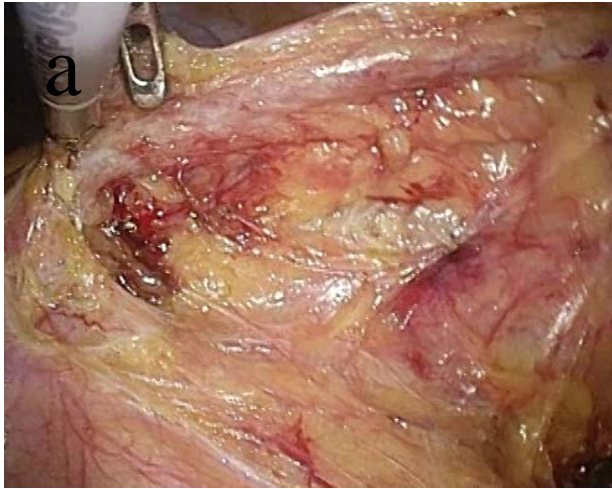
Figure 3

SILS + 1 Laparoscopic surgery for UC  
(N = 10)

2-stage SILS + 1  
Laparoscopic surgery (N = 6)

3-stage SILS + 1  
Laparoscopic surgery (N = 2)

SILS + 1 TPC  
(N = 2)

SILS + 1 IPAA (N = 6)

SILS+1STC, end ileostomy  
(N = 2)

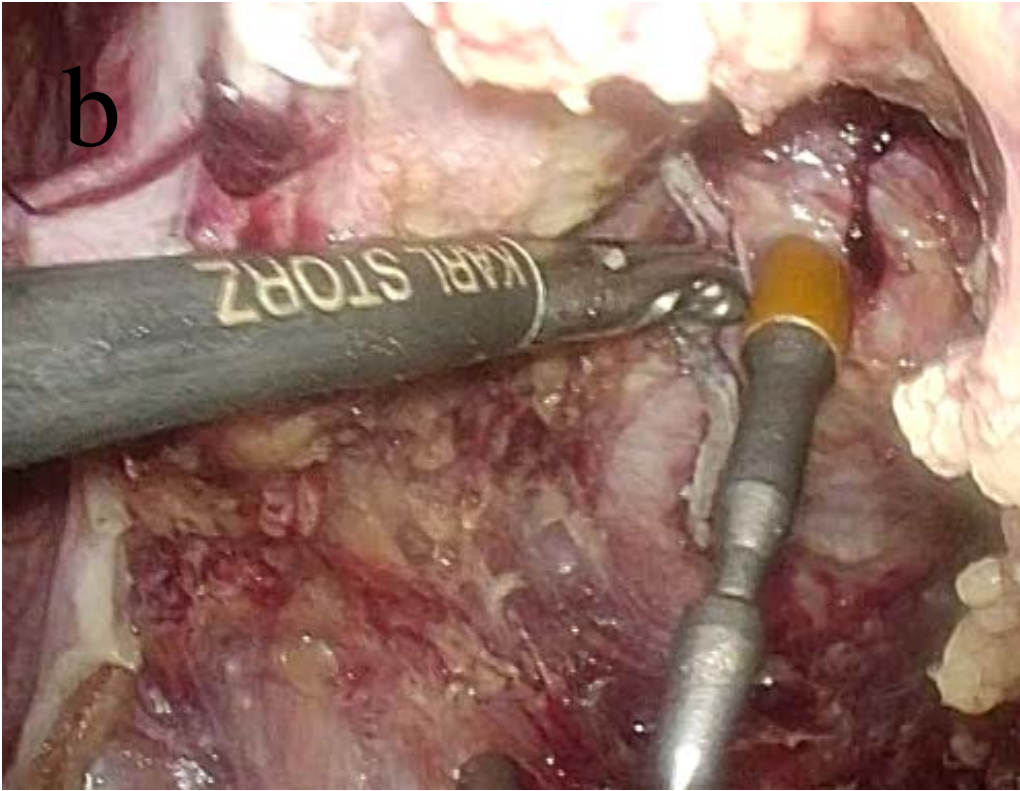
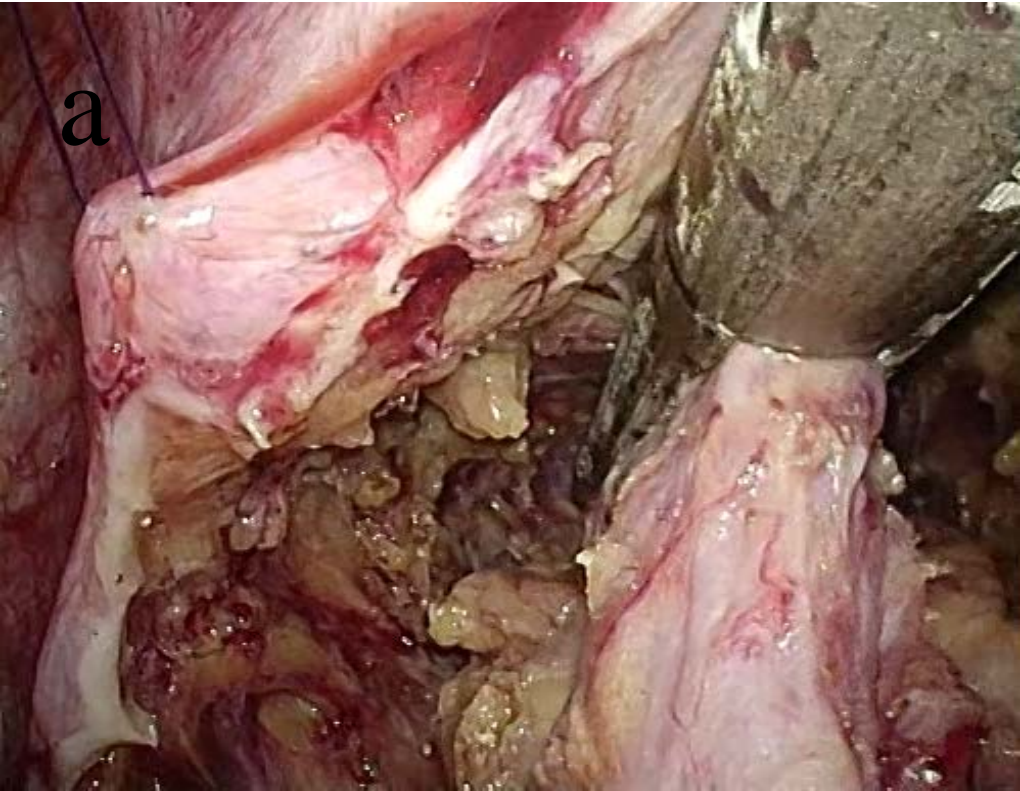
Ileostomy closed (N = 4)

SILS + 1 IPAA  
(N = 1)

Ileostomy  
closed (N = 1)



Supplemental Figure 1



**Table.1 Clinical characteristics of the 10 ulcerative patients**

Variable	Patient 1	Patient 2	Patient 3	Patient 4	Patient 5	Patient 6	Patient 7	Patient 8	Patient 9	Patient 10
1. Age (years)	25	38	22	37	26	20	53	39	30	30
2. Gender	Female	Male	Male	Male	Female	Female	Female	Male	Female	Female
3. BMI (kg/m <sup>2</sup> )	20.7	19.3	17.4	24.2	20.8	18.2	21.8	19.6	27.3	19.9
4. ASA score	2	2	2	2	2	3	3	3	3	2
5. Total steroid dose (g)	1.0	16.7	4.6	93.0	6.8	0.7	Steroid enema	39.3	10.0	20.0
6. Immunosuppressive therapy	AZA	AZA TAC	AZA TAC	None	TAC	TAC	TAC	AZA	AZA	AZA TAC
7. Use of Infliximab (times)	4	0	3	2	0	0	0	3	6	6
8. Cytapheresis	None	LCAP (10) GCAP (3)	LCAP (5) GCAP (1)	None	GCAP (15)	None	LCAP (7)	GCAP (5)	None	LCAP (15)

AZA; azathioprine, TAC; tacrolimus, LCAP; leukocyte apheresis, GCAP; granulocyte apheresis

**Table.2 Operative variables and surgical outcomes of 10 ulcerative patients**

<b>Variable</b>	<b>Patient 1</b>	<b>Patient 2</b>	<b>Patient 3</b>	<b>Patient 4</b>	<b>Patient 5</b>	<b>Patient 6</b>	<b>Patient 7</b>	<b>Patient 8</b>	<b>Patient 9</b>	<b>Patient 10</b>
<b>1. Port Selection</b>	SILS + 12 mm Fig.1a	SILS + 12 mm Fig.1a	SILS + 5 mm Fig.1b	SILS + 5 mm Fig.1b	SILS + 5 mm Fig.1b	SILS + 5 mm Fig.1b	SILS + 5 mm Fig.1b	SILS + 5 mm Fig.1b	SILS + 5 mm Fig.1b	SILS + 5 mm Fig.1b
<b>2.Operation Procedure</b>	RPC IPAA	RPC IPAA	RPC IPAA	TPC	RPC IPAA	STC (3-stage)	RPC IPAA	TPC	STC (3-stage)	RPC IPAA
<b>3. Ileocolic anastomosis</b>	hand-sewn	hand-sewn	DST	None	DST	None	DST	None	None	DST
<b>4. Operation time (min)</b>	465	322	371	391	363	382	253	389	308	387
<b>5. Estimated blood loss (mL)</b>	100	0	10	50	50	0	0	0	80	0
<b>6. Return of stoma function (days)</b>	1	1	1	1	1	1	1	1	1	1
<b>7. Complications</b>	MRSA enteritis	None	None	None	None	None	None	None	None	None
<b>8. Hospital stay (days)</b>	29	28	23	23	29	7	21	15	12	20

RPC; restorative proctocolectomy, IPAA: ileal pouch anal anastomosis, TPC; total proctocolectomy, STC; subtotal colectomy  
DST; double stapling technique

**Table.3 Short-term outcomes following reduced port surgery for ulcerative colitis**

<b>Author</b>	<b>Year</b>	<b>N</b>	<b>Time (min)</b>	<b>Method</b>	<b>Blood loss (g)</b>	<b>Complications (numbers)</b>	<b>Return of bowel function (day)</b>	<b>LOH (day)</b>	<b>Ileostomy closed (numbers)</b>
Nagpal AP	2010	1	256	SILS+2 IPAA	100	0	2	7	NA
Geisler DP	2011	5	153	SILS-IPAA	100	SBO (2)	2	4	5
Gash KJ	2011	10	185	SILS-IPAA	NA	surgical emphysema (1)	NA	3	9
Fichera A	2011	10	139	SILS-TPC	100	0	1.6	5.1	NA
Chatzizacharias NA	2012	1	210	SILS-STC	30	0	1	6	1
Our case	2015	10	363	SILS+1 IPAA	29	MRSA enteritis (1)	1	20.7	5
				SILS+1 STC					
				SILS+1 TPC					

LOH; length of postoperative hospital stay, IPAA: ileal pouch anal anastomosis, NA; not available, SBO; small-bowel obstruction, TPC; total proctocolectomy, STC; subtotal colectomy