



Title	Characteristics of idiopathic ventricular tachycardia originating above the pulmonary valve
Author(s)	Yokoshiki, Hisashi; Mizukami, Kazuya; Mitsuyama, Hirofumi; Watanabe, Masaya; Tenma, Taro; Tsutsui, Hiroyuki
Citation	Heart and vessels, 31(4), 599-607 https://doi.org/10.1007/s00380-015-0653-5
Issue Date	2016-04
Doc URL	http://hdl.handle.net/2115/64948
Rights	The final publication is available at link.springer.com
Type	article (author version)
File Information	HeartVessels31_599.pdf



[Instructions for use](#)

**Characteristics of Idiopathic Ventricular Tachycardia Originating Above the
Pulmonary Valve**

Hisashi Yokoshiki, MD, PhD, Kazuya Mizukami, MD, Hirofumi Mitsuyama,
MD, PhD, Masaya Watanabe, MD, PhD, Taro Tenma, MD, Hiroyuki Tsutsui,
MD, PhD

Department of Cardiovascular Medicine, Hokkaido University Graduate
School of Medicine

Address for correspondence: Hisashi Yokoshiki MD, PhD

Department of Cardiovascular Medicine, Hokkaido University Graduate
School of Medicine, Kita-15, Nishi-7, Kita-ku, Sapporo 060-8638, Japan.

Phone: 81-11-706-6973

Fax: 81-11-706-7874

E-mail: yokoshh@med.hokudai.ac.jp

Abstracts

Panoptic studies of ventricular tachycardia (VT) originating above the pulmonary valve are scarce. The purpose of this study is to clarify the characteristic of idiopathic VT arising above pulmonary valve. We analyzed 15 consecutive patients with idiopathic VT that was successfully abolished by catheter ablation at the right ventricular outflow tract (RVOT-VT, n = 11) and above the pulmonary valve (PA-VT, n = 4). Incidence of syncope was higher in PA-VT than RVOT-VT (100 % vs 27 %, $P < 0.05$) and polymorphic VT was also more prevalent in PA-VT (75 % vs 0 %, $P < 0.05$). The coupling interval (315 ± 29 ms vs 449 ± 32 ms, mean \pm SE) at the onset of VT and minimum cycle length (CL) (192 ± 13 ms vs 344 ± 37 ms) during VT were shorter in PA-VT (both $P < 0.05$). Among 12-lead ECG parameters, only R-wave amplitude in lead II was different between groups (2.05 ± 0.17 mV in PA-VT vs 1.44 ± 0.05 mV in RVOT-VT, $P < 0.005$). At the successful ablation site, the activation time from the onset of QRS complex did not differ between groups (-37 ± 3 ms vs -31 ± 4 ms, $P = 0.405$), whereas the amplitude of intracardiac electrograms was significantly lower in PA-VT (0.83 ± 0.38 mV vs 2.39 ± 0.36 mV, $P < 0.05$). Although the number of patients in this study is limited, VT originating above the pulmonary valve demonstrated rapid excitation and often degenerated into polymorphic VT, suggesting its malignant electrophysiological characteristics.

Keywords: ventricular tachycardia; polymorphic; pulmonary valve; syncope; catheter ablation

Introduction

Right ventricular outflow tract (RVOT) is one of the most common anatomical area where idiopathic ventricular tachycardia (VT) arises.[1] Timmermans et al first reported a case of idiopathic VT originating above pulmonary valve (PA-VT) in 2002[2] and subsequently summarized 6 cases of PA-VTs which exhibited rapid excitation (mean cycle length 292 ms) with a monomorphic type.[3] After this initial study, surface ECG characteristics and / or intracardiac electrograms regarding premature ventricular contraction (PVC) / VT originating above pulmonary valve were investigated.[4-7] However, little is known about the characteristics of PA-VT in terms of clinical symptoms and morphological alterations during VT.

Due to the anatomical vicinity, the QRS morphology of PA-VT is similar to that originating from RVOT with a left bundle branch block (LBBB)-like QRS morphology and inferior axis. Compared to VTs or premature ventricular contractions (PVCs) arising from RVOT (RVOT-VT/PVC), R-wave amplitudes on inferior ECG leads, aVL/aVR ratio of Q-wave amplitude, and R/S ratio on lead V2 were larger in the PA-VT/PVCs.[4] Although these ECG parameters were significantly different between the groups, there are still some overlaps in each value, thereby precluding us from determining a clear cutoff.

The present study is aimed to clarify the electrophysiological and

clinical characteristics of PA-VT by comparing to those of RVOT-VT that is one of the most common idiopathic VTs presenting a QRS morphology of LBBB shaped and inferior axis.

Methods

Subjects

We performed a retrospective review of 15 consecutive patients with idiopathic VT that was successfully abolished by catheter ablation at the right ventricular outflow tract (RVOT-VT, n = 11) and above the pulmonary valve (PA-VT, n = 4) from August 2005 to March 2013 in Hokkaido University Hospital. No signs of arrhythmogenic right ventricular cardiomyopathy/dysplasia (ARVC/D)[8] such as right ventricular (RV) enlargement, regional RV akinesia, dyskinesia, or aneurysm were detected by echocardiogram in any patients. Coronary angiography was performed in all patients in PA-VT group and 6 patients in RVOT-VT group, and no significant stenotic lesions of coronary artery were confirmed. The study was approved by the Ethics Committee of Hokkaido University Hospital.

ECG analysis

At least one strip of surface ECG at the initiation of VT was available in all patients. To assess the morphological characteristics of 12-lead ECG, the first QRS complex during VT was analyzed. The diagnosis of polymorphic VT was based on the European Heart Rhythm Association / Heart Rhythm Society Expert Consensus[9], which defines it as a continuously changing QRS configuration from beat to beat.

Electrophysiological study

After obtaining written informed consent, the electrophysiological

study was performed with no antiarrhythmic agents in the fasting state. In most cases, a quadripolar catheter and a 20-polar catheter were positioned in the right ventricular apex (RVA) and the RVOT, respectively. Target ventricular arrhythmias were induced spontaneously or by intravenous administration of isoproterenol at a dose of 1 – 4 μ g / min. Isoproterenol was required for the induction of VT in 82 % (9 out of 11 patients) in RVOT-VT group and 75% (3 out of 4 patients) in PA-VT group.

Ablation procedure

A 4 mm-tip ablation catheter (NaviStar, Biosense-Webster, Inc., Diamond Bar, CA, USA, or Mariner, Medtronic, Minneapolis, MN, USA) was inserted into the RV via right femoral vein[10, 11]. Since all patients exhibited PVCs similar to the first QRS complex during VT, the earliest activation site of the PVC was usually targeted. RF power was applied at a maximum of 35 W provided that temperature recorded from the electrode did not reach more than 55 °C. Energy application at one site was usually terminated for 60 sec. A successful ablation site in patients of PA-VT group was confirmed by the right and left anterior oblique views of angiographies of the pulmonary artery or right ventricle.

Statistical analysis

All data are expressed as means \pm SE. Simple between-group analyses were conducted using a Student's t test. Categorical variables were compared using Chi-square test. Differences with $P < 0.05$ were considered significant. Statview version 5.0 for Windows (SAS Institute Inc, Cary, NC,

USA) was used for all statistical analyses.

Results

Patient characteristics

The characteristics of 15 patients are shown in **Table 1**. All patients in PA-VT group had a history of syncope, which was significantly higher than that in RVOT-VT group (27%). Higher incidence of polymorphic VT was also observed in PA-VT group (75 % vs 0%, $P = 0.0088$). One patient in PA-VT group had been resuscitated from ventricular fibrillation (VF) and had undergone implantable cardioverter-defibrillator (ICD) implantation.

Electrocardiographic Findings

A representative VT in a patient from RVOT-VT group and examples of the VTs in 4 patients from PA-VT group are shown in **Fig. 1**. Although all VTs initially had a LBBB-shaped and inferior axis, 3 VTs in PA-VT group (patients 1, 2, and 4) developed polymorphic QRS configurations. Sudden changes in the cycle length were seen in 3 VTs (patients 1, 2 and 3) of PA-VT group.

The mean cycle length of VT tended to be shorter in PA-VT group ($P = 0.051$) (**Table 2**). The minimum cycle length during VT ($P = 0.032$) and the coupling interval at the onset of VT ($P = 0.034$) was significantly shorter in PA-VT group than in RVOT-VT group. The prematurity index, which was reported to be a predictor of polymorphic VT,[12] did not differ between the groups (**Table 2**).

Amplitude of R-wave in lead II at the onset of VT was higher in PA-VT group compared to that in RVOT-VT group (**Table 3**). However, there were no significant differences in the ECG characteristics such as QRS duration, R/S ratio and R-wave duration index in lead V₂, aVL/aVR of Q-wave amplitude, and the incidence of positive QRS wave in lead I [4, 13, 14] (**Table 3**).

Electrophysiological characteristics of ventricular myocardial extension into pulmonary artery

During polymorphic VTs, mapping above the pulmonary valve was performed in one patient of PA-VT group (patient 4). When the ablation catheter was positioned above the pulmonary valve (left semilunar valve), a characteristic sharp potential, which would represent activation from the myocardial extensions into the pulmonary artery, [2, 3, 5-7] was recorded by the distal bipolar electrodes of the ablation catheter (ABL d), in association with emergence of automaticity with a cycle length about 600 ms (**Fig. 2**). Subsequent rapid ventricular activations exhibited a polymorphic VT, in which a sharp potential preceded the onset of QRS complex about 30 ms (**Fig. 2B**). In addition, subtle changes in the sharp potential were observed in terms of morphology and duration. For example, a small q wave of the sharp potential disappeared during the rapid ventricular activation, and its duration was prolonged in accordance with a shortening of preceding coupling interval (**Fig. 2B**). This observation was also confirmed when the

mapping was performed above the anterior semilunar valve (**Fig. 2C**).

However, we should recognize that it is difficult to differentiate the spontaneous premature beats and catheter related ectopy when the prematurity exceeds -30 ms.

To evaluate the rate dependent conductivity of ventricular myocardium above the pulmonary valve, pulmonary artery potential (PAP) duration, defined as the duration of a sharp potential, was plotted against preceding coupling interval (**Fig. 3**). It appears that the myocardium above the pulmonary valve has a property of decremental conduction when the excitation interval becomes less than 400 ms. Rapid pacing above the left (posterior) semilunar valve reproduced a polymorphic QRS change with a significant delay between the pacing spike and the QRS onset (initial 5 pacing beats at S1 = 220 ms) (**Fig. 4**).

Ablation results

Ablation in PA-VT group was successfully performed at the posterior septal site in 2 patients (patients 1 and 3) and the anterior septal site in 2 patients (patients 2 and 4). The distance between the successful ablation site in the pulmonary artery and bottom of the cusp of pulmonary valve was 13 ± 1 mm (n = 4). The local activation time preceded the QRS onset during target PVC/VT by 37 ± 3 ms in PA-VT group and 31 ± 4 ms in RVOT-VT group (P = 0.405). Amplitude of the bipolar electrograms during PVC/VT at the successful ablation site was 0.83 ± 0.38 mV in PA-VT group and 2.39 ± 0.36

mV in RVOT-VT group ($P = 0.031$). The interval free from recurrence of VT during the follow-up period were similar between PA-VT group and RVOT-VT group (74 ± 12 months vs 45 ± 9 months; $P = 0.12$).

Discussion

The present study is the first to demonstrate that idiopathic PA-VT is prone to develop polymorphic QRS configurations. This is in agreement with a recent case report describing unusual polymorphic VT originating from the pulmonary artery.[15] Based on these findings, idiopathic PA-VT could be classified as a malignant entity in terms of the polymorphic QRS change and high incidence of syncope.

Idiopathic ventricular arrhythmias originating around RVOT are generally recognized as benign.[16, 17] In contrast, it has been reported that a small number of patients develop polymorphic VT and /or VF, thereby suggesting the malignant entity.[12, 13, 18-20] There are several studies attempting to differentiate such a malignant form of RVOT-VT from a benign one. Viskin et al reported that the malignant type had short-coupled premature extrasystoles which initiated the polymorphic VT and / or VF.[20] In contrast, Noda et al found that the malignant type exhibited a shorter cycle length of VT with no significant differences in the coupling interval.[18] In the present study, both the coupling interval and the (minimum) cycle length of VT were significantly shorter in the “malignant” PA-VT compared to the “benign” looking RVOT-VT.

Recently, it was reported that the prematurity index, defined as the ratio of the coupling interval of the first VT beat to the preceding sinus cycle length (R-R interval) just before the VT, was significantly smaller in the

idiopathic RVOT-VT patients with polymorphic QRS morphology versus those with monomorphic one.[12] However, in this study, the prematurity index in PA-VT group was similar to that in RVOT-VT group (**Table 2**). This is largely because that the polymorphic changes were prone to occur when the preceding R-R interval was prolonged in the patients from the previous study by Igarashi et al (mean \pm SD of R-R interval: 831 ± 152 ms),[12] implying the bradycardia-dependent provocation. This may prompt us to consider the mechanisms related to the electrophysiological abnormalities in ventricular myocardium, such as a pause-dependent initiation of polymorphic VT / VF in ICD recipients[21] and long-short R-R interval cycle sequences at the onset of torsades de pointes.[22] In contrast, the “malignant” PA-VT in this study appeared to be provoked by the catecholaminergic / tachycardia – dependent mechanism, because the preceding R-R interval was markedly abbreviated (**Table 2**). Based on these studies[12, 13, 18, 20] and ours, there might be at least two types of idiopathic polymorphic VT / VF arising from RVOT area.

Regarding the 12-lead ECG characteristics, R wave amplitude in lead II was greater in PA-VT group compared to RVOT-VT group (**Table 3**), consistent with a previous study.[4] On the other hand, no significant differences were detected in other parameters including aVL/aVR ratio of Q-wave amplitude and R/S ratio on lead V2 (**Table 3**), probably because of a small number of patients in our study. A recent study reported that an initial PVC with positive QRS complex in lead I was observed in about 70 % (10 out

of 14) of patients with idiopathic polymorphic VT / VF arising from RVOT.[13] The authors proposed the positive QRS complex in lead I as a malignant sign in RVOT-VT. The incidence of positive QRS complex in lead I in PA-VT group was 50 % (2 out of 4), that was comparable to that in RVOT-VT group in the present study (**Table 3**).

Hasdemir et al reported that, in 17 % (16 out of 95) of human hearts obtained at autopsy, ventricular myocardial extensions (VME) above the pulmonary valve was present with the maximum length up to 6 mm and the average length of 3.25 ± 1.3 mm.[23] Fibrosis and fatty tissue between the layers of VME was observed with high incidence (about 70%), thereby implicating the possible arrhythmogenic substrate with conduction disturbance. However, these results were obtained from subjects without any history of cardiac disease or symptoms. In patients with PA-VT, such VME into the pulmonary artery could be more evident and widely spread beyond the ventriculo-arterial junction.

This speculation was supported by the mapping above pulmonary valve, during which a sharp potential representing activation of VME into pulmonary artery was observed at the late phase [3, 5] or middle phase [6, 7] of the QRS complex during sinus rhythm and it preceded the QRS onset during VT/PVCs in all patients of PA-VT group. In our case, the presumable pulmonary artery potential was observed at the middle of QRS complex during sinus rhythm (**Fig. 2**), as reported previously [6, 7]. The timing of its activation in reference to QRS complex (during sinus rhythm) could depend

on distance above the pulmonary valve, because the sharp potential in representative cases by Timmermans et al [3] and Srivathsan et al [5] was recorded by the ablation catheter placed 2 cm and more above the valve. In addition to a sharp potential, Timmermans et al also observed a fragmented electrogram at the successful ablation site above pulmonary valve in one out of 6 patients.[3] This observation and the histological evidence of inhomogeneous distribution of VME[23] suggest that myocardial activation above pulmonary valve may be delayed in association with increase in excitation frequency.

In order to investigate the mechanism of polymorphic QRS changes in PA-VT, we defined a sharp potential recorded above pulmonary valve as pulmonary artery potential (PAP), and the duration and configuration of PAP obtained by bipolar electrodes were evaluated. During the polymorphic change of PA-VT in one patient, the PAP duration was increased when coupling interval became less than about 400 ms (**Fig. 3**), indicating a decremental property of VME in the pulmonary artery. The directional change in excitation of VME was also speculated, because the configuration of bipolar electrogram of PAP was altered during the polymorphic VT (**Figs 2B and 2C**). In addition, rapid pacing above pulmonary valve mimicked the polymorphic VT with a significant pacing delay (**Fig. 4**). On the other hand, it was shown that a QRS morphology of PA-VT/PVCs often changed following catheter ablation at the attachment just below pulmonary valve, and authors proposed the possible multiple propagation pathways from VME of

pulmonary artery to RVOT.[6] Based on these observations, rapid focal excitation from VME above pulmonary valve may produce the conduction delay (due to decremental property) with its directional changes in the myocardial sleeve, thereby altering the exit sites at the ventriculo-arterial junction that can develop polymorphic VT (**Fig. 5**).

Limitations

There are several limitations to be acknowledged in the present study. First, this study was a retrospective study in a single center, and may therefore include some biases. In general, RVOT-VT is considered to be the most common form of idiopathic VT. In this regard, the ration between PA-VT (4 patients: 27%) and RV-OT patients (11 patients: 73%) in the present study may be unusual. Second, the precise location of ablation site was not clear in RVOT-VT patients, as angiography was not performed in most of these patients. A recent study that used intracardiac echography demonstrated that myocardial extension above the pulmonary valve was found in about 90 % of subjects and that nearly half (46%) of the RVOT arrhythmias foci was localized beyond the valve in the pulmonary artery[24]. However, experienced operators can usually recognize the catheter position when it moved into the pulmonary artery. Third, the direct link between polymorphic QRS changes during PA-VT and propensity to degeneration into polymorphic VT / VF has not been proven, although one patient in PA-VT group had been resuscitated from VF (Table 1). The shorter cycle length in

PA-VT (Table 2) itself may explain higher incidence of syncope. Fourth, the number of PA-VT patients was as small as only 4. In addition, we implemented a detailed mapping during polymorphic VT only in one patient. This is due to the retrospective nature of the present study and inability of reproducible induction of polymorphic VT in all 4 patients. Therefore, the extrapolation of our findings to general population affected with idiopathic PA-VT should be made with caution. Especially, the proposed mechanism of polymorphic QRS change during PA-VT (**Fig. 5**) would require further evaluation in more patients in the future study.

Conclusions

Idiopathic VT originating above the pulmonary valve demonstrates rapid excitation and could degenerate into polymorphic VT, indicating a malignant entity among RVOT-VT. Since it is difficult to differentiate PA-VT from “benign” RVOT-VT by the QRS morphology, careful mapping above pulmonary valve would be required in patients with serious clinical symptoms such as syncope.

Acknowledgments

We thank Dr. Masayuki Sakurai, Director of Hokko Memorial Hospital, for constant encouragement of this study.

Conflict of interest

We declare that we have no conflict of interest.

References

1. Lerman BB, Stein KM, Markowitz SM (1997) Mechanisms of idiopathic left ventricular tachycardia. *J Cardiovasc Electrophysiol* 8:571-583
2. Timmermans C, Rodriguez LM, Medeiros A, Crijns HJ, Wellens HJ (2002) Radiofrequency catheter ablation of idiopathic ventricular tachycardia originating in the main stem of the pulmonary artery. *J Cardiovasc Electrophysiol* 13:281-284
3. Timmermans C, Rodriguez LM, Crijns HJ, Moorman AF, Wellens HJ (2003) Idiopathic left bundle-branch block-shaped ventricular tachycardia may originate above the pulmonary valve. *Circulation* 108:1960-1967
4. Sekiguchi Y, Aonuma K, Takahashi A, Yamauchi Y, Hachiya H, Yokoyama Y, Iesaka Y, Isoe M (2005) Electrocardiographic and electrophysiologic characteristics of ventricular tachycardia originating within the pulmonary artery. *J Am Coll Cardiol* 45:887-895
5. Srivathsan KS, Bunch TJ, Asirvatham SJ, Edwards WD, Friedman PA, Munger TM, Hammill SC, Cha YM, Brady PA, Jahangir A, Bradley DJ, Rea RF, Packer DL, Shen WK (2008) Mechanisms and utility of discrete great arterial potentials in the ablation of outflow tract ventricular arrhythmias. *Circ Arrhythm Electrophysiol* 1:30-38
6. Tada H, Tadokoro K, Miyaji K, Ito S, Kurosaki K, Kaseno K, Naito S, Nogami A, Oshima S, Taniguchi K (2008) Idiopathic ventricular arrhythmias arising from the pulmonary artery: prevalence, characteristics, and topography of the arrhythmia origin. *Heart Rhythm* 5:419-426
7. Yamashina Y, Yagi T, Namekawa A, Ishida A, Sato H, Nakagawa T, Sakuramoto M, Sato E, Yambe T (2010) Clinical and electrophysiological difference between idiopathic right ventricular outflow tract arrhythmias and pulmonary artery arrhythmias. *J Cardiovasc Electrophysiol* 21:163-169
8. Marcus FI, McKenna WJ, Sherrill D, Basso C, Bauce B, Bluemke DA, Calkins H, Corrado D, Cox MG, Daubert JP, Fontaine G, Gear K, Hauer R, Nava A, Picard MH, Protonotarios N, Saffitz JE, Sanborn DM, Steinberg JS, Tandri H, Thiene G, Towbin JA, Tsatsopoulou A, Wichter T, Zareba W (2010) Diagnosis of arrhythmogenic right ventricular cardiomyopathy/dysplasia: proposed modification of the task force criteria. *Circulation* 121:1533-1541
9. Aliot EM, Stevenson WG, Almendral-Garrote JM, Bogun F, Calkins CH, Delacretaz E, Della Bella P, Hindricks G, Jais P, Josephson ME, Kautzner J, Kay GN, Kuck KH, Lerman BB, Marchlinski F, Reddy V, Schalij MJ, Schilling R, Soejima K, Wilber D (2009) EHRA/HRS Expert Consensus on Catheter Ablation of Ventricular Arrhythmias: developed in a partnership with the European Heart Rhythm Association (EHRA), a Registered Branch of the European Society of Cardiology (ESC), and the Heart Rhythm Society (HRS); in collaboration with the American College of Cardiology (ACC) and the American Heart Association (AHA). *Heart Rhythm* 6:886-933
10. Abe Y, Sumitomo N, Okuma H, Nakamura T, Fukuhara J, Ichikawa R, Matsumura M, Miyashita M, Kamiyama H, Ayusawa M, Watanabe M, Joo K, Makita N, Horie M (2014) Successful control of life-threatening polymorphic ventricular tachycardia by radiofrequency catheter ablation in an infant. *Heart Vessels* 29:422-426
11. Yokoshiki H, Mitsuyama H, Watanabe M, Mizukami K, Tsutsui H (2014) Suppression of

ventricular fibrillation by electrical modification of the Purkinje system in hypertrophic cardiomyopathy. *Heart Vessels* 29:709-717

12. Igarashi M, Tada H, Kurosaki K, Yamasaki H, Akiyama D, Sekiguchi Y, Kuroki K, Machino T, Murakoshi N, Nakata Y, Kuga K, Nogami A, Aonuma K (2012)

Electrocardiographic determinants of the polymorphic QRS morphology in idiopathic right ventricular outflow tract tachycardia. *J Cardiovasc Electrophysiol* 23:521-526

13. Kurosaki K, Nogami A, Shirai Y, Kowase S (2013) Positive QRS complex in lead I as a malignant sign in right ventricular outflow tract tachycardia: comparison between polymorphic and monomorphic ventricular tachycardia. *Circ J* 77:968-974

14. Ouyang F, Fotuhi P, Ho SY, Hebe J, Volkmer M, Goya M, Burns M, Antz M, Ernst S, Cappato R, Kuck KH (2002) Repetitive monomorphic ventricular tachycardia originating from the aortic sinus cusp: electrocardiographic characterization for guiding catheter ablation. *J Am Coll Cardiol* 39:500-508

15. Lee DI, Park SW, Kook H, Kim W, Kim DH, Lee S, Oh SK, Kim YH (2013) Unusual polymorphic ventricular tachycardia originating from the pulmonary artery. *Korean Circ J* 43:119-122

16. Belhassen B (2005) Radiofrequency ablation of "benign" right ventricular outflow tract extrasystoles: a therapy that has found its disease? *J Am Coll Cardiol* 45:1266-1268

17. Gaita F, Giustetto C, Di Donna P, Richiardi E, Libero L, Brusin MC, Molinari G, Trevisani G (2001) Long-term follow-up of right ventricular monomorphic extrasystoles. *J Am Coll Cardiol* 38:364-370

18. Noda T, Shimizu W, Taguchi A, Aiba T, Satomi K, Suyama K, Kurita T, Aihara N, Kamakura S (2005) Malignant entity of idiopathic ventricular fibrillation and polymorphic ventricular tachycardia initiated by premature extrasystoles originating from the right ventricular outflow tract. *J Am Coll Cardiol* 46:1288-1294

19. Shimizu W (2009) Arrhythmias originating from the right ventricular outflow tract: how to distinguish "malignant" from "benign"? *Heart Rhythm* 6:1507-1511

20. Viskin S, Rosso R, Rogowski O, Belhassen B (2005) The "short-coupled" variant of right ventricular outflow tract tachycardia: a not-so-benign form of benign ventricular tachycardia? *J Cardiovasc Electrophysiol* 16:912-916

21. Taylor E, Berger R, Hummel JD, Dinerman JL, KenKnight B, Arria AM, Tomaselli G, Calkins H (2000) Analysis of the pattern of initiation of sustained ventricular arrhythmias in patients with implantable defibrillators. *J Cardiovasc Electrophysiol* 11:719-726

22. Ben-David J, Zipes DP (1993) Torsades de pointes and proarrhythmia. *Lancet* 341:1578-1582

23. Hasdemir C, Aktas S, Govsa F, Aktas EO, Kocak A, Bozkaya YT, Demirbas MI, Ulucan C, Ozdogan O, Kayikcioglu M, Can LH, Payzin S (2007) Demonstration of ventricular myocardial extensions into the pulmonary artery and aorta beyond the ventriculo-arterial junction. *Pacing Clin Electrophysiol* 30:534-539

24. Liu CF, Cheung JW, Thomas G, Ip JE, Markowitz SM, Lerman BB (2014) Ubiquitous myocardial extensions into the pulmonary artery demonstrated by integrated intracardiac echocardiography and electroanatomic mapping: changing the paradigm of idiopathic right ventricular outflow tract arrhythmias. *Circ Arrhythm Electrophysiol* 7:691-700

Figure Legends

Figure 1. Twelve-Lead ECGs of Ventricular Tachycardia Originating from Right Ventricular Outflow Tract (RVOT-VT) and above Pulmonary Valve (PA-VT).

A. A patient with a typical RVOT-VT exhibited a monomorphic VT showing a LBBB-shaped and inferior axis type. **B.** Three patients (Patients 1, 2, and 4) with PA-VT had polymorphic VTs. A fast monomorphic VT with a sudden change in its cycle length occurred in one patient (Patient 3).

Figure 2. Twelve-Lead ECG and Intracardiac Electrogram (EGM) during Polymorphic VT.

A. Accelerated ventricular rhythm and subsequent polymorphic VT occurred during the mapping above pulmonary valve by a quadripolar ablation catheter. After this event, couplets and triplets were repetitively observed. Intracardiac bipolar and unipolar electrograms given in panel **B** correspond temporally to the ECG marked by red bold lines. **B.** Intracardiac EGMs above left (posterior) semilunar valve during polymorphic VT are shown. Each interval of QRS complex (RR interval) (ms) and activation time (ms) of EGMs recorded by distal pairs of the ablation catheter (ABL d) relative to the QRS onset are shown in black. Numbers in red indicate duration of the presumable pulmonary artery potential (PAP) recorded by ABL d. Note that the morphological change and prolongation of PAP in association with an

alteration of RR interval. An approximate position of the ablation catheter is marked as a blue circle in the cartoon depicting the base of pulmonary artery. Shown are the surface ECGs, leads I, II, and V1, and intracardiac electrograms recorded from right atrium (RA d and RA p) and ablation catheter (ABL d and ABL p, distal and proximal pairs of electrodes of ablation catheter; ABL uni, unipolar recording by a distal electrode). The ablation catheter was located above pulmonary valve. **C.** Right and left anterior oblique views (RAO and LAO, respectively) of angiographies and intracardiac EGMs above anterior semilunar valve during couplet are given. A cartoon representing the catheter position by a blue circle is also shown.

Figure 3. Relation between Preceding RR interval and PAP duration.

Data were obtained when the mapping was performed above the anterior (red circles) and left (posterior) (blue circles) semilunar valve.

PAP: pulmonary artery potential.

Figure 4. Pacing above Left (posterior) Semilunar Valve.

ECGs during the pacing at a cycle length of 500 ms (S1 = 500) or 220 ms (S1 = 220) from base of pulmonary artery near left semilunar valve are shown.

Positive QRS morphology in lead I was seen by the pacing cycle length of 500 ms. At the beginning of the pacing cycle length of 220 ms, polymorphic QRS change was observed with a significant pacing delay. Note that the QRS morphology in lead I altered from positive (S1 = 500) to isoelectric or

negative by rapid pacing (S1 = 220). Stimulus artifacts are denoted as “S”.

Figure 5. The Proposed Mechanism of Polymorphic QRS Change in PA-VT.

A. Diagram during a PVC indicates direct propagation (red straight arrow) to RVOT through the nearest exit site. **B.** Rapid focal excitation (red star) from ventricular myocardial extensions above the pulmonary valve produces conduction block and delayed conduction with its directional changes in the myocardial sleeve (red tortuous arrows), thereby altering the exit sites at the ventriculo-arterial junction that could develop polymorphic VT. The orange area represents ventricular myocardial extension into the pulmonary artery. PVC: premature ventricular contraction; VT: ventricular tachycardia.

See text for details.

Table1. Patient Characteristics

	PA-VT (n = 4)	RVOT-VT (n = 11)	P value
Age (years)	48 ± 8	41 ± 5	NS
Male, n (%)	1 (25 %)	3 (27 %)	NS
Syncope, n (%)	4 (100 %)	3 (27 %)	0.026
Familial history of SCD, n (%)	0 (0 %)	0 (0 %)	NS
VF, n (%)	1 (25 %)	0 (0 %)	NS
Polymorphic VT, n (%)	3 (75 %)	0 (0 %)	0.0088
Sustained / Non-sustained VT	2 / 2	6 / 5	NS

Data are given as mean ± SE or n (%).

SCD: sudden cardiac death; VF: ventricular fibrillation; VT: ventricular tachycardia; PA: pulmonary artery; RVOT: right ventricular outflow tract.

Table 2. Electrocardiographic Findings at the Onset of VT and Cycle Length of the VT

	PA-VT (n = 4)	RVOT-VT (n = 11)	P value
Preceding RR (ms)	483 ± 84	688 ± 63	0.10
Preceding QT (ms)	304 ± 28	345 ± 16	NS
Coupling interval (ms)	315 ± 29	449 ± 32	0.034
Prematurity index	0.687 ± 0.089	0.685 ± 0.050	NS
Mean CL (ms)	255 ± 16	380 ± 34	0.051
Minimum CL (ms)	192 ± 13	344 ± 37	0.032

Data are given as means ± SE.

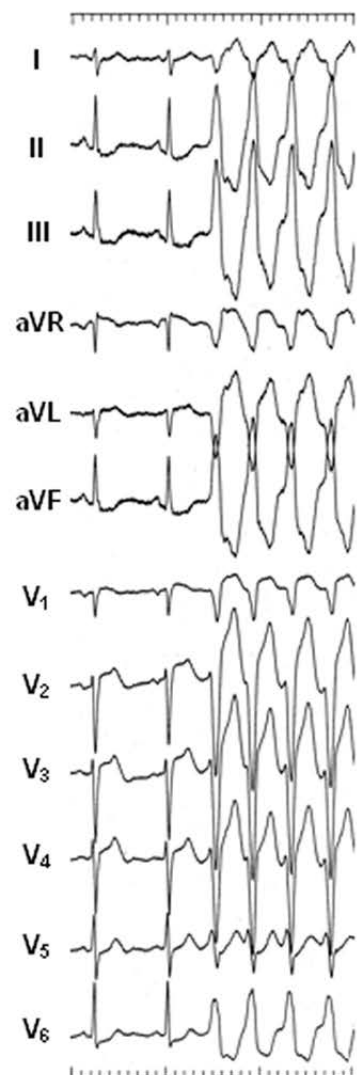
Preceding RR: preceding sinus cycle length (R-R interval) just before the VT;

Prematurity index: the ratio of the coupling interval of the first VT beat to the preceding sinus cycle length (preceding RR) just before the VT; CL: cycle length.

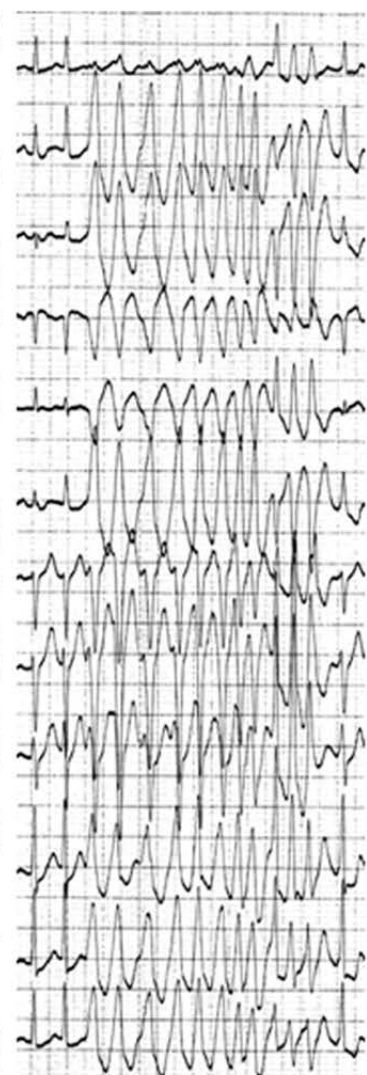Table 3. Twelve-lead ECG Characteristics at the Onset of VT

	PA-VT (n = 4)	RVOT-VT (n = 11)	P value
QRS duration (ms)	134 ± 5	131 ± 4	NS
R-wave amplitude in lead II (mV)	2.05 ± 0.17	1.44 ± 0.05	0.0005
R/S ratio in lead V ₂	0.15 ± 0.09	0.09 ± 0.02	NS
aVL/aVR of Q-wave amplitude	0.96 ± 0.16	1.06 ± 0.19	NS
R-wave duration index in lead V ₂	24 ± 10 %	24 ± 3 %	NS
Positive QRS wave in lead I, n (%)	2 (50 %)	5 (45 %)	NS

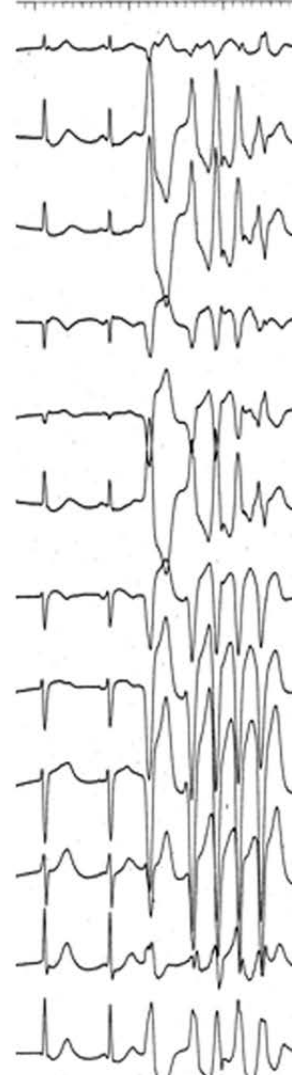
Data are given as means ± SE.

A**B**


Patient 1



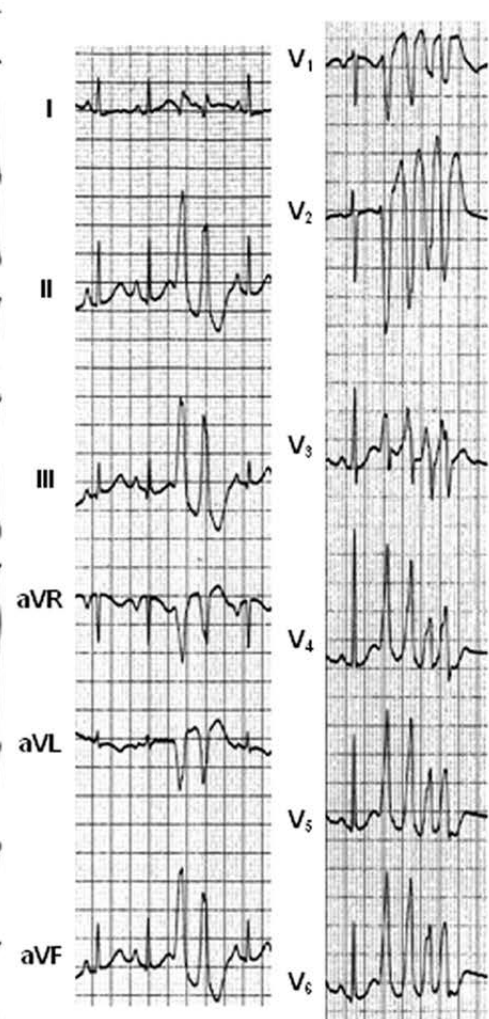
Patient 2



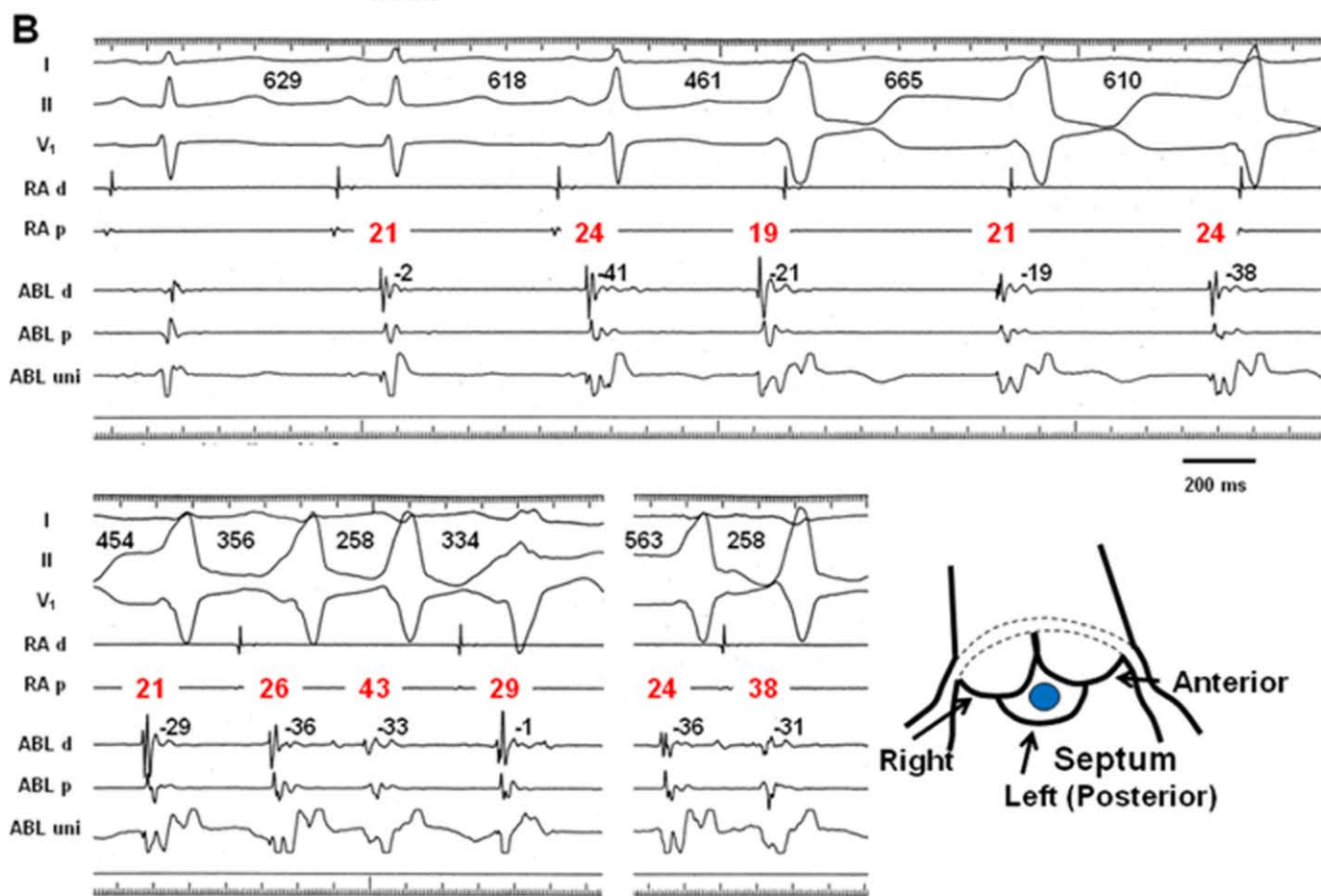
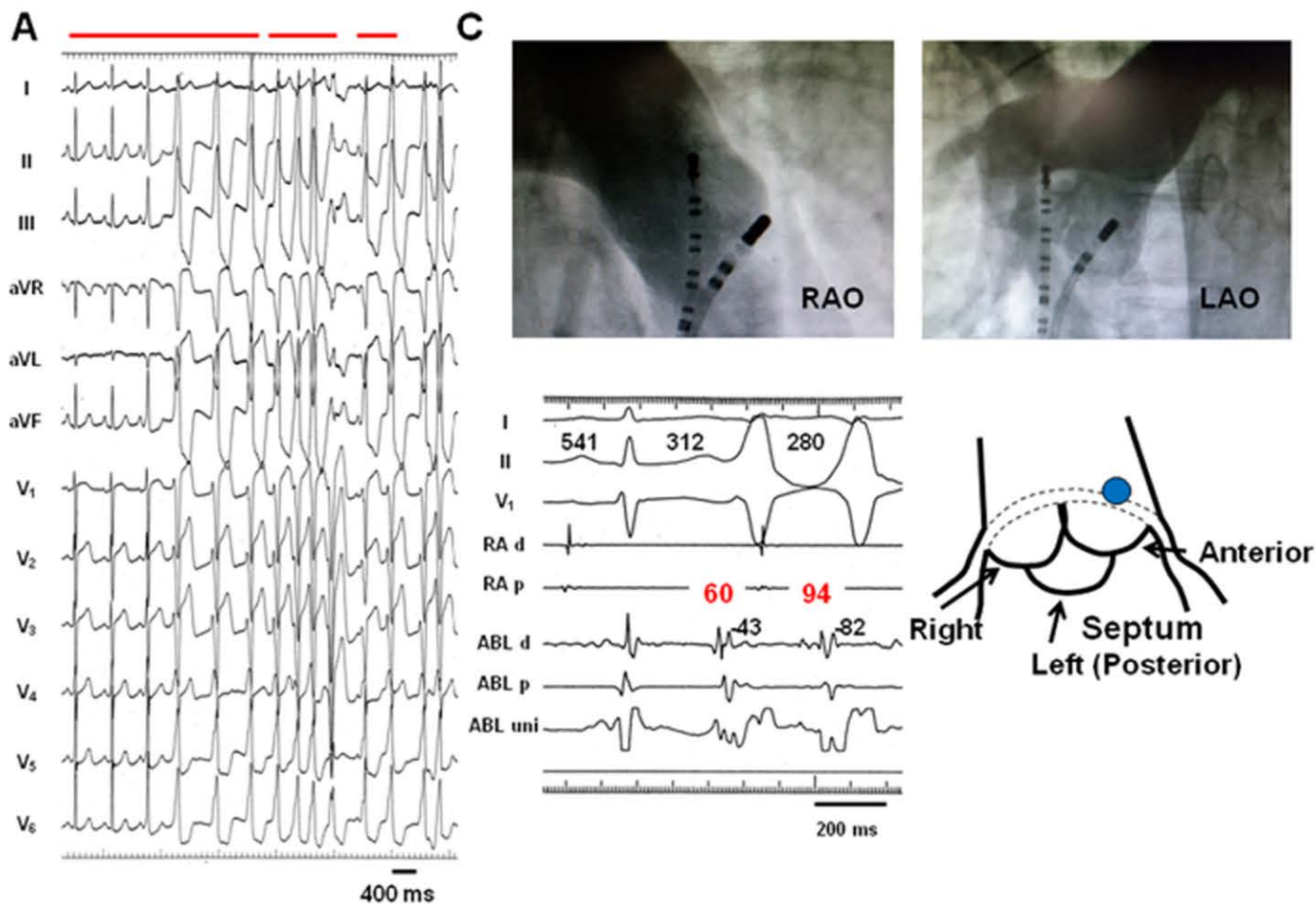
Patient 3

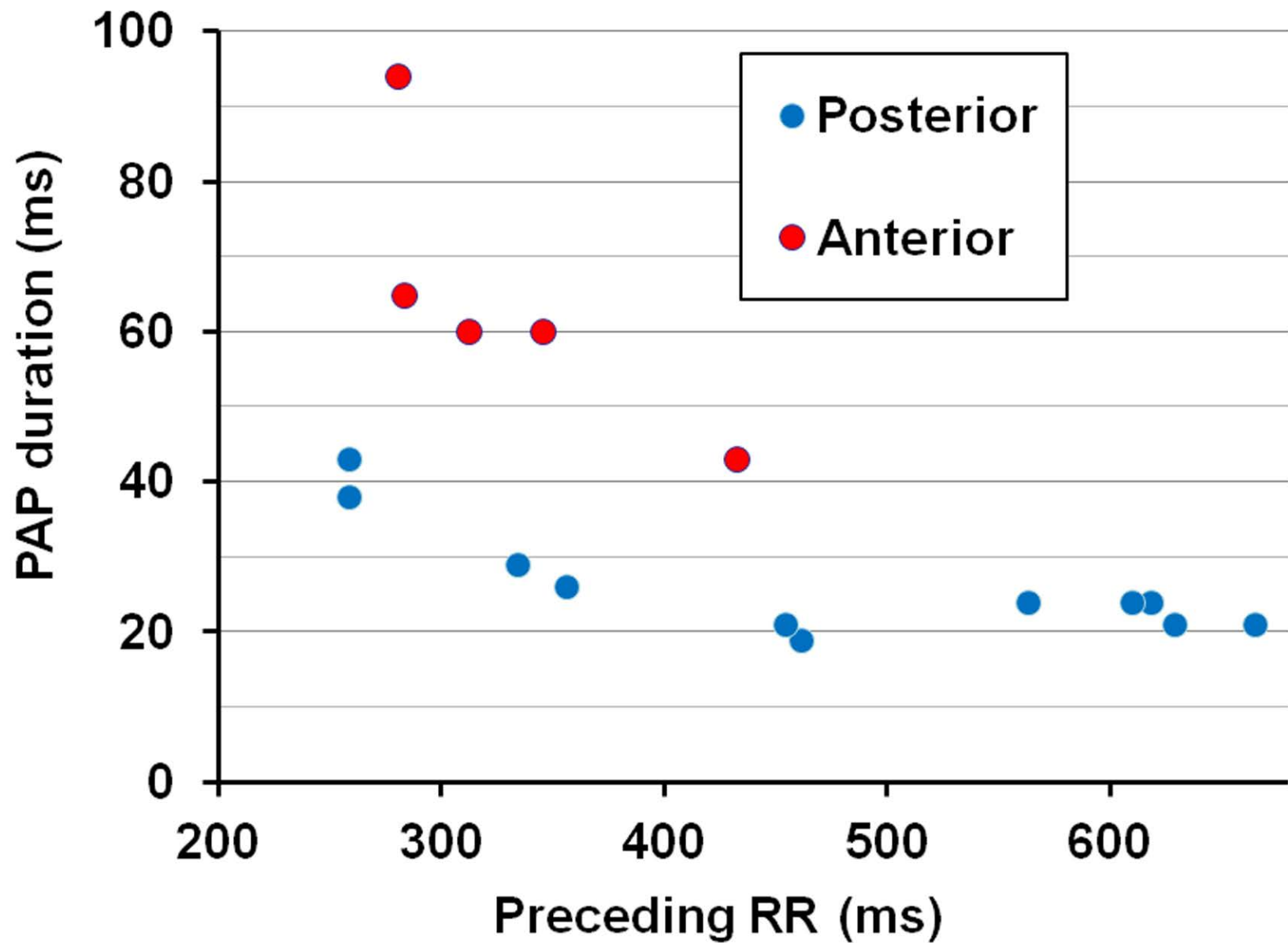


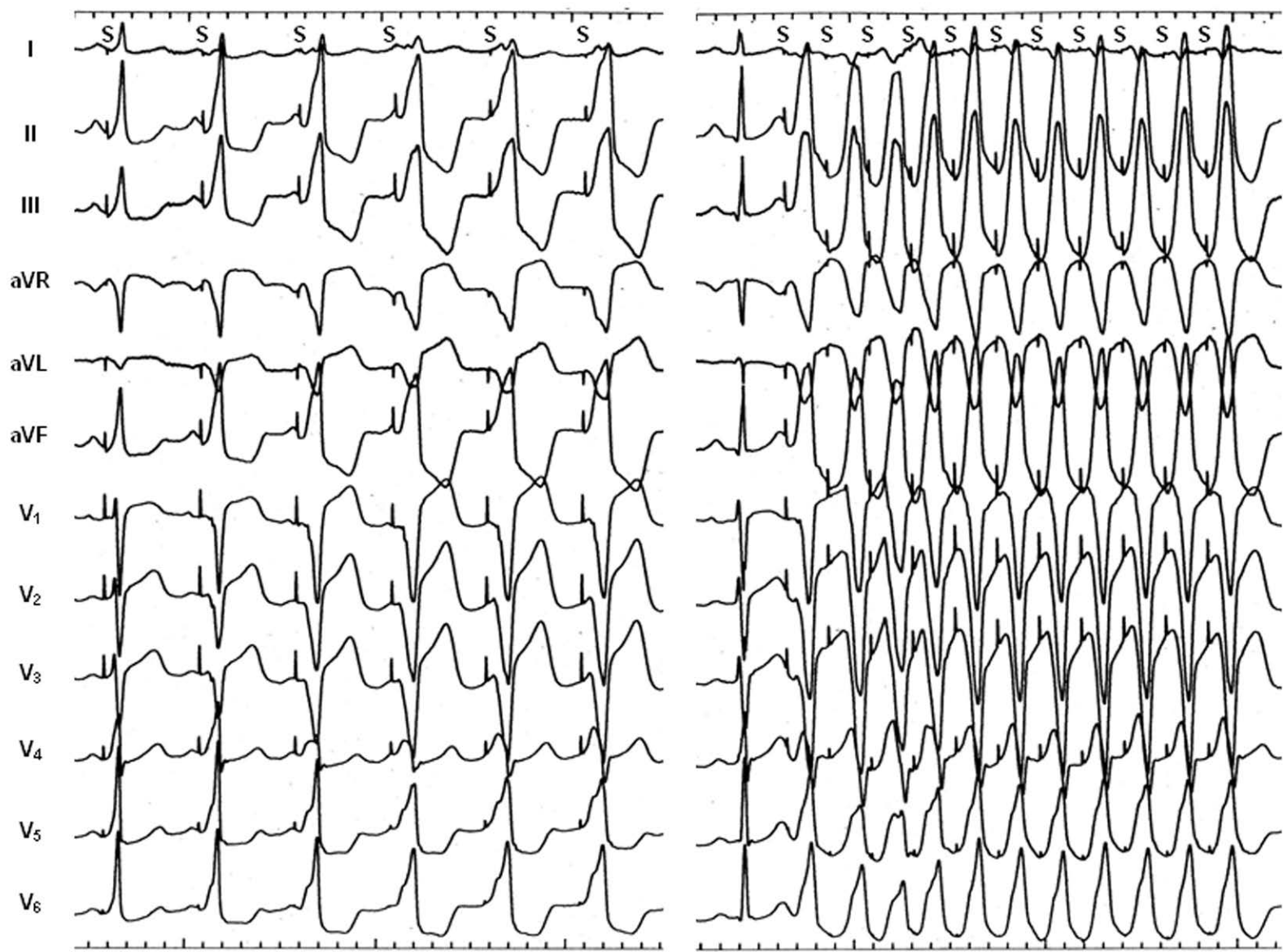
Patient 4



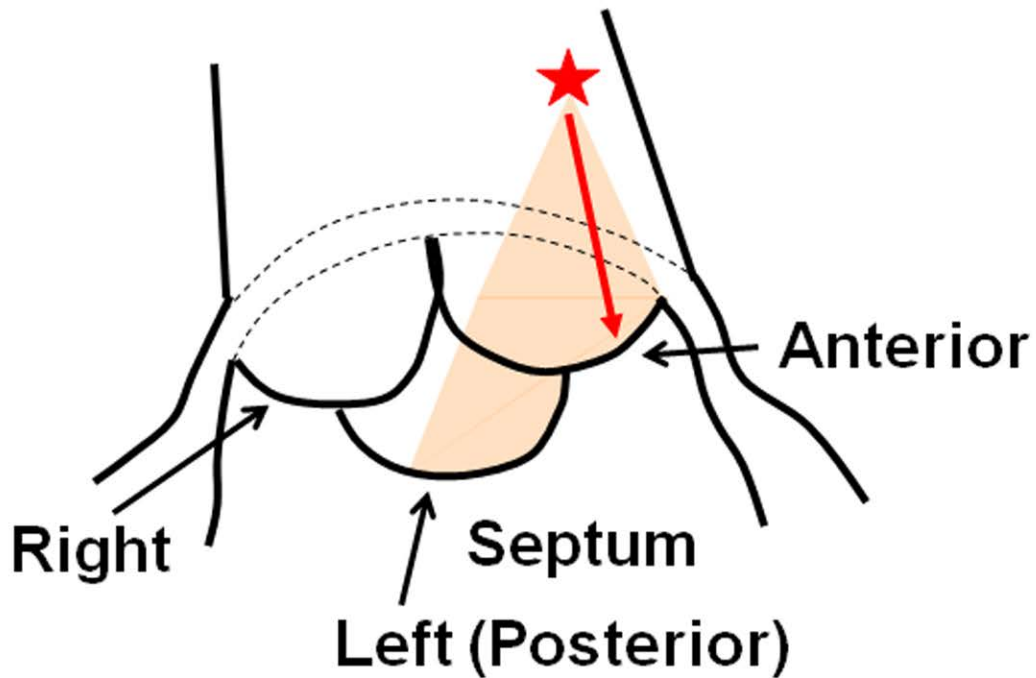
400 ms





S1 = 500**S1 = 220**

400 ms

A**PVC****B****Polymorphic VT**