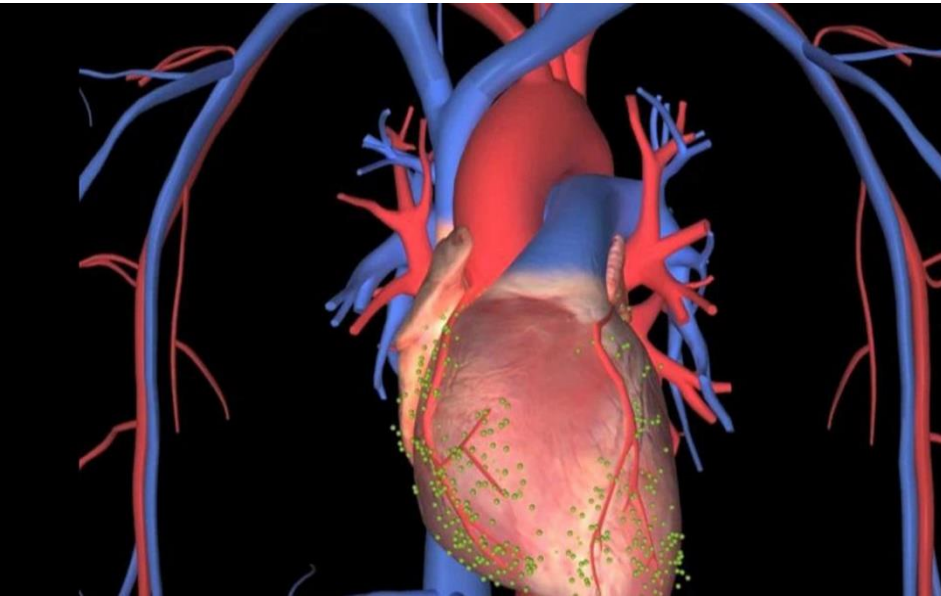


SIGNS AND SYMPTOMS OF CARDIOVASCULAR SYSTEM DISEASES (syndrome of coronary insufficiency)

LECTURE IN INTERNAL MEDICINE PROPAEDEUTICS

M. Yabluchansky, L. Bogun, L.Martymianova, O. Bychkova, N. Lysenko
V.N. Karazin National University Medical School' Internal Medicine Dept.

Plan of the lecture



Coronary insufficiency

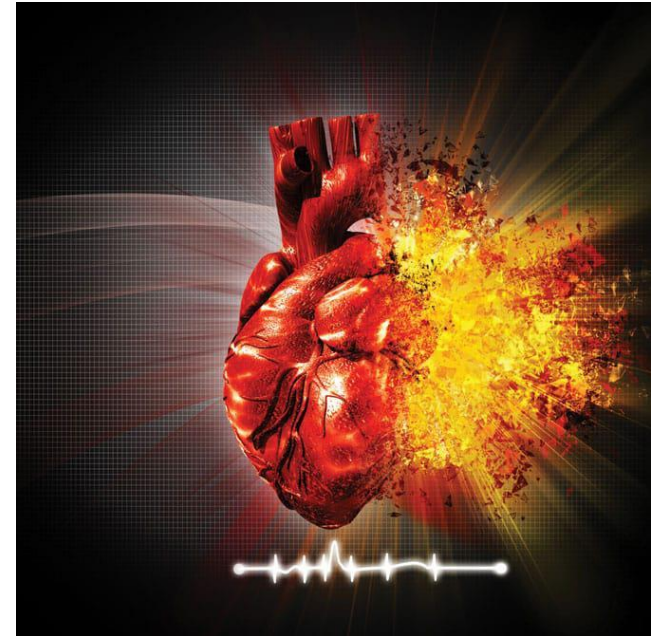
- Definition
- Classification
- Causes
- Pathophysiology
- Risk factors
- Clinical picture
- Diagnosis

Definition

Coronary insufficiency (CI) is the state in which an imbalance occurs between the oxygen supply and demand, which prevents adequate maintenance of the metabolic needs of the myocardium, resulting in ischemia of several degrees of intensity

Classification 1

- acute (unstable angina, acute coronary syndromes)
- chronic (stable angina)



Classification 2

- Acute coronary syndromes (ACS)) are named according to the appearance of the ECG
 - Non-ST segment elevation myocardial infarction (NSTEMI)
 - ST- segment elevation myocardial infarction (STEMI)

Classification 3

- ACS should be distinguished from stable angina, which develops during exertion and resolves at rest
- ACS occur suddenly, often at rest or with minimal exertion, or at lesser degrees of exertion than the individual's previous angina ("crescendo angina")
- New onset angina is also considered unstable angina, since it suggests a new problem in a coronary artery

Classification 4

- Chronic coronary insufficiency (stable angina (angina pectoris, angina)) is the sensation of chest pain, pressure, or squeezing, often due to ischemia of the heart muscle from obstruction or spasm of the coronary arteries
- The term derives from the Latin *angere* ("to strangle")
- There is a weak relationship between severity of pain and degree of oxygen deprivation in the heart muscle

Classification 5

- Worsening ("crescendo") angina attacks, sudden-onset angina at rest, new onset effort angina and angina lasting more than 15 minutes are symptoms of unstable angina (sudden-onset angina at rest and angina lasting more than 15 minutes usually grouped with similar conditions as the acute coronary syndrome)

Canadian Cardiovascular Society Functional Classification of Angina Pectoris

| Class | Definition | Specific Activity Scale |
|-------|--|--|
| I | Ordinary physical activity (eg, walking and climbing stairs) does not cause angina; angina occurs with strenuous, rapid, or prolonged exertion at work or recreation. | Ability to ski, play basketball, jog at 5 mph, or shovel snow without angina |
| II | Slight limitation of ordinary activity. Angina occurs on walking or climbing stairs rapidly, walking uphill, walking or stair climbing after meals, in cold, in wind, or under emotional stress, or only during the few hours after awakening, when walking more than 2 blocks on level ground, or when climbing more than 1 flight of stairs at a normal pace and in normal conditions. | Ability to garden, rake, roller skate, walk at 4 mph on level ground, have sexual intercourse without stopping |
| III | Marked limitation of ordinary physical activity. Angina occurs on walking 1 to 2 blocks on level ground or climbing 1 flight of stairs at a normal pace in normal conditions. | Ability to shower or dress without stopping, walk 2.5 mph, bowl, make a bed, play golf |
| IV | Inability to perform any physical activity without discomfort. | Anginal symptoms may be present at rest. Inability to perform activities requiring 2 or fewer metabolic equivalents without angina |

Causes

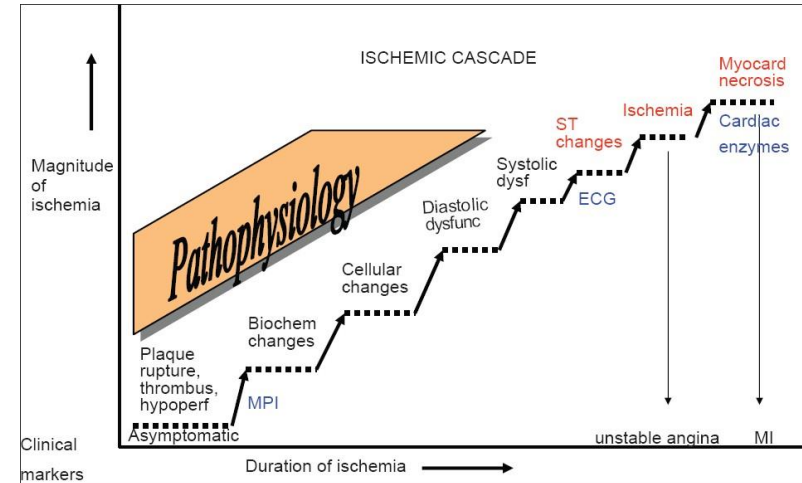
- Atherosclerotic obstructive coronary insufficiency (Coronary Artery Disease - CAD) –main cause
- Cardiac valvular diseases (aortic stenosis)
- Hypertrophic cardiomyopathy
- Microvasculature diseases (diabetes mellitus, syndrome X)
- Anomalous origin of coronary arteries, and coronary fistulas

Pathophysiology

Fundamental components

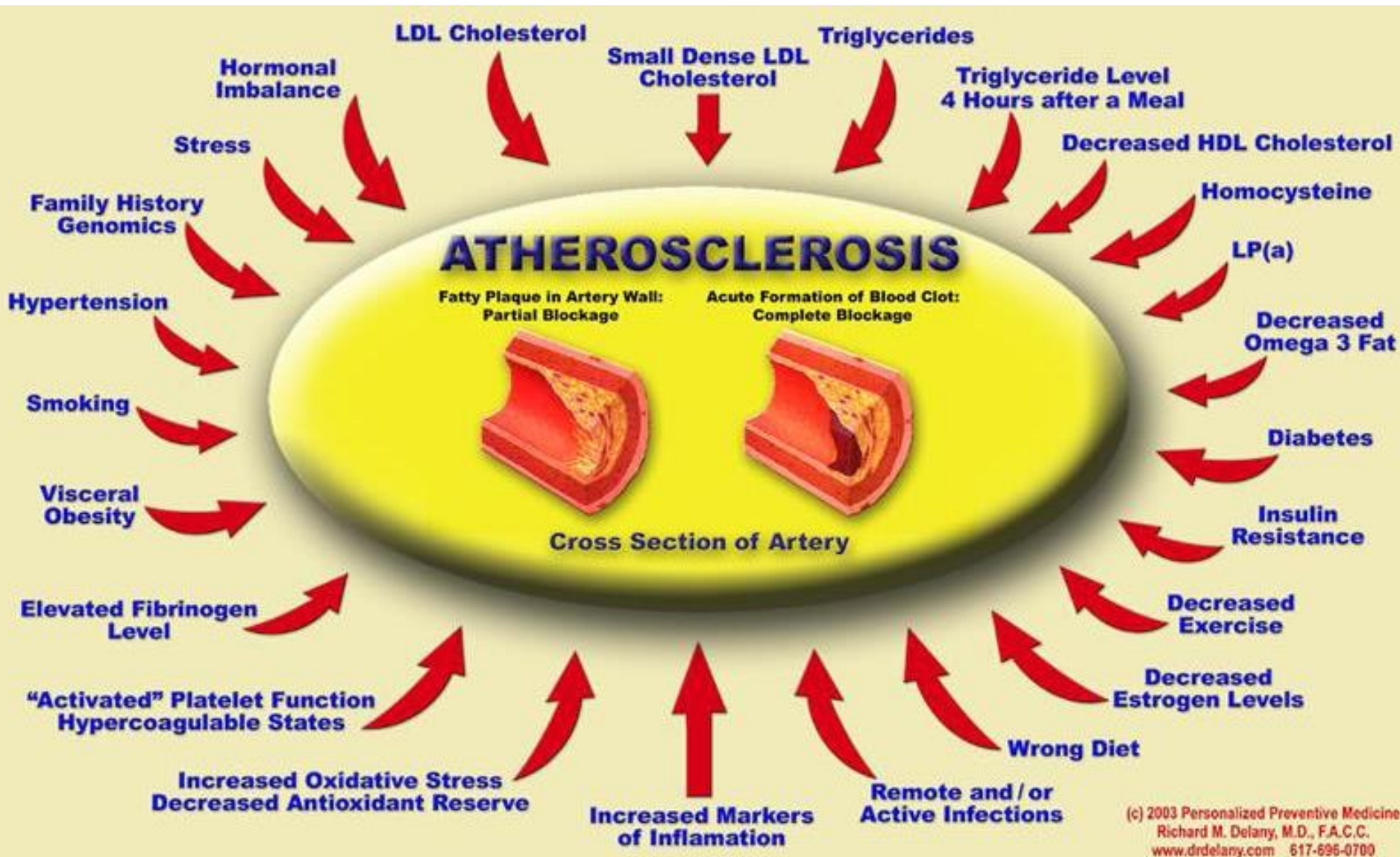
1. Endothelial dysfunction
2. Obstruction of the lumen of the vessel
3. Thrombosis at the location of the lesion

The decline of coronary reserve starts when lesions occupy at least 70% of the vessel diameter



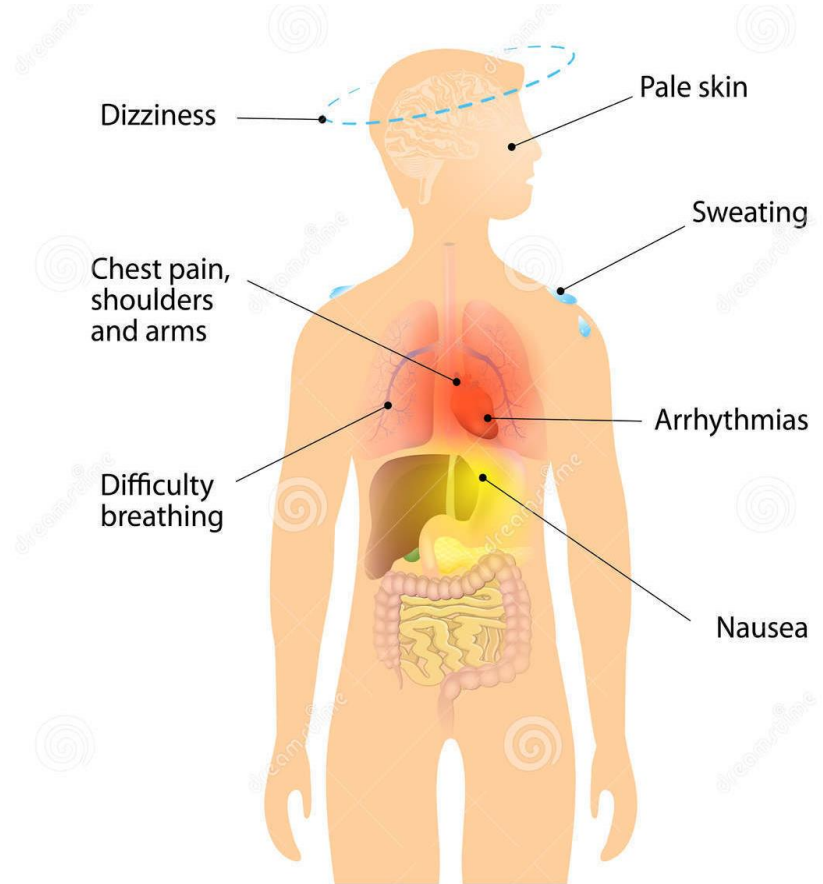
Depicts the myocardial ischemic cascade and stepwise changes, which occur at molecular and tissue level.

Risk factors



Clinical picture

- Chest pain or discomfort
- Shortness of breath
- Heart failure
- Irregular heartbeat
- Nausea
- Sweating
- Decreased exercise tolerance
- Etc.



Clinical picture from William Heberden 1

But there is a disorder of the breast marked with strong and peculiar symptoms, considerable for the kind of danger belonging to it, and not extremely rare, which deserves to be mentioned more at length.



WILLIAM HEBERDEN, 1772

Clinical picture from William Heberden 2

The seat of it and the sense of strangling and anxiety with which it is attended, may make it not improperly be called angina pectoris.



WILLIAM HEBERDEN, 1772

Clinical picture from William Heberden 3

Those who are afflicted with it, are seized while they are walking (more especially if it be uphill, and soon after eating) with a painful and most disagreeable sensation in the breast, which seems as if it would extinguish life if it were to increase or to continue; but the moment they stand still, all this uneasiness vanishes.



WILLIAM HEBERDEN, 1772

Clinical picture from William Heberden 4

In all other respects, the patients are, at the beginning of this disorder, perfectly well, and in particular have no shortness of breath, from which it is totally different. The pain is sometimes situated in the upper part, sometimes in the middle, sometimes in the bottom of the os. sterni, and often more inclined to the left than to the right side. It likewise very frequently extends from the breast to the middle of the left arm.



WILLIAM HEBERDEN, 1772

Clinical picture from Nomenclature and Criteria for Diagnosis of Diseases of the Heart and Blood Vessels, 1953 1

In this syndrome the major symptom is thoracic pain, which is precipitated usually by effort but sometimes by excitement, a heavy meal or exposure to cold.

The pain is usually substernal or just to the left of the sternum.

Occasionally the pain is epigastric and in rare instances it may be localized in the neck or the left arm or shoulder.

Clinical picture from Nomenclature and Criteria for Diagnosis of Diseases of the Heart and Blood Vessels, 1953 2

There is a tendency for the pain to radiate, most frequently to the left shoulder and arm and occasionally to the fingers. Less frequently it may radiate to the neck, jaw and teeth, to the back, upper abdomen, or to the right shoulder and arm.

At times the pain will start at one of these points before focusing on the anterior surface of the chest. The intensity varies from a slight sense of heaviness to a severe crushing pain.

Clinical picture from Nomenclature and Criteria for Diagnosis of Diseases of the Heart and Blood Vessels, 1953 3

Since the precipitating cause is commonly physical exertion, rest usually causes the pain to subside.

The length of the episode, therefore, is relatively short.

Occasionally an attack may come on while the patient is at rest or even when asleep.

The pain is often accompanied by a sense of choking or inability to breathe which is also relieved by rest.

The patient will often complain of flatulence as well.

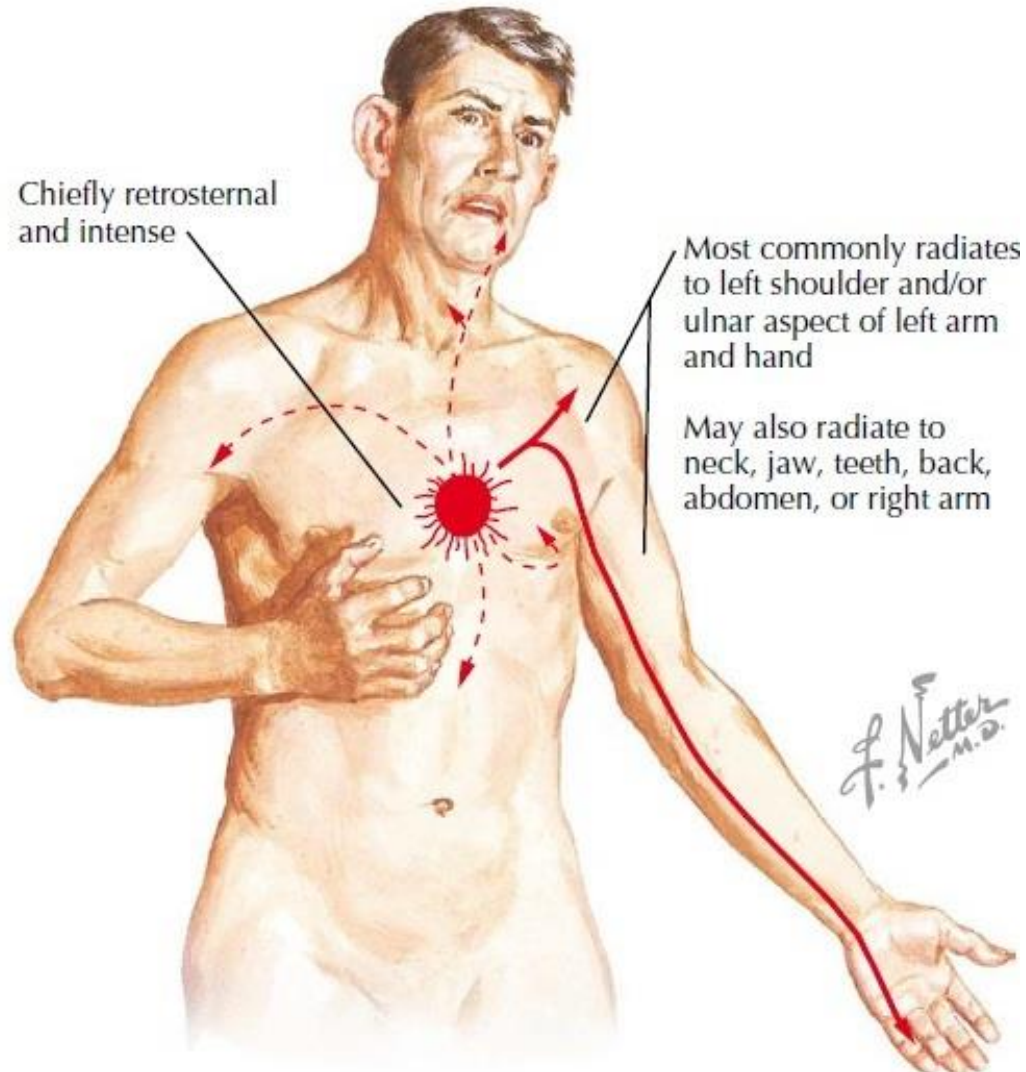
Clinical picture from Nomenclature and Criteria for Diagnosis of Diseases of the Heart and Blood Vessels, 1953 4

If the attack is not relieved by rest or a nitrite and lasts for an hour or more, and especially if it is accompanied by circulatory collapse, myocardial infarction should be strongly suspected.

Occasionally the pain of myocardial infarction may be identical with the pain of the anginal syndrome.

The associated symptomatology and the subsequent course will determine the diagnosis.

Clinical picture



Clinical picture

Pain (Chest)

| | | Cardiac | Pleuritic | Traumatic |
|----------|---|--|--|--|
| D | Description: <ul style="list-style-type: none"> • Can you describe the pain to me? (You need to determine it's nature.) • Is it there all the time? Does it come and go? • Have you ever had this pain before? • What was it that time? | <ul style="list-style-type: none"> • Heavy • Tight • Squeezing • Dull | <ul style="list-style-type: none"> • Sharp • Catching • Stabbing | <ul style="list-style-type: none"> • Sharp • Catching • Stabbing |
| O | Onset: <ul style="list-style-type: none"> • When did it start? • What were you doing at the time? • Did it come only suddenly or slowly? | <ul style="list-style-type: none"> • Gradual (Angina) • Sudden (UA/Infarct) • With Exercise (Angina) • At Rest (UA/Infarct) | <ul style="list-style-type: none"> • Gradual (Infection) • Sudden (Pneumothorax) | <ul style="list-style-type: none"> • Gradual (post trauma) • Sudden (post trauma) |
| L | Location: <ul style="list-style-type: none"> • "Take one finger and point to the pain?" • "Does it extend anywhere else?" • If well localised palpate and visualise | <ul style="list-style-type: none"> • Poorly localised • Chest to back to jaw • Rarely changes with palpation | <ul style="list-style-type: none"> • Well localised • Usually chest wall • Usually changes with palpation / ventilation | <ul style="list-style-type: none"> • Well defined • Usually chest wall • Changes with palpation / ventilation |
| O | Other Signs and Symptoms: <ul style="list-style-type: none"> • "Do you feel nauseous?" • (If yes) "Have you vomited?" • "Do you feel SOB?" • "Have you noticed palpitations?" • "What came first, the discomfort or the (OSS)?" | <ul style="list-style-type: none"> • SOB % • Diaphoresis % • Palpitations % | <ul style="list-style-type: none"> • SOB (on exertion) • Chest infection (prodromal) | <ul style="list-style-type: none"> • SOB (on exertion) |
| R | Relief: <ul style="list-style-type: none"> • "Have you taken anything for the discomfort?" • (If yes) "Has it helped?" • "Does it usually?" • "Does taking a deep breath make the pain better, worse or no different?" • "Does moving make the pain better, worse or no different?" | <ul style="list-style-type: none"> • Relieved with Nitrates (Angina) • Unrelieved with Nitrates (UA/Infarct) • Poor relief with NSAIDS • Poor relief with position | <ul style="list-style-type: none"> • Unrelieved with Nitrates • Mild relief with NSAIDS • Some relief with position | <ul style="list-style-type: none"> • Unrelieved with Nitrates • Mild relief with NSAIDS • Some relief with position |

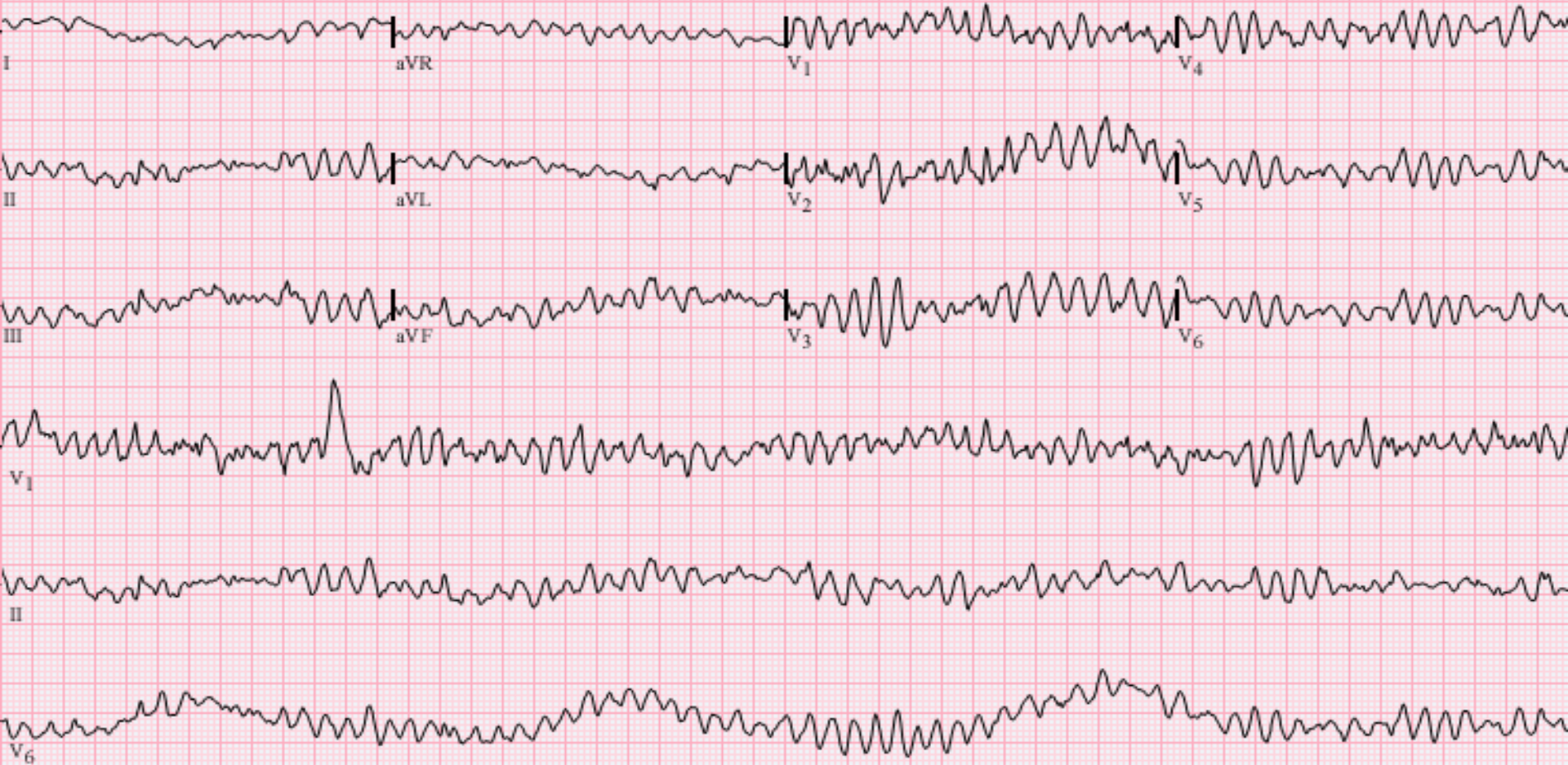Clinical picture



A man experiences shortness of breath.

Clinical picture

Courtesy of Jason E. Roediger, CCT, CRAT



Ventricular fibrillation.

Clinical picture



Nausea.

<http://cdn1.medicalnewstoday.com/content/images/articles/290/290196/woman-curl-up-with-nausea.jpg>

Clinical picture

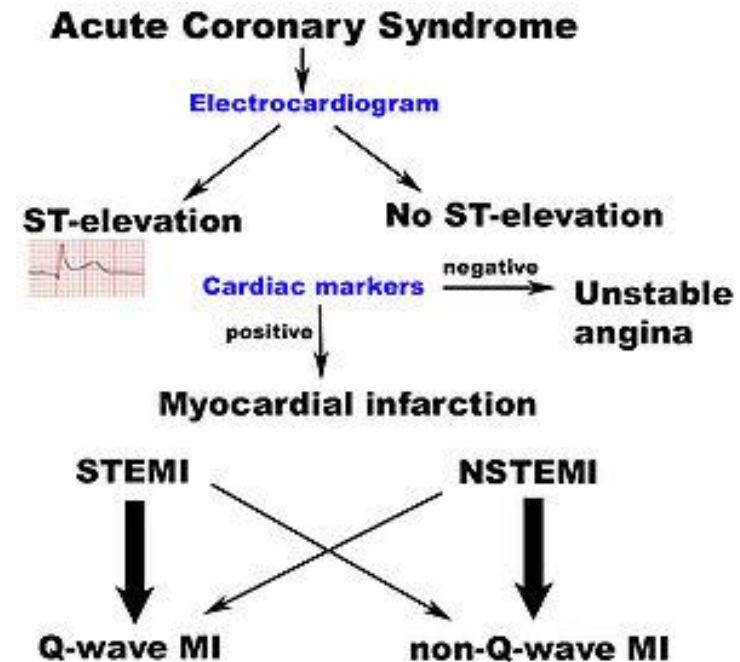


Sweating.

<http://images.medicinenet.com/images/slideshow/15-heart-symptoms-s13-businessman-in-cold-sweat.jpg>

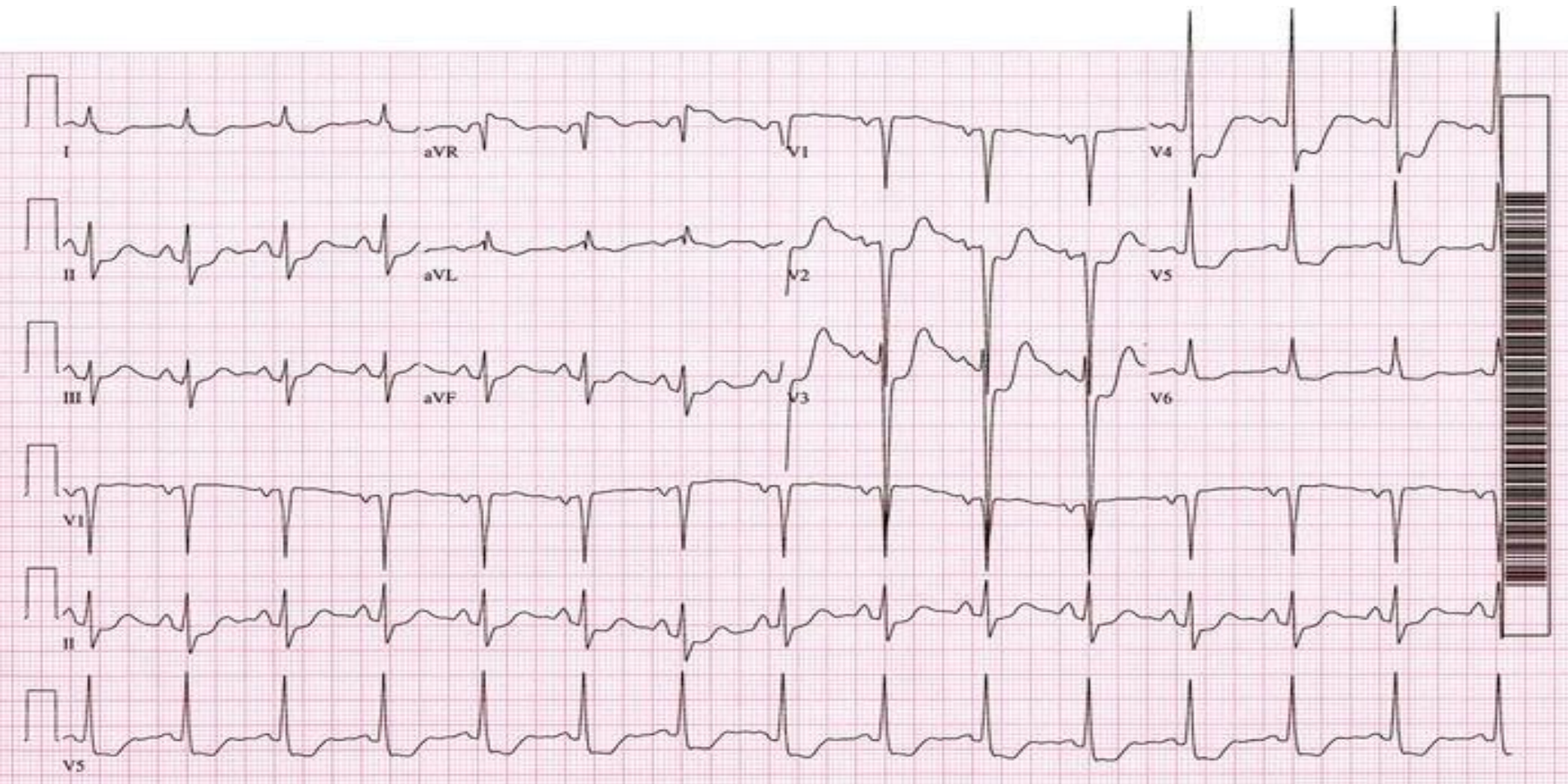
Diagnosis

- Electrocardiography
- Stress test
- Echocardiography (including stress echocardiography and intravascular ultrasound)
- Coronary angiography
- Radioisotopes
- Visualization
- Blood Test



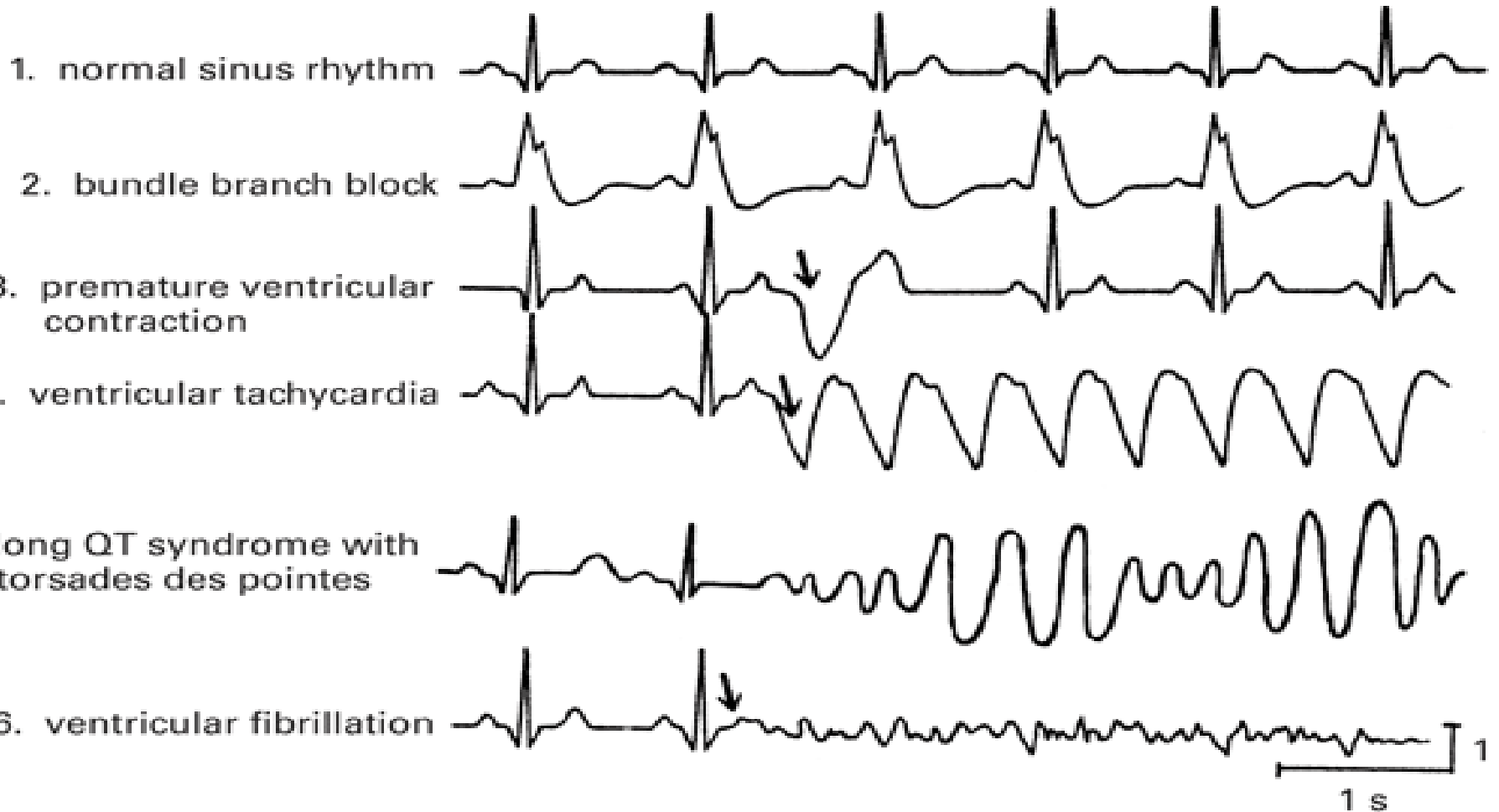
Diagnostics algorithm:
STEMI ST-elevation Myocardial Infarction,
NSTEMI – No ST-elevation Myocardial
Infarction

Diagnosis: electrocardiography 1



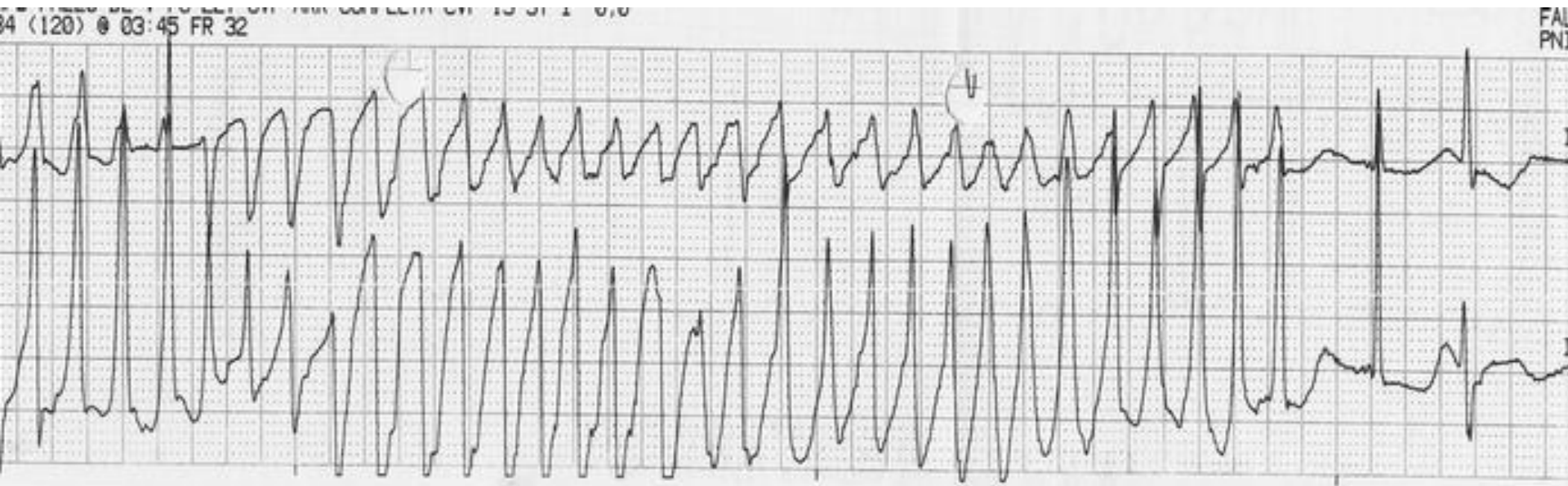
A 12-lead ECG of ischemic anterolateral ST-segment depression in a patient with coronary artery disease.

Diagnosis: electrocardiography 2



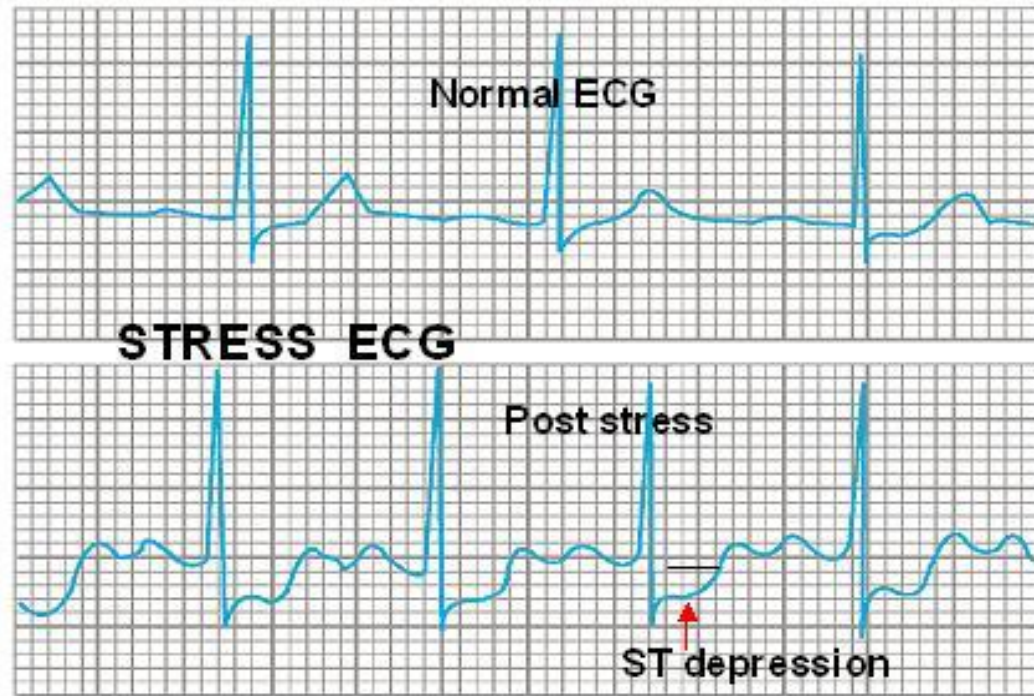
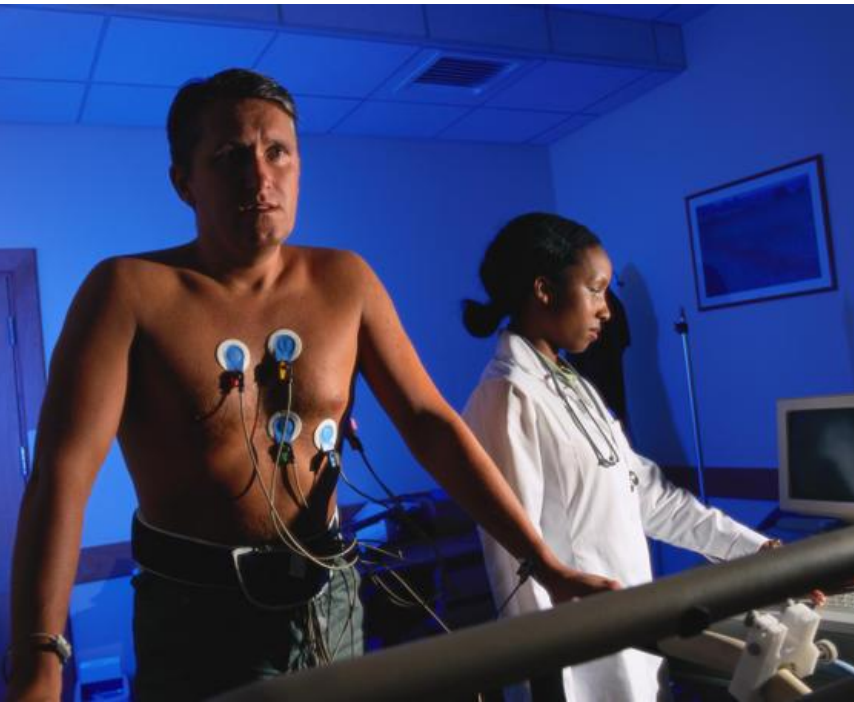Ventricular arrhythmias.

Diagnosis: electrocardiography 3



Polymorphic ventricular tachycardia
in torsade de pointes.

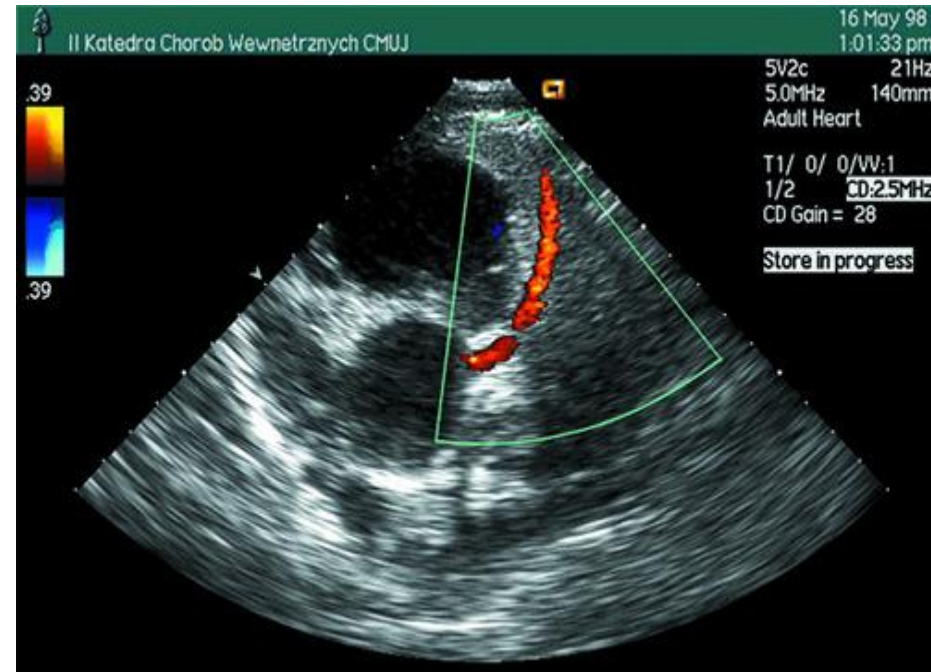
Diagnosis: stress test



ST-segment depression confirms ischemia
and positive stress test

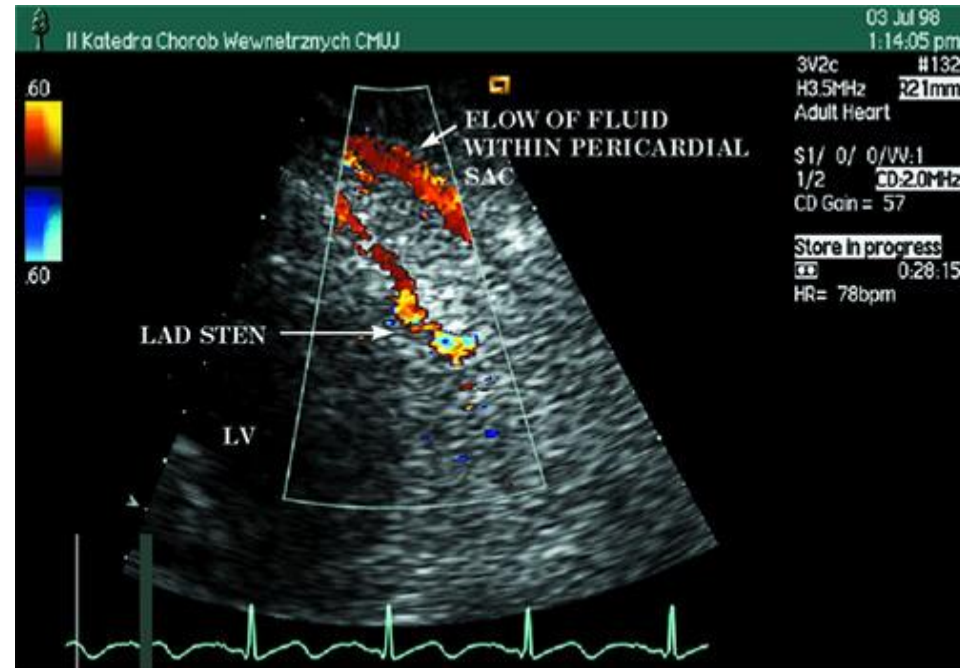
Diagnosis: echocardiography 1

Left main stem coronary artery and proximal segment of left anterior descending coronary artery (LAD) in color-coded transthoracic Doppler echocardiography



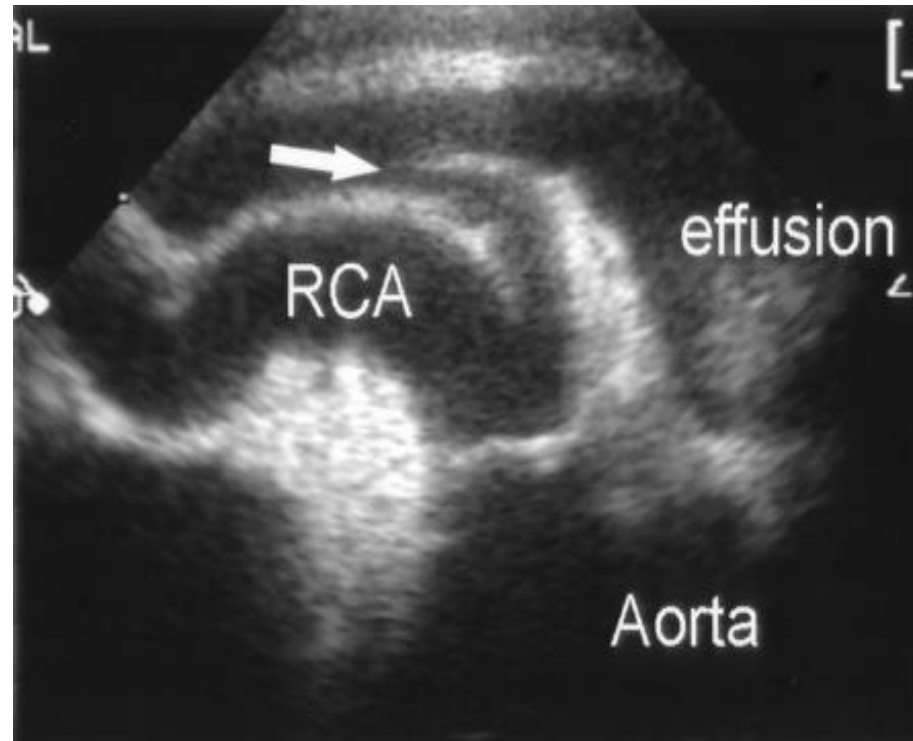
Diagnosis: echocardiography 2

- Direct visualization of coronary artery stenosis
- The portion of mid segment of left anterior descending coronary artery (LAD) with color mosaic (a sign of high-velocity, turbulent flow) at stenotic site



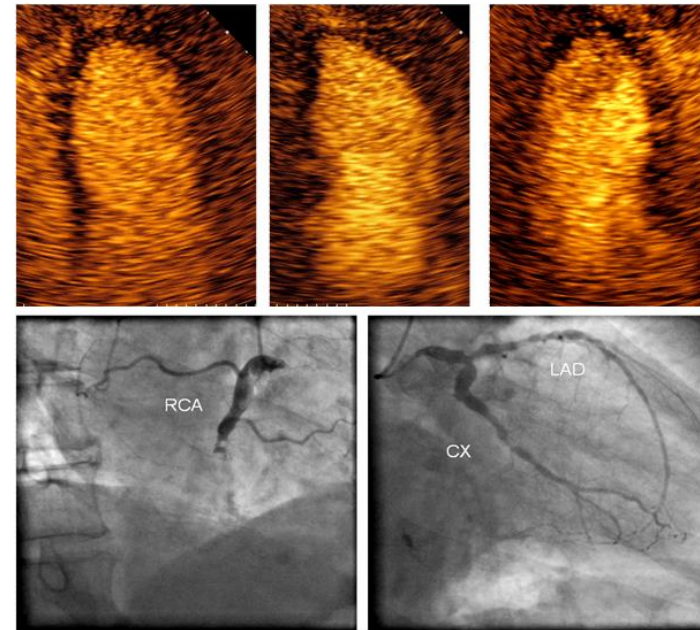
Diagnosis: echocardiography 3

- Echocardiography, parasternal short-axis view
- In presence of pericardial effusion, proximal part of right coronary artery (RCA) is suspicious for dissection (arrow).
Imaging plane is off axis of nondilated RCA ostium



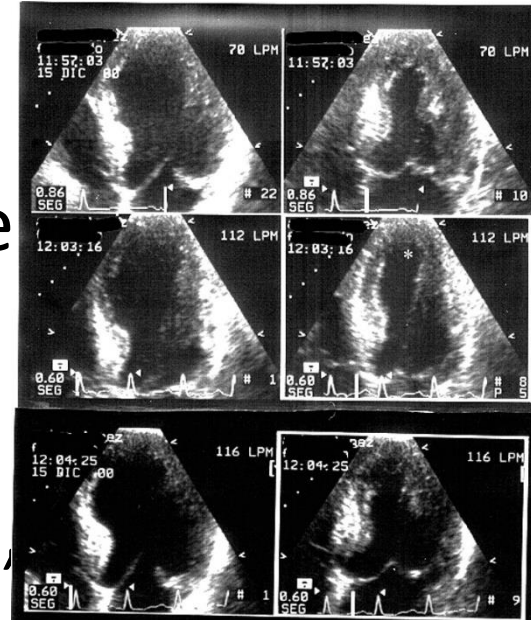
Diagnosis: echocardiography 4

Contrast echocardiography in apical 4-chamber, 2-chamber and 3-chamber views (upper panels) demonstrating the extensive reduction of myocardial perfusion in a non ST-elevation myocardial infarction (NSTEMI) patient with angiographic trippel-vessel disease including acute occlusion of the right coronary artery and left main stem stenosis (lower

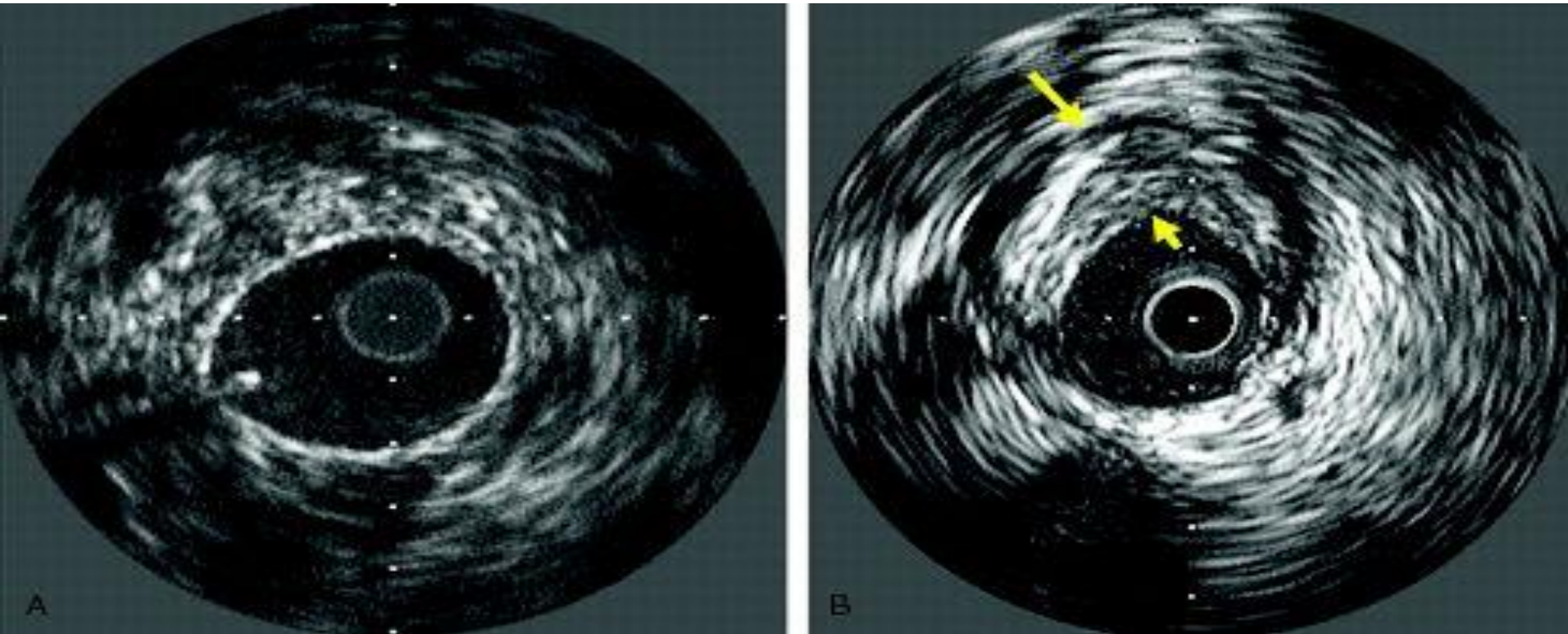


Diagnosis: echocardiography 5

- Four-chamber diastolic (left) and systolic (right) apical frames at rest (top), peak (middle) and post-exercise (bottom) imaging in a patient with a previous inferior infarction
- Rest regional wall motion was normal, whereas apical hypokinesia developed at peak exercise (asterisk) and had been resolved by the time post-exercise imaging was performed

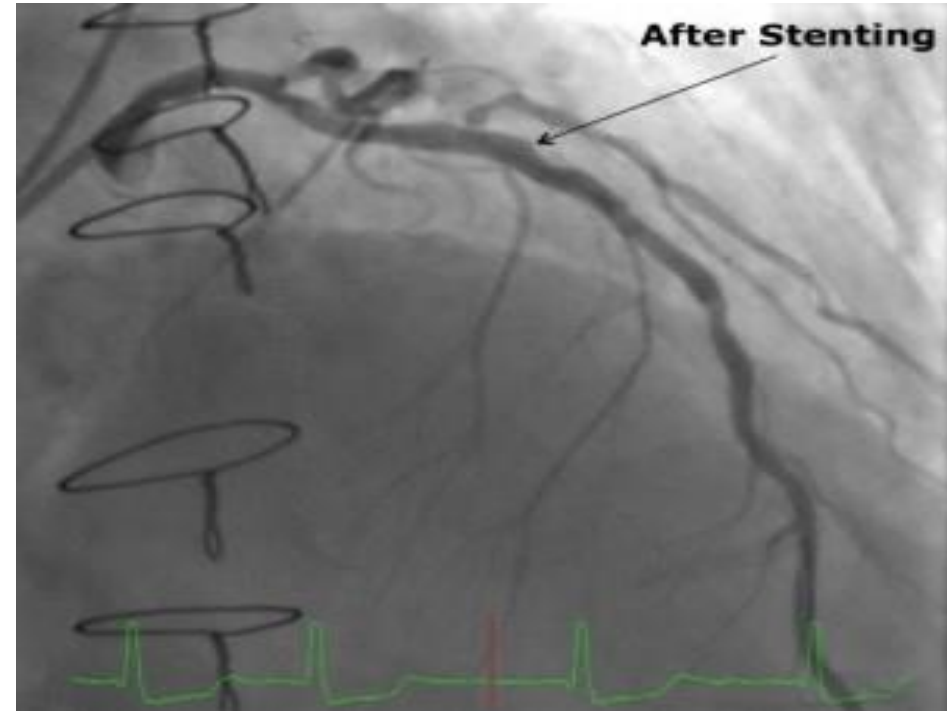
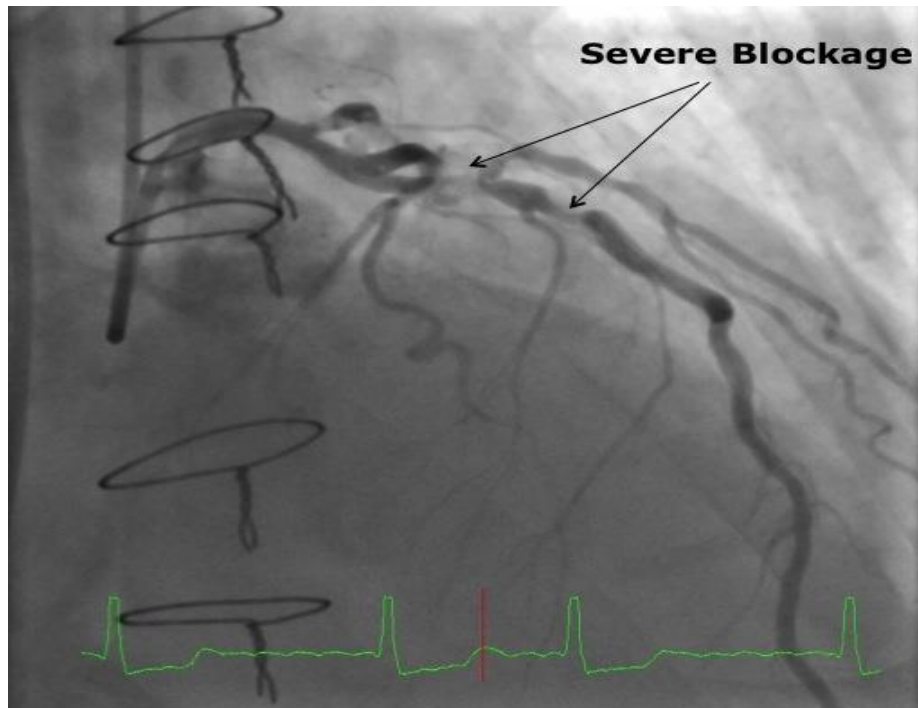


Diagnosis: intravascular echocardiography



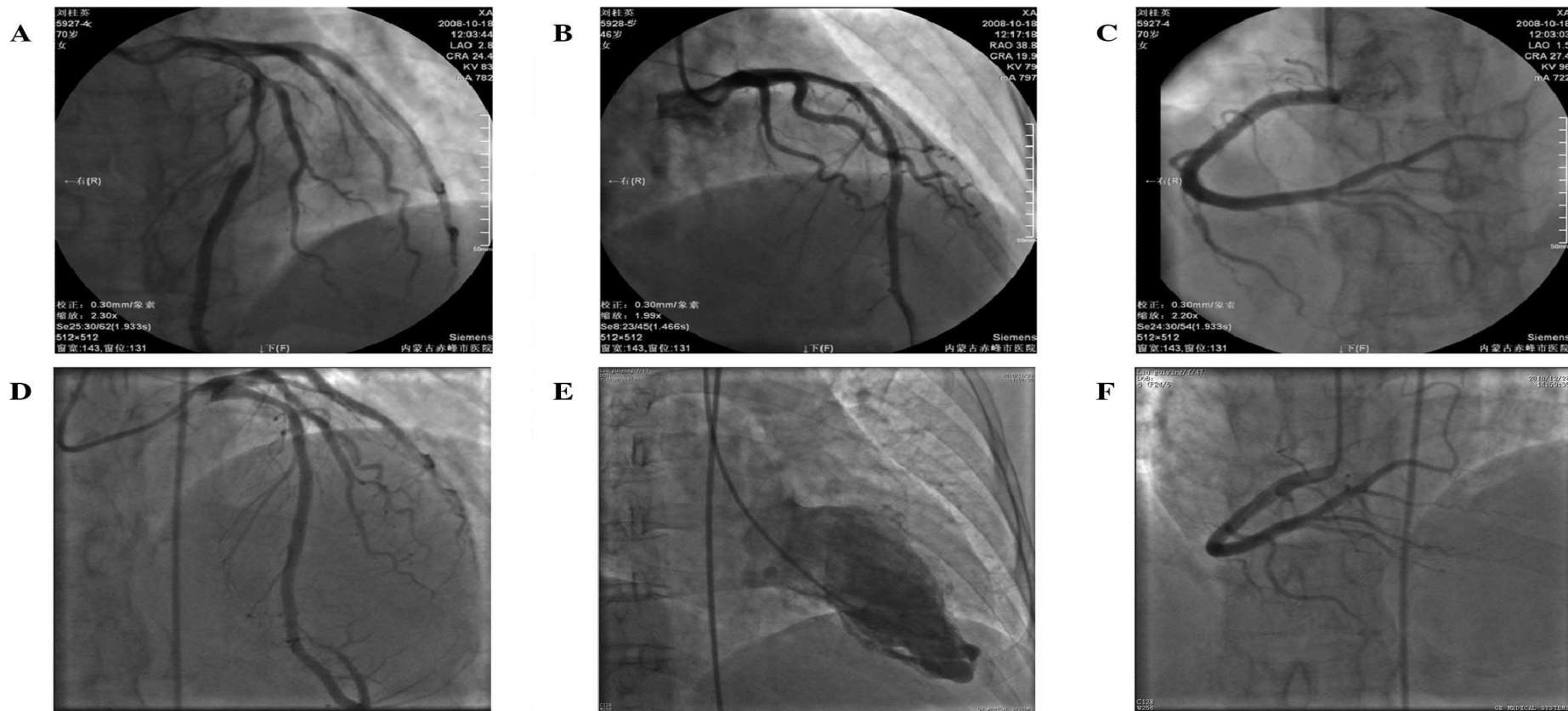
- Left - normal coronaries
- Right - increased coronary intimal thickness (1.2 mm; arrows), suggesting severe vasculopathy

Diagnosis: coronary angiography 2



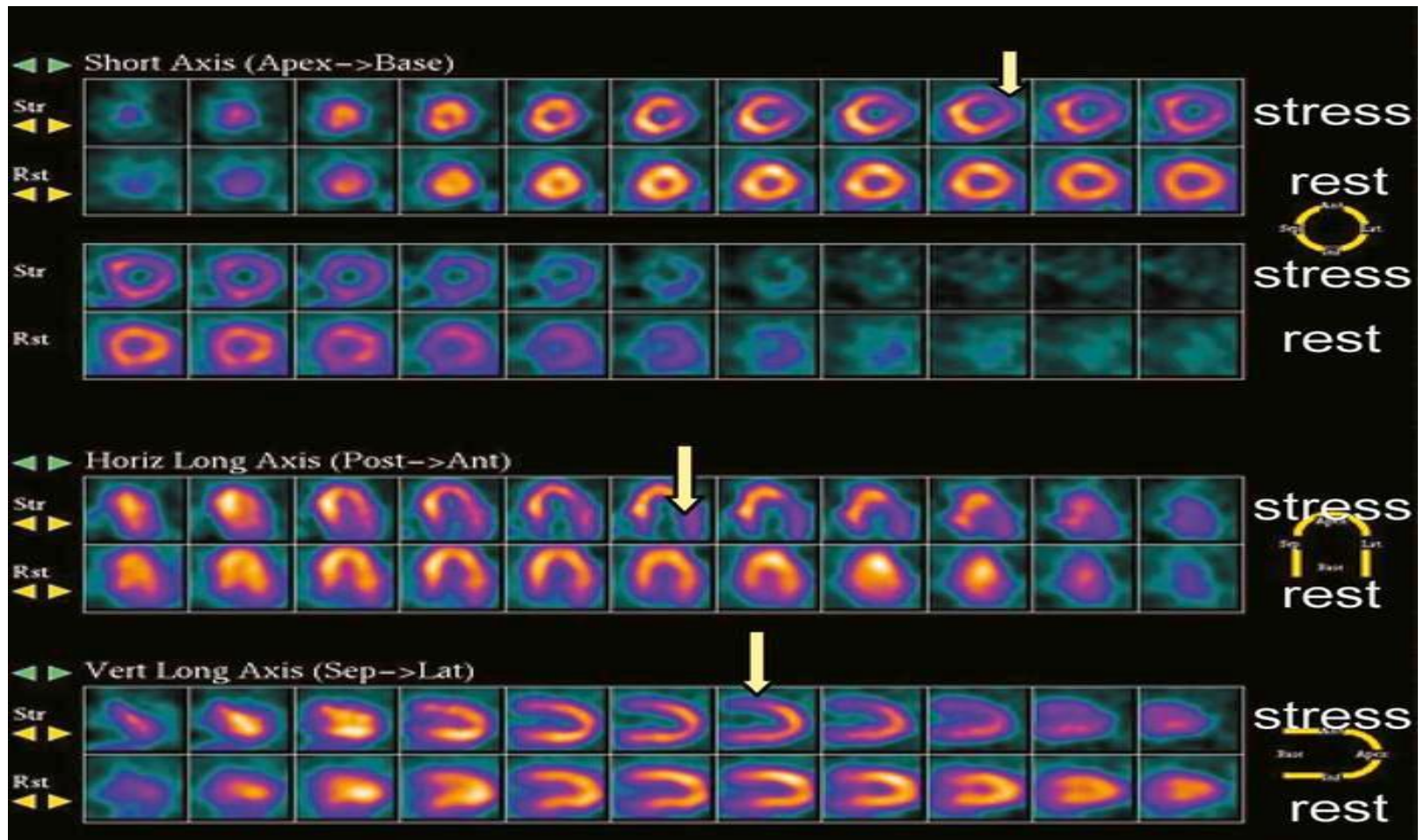
Single-vessel coronary artery disease

Diagnosis: coronary angiography 3



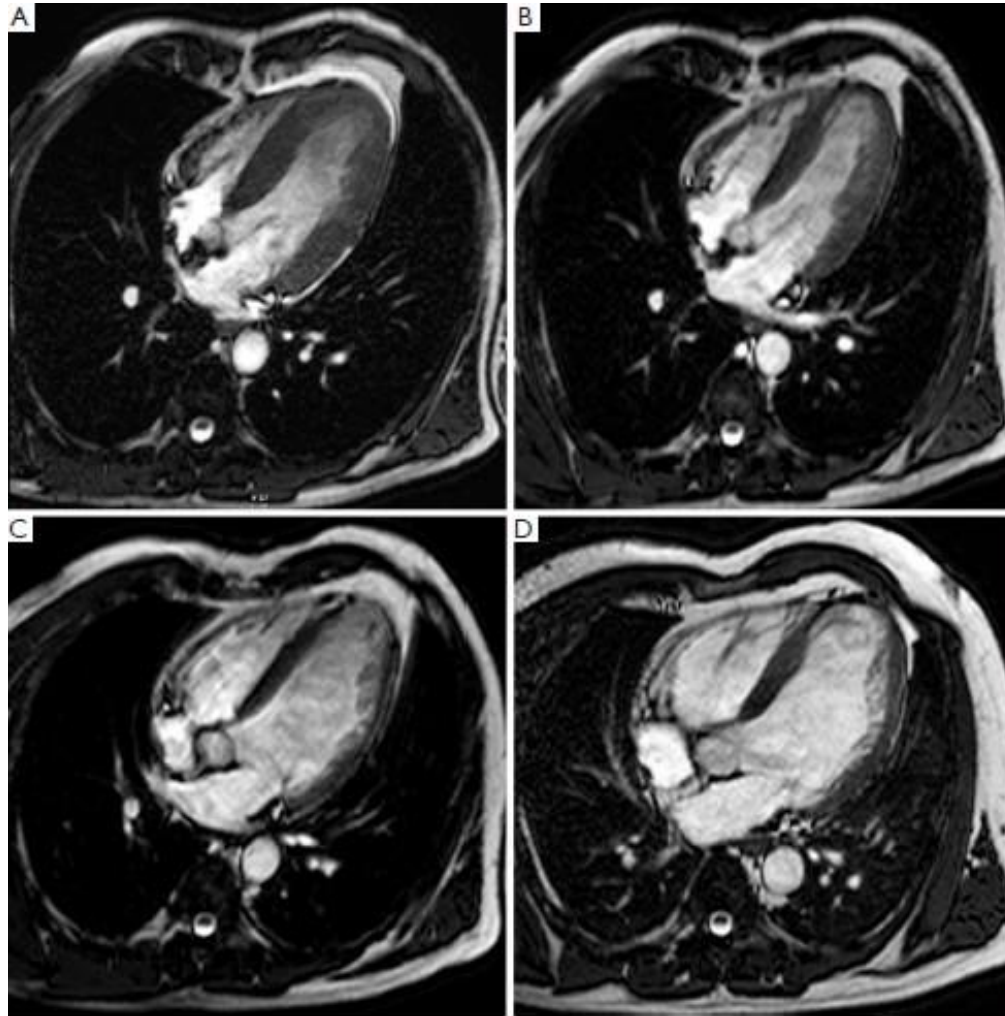
Coronary angiography of a case with acute myocardial infarction in the (A–C) first and (D–F) second time admissions.

Diagnosis: radioisotopes



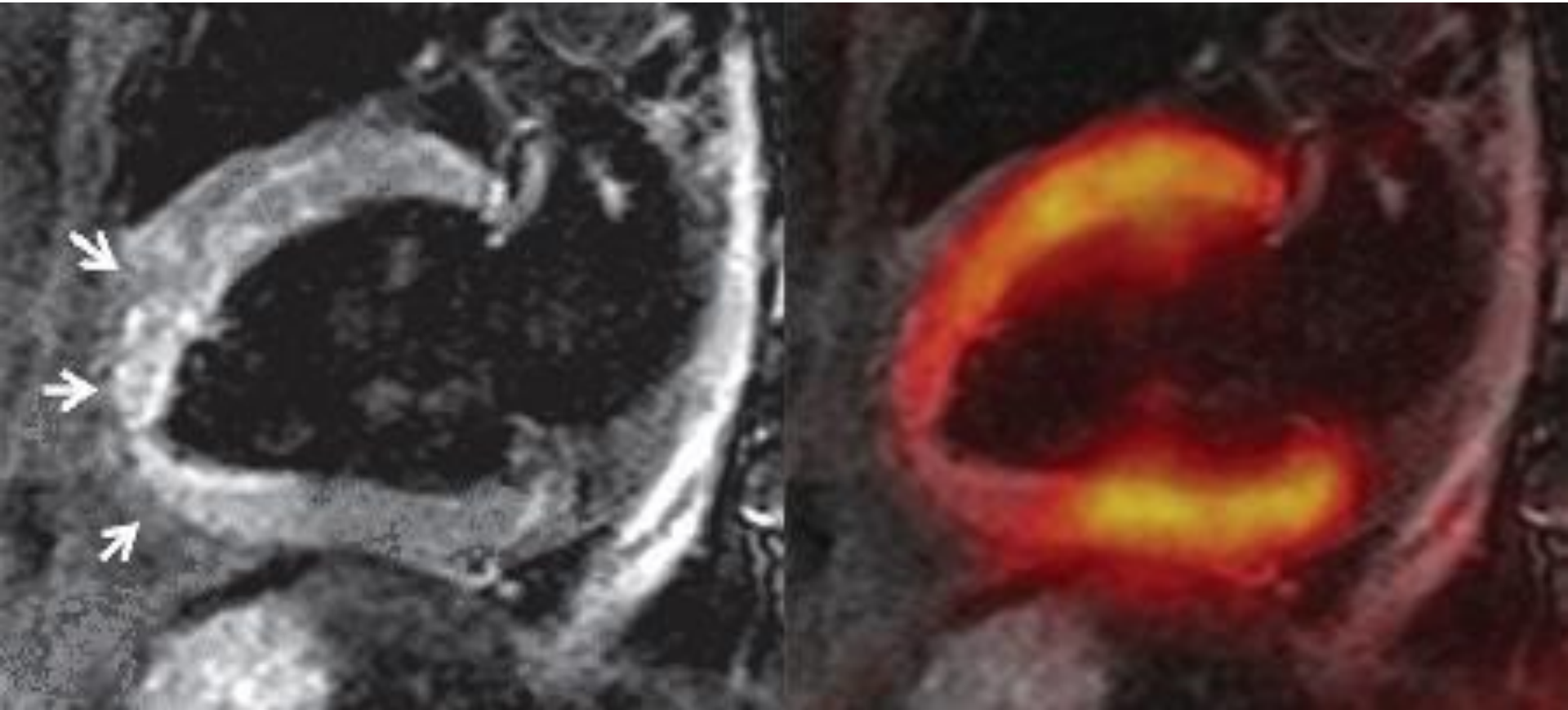
Stress images (arrows) demonstrate inferolateral and anterolateral (left circumflex) ischemia.

Diagnosis: magnetic resonance imaging



Ventricular remodeling post myocardial infarction.

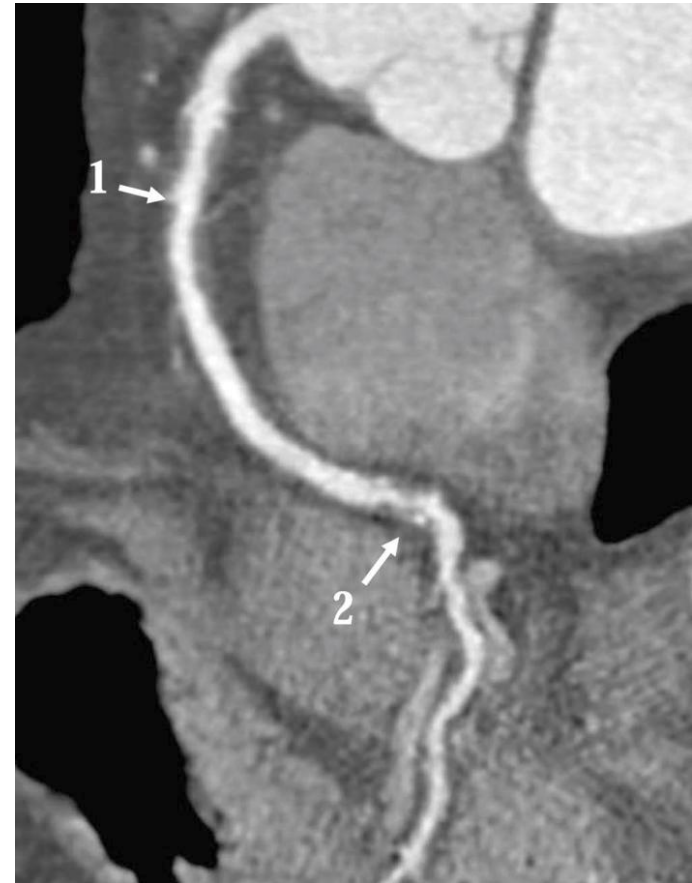Diagnosis: positron emission tomography



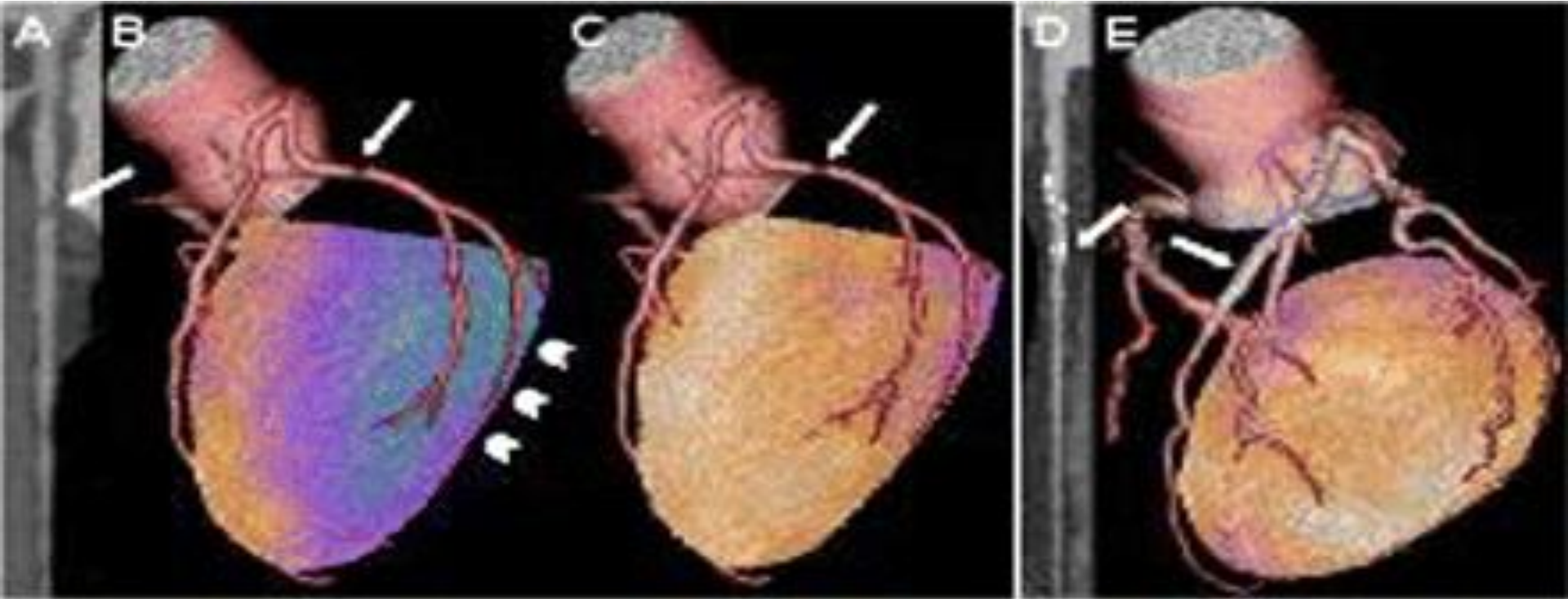
The infarct zone of the entire left ventricular myocardium.

Diagnosis: computed tomography

1. Mild proximal stenosis with expansive remodelling and predominantly nonexpansive plaque
2. Partially calcified advanced mid to distal stenosis



Diagnosis: hybrid imaging



Patient with silent ischemia. Cardiac hybrid imaging integrating single-photon emission computed tomography with computed tomography coronary angiography.

Diagnosis: blood test 1

- Lipid profile (LDL-C, HDL-C, cholesterol, triglycerides)
- CRP—C-reactive protein, a marker of inflammation that is associated with atherosclerosis, among other conditions
- Lp(a)—an additional lipid test that may be used to identify an elevated level of lipoprotein (a), a modification to LDL-C that increases risk of atherosclerosis; the test may be used in conjunction with a routine lipid profile to provide additional information

Diagnosis: blood test 2

Heart attacks tests:

- Troponin
- Myoglobin
- CK-MB
- Etc.

