

Technical University of Denmark



Evaluation of uterine ultrasound imaging in cervical radiotherapy; a comparison of autoscan and conventional probe

Baker, Mariwan; Cooper, David T.; Behrens, Claus F.

Published in:
British Journal of Radiology

Link to article, DOI:
[10.1259/bjr.20160510](https://doi.org/10.1259/bjr.20160510)

Publication date:
2016

Document Version
Publisher's PDF, also known as Version of record

[Link back to DTU Orbit](#)

Citation (APA):
Baker, M., Cooper, D. T., & Behrens, C. F. (2016). Evaluation of uterine ultrasound imaging in cervical radiotherapy; a comparison of autoscan and conventional probe. *British Journal of Radiology*, 89(1066), [20160510]. DOI: 10.1259/bjr.20160510

DTU Library

Technical Information Center of Denmark

General rights

Copyright and moral rights for the publications made accessible in the public portal are retained by the authors and/or other copyright owners and it is a condition of accessing publications that users recognise and abide by the legal requirements associated with these rights.

- Users may download and print one copy of any publication from the public portal for the purpose of private study or research.
- You may not further distribute the material or use it for any profit-making activity or commercial gain
- You may freely distribute the URL identifying the publication in the public portal

If you believe that this document breaches copyright please contact us providing details, and we will remove access to the work immediately and investigate your claim.

Received:
7 June 2016Revised:
12 July 2016Accepted:
21 July 2016<http://dx.doi.org/10.1259/bjr.20160510>

Cite this article as:

Baker M, Cooper DT, Behrens CF. Evaluation of uterine ultrasound imaging in cervical radiotherapy; a comparison of autoscan and conventional probe. *Br J Radiol* 2016; **89**: 20160510.

FULL PAPER

Evaluation of uterine ultrasound imaging in cervical radiotherapy; a comparison of autoscan and conventional probe

^{1,2,3}MARIWAN BAKER, PhD, ⁴DAVID T COOPER, BSc and ¹CLAUS F BEHRENS, PhD¹Department of Oncology, Radiotherapy Research Unit, Herlev Hospital, University of Copenhagen, Copenhagen, Denmark²Center for Fast Ultrasound Imaging, Department of Electrical Engineering, Technical University of Denmark, Lyngby, Denmark³Center for Nuclear Technologies, Technical University of Denmark, Roskilde, Denmark⁴Elekta Ltd., Montréal, QC, Canada

Address correspondence to: Dr Mariwan Baker

E-mail: mariwan.baker@regionh.dk

Objective: In cervical radiotherapy, it is essential that the uterine position is correctly determined prior to treatment delivery. The aim of this study was to evaluate an autoscan ultrasound (A-US) probe, a motorized transducer creating three-dimensional (3D) images by sweeping, by comparing it with a conventional ultrasound (C-US) probe, where manual scanning is required to acquire 3D images.

Methods: Nine healthy volunteers were scanned by seven operators, using the Clarity® system (Elekta, Stockholm, Sweden). In total, 72 scans, 36 scans from the C-US and 36 scans from the A-US probes, were acquired. Two observers delineated the uterine structure, using the software-assisted segmentation in the Clarity workstation. The data of uterine volume, uterine centre of mass (COM) and maximum uterine lengths, in three orthogonal directions, were analyzed.

Results: In 53% of the C-US scans, the whole uterus was captured, compared with 89% using the A-US. *F*-test on 36 scans demonstrated statistically significant

differences in interobserver COM standard deviation (SD) when comparing the C-US with the A-US probe for the inferior–superior ($p < 0.006$), left–right ($p < 0.012$) and anteroposterior directions ($p < 0.001$). The median of the interobserver COM distance (Euclidean distance for 36 scans) was reduced from 8.5 (C-US) to 6.0 mm (A-US). An *F*-test on the 36 scans showed strong significant differences ($p < 0.001$) in the SD of the Euclidean interobserver distance when comparing the C-US with the A-US scans. The average Dice coefficient when comparing the two observers was 0.67 (C-US) and 0.75 (A-US). The predictive interval demonstrated better interobserver delineation concordance using the A-US probe.

Conclusion: The A-US probe imaging might be a better choice of image-guided radiotherapy system for correcting for daily uterine positional changes in cervical radiotherapy.

Advances in knowledge: Using a novel A-US probe might reduce the uncertainty in interoperator variability during ultrasound scanning.

INTRODUCTION

In cervical radiotherapy organ motion, tumour regression and setup variations may occur and therefore, daily pre-treatment verification imaging is desirable.^{1,2} Recently, various three-dimensional (3D) ultrasound systems have been introduced as alternative inexpensive image-guided radiotherapy (IGRT), such as the Clarity® system, Model 310C00 (Elekta, Stockholm, Sweden).^{3–5}

In cervical IGRT, there are some challenges in using the ultrasound imaging system such as interoperator variability while performing transabdominal scans.⁶ Another drawback is that daily ultrasound probe pressure variations might cause prostate and target displacement.⁷ There is

limited literature on gynaecological ultrasound scan, but many articles on prostate ultrasound scanning. Some studies have claimed that prostate displacement might occur owing to probe pressure,^{8–11} while others have speculated that the impact on uterus displacement is less significant.¹²

The conventional ultrasound (C-US) probe is a frequently used ultrasound IGRT system. For example, the Clarity C-US probe, a transabdominal imaging tool, can acquire ultrasound images of the prostate in the transversal plane, using a manual sweep technique. Ultrasound scanning of the uterus requires a sweep-slide technique, which was shown to be cumbersome and might lead to undesired

interoperator variability.¹³ Moreover, operators experience a visual challenge in identifying the uterus in the transversal plane, although it is normally easily recognizable in the sagittal plane. In this study, a novel Clarity autoscan ultrasound (A-US) probe was utilized to acquire images in the sagittal plane. The A-US probe contains a mechanically motorized head, enabling automatic transabdominal sweep scans after manual positioning of the probe above the pubis symphysis. The A-US probe is the same probe¹⁴ that was initially designed for transperineal prostate scanning and real-time tracking of the prostate, to address intrafractional prostate motion, but redesigned to a smooth hand-held probe for acquiring transabdominal scans of uterus. The hypothesis of the present study was that the A-US probe may be a better IGRT alternative than the C-US probe in cervical radiotherapy, where the large uterine volume is possibly easier to capture using the A-US probe.

METHODS AND MATERIALS

Volunteers

Nine healthy volunteers, with a mean age of 44 years (27–57 years), were scanned by six radiation therapy technologists and one physicist. Each operator performed subsequent scanning with both C-US and A-US. The study was approved by the national ethical committee, and voluntary informed consent was obtained for each participant according to the *World Medical Association Declaration of Helsinki (1975/2000)*. The volunteers were placed in a supine position and instructed to remain still throughout the subsequent scans. To ensure better image quality, the volunteers were requested to comply with a moderate bladder-filling protocol.

Clarity ultrasound system

The Clarity system consists of two mobile units (one in the CT room and the second in the treatment room), which are connected through a workstation/server. The workstation was used for target delineation, measuring the uterine length as well as retrieving the volume (calculated by Clarity), distance and interobserver uterine volume overlap. Details of ultrasound 3D image reconstructions and precision of the system are explained thoroughly in a previous study.⁶ In short, a ceiling-mounted infrared (IR) camera, capable of tracking the ultrasound probes by monitoring the IR reflectors affixed to them, is central for determining the geographical position of the reconstructed anatomical structures ([Supplementary Figure A](#)).

Conventional ultrasound and autoscan ultrasound probes

The C-US probe consists of a transducer array of 128 elements, using a centre frequency of 3.4 ± 0.3 Mhz. The probe is provided with IR reflectors fixed in such a way that they can be detected by the ceiling-mounted IR camera [[Supplementary Figure A](#) (a,d,f)]. The camera cannot detect the reflectors if the probe is, for instance, turned 90°; thus, this restricts image acquisition to only the transversal plane. Initially, the probe is tilted backwards to localize the vaginal region, followed by sweeping to the vertical position. Approximately half of the uterine volume can be captured by the sweep; thus, a cranial slide technique is required to cover the rest of the uterus.

The A-US probe comprises a similar type of transducer, but with a centre frequency of 5.0 ± 0.5 MHz. Initially, and prior to acquiring the scan, the desired uterine structure is identified in the sagittal plane. The transabdominal scan is achieved by selecting a central slice of the uterine volume, and then allowing the motorized head to automatically sweep over the uterine volume.

Image acquisition and organ delineation

The C-US probe images, axial and sagittal images, superimposed to the A-US probe images without the application of any alignment shifts. In the Clarity workstation, this step is required to be able to read the interobserver values of delineated uterine structures. Two observers (MB and DTC), a physicist and an ultrasound specialist, independently delineated the uterine structure in the 72 acquired scans: 36 scans from the C-US and 36 scans from the A-US probe. To avoid biases, only one image (either C-US or A-US) was visible at a time while segmenting the uterine structure. The outlined uterine structures served to determine the interobserver contouring variability. Since the image acquisitions are acquired by different operators, the interoperator variability is immanent to the interobserver variability. The observer MB recontoured the uterine structure to investigate intraobserver variability. To prevent any recall bias when conducting the second segmentation of the same volunteer, the observer was not aware of the previous result and reanalyzed all the subsequent C-US and A-US images 2 weeks after the first delineation. The uterus delineation procedure was always carried out as follows: the observer outlined (free-hand delineation) the uterine structure in three slices in the transversal plane: one slice in the cranial and one slice in the caudal uterine peripheral endings, and a third slice at the centre of the uterus. Secondly, the uterus was outlined in the central sagittal slice. Finally, based on the manually drawn contours, the Clarity segmentation algorithm was used to segment the whole uterus. The algorithm in the workstation is available to use on any data set regardless of the probe used and the segmentation is reliant only on the image quality and the amount of the uterine body captured.

The same window and level settings of the segmentation algorithm were used for both observers. The algorithm is based on a discrete dynamic contouring algorithm. It starts with an initial contour and moves the points in a graded sequence to balance external forces (that push points towards gradients in the image) and internal forces (that maintain smoothness).^{15–17} The delineated uterine structures were classified into two groups: one group with all the scans and the other group with the best scans (scans where both C-US and A-US images showed the whole uterus).

Data collection and statistical analysis

The interobserver differences in uterine centre of mass (COM) position between Observer 1 (OBS 1) and Observer 2 (OBS 2) were calculated in the inferior–superior (I/S), left–right (L/R) and anteroposterior (A/P) directions, respectively. Furthermore, the overall mean [± 1 standard deviation (SD)] of the differences was calculated to compare the C-US and A-US probe scans. Moreover, the maximum uterine length (largest length of the

delineated uterus) was measured in the three directions. Finally, the Euclidean space distance (3D vector) of COM between OBS 1 and OBS 2 was calculated for both the C-US and the A-US probe scans.

In addition, an *F*-test was applied to compare the variance in interobserver COM differences for the C-US and A-US probes in all three cardinal directions. The null hypothesis was that there was no significant difference in variance. The *p*-values were calculated for a 95% confidence interval (CI). Statistical predictive inference was applied to illustrate the prediction interval for OBS 1 and OBS 2 in determining the uterine volume, when comparing the C-US and A-US probes. Similarly, the predictive inference was applied on the maximum uterine length to investigate whether the two observers were more concordant in uterine segmentations based on A-US images than on C-US images. Finally, the Dice coefficient or Sørensen–Dice index (DI) (ranges between 0 and 1) was utilized to check the overlap of the uterine volume outlined by OBS 1 (V_1) and the uterine volume outlined by OBS 2 (V_2) (Equation (1)). For the data and statistical analysis, the statistical program R (v. 2.15.3) was used.

$$DI = \frac{2|V_1 \cap V_2|}{|V_1| + |V_2|} \quad (1)$$

RESULTS

Figure 1(a,b) illustrates that the A-US probe can yield images with slightly better spatial resolution than the C-US probe. In addition, Figure 1(c,d) exemplifies a uterus scan where the image is incomplete using the C-US probe, owing to the difficulty in identifying the uterus in the transversal plane while manually scanning the pelvic region. As a result, the whole uterus was captured in only 19 (53%) scans using the C-US probe, whereas the corresponding figure for the A-US probe was 32 (89%).

Table 1 summarizes the calculated overall mean of interobserver COM differences using the C-US and A-US probes in all three orthogonal directions. Similarly, the computed mean of intraobserver COM differences are tabulated. When comparing the A-US with the C-US probe, the reduction in SD was statistically significant (*F*-test) in all three directions, the only exception being intraobserver delineations in the A/P direction. In addition, the largest interobserver difference was 23 mm in the A/P direction using the C-US probe, whereas the largest value was 9 mm in the I/S direction when using the A-US probe. Finally, the largest SD was found to be 6.6 mm for interobserver COM differences in the A/P direction using the C-US probe.

Application of the *F*-test on all 36 scans demonstrated a statistically significant different SD for interobserver COM when

Figure 1. Ultrasound images (two volunteers) using conventional ultrasound (C-US) and autoscan ultrasound (A-US) probes: (a) Ultrasound image of the bladder and uterus using the A-US probe in Volunteer 1. (b) Ultrasound image of the same volunteer but using the C-US probe, where image distortion and lower image quality can be observed. (c) Ultrasound image of Volunteer 2 using the A-US probe, where the whole uterus is captured. (d) Ultrasound image of the same volunteer but using the C-US probe, where only half of the uterus is imaged.

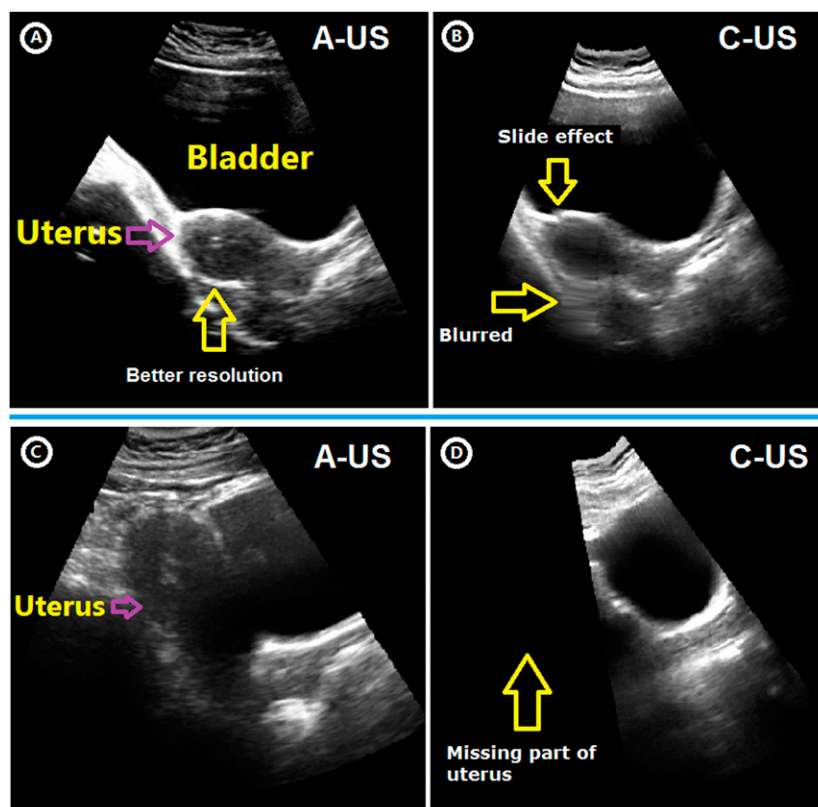


Table 1. Median and mean interobserver and intraobserver differences in uterine centre of mass (COM), maximum uterine lengths for the three directions and uterine volume using conventional ultrasound (C-US) and autoscan ultrasound (A-US) probes

	Interobserver ^a			Intraobserver ^b		
	Mean \pm 1SD (mm)			Mean \pm 1SD (mm)		
COM directions	C-US probe		A-US probe	C-US probe		A-US probe
I/S	3.2 \pm 6.3		1.8 \pm 3.9	-0.9 \pm 6.1		-1.3 \pm 3.2
L/R	0.9 \pm 5.5		0.0 \pm 3.6	0.2 \pm 5.8		-2.1 \pm 3.8
A/P	-0.4 \pm 6.6		0.4 \pm 3.6	-0.7 \pm 3.5		0.8 \pm 3.5
	C-US probe			A-US probe		
	Median/mean \pm 1SD (mm)			Median/mean \pm 1SD (mm)		
Maximum length	A/P	I/S	L/R	A/P	I/S	L/R
OBS 1	70/69 \pm 16	83/77 \pm 22	59/59 \pm 17	69/69 \pm 13	83/79 \pm 23	66/62 \pm 14
OBS 2	68/69 \pm 13	84/80 \pm 20	69/68 \pm 13	74/73 \pm 14	87/83 \pm 23	65/67 \pm 13
Uterine volume	C-US probe			A-US probe		
	Median/mean \pm 1SD (cc)			Median/mean [cc] \pm 1SD (cc)		
OBS 1	84/114 \pm 69			121/112 \pm 60		
OBS 2	124/120 \pm 47			129/137 \pm 63		

A/P, anteroposterior; I/S, inferior-superior; L/R, left-right; OBS 1, Observer 1; OBS 2, Observer 2; SD, standard deviation.

^aInterobserver: the differences between two observers.

^bIntraobserver: the differences between two delineations by the same observer.

comparing the C-US with the A-US probe for the I/S ($p < 0.006$), L/R ($p < 0.012$) and A/P directions ($p < 0.001$) (Table 2.). In contrast, the corresponding *F*-test on the best 19 scans indicated no significant differences, except for a weak difference in the A/P direction ($p < 0.04$).

Euclidean COM distances for interobserver and intraobserver scans were calculated (Figure 2). For interobserver and all scans (a), the median of the distances was reduced from 8.5 (C-US) to 6.0 mm (A-US), whereas for the best scans (b), the reduction was only from 5.3 (C-US) to 4.9 (A-US). However, the intra-observer graphs (c,d) illustrate that for all and for the best scans, the median of distance is around 5.0 mm, irrespective of whether the C-US or A-US probe was employed. Moreover, an *F*-test revealed that for all scans and interobserver COM distance, there

were strong significant differences in SD when comparing the C-US with the A-US probe scans ($p < 0.0001$). However, the difference was not significant for intraobserver distances.

The mean uterine volume was calculated as 117 \pm 59 and 125 \pm 64 cm³ for the C-US and A-US probe scans, respectively. The Dice coefficient index (mean value) was calculated as 0.67 and 0.75 for the C-US and A-US probe scans, respectively. Furthermore, when applying regression analysis for the uterine volume of OBS 1 as a function of the uterine volume of OBS 2, the predicted interval remained almost unchanged when comparing all C-US and A-US scans [Figure 3(a,b)]. However, for the best scans, the interval was obviously smaller for the A-US than for the C-US scans [Figure 3(c,d)]. Moreover, when analyzing the uterine volume delineated by the same observer (intraobserver), the predicted

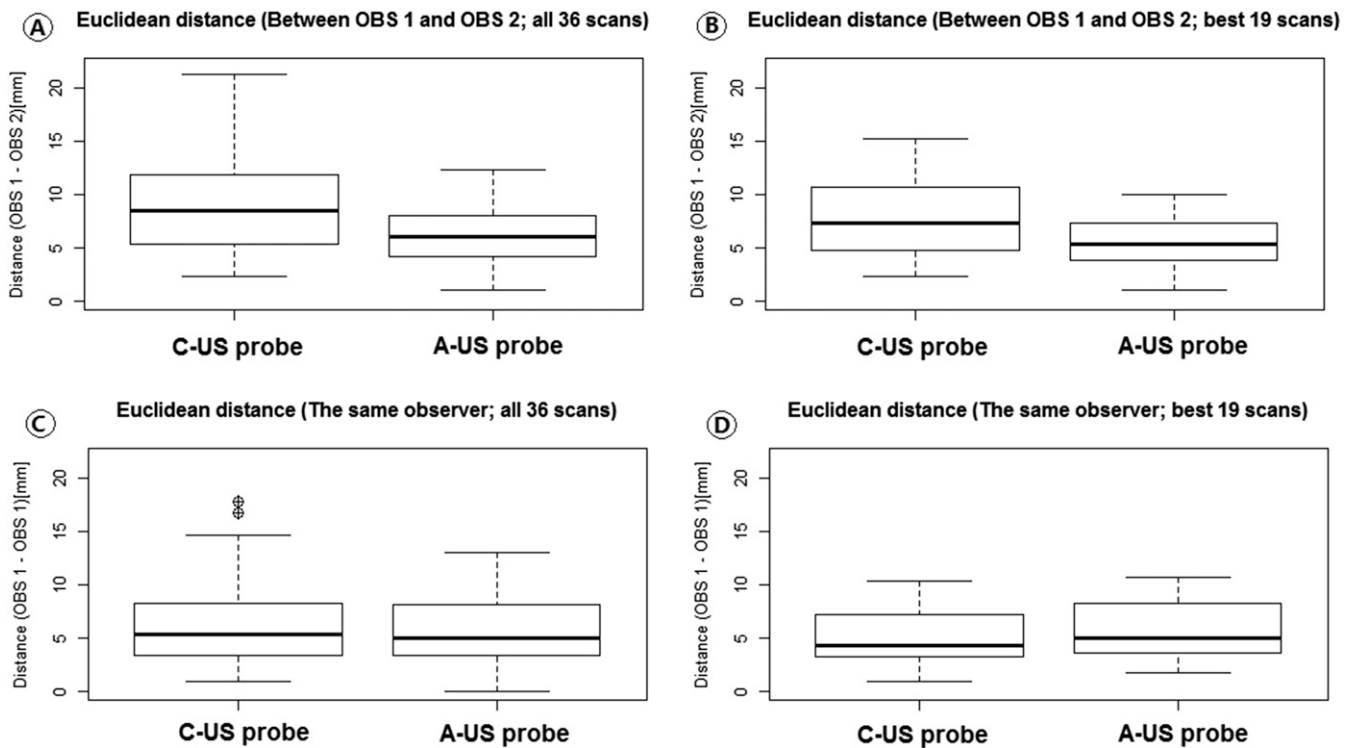
Table 2. *F*-test of the standard deviation for interobserver uterine centre of mass (COM) differences as well as interobserver and intraobserver Euclidean COM distances in all the three orthogonal directions (the test is performed for all scans and the best scans)

Directions	All scans ($n = 36$)			Best scans ^a ($n = 19$)		
	Ratio of variances	95% CI upper/lower	<i>p</i> -value	Ratio of variances	95% CI upper/lower	<i>p</i> -value
I/S	2.61	(1.33–5.33)	0.006	1.16	(0.45–3.01)	0.7571
L/R	2.38	(1.21–4.67)	0.012	1.84	(0.71–4.77)	0.2067
A/P	3.29	(1.68–6.45)	0.001	2.83	(1.09–7.35)	0.0331
Euclidean (interobserver)	4.90	(2.50–9.61)	0.000006			
Euclidean (intraobserver)	1.83	(0.93–3.59)	0.077			

A/P, anteroposterior; CI, confidence interval; I/S, inferior-superior; L/R, left-right.

^aBest scans: the ultrasound scans where the whole uterus is captured with both the autoscan ultrasound and conventional ultrasound probes.

Figure 2. Median (horizontal line), 25th and 75th percentiles (box) and range (whiskers) of Euclidean distances between uterine the centre of mass (COM) delineated by Observer 1 (OBS 1) and Observer 2 (OBS 2) and the same observer twice (OBS 1): (a, b) distance differences (OBS 1 – OBS 2) for the conventional ultrasound (C-US) and autoscans ultrasound (A-US) probes using all 36 scans and best 19 scans, respectively. (c, d) Distance differences [two delineations by the same observer (OBS 1)] for the C-US and A-US probes using all 36 scans and best 19 scans, respectively.



interval was significantly reduced for the A-US compared with the C-US scans, for all and for the best scans [Figure 3(e-h)].

Finally, the predictive interval was applied on the maximum uterine length for all 36 scans (Figure 4). The A-US scans revealed a smaller/narrower predictive interval compared with the C-US scans, especially in the I/S and A/P directions.

DISCUSSION

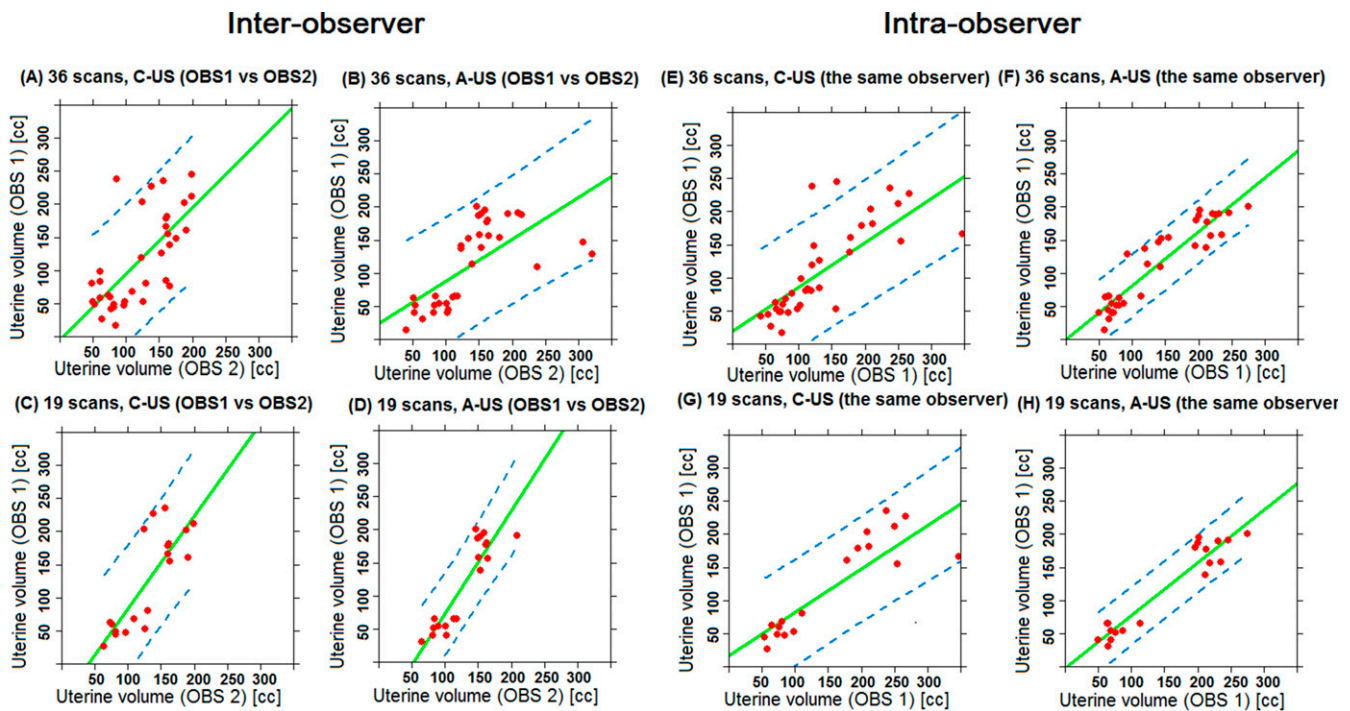
Transabdominal ultrasound imaging has been used as prostate interfraction IGRT; but, to our knowledge, there are very few studies employing such imaging in external cervical radiotherapy. A clinical trial for a cervical brachytherapy study comprising 192 patients, based on transabdominal ultrasound scan, was recently published.¹⁸ The study compared ultrasound imaging with MRI modality and demonstrated that the ultrasound scan can replace MRI as an alternative image-guided modality. Another brachytherapy study,¹⁹ also applying ultrasound transabdominal scan vs MRI and including 20 patients, verified a strong correlation between the modalities in uterine, cervical and central disease delineations. In a previous ultrasound study of the Clarity C-US probe on patients with cervical cancer, the pros and cons of the C-US probe system were addressed.¹³ Interoperator uncertainties due to the difficulty in performing sweep-slide imaging in addition to variation in the probe pressure limit the use of the C-US probe as a cervical IGRT system. Thus, the overall quality of the acquired ultrasound image is a result of a combination of different factors stemming,

particularly, from the operator performance. The American Association of Physicists in Medicine stresses that clinical ultrasound training of the operators is of utmost prominence.²⁰

The A-US transducer used in this study inherits identical characteristics as the real-time monitoring autoscans,¹⁴ initially designed for transperineal prostate tracking, but was modified to perform transabdominal imaging. Since the system was not provided with a robotic arm, and our software was not adapted for real-time monitoring, the probe was incapable of real-time tracking of the uterus and thus was unable to determine intra-fractional motion, which otherwise would be an interesting field to investigate. Even though there is no study regarding applying transperineal scan for the GYN patients, it is doubtful whether this technique is clinically possible owing to the complexity of the female anatomical structures and the large uterine volume.

All the operators in the present study reported that it was easier to handle the A-US probe, particularly when identifying the uterus and bladder in the sagittal plane; however, some of the operators, 11% of the A-US scans, were not able to capture the entire uterine volume. Furthermore, image acquisition was performed more quickly and less probe pressure was exerted during A-US probe scanning. Moreover, the image detail of the A-US probe scan was slightly better than that of the C-US probe [Figure 1(a,b)], the reason being the higher transducer frequency used in the former. The higher frequency provides better spatial (axial and lateral) resolution. In addition, the study

Figure 3. Comparison of the uterine volume delineated by Observer 1 (OBS 1) and Observer 2 (OBS 2) (a-d) and two independent delineations by OBS 1 (e-h) using conventional ultrasound (C-US) and autoscans ultrasound (A-US) probes. The left graphs are all 36 scans and the right graphs are best 19 scans. The regression (solid lines) and predicted interval (dashed lines) for 95% confidence interval are indicated. cc, cubic centimetre.



revealed that the A-US is superior to the C-US probe for capturing the whole uterine volume (Figure 1(c-d)).

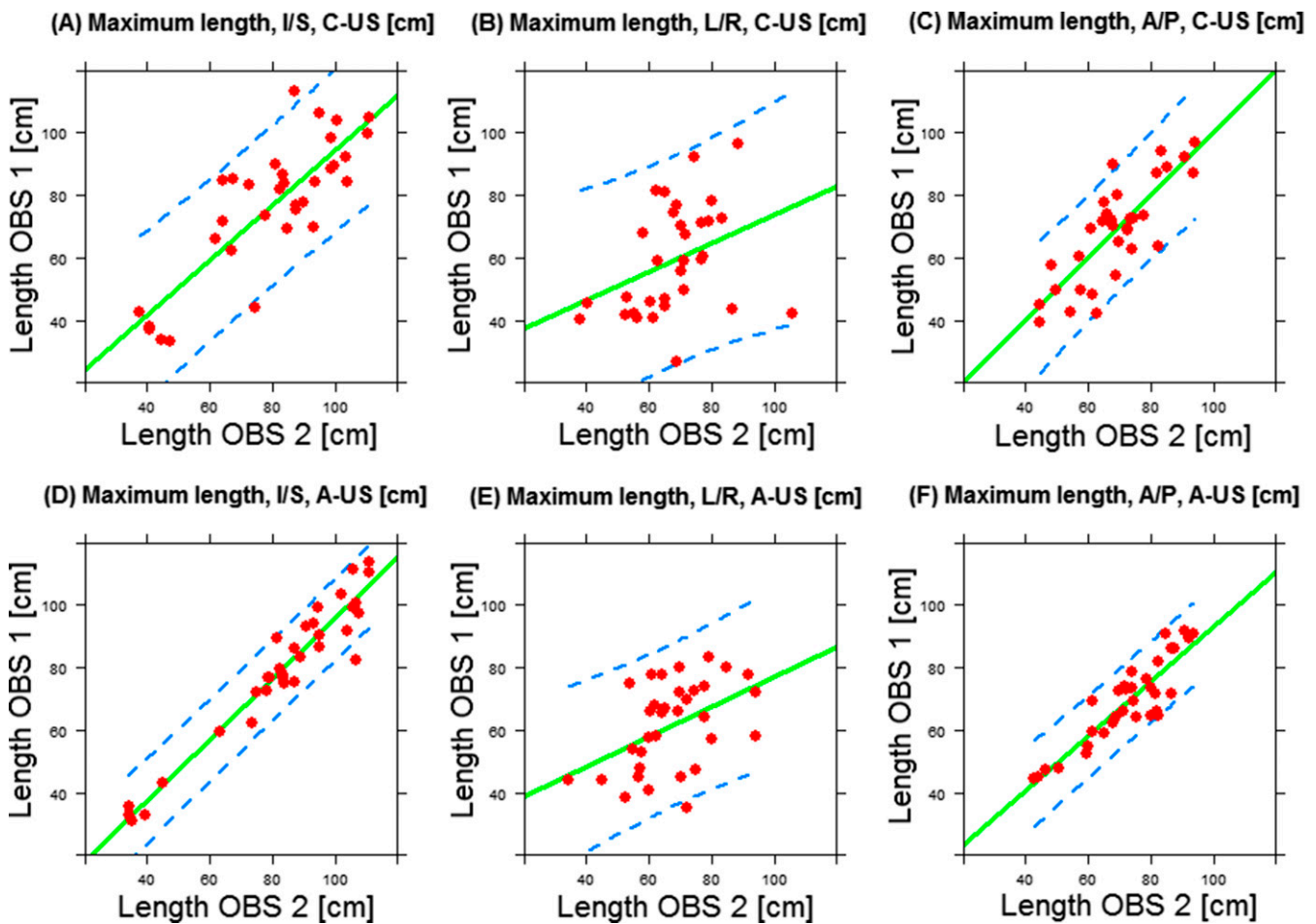
The SD of the COM differences demonstrated that the A-US probe scans resulted in less interobserver and intraobserver variability. The A-US probe also yielded a lower Euclidean median COM difference. However, for the best scans, the *F*-test indicated no statistically significant differences owing to better interobserver delineation concordance for scans with the whole uterus imaged, irrespective of the type of probe. These findings warranted further investigation of the uterine COM point by examining the Euclidean space distance between the C-US and A-US uterine COM. The interobserver box plot of Euclidean distances revealed a median distance reduction of 2.5 mm with the A-US probe. However, when the whole uterine volume was imaged (best scans), the benefit provided by the A-US probe was minimal (Figure 2b).

As one uterine COM point did not reveal substantial data on the outlined large uterine volume, the maximum uterine length in all three directions was examined. The predictive interval indicated better interobserver concordance when applying the A-US compared with the C-US probe. However, the benefit was limited in the L/R-direction, which can be attributed to the poor lateral image resolution in both the C-US and the A-US probe scans. Nevertheless, owing to better spatial resolution of the A-US probe images in the sagittal plane, especially in the vicinity of the fundus, bladder-uterus and the posterior part of the uterus, the observers were more consistent when using the A-US probe images than when using the C-US probe images.

The large SD of the uterine volume confirms significant interobserver contouring variability. This could result from the fact that in the “all scans” group, a number of scans do not contain an image of the whole uterus and therefore, the observers estimated the missing part, leading to larger variations. Another reason might be the challenge in contouring the uterine structure in the vaginal region, where larger interobserver deviations were anticipated. These results suggest the need for target delineation guidelines to improve contouring consistency and thus higher interobserver spatial concordance. To emphasize this necessity, the predictive interval indicated that the same observer most likely followed a similar delineation procedure, leading to less intraobserver variability compared with the discordance in interobserver delineation. However, the intraobserver results should be taken with caution, since they are based on only one observer.

The Dice coefficient index verified good concordance using the A-US probe (CI = 0.75) but only modest concordance with the C-US probe (CI = 0.67). The highest interobserver discordance stems from inaccurate uterine segmentation in the missing part of the imaged uterus using the C-US probe, which is eliminated while comparing the “best scans” group, in which the concordance is good for both A-US (CI = 0.75) and C-US (CI = 0.71). The present result is comparable with an MRI/CT-based cervix, uterus, vagina and parametria delineation study²¹ performed by 19 experienced observers, where the kappa value, a statistic tool to measure interobserver overlap agreement, for uterine delineation was 0.57 (the theoretical range of the kappa value is 0–1, where 0 implies no agreement and

Figure 4. Comparison of the maximum uterine length by Observer 1 (OBS 1) and Observer 2 (OBS 2) on conventional ultrasound (C-US) and autoscans (A-US) scans in the inferior-superior (I/S), left-right (L/R), and anteroposterior (A/P) directions. The regression line fit (solid lines) and the predicted interval (dashed lines) for 95% confidence interval are indicated. cm, centimetre.



1 reflects perfect agreement, and the range 0.41–0.60 interprets as moderate agreement).²²

Despite the promising results of using the A-US probe for IGRT, the present study suffers from statistical limitations. Firstly, this volunteer study should be replicated on patients with cervical cancer, including larger number of participants and greater number of acquired scans. The cervical tumour can, for instance, be large and deform the actual shape of the uterus, possibly leading to greater interobserver delineation variability. Secondly, the mean age of patients is normally higher than that of our volunteers (44 years). In the present study, we experienced that the uterine structure was easier to identify visually in the younger volunteers. Thirdly, target contouring should preferably be performed by several specialized radiologists and/or oncologists. Fourthly, despite the lack of clinical study regarding exerted probe pressure required to acquire sufficient image quality, the magnitude of the uterine displacement might be strongly correlated to the bladder-filling variations. Lastly, a quantitative image analysis of the C-US and A-US probe images, as well as a study of interoperator variability, is recommended for future study.

CONCLUSION

The A-US probe imaging might be a more accurate technology than the C-US probe imaging in terms of better spatial resolution, facilitating the capture of the whole uterus and less applied probe pressure. In our results, the A-US probe led to less interoperator variability and consequently less contouring variations. In conclusion, the A-US probe compared with the C-US probe ultrasound imaging might be a better IGRT system for correcting for daily uterine positional changes in cervical radiotherapy.

ACKNOWLEDGMENTS

We would like to thank all our colleagues who helped us conduct this study: Gullander L [radiation therapy technologist (RTT)], Pedersen S K (RTT) Zarp T (RTT), Jacobsson S (RTT), Pazhang S (radiographer) and Lynnerup VK (radiographer). We would also like to acknowledge Elekta's support for this study.

CONFLICTS OF INTEREST

The present study is a part of a 3-year PhD research project at Herlev, which is granted by Elekta, Inc.

REFERENCES

1. Beadle BM, Jhingran A, Salehpour M, Sam M, Iyer RB, Eifel PJ. Cervix regression and motion during the course of external beam chemoradiation for cervical cancer. *Int J Radiat Oncol Biol Phys* 2009; **73**: 235–41. doi: <http://dx.doi.org/10.1016/j.ijrobp.2008.03.064>
2. Chan P, Dinniwell R, Haider MA, Cho YB, Jaffray D, Lockwood G, et al. Inter- and intrafractional tumor and organ movement in patients with cervical cancer undergoing radiotherapy: a cinematic-MRI point-of-interest study. *Int J Radiat Oncol Biol Phys* 2008; **70**: 1507–15. doi: <http://dx.doi.org/10.1016/j.ijrobp.2007.08.055>
3. Baker M, Jensen JA, Behrens CF. Inter-operator variability in defining uterine position using three-dimensional ultrasound imaging. *2013 IEEE International Ultrasonics Symposium (IUS)*. IEEE; 2013. pp. 848–51.
4. Cury FL, Shenouda G, Souhami L, Duclos M, Faria SL, David M, et al. Ultrasound-based image guided radiotherapy for prostate cancer: comparison of cross-modality and intramodality methods for daily localization during external beam radiotherapy. *Int J Radiat Oncol Biol Phys* 2006; **66**: 1562–7. doi: <http://dx.doi.org/10.1016/j.ijrobp.2006.07.1375>
5. Pinkawa M, Pursch-Lee M, Asadpour B, Gagel B, Piroth MD, Klotz J, et al. Image-guided radiotherapy for prostate cancer. Implementation of ultrasound-based prostate localization for the analysis of inter- and intrafraction organ motion. *Strahlenther Onkol* 2008; **184**: 679–85. doi: <http://dx.doi.org/10.1007/s00066-008-1902-7>
6. Van der Meer S, Bloemen-van Gurp E, Hermans J, Voncken R, Heuvelmans D, Gubbels C, et al. Critical assessment of intramodality 3D ultrasound imaging for prostate IGRT compared to fiducial markers. *Med Phys* 2013; **40**: 071707. doi: <http://dx.doi.org/10.1118/1.4808359>
7. Artignan X, Smitsmans MH, Lebesque JV, Jaffray DA, van Her M, Bartelink H. Online ultrasound image guidance for radiotherapy of prostate cancer: impact of image acquisition on prostate displacement. *Int J Radiat Oncol Biol Phys* 2004; **59**: 595–601. doi: <http://dx.doi.org/10.1016/j.ijrobp.2004.01.043>
8. McGahan JP, Ryu J, Fogata M. Ultrasound probe pressure as a source of error in prostate localization for external beam radiotherapy. *Int J Radiat Oncol Biol Phys* 2004; **60**: 788–93. doi: <http://dx.doi.org/10.1016/j.ijrobp.2004.04.005>
9. Serago CF, Chungbin SJ, Buskirk SJ, Ezzell GA, Collie AC, Vora SA. Initial experience with ultrasound localization for positioning prostate cancer patients for external beam radiotherapy. *Int J Radiat Oncol Biol Phys* 2002; **53**: 1130–8. doi: [http://dx.doi.org/10.1016/S0360-3016\(02\)02826-2](http://dx.doi.org/10.1016/S0360-3016(02)02826-2)
10. Fargier-Voiron M, Presles B, Pommier P, Rit S, Munoz A, Liebgott H, et al. Impact of probe pressure variability on prostate localization for ultrasound-based image-guided radiotherapy. *Radiother Oncol* 2014; **111**: 132–7. doi: <http://dx.doi.org/10.1016/j.radonc.2014.02.008>
11. Fontanarosa D, van der Meer S, Bamber J, Harris E, O'Shea T, Verhaegen F. Review of ultrasound image guidance in external beam radiotherapy: I. Treatment planning and inter-fraction motion management. *Phys Med Biol* 2015; **60**: R77–114. doi: <http://dx.doi.org/10.1088/0031-9155/60/3/R77>
12. Baker M, Juhler-Nøttrup T, Behrens CF. Impact of ultrasound probe pressure on uterine positional displacement in gynecologic cancer patients. *Womens Health (Lond)* 2014; **10**: 583–90. doi: <http://dx.doi.org/10.2217/whe.14.49>
13. Baker M. Determining inter-fractional motion of the uterus using 3D ultrasound imaging during radiotherapy for cervical cancer. *Proc SPIE*. 2014; **9040**: 071707. doi: <http://dx.doi.org/10.1117/12.2043173>
14. Lachaine M, Falco T. Intrafractional prostate motion management with the clarity auto-scan system. *Med Phys Int* 2013; **1**: 72–80.
15. Ding M, Chiu B, Gyacskov I, Yuan X, Drangova M, Downey DB, et al. Fast prostate segmentation in 3D TRUS images based on continuity constraint using an autoregressive model. *Med Phys* 2007; **34**: 4109–25. doi: <http://dx.doi.org/10.1118/1.2777005>
16. Ding M, Chen C, Wang Y, Gyacskov I, Fenster A. Prostate segmentation in 3D US images using the cardinal-spline-based discrete dynamic contour. In: Galloway RL Jr, ed. *Proceedings of SPIE—the International Society for Optical Engineering*; 2003. pp. 69–76.
17. Ladak HM, Mao F, Wang Y, Downey DB, Steinman DA, Fenster A. Prostate boundary segmentation from 2D ultrasound images. *Med Phys* 2000; **27**: 1777–88. doi: <http://dx.doi.org/10.1118/1.1286722>
18. van Dyk S, Kondalsamy-Chennakesavan S, Schneider M, Bernshaw D, Narayan K. Comparison of measurements of the uterus and cervix obtained by magnetic resonance and transabdominal ultrasound imaging to identify the brachytherapy target in patients with cervix cancer. *Int J Radiat Oncol Biol Phys* 2014; **88**: 860–5. doi: <http://dx.doi.org/10.1016/j.ijrobp.2013.12.004>
19. Mahantshetty U, Khanna N, Swamidas J, Engineer R, Thakur MH, Merchant NH, et al. Trans-abdominal ultrasound (US) and magnetic resonance imaging (MRI) correlation for conformal intracavitary brachytherapy in carcinoma of the uterine cervix. *Radiother Oncol* 2012; **102**: 130–4. doi: <http://dx.doi.org/10.1016/j.radonc.2011.08.001>
20. Molloy JA, Chan G, Markovic A, McNeeley S, Pfeiffer D, Salter B, et al. Quality assurance of U.S.-guided external beam radiotherapy for prostate cancer: report of AAPM Task Group 154. *Med Phys* 2011; **38**: 857–71. doi: <http://dx.doi.org/10.1118/1.3531674>
21. Fyles AW, Lim K, Small W, Portelance L, Gaffney D, Erickson B, et al. Variability in delineation of clinical target volumes for cervix cancer intensity-modulated pelvic radiotherapy. *Int J Radiat Oncol Biol Phys* 2009; **75**: S83–4. doi: <http://dx.doi.org/10.1016/j.ijrobp.2009.07.208>
22. Landis JR, Koch GG. The measurement of observer agreement for categorical data. *Biometrics* 1977; **33**: 159–74. doi: <http://dx.doi.org/10.2307/2529310>