

Technical University of Denmark



## Baylisascaris procyonis in wild raccoons (*Procyon lotor*) in Denmark

**Al-Sabi, Mohammad Nafi Solaiman; Chriél, Mariann; Hansen, Mette Sif; Enemark, Heidi**

*Published in:*  
Parasitology (Cambridge)

*Link to article, DOI:*  
[10.1016/j.vprsr.2016.03.001](https://doi.org/10.1016/j.vprsr.2016.03.001)

*Publication date:*  
2015

*Document Version*  
Publisher's PDF, also known as Version of record

[Link back to DTU Orbit](#)

*Citation (APA):*  
Al-Sabi, M. N. S., Chriél, M., Hansen, M. S., & Enemark, H. (2015). Baylisascaris procyonis in wild raccoons (*Procyon lotor*) in Denmark. Parasitology (Cambridge), 1-2, 55-58. DOI: 10.1016/j.vprsr.2016.03.001

## DTU Library

Technical Information Center of Denmark


---

### General rights

Copyright and moral rights for the publications made accessible in the public portal are retained by the authors and/or other copyright owners and it is a condition of accessing publications that users recognise and abide by the legal requirements associated with these rights.

- Users may download and print one copy of any publication from the public portal for the purpose of private study or research.
- You may not further distribute the material or use it for any profit-making activity or commercial gain
- You may freely distribute the URL identifying the publication in the public portal

If you believe that this document breaches copyright please contact us providing details, and we will remove access to the work immediately and investigate your claim.



## Short Communication

*Baylisascaris procyonis* in wild raccoons (*Procyon lotor*) in DenmarkMohammad Nafi Solaiman Al-Sabi<sup>a</sup>, Mariann Chriél<sup>a</sup>, Mette Sif Hansen<sup>b</sup>, Heidi Larsen Enemark<sup>a,c,\*</sup><sup>a</sup> Section for Diagnostics and Scientific Advice, National Veterinary Institute, Technical University of Denmark, DK-1870, Frederiksberg C, Denmark<sup>b</sup> Section for Bacteriology and Pathology, National Veterinary Institute, Technical University of Denmark, DK-1870, Frederiksberg C, Denmark<sup>c</sup> Norwegian Veterinary Institute, P.O. Box 750 Sentrum, NO-0106 Oslo, Norway

## ARTICLE INFO

## Article history:

Received 3 December 2015

Received in revised form 26 February 2016

Accepted 1 March 2016

Available online 3 March 2016

## Keywords:

*Baylisascaris procyonis*

Raccoon

Invasive species

Denmark

## ABSTRACT

The nematode *Baylisascaris procyonis*, which may cause severe clinical disease in humans and animals, is emerging in Europe after its introduction with raccoons (*Procyon lotor*) from North America. *B. procyonis* has a broad spectrum of paratenic hosts, including rodents, birds, wild carnivores and primates, which are severely affected by the migrating larval stages of the parasite. We report here the recovery of *B. procyonis* from two out of 18 examined wild raccoons in Denmark. The parasites were identified based on morphology and their identity was confirmed by partial sequencing of the 18S rRNA gene. Follow-up telephone interviews of staffs in nine zoos housing captive raccoons and veterinarians supervising these zoos showed that knowledge of *B. procyonis* and its zoonotic potential were sparse. Eggs of *B. procyonis* were detected in two raccoons kept in one of three zoos that submitted fecal samples following the telephone interviews. Continuous monitoring and increased awareness are needed to reduce further spread of the parasite and to limit the public health risks associated with baylisascariasis.

© 2016 The Authors. Published by Elsevier B.V. This is an open access article under the CC BY-NC-ND license (<http://creativecommons.org/licenses/by-nc-nd/4.0/>).

## 1. Introduction

*Baylisascaris procyonis* is an ascarid nematode that can cause severe disease in humans and animals. The parasite is indigenous to North America (Bowman, 2003) and emerging in Europe (Beltrán-Beck et al., 2012). *B. procyonis* has an indirect life cycle with raccoons (*Procyon lotor*) as definitive host (DH) and more than 130 vertebrate species, including rodents, birds, wild carnivores, pets and primates as potential paratenic hosts (PH) (Kazacos et al., 2013). Following ingestion of infective eggs by PH the larvae develop rapidly, reaching up to 1.9 mm in size 15 days post infection (Kazacos and Boyce, 1989). The larvae migrate to vital organs including liver, lung, eye and brain where they may cause visceral (VLM), ocular (OLM), cutaneous (CLM) or neural larva migrans (NLM) (Gavin et al., 2005). It has been approximated that around 5% of the migrating larvae invade the brain (Tiner, 1953). Symptoms caused by NLM include depression, lethargy, opisthotonus, nystagmus, and various degrees of motor weakness, which ultimately may lead to head and/or body torticollis, lateral recumbency, coma and death (Kazacos and Boyce, 1989; Sheppard and Kazacos, 1997). Weakening and marked reduction in the survival of infected PH are well documented (Kazacos, 2001; LoGiudice, 2003; Page et al., 2012). In humans, baylisascariasis may induce severe neurological disease or death (Kazacos et al., 2013), although asymptomatic infections are probably more common (Murray and Kazacos, 2004; Pai et al., 2007). The possible contribution

of *B. procyonis* to local extinction of native rodent species, for example the Allegheny woodrat (*Neotoma magister*) (Page et al., 2012), signifies the threat induced by this parasite to biodiversity. The eggs are highly resistant and can stay infective for many years (Gavin et al., 2005), which is one of the major challenges for the control of *B. procyonis* (Page et al., 1999).

*B. procyonis* was introduced in Europe in the early 20th century via imported raccoons. Since, the parasite has become endemic in several European countries (Gey, 1998; Beltrán-Beck et al., 2012; Davidson, 2012). So far a limited number of infections have been reported in PH in Europe, but one NLM infection in a beaver (Koch and Rapp, 1981), one human case of OLM (Küchle et al., 1993) and two seropositive human cases (Conraths et al., 1996) have been described. In Denmark, *B. procyonis* has only been reported once in captive raccoons from a zoo (Brinch, 2006). Here we report *B. procyonis* for the first time in wild raccoons in Denmark. The parasites were detected on two separate occasions. Following these findings we initiated an epidemiological survey among Danish mini zoos with captive raccoons to assess the level of knowledge about the parasite and the potential public health risks related to its presence.

## 2. Materials and methods

## 2.1. Case description

As part of a wildlife surveillance program conducted by the National Veterinary Institute, Technical University of Denmark, 18 raccoons underwent post mortem examination including coprological analysis

\* Corresponding author at: Norwegian Veterinary Institute, P.O. Box 750 Sentrum, NO-0106 Oslo, Norway.

E-mail address: [heidi.enemark@vetinst.no](mailto:heidi.enemark@vetinst.no) (H.L. Enemark).

for detection of parasites. The raccoons were road-killed, hunted or found dead between October 2009 and February 2015. Prior to examination, the carcasses were stored at  $-80^{\circ}\text{C}$  for at least 4 days to reduce the risk of transmission of zoonotic infections. All raccoons, except one from the island of Zealand, were sampled in Jutland. Year of sampling and geographical origin of raccoons included in the study are presented in Fig. 1.

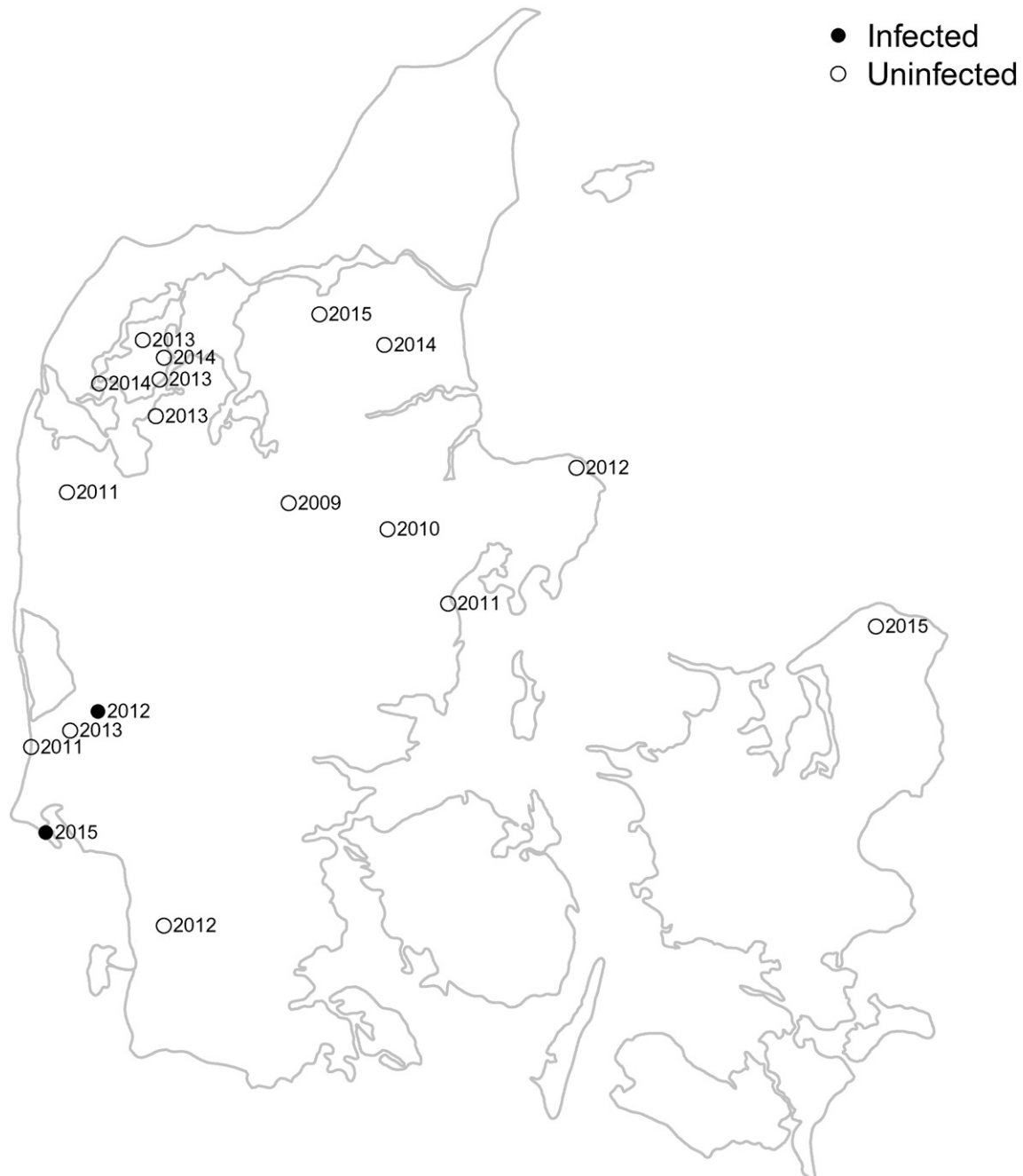
## 2.2. Telephone interview of nine zoos with captive raccoons

In order to collect information about management of raccoons and to raise the awareness of the risk of infection with *B. procyonis*, staff ( $n = 9$ ) in nine zoos with captive raccoons and the local veterinarians ( $n = 9$ ) were contacted by telephone. Zoos with captive raccoons included in the study were identified through their homepages.

Information about number of raccoons, handling of feces, tests for parasites and/or anthelmintic treatment was obtained from the zoo staff and information concerning awareness of the zoonotic potential of raccoon parasites and the methods used for surveillance of parasites in the captive raccoons were obtained from the veterinarians. All participating zoos were offered free coprological analysis of raccoons for detection of parasites.

## 2.3. Parasite recovery and identification

Intestinal helminths were recovered using the sedimentation and counting technique (Hofer et al., 2000). Morphological identification of ascarid worms and eggs was based on the criteria reported by Sprent (1968), and parasite eggs from fecal samples were quantified using a modified McMaster technique (Roepstorff and Nansen, 1998).



**Fig. 1.** Map of Denmark showing year of sampling and geographical origin of wild raccoons infected with *Baylisascaris procyonis* ( $N = 2$ , black dots). Origin and year of sampling of uninfected wild raccoons ( $N = 16$ ) are presented as open circles.

#### 2.4. Molecular analysis

One worm from the intestines of each of the *B. procyonis* positive cases was subjected to molecular analysis for diagnostic verification. DNA was extracted from a small piece (approximately 0.5 cm) of worm tissue by bead beating using FastPrep®-24 (MP Biomedicals Inc., France). The magnetic beads were 2 mm in diameter, and the bead beating was done in three intervals of 60 s, each with 0.5 ms of increments. The DNA was then purified using a commercial kit (QIAmp DNA Mini Kit®, Qiagen GmbH, Hilden, Germany), and a fragment of the small subunit 18S ribosomal RNA (SSU rRNA) gene was amplified using the Nem 18S F/R primers (Floyd et al., 2005). The polymerase chain reaction (PCR) was performed in 25 µl volumes using 0.02 U/µl of Phusion® High-Fidelity DNA Polymerase (New England Biolabs, Ipswich, USA). PCR products were sequenced in both directions using ABI Prism Big Dye Terminator v 3.1 Sequencing Kit (Applied Biosystems, Foster City, CA). The consensus sequences were compared to sequences available in GenBank by BLASTn analysis.

### 3. Results

Two of the 18 (11%) examined raccoons were infected with ascarids. Case no. 2012-52-81: adult male raccoon weighing 6.5 kg, road-killed in December 2011 in Lyne, in the central part of Jutland, Denmark. The raccoon was in a good body condition with moderate fat deposits. Examination of the intestinal contents revealed the presence of six *B. procyonis*: four males (6.9–14.6 cm), and two females (16.0 cm and 18.7 cm). Additionally, one male *Toxascaris leonina* was identified. By McMaster analysis 760 ascarid eggs/g of feces were detected. Morphological differentiation of ascarid eggs was not performed.

Case no. 15-13670: adult male raccoon found dead in February 2015 in Skallingen, less than 50 km from the origin of case no. 2012-52-81. This raccoon was apparently healthy and in good body condition with moderate fat deposits. Three ascarid worms, identified as *B. procyonis*, were detected in the small intestines: one male worm (8.1 cm) and two juvenile worms (one male: 1.8 cm, and one female: 2.1 cm). No ascarid eggs were detected by coprological examination.

The morphological identification of worms was supported by the results of the molecular analyses. The amplified fragments (815 base pairs) of the 18S rRNA gene were 100% identical to two *B. procyonis* isolates in GenBank (KC172105 from Norway and U94368 from USA). Sequences generated in the present study were uploaded to GenBank under the accession numbers KU050691 (2012-52-81) and KU050692 (15-13670).

The number of raccoons in the zoos varied from two to six animals. The staff in eight out of nine zoos had never heard of *B. procyonis* and consequently had no knowledge about the zoonotic potential of this parasite. Only one zoo performed regular parasitic analyses as part of their health control, and only one out of nine veterinarians included in the telephone interviews had knowledge of the zoonotic potential of *B. procyonis*. None of the veterinarians knew how to differentiate ascarid type eggs microscopically. In four zoos diagnostic parasitic analyses were not carried out regularly, and four other zoos never performed coprological analyses. None of the zoos had implemented special measures to secure safe management of the raccoon feces. Following the interviews, three veterinarians submitted fecal samples from captive raccoons from the zoos they advised. The eggs of *B. procyonis* were found in two raccoons (180 and 1050 eggs/g of feces, respectively) from one of these zoos. The eggs (N = 10) measured: 56.3–61.3 × 65.2–75.1 µm.

### 4. Discussion

This is the first report of *B. procyonis* in wild raccoons in Denmark, reported only a few years after the first finding of *B. procyonis* in captive

raccoons in Danish zoos (Brinch, 2006). Infected raccoons reported here as well as those reported by Brinch (2006) were all found in the southern part of the peninsula of Jutland. It is unknown if the infected wild raccoons were released/escaped into the Danish nature or if they had immigrated from neighboring Germany. In this context it is worth mentioning that spread of *B. procyonis* from infected captive raccoons can be prevented by regular anthelmintic treatment, sanitation of their cages and relevant equipment with boiling water, and burning of feces and top soil, which has been in contact with the raccoons' latrines (Kazacos, 2001).

In endemic areas in North America, high prevalence rates of *B. procyonis* were recorded in several raccoon populations, reaching up to 90% (Kazacos et al., 2013). In those areas, OLM and fatal cases of NLM infections were reported from several cases, especially among children (Gavin et al., 2005; Page et al., 2009). In Europe, OLM has been reported in a German patient who kept a pet raccoon (Küchle et al., 1993), and VLM has been reported in two animal caretakers also in Germany (Conraths et al., 1996). The general trend of higher prevalence of *B. procyonis* infection among raccoons in rural settings (Blizzard et al., 2010; Page, 2013) increases the risk of human exposure when raccoons migrate to urban areas in search for food. Thus, limiting human exposure to raccoons is recommended to reduce the risk of human baylisascariasis (Gavin et al., 2005).

The raccoon is regarded as an invasive species in Denmark and may therefore be hunted all year round. Raccoons were first included in the national statistics in the hunting season 2012–13. Since then, 12 and 30 raccoons were reported to the Danish Game Bag Statistics during the hunting seasons 2013–14 and 2014–15, respectively (Asferg, 2014). Hunted raccoons were reported from 14 different locations all over Denmark but mainly from the southern part of Jutland. In 2014, a new legislation came into force (legislation no. 208 published by the Ministry of Food on 06/03/2014), which stated that all privately owned animals, that are considered dangerous, such as raccoons, should be registered by the Danish Veterinary and Food Administration. The intention was to ensure that such animals carry unique identification (e.g. chip mark), that they are neutered and that they can only be handed over to zoos or exported. However, while this report is written unregistered raccoons are still for sale online in Denmark.

One major concern related to the presence of *B. procyonis* in wildlife is its ability to infect dogs who can act as both paratenic and definitive host for the parasite (Miyashita, 1993; Averbek et al., 1995; Thomas, 1988; Bowman et al., 2005) thereby increasing the risk of zoonotic transmission to pet owners as well as professionals such as veterinarians. Our study demonstrated that Danish zoo veterinarians and zoo staff were generally unaware of the possible presence of *B. procyonis* in captive raccoons and its zoonotic potential. Further, they had no knowledge about the morphological resemblance of *B. procyonis* eggs and other ascarid type eggs, which may prevent timely detection of the parasite. Differential diagnosis between ascarid species can be achieved by morphological analysis of adult worms or careful examination of eggs (Kazacos, 2001) and by using molecular methods (Dangoudoubiyam et al., 2009).

In conclusion, *B. procyonis* was recovered from captive raccoons and detected for the first time in wild raccoons in Denmark. Due to the high morphological similarity of *B. procyonis* eggs and other ascarid type eggs coprological differentiation is difficult, and the prevalence may be underreported. Continuous monitoring and increased awareness are needed to reduce further spread of the parasite and limit the public health risks associated with baylisascariasis.

### Acknowledgments

Surveillance of diseases in wildlife was financed by the Danish Forest and Nature Agency, project no. NST-410239.

## References

- Asferg, T., 2014. Kvalitetssikring af indberetninger af vaskebjørnen til vildtudbyttestatistik for jagtsæsonen 2012/13 (in Danish). Danish Centre for Environment and Energy, Aarhus University, Denmark.
- Averbeck, G.A., Vanek, J.A., Stromberg, B.E., Laursen, J.R., 1995. Differentiation of *Baylisascaris* species, *Toxocara canis*, and *Toxascaris leonina* infections in dogs. *Compend. Contin. Educ. Pract. Vet.* 17, 475–478.
- Beltrán-Beck, B., García, F.J., Gortázar, C., 2012. Raccoons in Europe: disease hazards due to the establishment of an invasive species. *Eur. J. Wildl. Res.* 58, 5–15.
- Blizzard, E.L., Davis, C.D., Henke, S., Long, D.B., Hall, C.A., Yabsley, M.J., 2010. Distribution, prevalence, and genetic characterization of *Baylisascaris procyonis* in selected areas of Georgia. *J. Parasitol.* 96, 1128–1133.
- Bowman, D.D. (Ed.), 2003. *Georgis' Parasitology for Veterinarians*. Saunders, St. Louis, Missouri.
- Bowman, D.D., Ulrich, M.A., Gregory, D.E., Neumann, N.R., Legg, W., Stansfield, D., 2005. Treatment of *Baylisascaris procyonis* infections in dogs with milbemycin oxime. *Vet. Parasitol.* 129, 285–290.
- Brinch, K.S., 2006. *Baylisascaris procyonis* (vaskebjørnens spolorm) hos danske vaskebjørne – en parasit med stor zoonotisk betydning (in Danish). *Dan. Vet. Tidsskr.* 89, 28–34.
- Conraths, F.J., Bauer, C., Cseke, J., Laube, H., 1996. Arbeitsplatzbedingte Infektionen des Menschen mit dem Waschbärpulwurm *Baylisascaris procyonis* (in German). *Arbeitsmed. Sozialmed. Umweltmed* 31, 13–17.
- Dangoudoubiyam, S., Vemulapalli, R., Kazacos, K.R., 2009. PCR assays for detection of *Baylisascaris procyonis* eggs and larvae. *J. Parasitol.* 95, 571–577.
- Davidson, R.K., 2012. Norwegian NRL for *Trichinella*. Oral Presentation in a Workshop at the Istituto Superiore di Sanità (ISS) (Rome, Italy).
- Floyd, R.M., Rogers, A.D., Lambshead, P.J.D., Smith, C.R., 2005. Nematode-specific PCR primers for the 18S small subunit rRNA gene. *Mol. Ecol. Notes* 5, 611–612.
- Gavin, P.J., Kazacos, K.R., Shulman, S.T., 2005. Baylisascariasis. *Clin. Microbiol. Rev.* 18, 703–718.
- Gey, A.B., 1998. Synopsis der Parasitenfauna des Waschbaren (*Procyon lotor*) unter Berücksichtigung von Befunden aus Hessen (in German) PhD thesis Justus Liebig Universität, Fachbereich Veterinärmedizin, Giessen, Germany (203 pp.).
- Hofer, S., Gloor, S., Müller, U., Mathis, A., Hegglin, D., Deplazes, P., 2000. High prevalence of *Echinococcus multilocularis* in urban red foxes (*Vulpes vulpes*) and voles (*Arvicola terrestris*) in the city of Zurich, Switzerland. *Parasitol.* 120, 135–142.
- Kazacos, K.R., 2001. *Baylisascaris procyonis* and related species. In: Samuel, W.M., Pybus, M.J., Kocan, A.J. (Eds.), *Parasitic Disease of Wild Mammals*, 2nd ed. Iowa State University Press, Ames, IA, pp. 301–341.
- Kazacos, K.R., Boyce, W.M., 1989. *Baylisascaris larva migrans*. *J. Am. Vet. Med. Assoc.* 195, 894–903.
- Kazacos, K.R., Jelicks, L.A., Tanowitz, H.B., 2013. Chapter 20: *Baylisascaris larva migrans*. *Handbook of Clinical Neurology* vol. 114, pp. 251–262 (3rd series). (Neuroparasitology and Tropical Neurology, H.H. Garcia, H.B. Tanowitz, and O.H. Del Brutto, Eds. Elsevier B.V.).
- Koch, F., Rapp, J., 1981. Zerebrale Nematodiasis bei Sumpfbibern (*Myocastor coypus*) – verursacht durch Larven von *Baylisascaris* (Nematoda) (in German). *Berl. Munch. Tierarztl. Wochenschr.* 94, 111–114.
- Küchle, M., Knorr, H.L.J., Medenblik-Frysch, S., Weber, A., Bauer, C., Naumann, G.O.H., 1993. Diffuse unilateral subacute neuroretinitis syndrome in a German most likely caused by the raccoon roundworm, *Baylisascaris procyonis*. *Graef. Arch. Clin. Exp.* 231, 48–51.
- LoGiudice, K., 2003. Trophically transmitted parasites and the conservation of small populations: raccoon roundworm and the imperiled Allegheny woodrat. *Conserv. Biol.* 17, 258–266.
- Miyashita, M., 1993. Prevalence of *Baylisascaris procyonis* in raccoons in Japan and experimental infections of the worm to laboratory animals (in Japanese). *J. Urban Living Health Assoc.* 37, 137–151.
- Murray, W.J., Kazacos, K.R., 2004. Raccoon roundworm encephalitis. *Clin. Infect. Dis.* 39, 1484–1492.
- Page, L.K., 2013. Parasites and the conservation of small populations: the case of *Baylisascaris procyonis*. *Inter. J. Parasitol. Parasit. Wildl.* 2, 203–210.
- Page, L.K., Swihart, R.K., Kazacos, K.R., 1999. Implications of raccoon latrines in the epizootiology of baylisascariasis. *J. Wildl. Dis.* 35, 474–480.
- Page, L.K., Johnson, S.A., Swihart, R.K., Kazacos, K.R., 2012. Prevalence of *Baylisascaris procyonis* in habitat associated with Allegheny woodrat (*Neotoma magister*) in populations in Indiana. *J. Wildl. Dis.* 48, 503–507.
- Page, L.K., Anchor, C., Luy, E., Kron, S., Larson, G., Madsen, L., Kellner, K., Smyser, T.J., 2009. Backyard raccoon latrines and risk for *Baylisascaris procyonis* transmission to humans. *Emerg. Infect. Dis.* 15, 1530–1531.
- Pai, J.P., Blackburn, B.J., Kazacos, K.R., Warrior, R.P., Bégué, R.E., 2007. Full recovery from *Baylisascaris procyonis* eosinophilic meningitis. *Emerg. Infect. Dis.* 13, 928–930.
- Roepstorff, A., Nansen, P. (Eds.), 1998. *Epidemiology, Diagnosis and Control of Helminth Parasites of Swine*. FAO Animal Health Manual, Rome, Italy.
- Sheppard, C.H., Kazacos, K.R., 1997. Susceptibility of *Peromyscus leucopus* and *Mus musculus* to infection with *Baylisascaris procyonis*. *J. Parasitol.* 83, 1104–1111.
- Sprent, J.F., 1968. Notes on *Ascaris* and *Toxascaris*, with a definition of *Baylisascaris* gen.nov. *Parasitology* 58, 185–198.
- Thomas, J.S., 1988. Encephalomyelitis in a dog caused by *Baylisascaris* infection. *Vet. Pathol.* 25, 94–95.
- Tiner, J.D., 1953. Fatalities in rodents caused by larval *Ascaris* in the central nervous system. *J. Mammal.* 34, 153–167.