

Kainic Acid-Induced Eye Enlargement in Chickens: Differential Effects on Anterior and Posterior Segments

C. F. Wildsoer*† and J. D. Pettigrew†

Intravitreal injections of kainic acid were used to examine the significance of normal retinal activity for eye growth in chickens, this acid being chosen because of its known, selective neurotoxic effects on cells in the chicken retina. A 6 nmole dose of kainic significantly reduces amacrine cell numbers when used in very young chickens, while higher doses of kainic acid also affect bipolar and horizontal cell numbers. The effects of intravitreal injection of kainic acid on eye growth were assessed 4 weeks after treatment. A 200 nmole dose of kainic acid, used with day-old and 14-day-old chickens, had opposing effects on the anterior and posterior segments of the eye; while growth of the anterior segment was inhibited, the posterior segment was enlarged, predominantly in the equatorial direction. A 20 nmole dose of this acid similarly affected growth in 14-day-old chickens, but in day-old chickens, the anterior segment was also enlarged and the overall eye enlargement had an axial bias. Myopia was the most common refractive error associated with both patterns of development. A 2 nmole dose of kainic acid was without effect on eye growth. Parallels are drawn between these eye enlargement phenomena and those described in chickens whose visual environments have been manipulated. Our results indicate that normal retinal activity is fundamental to normal eye growth in chickens, and furthermore, that growth of the anterior and posterior segments of the chicken eye are independently regulated. Invest Ophthalmol Vis Sci 29:311-319, 1988

Environmental influences are thought to play a part in the development of myopia in humans.¹ However, experiments designed to examine this possibility are fraught with logistical problems. These problems are largely avoided when animal models are available and it has now been shown that myopia can be induced reliably in monkeys,^{2,3} tree shrews⁴ and chickens⁵ by appropriate manipulation of their visual environments. Axial elongation of the eye is largely responsible for the myopia in these animals just as in humans it is axial length which undergoes the primary change during childhood development of myopia.⁶

Chickens have been used extensively in myopia research. High myopia and eye enlargement are induced in these animals by lid suturing⁷ and certain forms of field occlusion.^{5,8} These procedures are used to degrade retinal image quality and thus to disrupt form vision. Chickens reared either in continuous light⁹⁻¹² or in total darkness¹³⁻¹⁵ also show excessive

eye growth, with both the anterior and posterior segments of the eye exhibiting differential growth patterns for some of these treatments. Dramatic increases in anterior chamber depth are induced by full-field occlusion⁵ and a similar pattern (though not always as dramatic) is seen in lid-sutured animals.^{5,16} In contrast, anterior chamber depth is reduced in animals reared in continuous light^{11,13} or continuous dark.^{15,17} Some treatments also appear to produce differential growth of axial and equatorial dimensions.^{8,18,19} Frontal field occlusion¹⁸ and dark rearing¹⁵ both produce greater equatorial enlargement than axial enlargement, while full field occlusion appears to produce more symmetrical changes.^{8,18} All of these treatments involve manipulation of retinal light levels and thus presumably retinal neural activity.

The purpose of the experiments described here was to investigate the significance of retinal activity for anomalous eye growth in chickens. Kainic acid was used to modify retinal activity. This acid is an analog of glutamate which is a putative retinal neurotransmitter,²⁰ but it is also neurotoxic; its effects on chicken retina appear to be receptor-mediated²¹ and are cell-selective and dose-dependent, but irreversible.²² An appropriate intermediate dose of kainic acid selectively eliminates retinal off-responses.²³ Higher doses cause more extensive retinal cell death and therefore are likely to be less selective in their effects on retinal activity.²² Our experiments show

From the *Department of Optometry, Queensland Institute of Technology, and the †Department of Physiology and Pharmacology, University of Queensland, Brisbane, Queensland, Australia.

Supported by NH and MRL grant number 880904.

Submitted for publication: January 23, 1987; accepted September 24, 1987.

Reprint requests: C. F. Wildsoet, Department of Optometry, Queensland Institute of Technology, GPO Box 2434, Brisbane, Queensland 4001, Australia.

Table 1. Ocular dimensions of chickens treated on day 1

Ocular parameter	Treatment			
	Distilled water (n = 26)	Kainic acid 2 nmole (n = 7)	Kainic acid 20 nmole (n = 11)	Kainic acid 200 nmole (n = 8)
Ocular refraction (D)	+1.41 ± 0.75	+1.41 ± 0.75	-3.75 ± 11.40	-7.47 ± 9.28
Corneal radius of curvature (mm)	3.80 ± 0.12	3.82 ± 0.15	3.66 ± 0.13‡	4.13 ± 0.33*
Axial length (mm)	11.14 ± 0.40	11.16 ± 0.18	11.77 ± 1.02†	11.85 ± 0.44‡
Equatorial diameter (mm)	14.44 ± 0.40	14.51 ± 0.27	14.65 ± 0.59	15.71 ± 0.72‡
Corneal sag (mm)	1.92 ± 0.17	1.96 ± 0.09	2.22 ± 0.49†	1.47 ± 0.19†
Corneal diameter (mm)	6.55 ± 0.21	6.55 ± 0.17	6.78 ± 0.33*	6.31 ± 0.28‡

Each value represents mean ± SD.

Difference between treatment and control eye significant at 0.5% (‡), 1% (†), 5% (*) level (Wilcoxon matched-pairs signed-ranks test).

that kainic acid causes eye enlargement. The observed patterns of eye enlargement, while exhibiting both dose-dependent and age-dependent variations, share many features with environmentally induced patterns. Our results also provide further evidence that growth of the anterior and posterior segments of the chicken eye are independently regulated.

Materials and Methods

Experimental Animals

Male white Leghorn chickens were used. They were reared in open mesh cages. Ambient lighting was provided by fluorescent lights set to a 12 hr light/dark cycle and heating was provided by an infrared lamp which maintained a cage temperature of 30°C.

Treatment Details

Kainic acid (Sigma, St. Louis, MO) dissolved in distilled water, or distilled water (control treatment), was injected into the vitreal chamber from a temporal site using a SGE microsyringe fitted with a fine glass pipette. Animals were maintained under halothane anaesthesia during this surgery. All injected solutions were adjusted to pHs in the range 7.0 to 7.6 using sodium hydroxide and hydrochloric acid and all injected volumes were 10 µl.

Three different doses of kainic acid were studied, 2 nmole, 20 nmole and 200 nmole. Treatments were randomly allocated so that all animals received both kainic acid and control treatments and approximately equal numbers of right and left eyes received kainic acid in any batch of animals. Two of the three dose levels were used with each batch and duplicate data were obtained for the 20 nmole and 200 nmole dose levels. To minimize experimental bias, animals were identifiable only by numbered leg bands during all data collection. Day-old chickens were injected with 2 nmole, 20 nmole or 200 nmole kainic acid and the two higher doses were also injected into 14-day-

old chickens. Treatment effects were assessed 4 weeks after injection of animals.

Assessment of Treatment Effect

Animals were deeply anaesthetized using halothane, and retinoscopy and photokeratoscopy²⁴ undertaken to obtain refractive error and corneal curvature data respectively. In both cases, the average of measurements made along horizontal and vertical meridians were used in subsequent data analysis. Animals were then perfused with either formalin or glutaraldehyde fixative after receiving an overdose of pentobarbitone. Eyes were then dissected free of muscle and loose connective tissue and reinflated to a pressure determined by prior intraocular pressure assessment in the anaesthetized animal with an applanation tonometer. Axial and equatorial diameters, horizontal corneal diameter and corneal sag were then measured with digital callipers. Corneal sag was measured as the vertical distance between the corneal apex and its limbal margin and was used to estimate anterior chamber depth. Both horizontal and vertical equatorial diameters were recorded and their average used in data analysis.

Data were analyzed using nonparametric statistics; the Wilcoxon matched-pairs signed-ranks test was used to test differences between treatment and control eyes of the same animal and differences between treatments were assessed using the Mann-Whitney U-test.

These experiments followed the ARVO Resolution on the Use of Animals in Research.

Results

Treatment Effects Induced in Day-Old Chickens

There were dose-dependent differences in the effect produced by intravitreal injection of kainic acid in day-old chickens (Table 1, Figs. 1, 2). The anterior

segment shared in the enlargement produced by a 20 nmole dose while the 200 nmole dose produced enlargement of the posterior segment but inhibited anterior segment growth. These contrasting effects of the two doses on the anterior segment were visible in most animals (Fig. 1).

Dimensional changes: There was a trend towards increasing equatorial diameter, corneal diameter and corneal sag for the 2 nmole dose of kainic acid although these effects were not statistically significant. The trend towards enlarged corneas was also evident for the 20 nmole dose of kainic acid. Both corneal diameter and sag were significantly increased and these changes were accompanied by a decrease in corneal radius of curvature which was also statistically significant. Axial length, but not equatorial diameter, was significantly increased. In contrast, the 200 nmole dose had a greater effect on equatorial dimensions than axial dimensions although induced increases in both axial and equatorial dimensions were statistically significant here. The difference between these two doses with respect to induced changes in axial and equatorial dimensions also proved significant (Table 2). The effect of the 200 nmole dose of kainic acid on the anterior segment of the eye contrasted with that seen with the intermediate dose; the corneas were now reduced in both diameter and sag and flatter than control corneas with all differences being statistically significant. These differences between the two doses were also statistically significant (Table 2).

Pattern analysis: The dose-dependent differences in observed growth patterns were further demonstrated when the relative changes in axial and equatorial dimensions were examined (Table 3). The ratios of corneal diameter to corneal sag, corneal sag to axial length, and axial length to equatorial diameter for treatment and control eyes were compared. This analysis shows the reduction in corneal sag produced with the 200 nmole dose to be disproportionate with respect to both changes in corneal diameter and axial length. Equatorial changes also proved to be disproportionately larger than axial changes. The trends for the 20 nmole dose tended to be in the opposite direction although none were statistically significant.

Refractive error findings: The 2 nmole dose of kainic acid did not affect refractive error, and eyes receiving this or control treatment exhibited small hyperopic errors. The 20 nmole and 200 nmole doses both caused increases in scatter of the refractive error distributions compared with control eyes and a shift toward myopia (Fig. 3). Some animals in both treatment groups exhibited very high myopia, but small refractive errors and large hyperopic errors were also recorded.

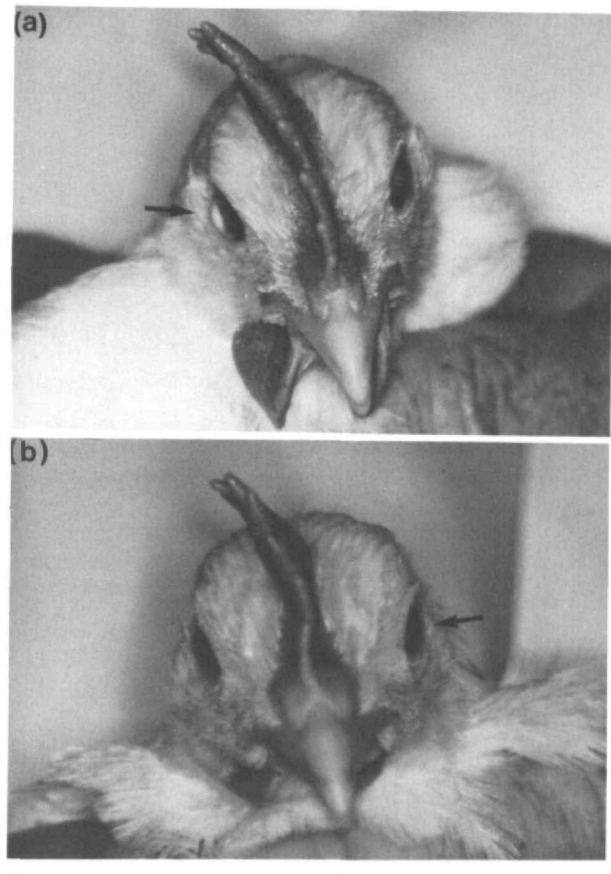


Fig. 1. External appearance of eyes of chickens treated with (a) 20 nmole and (b) 200 nmole kainic acid, injected intravitreally; arrows indicate treated eyes.

Treatment Effect Induced in 14-Day-Old Chickens

In older animals, kainic acid appears to have opposing, dose-dependent effects on the anterior and posterior segments of the eye (Table 4, Fig. 2); enlargement of the posterior segment and retarded development of the anterior segment were observed.

Dimensional changes: The opposing influences on anterior segment development of 20 nmole and 200 nmole doses of kainic acid described above were not seen when treatment was delayed till age 14 days. Instead, corneal sag was reduced in a dose-dependent manner which was statistically significant in both cases and accompanied by corneal flattening which was significant only for the higher dose. Corneal diameters were also smaller in eyes receiving the 200 nmole dose. Axial elongation was produced by both doses and was again greatest for the 20 nmole dose and significant only for this dose. Both doses also produced significant equatorial enlargement, the 200 nmole dose having the greater effect. Changes in equatorial diameter, corneal sag and corneal diameter induced by the 200 nmole dose were significantly

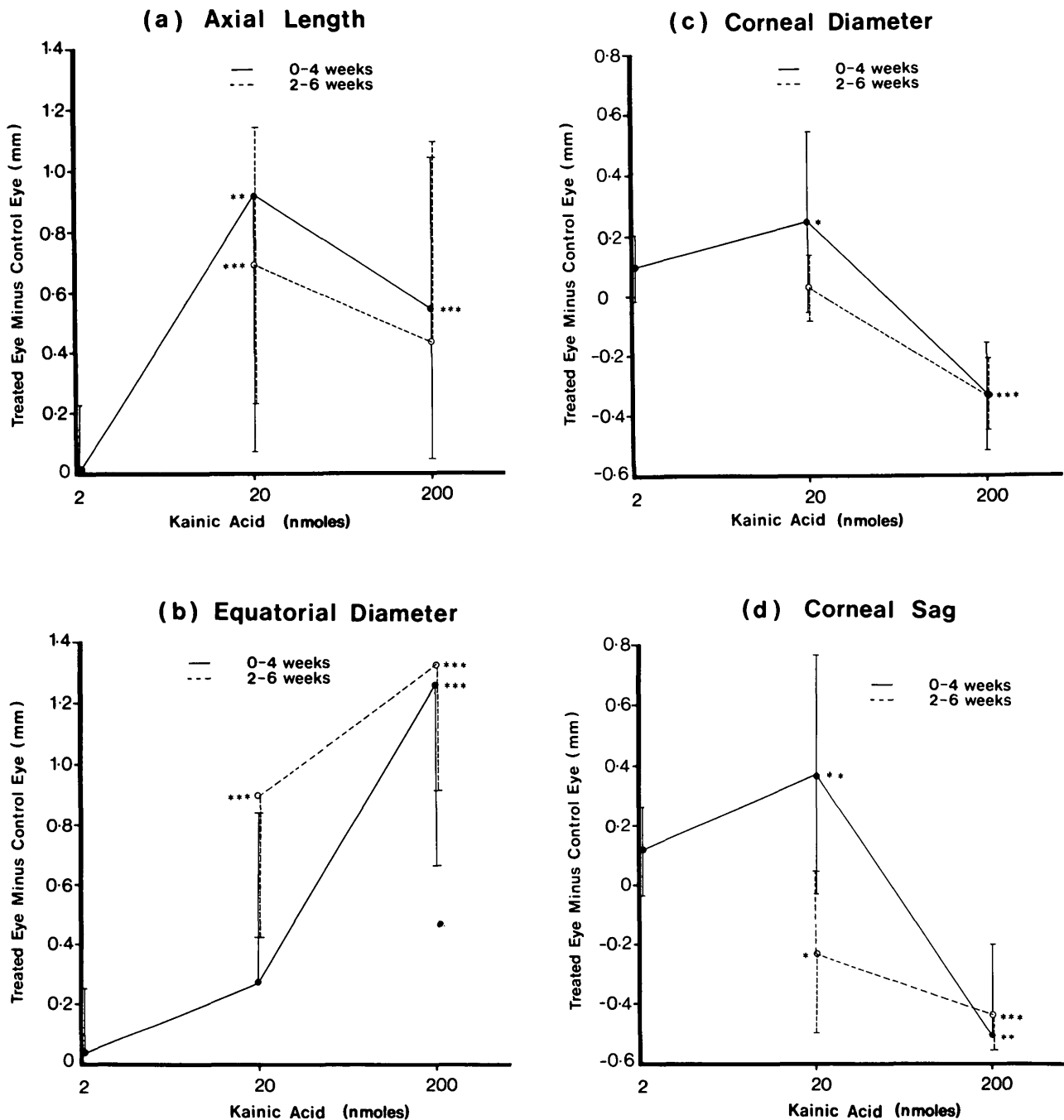


Fig. 2. Mean difference (with SD) in (a) axial length, (b) equatorial diameter, (c) corneal diameter and (d) corneal sag, between treatment and control eyes, measured 4 weeks after intravitreal injection of solutions of kainic acid and distilled water (control) in day-old and 14-day-old chickens, as a function of dose of kainic acid used. Difference significant at 0.5% (***), 1% (**), 5% (*) level (Wilcoxon matched-pairs signed-ranks test).

greater than those induced by the 20 nmole dose (Table 2).

Pattern analysis: The effect of treatment on the overall pattern of development was again examined by comparing ratios for treatment and control eyes of various parameters (Table 5). As seen in the younger animals, the 200 nmole dose of kainic acid produced disproportionate decreases in corneal sag relative to

both corneal diameter and axial length, and equatorial enlargement dominated over axial changes. However in the older animals, the 20 nmole dose also produced a disproportionate decrease in corneal sag relative to both corneal diameter and axial length.

Refractive error findings: The same patterns of refractive error distribution were seen for both doses of kainic acid (Fig. 3) and these patterns were similar to

those seen in younger animals treated with the same doses of kainic acid. There was a shift towards myopia and an increase in spread of the refractive error distributions for kainic acid treated eyes relative to that for control eyes.

Discussion

Chemically Induced Eye Enlargement

Our results demonstrate that ocular growth patterns may be altered through chemical intervention. Apparently the only other report of chemically induced eye enlargement in chickens is that by Groschke²⁵ who observed eye enlargement in chickens fed high amounts of free glycine in their diet. Glycine is a putative retinal neurotransmitter^{26,27} and there is an interesting parallel established by the current observation that an analog of glutamate, another putative retinal neurotransmitter,^{20,27} also caused eye enlargement. Kainic acid-induced enlargement was confined to the vitreal chamber when used in a 200 nmole dose for day-old chickens and in a 200 nmole dose or a 20 nmole dose for older chickens. Corneas were reduced in diameter and also flattened, indicating that corneal growth was inhibited by these treatments. In contrast, the 20 nmole dose of kainic acid given to day-old animals appeared to stimulate corneal growth, with corneas of treated eyes enlarged and slightly steeper; the increase in sag dimensions also contributed substantially to the overall axial changes.

Parallels With Chicken Eye Enlargement Patterns Induced by Environmental Manipulation

The pattern of growth obtained with the 200 nmole dose of kainic acid bears closest resemblance to those described for animals reared in continuous light or in total darkness. In dark rearing experiments, increases in eye weight,¹⁴ axial length^{13,28} and equatorial diameter^{15,28} have been observed and, as in the kainic acid experiments, equatorial changes appear to dominate over axial length changes.^{15,28} Similarly, corneal flat-

Table 2. Significance of differences between treatment-induced changes in ocular dimensions of chickens treated on day 1 and day 14 (in brackets)

Ocular parameter	Compared treatments		
	2, 20 nmole Kainic acid (n = 7, 11)	2, 200 nmole Kainic acid (n = 7, 8)	20, 200 nmole Kainic acid (n = 11, 8 (8, 8))
Corneal radius of curvature	†	*	† (-)
Axial length	*	*	- (-)
Equatorial diameter	—	‡	† (‡)
Corneal sag	—	‡	‡ (*)
Corneal diameter	—	‡	‡ (‡)

Difference between treatment effects are significant at 0.5% (‡), 1% (†) or 5% (*) level (Mann-Whitney U-test).

tening and reduced anterior chamber depth have been reported.^{15,28} These observations may also be interpreted as inhibitory effects on anterior segment development although in these cases, corneal diameters were unaltered. Similar eye enlargement patterns have also been described in animals reared in constant light environments.^{9,11,13,14,28}

The response to the 20 nmole dose of kainic acid used in day-old chickens resembles the described responses to lid suture^{5,16} and the fitting of dome-shaped, full-field translucent occluders^{5,8} in these animals; with all three treatments, corneal enlargement contributes significantly to the overall eye enlargement. Both translucent occluders and lid suture cause overall retinal image degradation^{18,29} and it is most probably for this reason that the induced eye growth patterns for these two treatments are very similar. Both axial length and equatorial diameter are increased by these three treatments but here the changes are more symmetrical and thus do not affect eye shape. As seen in both lid-sutured and occluded chickens, the 20 nmole dose of kainic acid also produced increases in both corneal diameter and anterior chamber depth with day-old chickens.^{5,7,8,28,30}

Table 3. Geometric relationship between ocular dimensions of chickens treated on day 1

Ratios of ocular parameters	Treatment			
	Distilled water (n = 26)	Kainic acid 2 nmole (n = 7)	Kainic acid 20 nmole (n = 11)	Kainic acid 200 nmole (n = 8)
Axial length: equator diameter	0.77 ± 0.02	0.77 ± 0.01	0.80 ± 0.05	0.76 ± 0.03†
Corneal sag: axial length	0.17 ± 0.01	0.18 ± 0.01*	0.22 ± 0.11	0.12 ± 0.02‡
Corneal diameter: corneal sag	3.42 ± 0.24	3.35 ± 0.14	3.17 ± 0.63	4.36 ± 0.60†

Each value represents mean ± SD.

Difference between treatment and control eye significant at 0.5% (‡), 1% (†), 5% (*) level (Wilcoxon matched-pairs signed-ranks test).

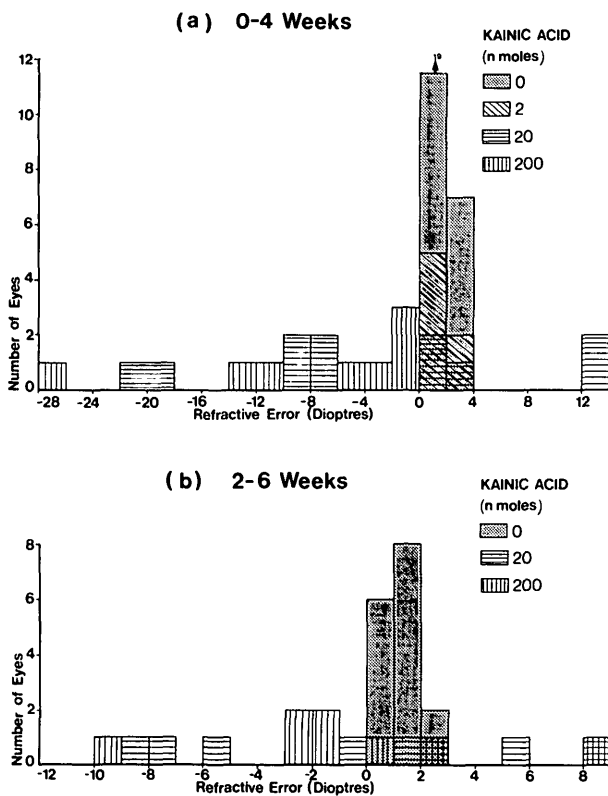


Fig. 3. Refractive error distributions of treatment and control eyes, measured 4 weeks after intravitreal injections of solutions of kainic acid and distilled water (control) in (a) day-old and (b) 14-day-old chickens.

This result favours a vision-dependent mechanism as the basis for corneal enlargement over alternative theories implicating abnormal temperature or anoxic conditions potentially created by lid suture and occlusion.²⁹

There are some discrepancies between corneal curvature data obtained with these lid suture, occlusion and kainic acid treatments. They are of questionable significance, however, as it is likely that the corneas were aspheric and different methods were used to measure corneal curvature in these studies. Corneal

steepening was obtained with the 20 nmole dose of kainic acid used in day-old chickens but corneal flattening has been recorded for lid-sutured animals.^{7,16,30} As Hayes and coworkers⁸ found no significant change in central corneal curvature for full-field occlusion despite an apparent increase in corneal curvature, it appears likely that the corneas were aspheric. Corneal asphericity in lid-sutured eyes could be caused by mechanical interaction between the central corneal zone and closed lids; this interpretation is supported by recent evidence that lid suturing exaggerates the corneal flattening response to dark rearing¹⁷ and the failure of occluders to cause corneal flattening.⁸ It also explains why sag calculations based on the corneal dimensions recorded by Yinon and coworkers¹⁶ in lid-sutured chickens predict generally shallower anterior chambers than observed.

Kainic Acid and Retinal Function

In the current study and those cited, retinal activity has been modified, either indirectly through the use of occluders or directly by chemical means. This suggests that the nature of retinal output, and thus visual experience, is critical to ocular development.

Morgan and coworkers^{22,23,31,32} have extensively studied the neurotoxic effects of kainic acid on chicken retina. In 2-day-old chickens, intravitreal injections of a 6 nmole dose of kainic acid caused the selective elimination of 50% of amacrine cells. Other classes of retinal cells were also affected when higher doses of kainic acid were used; a 20 nmole dose of kainic acid destroyed two-thirds of the bipolar cells and significant loss of horizontal cells was observed with doses of 120 nmole and 200 nmole. Müller cells, photoreceptors and ganglion cells were more resistant to the neurotoxic effects of kainic acid. Structural changes have also been reported in the retina for chickens fitted with full-field occluders⁸ or with sutured lids,¹⁶ and also in the optic tectum receiving input from the deprived eye in lid-sutured chickens.³³

Table 4. Ocular dimensions of chickens treated on day 14

Ocular parameter	Treatment		
	Distilled water (n = 16)	20 nmole Kainic acid (n = 8)	200 nmole Kainic acid (n = 8)
Ocular refraction (D)	+1.16 ± 0.69	-0.64 ± 6.34	-0.64 ± 5.02
Corneal radius of curvature (mm)	4.14 ± 0.12	4.47 ± 0.24	4.43 ± 0.11‡
Axial length (mm)	12.20 ± 0.35	13.06 ± 0.57‡	12.45 ± 0.80
Equatorial diameter (mm)	15.74 ± 0.52	16.89 ± 0.64‡	16.82 ± 0.66‡
Corneal sag (mm)	2.10 ± 0.12	1.91 ± 0.25*	1.61 ± 0.18‡
Corneal diameter (mm)	7.34 ± 0.23	7.46 ± 0.24	6.92 ± 0.28‡

Each value represents mean ± SD.

Difference between treatment and control eyes significant at 0.5% (‡), 1% (†), 5% (*) level (Wilcoxon matched-pairs signed-ranks test).

Morgan's group has also shown that a 100 nmole dose of kainic acid in 4- to 6-week-old chickens irreversibly abolishes retinal driven off-responses; on-responses remain in a simpler form.²³ The equivalent dose for day-old chickens, when allowance is made for age-related differences in vitreal volume, is approximately 20 nmole, which is the dose used to obtain growth patterns similar to those observed in lid-sutured and occluded chickens. Is it possible that lid suturing and full-field occlusion, through stimulus modification, similarly modify retinal activity? The same dose used in older animals inhibited anterior segment growth. Does this mean that the sensitive period for anterior segment enlargement is limited to 2 weeks? Wallman and coworkers³⁴ and Noller³⁵ have observed reduced sensitivity in older animals to the effects of occlusion. However, Wallman and coworkers found that anterior segment changes develop only late in the course of events for chickens restricted to frontal vision, although they also indicate that anterior segment enlargement occurs much earlier in chickens totally deprived of form vision. Results obtained by Yinon and coworkers¹⁶ suggest a sensitive period much longer than 2 weeks; they observed anterior segment enlargement in animals where lid suturing was delayed till 4 weeks of age.

The 200 nmole dose of kainic acid used would be expected to alter retinal activity more radically on the basis of histological evidence.²² It also had a much more dramatic effect on retinal ophthalmoscopic appearance than the lower dose (personal observation). Electrophysiological recordings may well reveal further similarities between changes induced by this dose of kainic acid and by continuous light or continuous dark rearing conditions, all of which appear to induce similar eye enlargement. Intuitively it seems that both dark rearing and the 200 nmole dose of kainic acid would produce similar dampening of retinal electrical activity; in dark rearing the stimulus for activity has been withdrawn, whereas kainic acid depresses the retinal response to stimulation. However, histological studies have not provided evidence of a link between these treatments. Chicken retinas are unaffected by continuous dark rearing treatment.²⁸ Retinal lesions are also only inconsistently described for chickens reared under continuous light^{10,14} although retinal degeneration has been reported for rats reared under similar conditions.³⁶

Mechanisms For Eye Enlargement

Is eye enlargement due to enhanced growth? We now have evidence that both lid suture and kainic acid-induced changes are mediated by local ocular mechanisms and retinal, vitreal and whole eye tissue

Table 5. Geometric relationship between ocular dimensions of chickens treated on day 14

Ratio of ocular parameters	Treatment		
	Distilled water	Kainic acid 20 nmole	Kainic acid 200 nmole
Axial length: equatorial diameter	0.78 ± 0.01	0.77 ± 0.01	0.74 ± 0.02‡
Corneal sag: axial length	0.17 ± 0.01	0.15 ± 0.02†	0.13 ± 0.01‡
Corneal diameter: corneal sag	3.50 ± 0.17	3.95 ± 0.48†	4.32 ± 0.37‡

Each value represents mean ± SD.

Difference between treatment and control eyes significant at 0.5% (‡), 1% (†), 5% (*) level (Wilcoxon matched-pairs signed-ranks test).

extracts have demonstrable growth modulatory activity.³⁷⁻⁴² The retina alone contains a diverse range of peptides^{43,44} of which three are known to influence growth of other tissues.⁴⁵⁻⁴⁸ These peptides may subserve a vision-dependent system of regional control of posterior chamber growth, and their regional variations in distribution⁴⁹⁻⁵⁶ could underlie the differential growth rates indicated by the asymmetric nature of some enlargement patterns described.^{8,18,19,28}

Our results support the hypothesis that growth of the anterior and posterior segments of the eye may be independently regulated. We have shown that enhanced or inhibited anterior segment growth may occur with enhanced posterior segment growth. Anterior segment growth may also be subject to retinal influence but a second regulatory mechanism is required to explain those cases involving opposing effects on anterior and posterior eye segments. It is possible that corneal nerves subserve both sensory and trophic functions. Alternatively the ciliary nerve may be involved. Wallman and coworkers showed that ciliary nerve sectioning reduced the myopic response induced when occluders were fitted to allow only frontal vision.⁵⁷ This result may reflect the removal of a tonic influence of the ciliary muscle on corneal curvature⁵⁸ as the surgery caused corneal flattening. However, an alternative explanation could be based on the premise that the ciliary nerve exercises a trophic influence over the anterior eye segment.

Eye Enlargement and Refractive Errors

Normal development involves both an age-dependent narrowing of the refractive error distribution and a shift of the median position towards emmetropia.⁵⁹ This suggests that there is coordinated development of all refractive components. Both kainic acid and techniques used to manipulate visual experience disrupt this emmetropization process.

Myopia is the most common refractive error seen with eye enlargement,^{5,8,16} however myopia cannot

be considered synonymous with eye enlargement. While it predominates when lid suture or full-field occlusion techniques are used with chickens, both hyperopia^{15,17} and myopia^{13,60} have been reported with eye enlargement in both dark and light reared chickens and in our chickens with kainic acid. The variability in the refractive outcome is not surprising as the refractive state represents the balance positions in a multidimensional system where induced changes can work in opposition. For example, myopia may be due to an increase in the separation of the cornea from the retina, but may also arise when the vitreal chamber is expanded by a shift of the lens toward the cornea. The steepening of any of the optical surfaces will also cause a myopic shift.

In our experiments, the higher dose of kainic acid produced consistent corneal flattening which tends to offset the myopic shift associated with the expansion of the vitreal chamber of the same eyes. In contrast, the corneal steepening observed in some eyes receiving the 20 nmole dose will cause a myopic shift which will be opposed by the effects of increased corneal-lens separation where this is not accompanied by an equal or greater increase in axial length.

In summary, our data provide further evidence that normal ocular development and emmetropization in chickens is dependent on "normal" retinal activity which is synonymous with normal visual experience and normal retinal function. Kainic acid modifies retinal function and causes eye enlargement, the exact nature of which is both dose-dependent and age-dependent. In light of the demonstrated ability of the anterior and posterior segments to undergo differential growth, due consideration must be given in future models of ocular growth and emmetropization to the possibility that growth of anterior and posterior segments are independently regulated.

Key words: kainic acid, eye enlargement, eye development, myopia, chicken myopia

Acknowledgment

The critical advice of Dr. B. Brown during the preparation of this manuscript was greatly appreciated.

References

1. Young FA: The development and control of myopia in human and subhuman primates. *Contacto* 9:16, 1975.
2. Young FA: The effect of restricted visual space on the primate eye. *Am J Ophthalmol* 52:799, 1961.
3. Wiesel TN and Raviola E: Myopia and eye enlargement after neonatal lid fusion. *Nature* 266:66, 1977.
4. Sherman SM, Norton TT, and Casagrande VA: Myopia in the lid-sutured tree shrew (*Tupaia glis*). *Brain Res* 124:154, 1977.
5. Wallman J, Turkel J, and Trachtman J: Extreme myopia produced by modest change in early visual experience. *Science* 201:1249, 1978.
6. Goss DA and Cox VD: Trends in the change of clinical refractive error in myopes. *J Am Optom Assoc* 56:608, 1985.
7. Yinon U, Rose L, Shapiro A, Goldschmidt MM, and Steinschneider TY: Refractive changes in the chicken eye following lid fusion. In *Developmental Neurobiology of Vision*, Freeman RD, editor. New York, Plenum Press, 1979, pp. 411-418.
8. Hayes BP, Fitzke FW, Hodos W, and Holden AL: A morphological analysis of experimental myopia in young chickens. *Invest Ophthalmol Vis Sci* 27:981, 1986.
9. Jensen LS and Matson WE: Enlargement of avian eye by subjecting chicks to continuous incandescent illumination. *Science* 125:741, 1957.
10. Lauber JK, Shutze JV, and McGinnis J: Effects of exposure to continuous light on the eye of the growing chicks. *Proc Soc Exp Biol Med* 106:871, 1961.
11. Smith ME, Becker B, and Podos SM: Light-induced angle-closure glaucoma in the domestic fowl. *Invest Ophthalmol* 8:213, 1969.
12. Chiu PSL, Lauber JK, and Kinnear A: Dimensional and physiological lesions in the chick eye as influenced by the light environment. *Proc Soc Exp Biol Med* 148:1223, 1975.
13. Shiraki K, Sotani T, Oishi T, and Okuzawa T: Effects of continuous light and continuous dark on the eyes of chicks. *Folia Ophthalmol Jpn* 32:1157, 1981.
14. Oishi T and Murakami N: Effects of duration and intensity of illumination on several parameters of the chick eye. *Comp Biochem Physiol* 81A:319, 1985.
15. Gottlieb MD, Wentzek L, and Wallman J: Differential visual restrictions cause different eye growth abnormalities. *ARVO Abstracts. Invest Ophthalmol Vis Sci* 26(Suppl):331, 1985.
16. Yinon U, Koslowe KC, Lobel D, Landshman N, and Barishak YR: Lid suture myopia in developing chicks: Optical and structural considerations. *Curr Eye Res* 2:877, 1982/1983.
17. Yinon U and Koslowe KC: Hypermetropia in dark reared chicks and the effect of lid suture. *Vision Res* 26:999, 1986.
18. Hodos W and Kuenzel WJ: Retinal-image degradation produces ocular enlargement in chicks. *Invest Ophthalmol Vis Sci* 25:652, 1984.
19. Gottlieb MD, Rajaram V, Wentzek L, and Wallman J: Local visual restrictions produce local regions of myopia. *ARVO Abstracts. Invest Ophthalmol Vis Sci* 27(Suppl):202, 1986.
20. Morgan IG: Organization of amacrine cell types which use different transmitters in chicken retina. *Prog Brain Res* 58:191, 1983.
21. Morgan IG and Dvorak DR: A physiologically active kainic acid-preferring receptor in chicken retina. *Neurosci Lett* 44:299, 1984.
22. Ingham CA and Morgan IG: Dose-dependent effects of intravitreal kainic acid on specific cell types in chicken retina. *Neuroscience* 9:165, 1983.
23. Dvorak DR and Morgan IG: Intravitreal kainic acid permanently eliminates off-pathways from chick retina. *Neurosci Lett* 36:249, 1983.
24. Sivak JG: A simple photokeratoscope. *Am J Optom Physiol Opt* 54:241, 1977.
25. Groschke AC, Anderson JO, and Briggs GM: Peculiar enlargement of eyeballs in chicks caused by feeding a high level of glycine. *Proc Soc Exp Biol Med* 69:491, 1948.
26. Watt CB, Li H-B, and Lam D M-K: The presence of three neuroactive peptides in putative glycinergic amacrine cells of an avian retina. *Brain Res* 348:187, 1985.
27. Ehinger B: Neurotransmitter systems in the retina. *Retina* 2:305, 1982.
28. Osol G, Schwartz B, and Foss DC: The effects of photoperiod

- and lid suture on eye growth in chickens. *Invest Ophthalmol Vis Sci* 27:255, 1986.
29. Yinon U: Myopia induction in animals following alteration of the visual input during development: A review. *Curr Eye Res* 3:677, 1984.
 30. Yinon U, Rose L, and Shapiro A: Myopia in the eye of developing chicks following monocular and binocular lid closure. *Vision Res* 20:137, 1980.
 31. Ehrlich D and Morgan IG: Kainic acid destroys displaced amacrine cells in post-hatch chicken retina. *Neurosci Lett* 17:43, 1980.
 32. Morgan IG and Ingham CA: Kainic acid affects both plexiform layers of chicken retina. *Neurosci Lett* 21:275, 1981.
 33. Ali SF, Hong J-S, and Bondy SC: Response of neuropeptides and neurotransmitter binding sites in the retina and brain of the developing chick to reduced visual input. *International Journal of Developmental Neuroscience* 1:99, 1983.
 34. Wallman J and Adams JI: Developmental aspects of experimental myopia in chicks: Susceptibility, recovery and relation to emmetropization. *Vision Res* 27:1139, 1987.
 35. Noller N: Eye enlargement of the chick following visual deprivation. Master's Thesis, University of Melbourne, 1984.
 36. Noell WK, Walker VS, Kang BS, and Berman S: Retinal damage by light in rats. *Invest Ophthalmol* 5:450, 1966.
 37. Luty GA, Mello RJ, Chandler C, Fait C, Bennett A, and Patz A: Regulation of cell growth by vitreous humour. *J Cell Sci* 76:53, 1985.
 38. Courty J, Loret C, Moener M, Lagente O, Mascarelli F, Arruti C, Barritault D, and Courtois Y: Recent progress in eye-derived growth factor EDGF, purification and mechanism of action. *Eur J Cell Biol* 36(Suppl 8):9, 1985.
 39. Barritault D, Arruti C, and Courtois Y: Is there a ubiquitous growth factor in the eye? Proliferation induced in different cell types by eye-derived growth factors. *Differentiation* 18:29, 1981.
 40. Barritault D, Plouet J, Courty J, and Courtois Y: Purification, characterization, and biological properties of the eye-derived growth factor from retina: Analogies with brain-derived growth factor. *J Neurosci Res* 8:477, 1982.
 41. Wiedeman P, Ryan SJ, Novak P, and Sorgente N: Vitreous proliferation of fibroblasts and retinal pigment epithelial cells. *Exp Eye Res* 41:619, 1985.
 42. Courty J, Chevallier B, Moenner M, Loret C, Lagente O, Bohlen P, Courtois Y, and Barritault D: Evidence for FGF-like growth factor in adult bovine retina: Analogies with EDGF 1. *Biochem Biophys Res Comm* 136:102, 1986.
 43. Stell W, Marshak D, Yamada T, Brecha N, and Karten H: Peptides are in the eye of the beholder. *Trends Neurosci* 3:292, 1980.
 44. Tervo T, Tervo K, and Eranko L: Ocular neuropeptides. *Med Biol* 60:53, 1982.
 45. Hohmann EL, Elde RP, Rysavy JA, Einzig S, and Gerhard RL: Innervation of periosteum and bone by sympathetic vasoactive intestinal peptide-containing nerve fibres. *Science* 232:868, 1986.
 46. Nilsson J, von Euler AM, and Dalsgaard C-J: Stimulation of connective tissue cell growth by substance P and substance K. *Nature* 315:61, 1985.
 47. Nakai K and Kasamatsu T: Accelerated regeneration of central catecholamine fibres in cat occipital cortex: Effects of substance P. *Brain Res* 323:374, 1984.
 48. Sakellaris N, Mangoura D, and Vernadakis A: Effects of opiates on the growth of neuron-enriched cultures from chick embryonic brain. *Int J Neurosci* 4:293, 1986.
 49. Brecha N, Karten HJ, and Laverack C: Enkephalin-containing amacrine cells in the avian retina: Immunohistochemical localization. *Proc Natl Acad Sci USA* 76:3010, 1979.
 50. Brecha N, Karten HJ, and Schenker C: Neurotensin-like and somatostatin-like immunoreactivity within amacrine cells of the retina. *Neuroscience* 6:1329, 1981.
 51. Karten HJ and Brecha N: Localisation of substance P immunoreactivity in amacrine cells of the retina. *Nature* 283:87, 1980.
 52. Ishimoto I, Shiosaka S, Shimizu Y, Kuwayama Y, Fukuda M, Inagaki S, Takagi H, Sakanaka M, Takatsuki K, Senba E, and Tohyama M: Two types of substance P-containing cells and their uneven distribution in the chicken retina: An immunohistochemical analysis with flat-mounts. *Brain Res* 240:171, 1982.
 53. Ishimoto I, Shiosaka S, Shimizu Y, Kuwayama Y, Fukuda M, Inagaki S, Takagi H, Sakanaka M, Sasaoka A, Senba E, Sakiyama T, and Tohyama M: Leu-enkephalin-like immunoreactivity in the chicken retina with a special reference to its fine structures. *Invest Ophthalmol Vis Sci* 24:879, 1983.
 54. Ishimoto I, Millar T, Chubb IW, and Morgan IG: Somatostatin-immunoreactive amacrine cells of chicken retina: Retinal mosaic, ultrastructural features, and light-driven variations in peptide metabolism. *Neuroscience* 17:1217, 1986.
 55. Katayama-Kumoi Y, Kiyama H, Emson PC, Kimmel JR, and Tohyama M: Coexistence of pancreatic polypeptide and substance P in the chicken retina. *Brain Res* 361:25, 1985.
 56. Katayama Y, Kiyama H, Arai Y, and Tohyama M: Immunoreactive avian pancreatic polypeptide in the chicken retina: Overall distribution. *Brain Res* 310:164, 1984.
 57. Wallman J, Rosenthal D, Adams JI, Trachtman JN, and Romagnano L: Role of accommodation and developmental aspects of experimental myopia in chicks. *Doc Ophthalmol Proc Ser* 28:197, 1981.
 58. Troilo D and Wallman J: Changes in corneal curvature during accommodation in chicks. *Vision Res* 27:241, 1987.
 59. Wallman J, Adams JI, and Trachtman JW: The eyes of young chickens grow towards emmetropia. *Invest Ophthalmol Vis Sci* 20:557, 1981.
 60. Lauber JK, Boyd JE, and Boyd TAS: Intraocular pressure and aqueous outflow facility in light-induced avian buphthalmos. *Exp Eye Res* 9:181, 1970.