



Foster, A. P., Millar, M., Daniel, R., Tilling, O., & Whyte, I. (2015).
Drenching gun injuries in cattle. *Veterinary Record*, 177(13), 345-346. DOI:
10.1136/vr.h5220

Peer reviewed version

License (if available):
Unspecified

Link to published version (if available):
[10.1136/vr.h5220](https://doi.org/10.1136/vr.h5220)

[Link to publication record in Explore Bristol Research](#)
PDF-document

This is the author accepted manuscript (AAM). The final published version (version of record) is available online via BMJ at <http://veterinaryrecord.bmj.com/content/177/13/345.3> . Please refer to any applicable terms of use of the publisher.

University of Bristol - Explore Bristol Research

General rights

This document is made available in accordance with publisher policies. Please cite only the published version using the reference above. Full terms of use are available:
<http://www.bristol.ac.uk/pure/about/ebr-terms.html>

Drenching gun injuries in cattle

Dear Editor,

Drenching gun injuries are well recognised in sheep and have been clearly shown to pose a threat to the health and welfare of sheep in the UK (Harwood and Hepple 2011). In cattle liver fluke infection is associated with the widespread use of anthelmintic products to reduce the impact of infestation on production, particularly in dairy cattle (Howell and others 2015). We wish to report on three cases of dosing gun injury, with fatal outcome, for three dairy farms where cattle were treated for liver fluke.



Figure 1 Farm 1 New gun (top) - longer barrel with more acute angle

On the first farm, three cows in a 130 cow dairy herd had died in a week, with the first two to die showing reduced milk yield and some coughing. One of these was examined at the knacker's yard and had a large amount of blood in its "stomach". Coughed up blood had been noted on the bedding. The whole herd had been drenched three weeks before signs were observed after fluke were found in cull cows at the abattoir. The last cow to die was submitted for postmortem examination to the University of Bristol Farm Animal Pathology Service (FAPS); she had shown no premonitory signs and collapsed at milking, and died soon after. There were large amounts of clotted blood in the pharyngeal region extending down the neck between the trachea and

oesophagus, and within the rumen. There was extensive, foul smelling fibrin and pus associated with irregular swelling in the right pharyngeal region, obliterating the entrance to the larynx and surrounding the right carotid. These findings were consistent with severe right sided pharyngitis caused by a drenching gun injury with death likely a consequence of asphyxiation and blood loss due to arterial damage caused by the infection. It seemed likely the other two cow deaths had been due to the same cause. The farmer had purchased a new gun prior to drenching the cows; the gun was longer and had a more acute bend, with the damage a consequence of the gun being used by someone who was used to using the shorter gun (See figure).

On the second farm, a group of six dairy cows were dried off and dosed by an experienced stockman with an albendazole-based oral drench. The drenching gun had been purchased two weeks prior to its use. Several hours later one of the cows developed acute severe signs of upper respiratory tract disease and died the same day. Postmortem examination revealed the presence of firm white material in the submucosal tissues of the right side of the pharynx extending to the larynx. Death was assumed to have been the consequence of asphyxia due to the administration of the drench material.

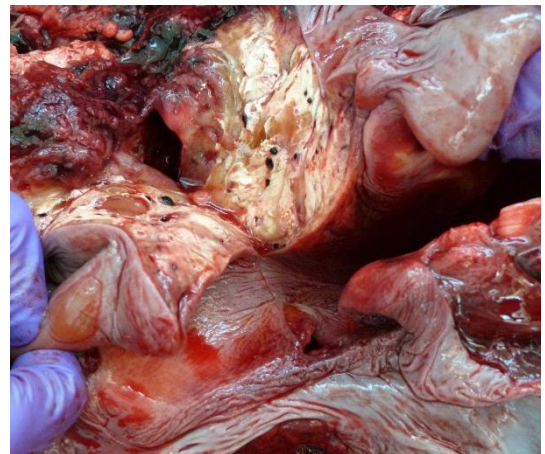


Figure 2 Farm 2: Expansion of soft tissues in larynx due to drench material (white)

On the third farm, a heifer was presented for postmortem examination to APHA Carmarthen. It was the only heifer affected in a group of 57, in a 285 cow dairy herd. The only clinical sign the farmer had observed was a green discharge from the nose. The group had been wormed regularly. There was a penetrating injury in the oropharynx which had caused an abscess track containing inspissated foul-smelling pus. This was on the right side of the oropharynx above the larynx extending towards the base of the mandible.

The abscess was surrounded by extensive fibrous tissue and some tracks from the main abscess cavity. There was extensive abscessation of the anterior and middle lung lobes. The findings were consistent with a traumatic lesion to the oropharynx which had caused chronic abscessation, fibrosis and probably a purulent pneumonia as a sequel. This would account for the animal being a poor doer for many months. The likely cause of the traumatic lesion was a drenching gun injury possibly due to a sharp nozzle.

These cases highlight the potential risk of injury to some cattle when drenched (with any oral product) and the importance of careful attention to manufacturer instructions when using new equipment, even when used by experienced stock people. Checking and maintenance of drenching equipment is also important. Similar considerations may apply when using instruments to administer boluses to cattle.

Aiden P. Foster & Michael Millar, Farm Animal Pathology Service, School of Veterinary Sciences, University of Bristol, Langford House, North Somerset, BS40 5DU, UK.

Roger Daniel, APHA Carmarthen, Job's Well Road, Johnstown, Carmarthen, Carmarthenshire, SA31 3EZ, Wales.

Oliver Tilling, Shepton Veterinary Group Ltd, Allyn Saxon Drive, Shepton Mallet, BA4 5QH, UK.

Iain Whyte, Westfield Veterinary Centre, The Old Engine Shed, Westfield Road, Wells, Somerset BA5 2HS.

HARWOOD, D. & HEPPLER, S. (2011) Drenching / bolus gun injuries in sheep. *Veterinary Record* 168: 308-309.

HOWELL, A., BAYLIS, M., SMITH, R., PINCHBECK, G. & WILLIAMS, D. (2015) Epidemiology and impact of *Fasciola hepatica* exposure in high-yielding dairy herds. *Preventive Veterinary Medicine* 121, 41-48.