

**Over diagnosis and rising rates of Obstetric Anal Sphincter Injuries (OASIS) –****time for reappraisal****Short Title**

Over diagnosis of OASIS

**Authors:**

Dimos Sioutis

Clinical Fellow in Obstetrics and Gynaecology

Croydon University Hospital, Croydon, UK

Ranee Thakar MD, FRCOG

Consultant Obstetrician and Urogynaecologist

Croydon University Hospital, Croydon

Abdul H. Sultan MD, FRCOG

Consultant Obstetrician and Urogynaecologist

Croydon University Hospital

Corresponding Author:

Abdul H. Sultan

Consultant Obstetrician and Urogynaecologist

Croydon University Hospital

530 London Road

Croydon, Surrey

CR7 7YE

United Kingdom.

Tel: # 44 208 401 3161

This article has been accepted for publication and undergone full peer review but has not been through the copyediting, typesetting, pagination and proofreading process, which may lead to differences between this version and the Version of Record. Please cite this article as doi: 10.1002/uog.17306

Fax: # 44 203 1378698

Email: abdulsultan@nhs.net

**Keywords:** third degree tears, OASIS, endoanal ultrasound, anal sphincter

## **Abstract**

**Objectives:** To identify the accuracy of clinically diagnosed OASIS using 3D endoanal ultrasound and compare symptoms and anal manometry measurements between those whose anal sphincters were adequately repaired to those who had persistent anal sphincter defects.

**Methods:** The endoanal scan images of women who sustained OASIS and attended the perineal clinic over a 10 year period (2003 – 2013) were re-analysed from data entered prospectively of women with clinically diagnosed and repaired OASIS. The St Mark's Incontinence Score (SMIS) as well as anal manometry measurements were included in the analysis.

**Results:** The images of 908 women were re-analysed. We found that there was no evidence of OASIS (Group A) = 64 (7%); external anal sphincter (EAS) scar alone (Group B) = 520 (57.3%); anal sphincter defect (Group C) = 324 (35.7%). Of the 324 women with a defect, 112 had an EAS defect and 90 had an internal anal sphincter (IAS) defect and 122 had a combined IAS + EAS defect. The SMIS was significantly higher in women with a defect ( $p= 0.018$ ) but there was no significant difference in scores between women with an intact sphincter and women with a scar. Compared to the intact group, both the maximum resting (median and range [55 (29-86) vs 43.5 (8-106) mmHg;  $p<0.001$ ] and maximum squeeze pressures [103 (44-185) vs 73.5, (23-

180);  $p < 0.001$ ] were significantly lower in women with a defect but less so with a scar. The anal length was significantly shorter in woman with a defect [25 (10-40) vs 20 (10-40) mm].

Conclusions: Seven percent of women who had a clinical diagnosis of OASIS were wrongly diagnosed as they only had a second degree tear. We believe that this rate may differ from other units but training methods and competency assessment tools for the diagnosis and repair of OASIS need urgent reappraisal. The role of anal ultrasound in the immediate post-partum period needs further evaluation as it will be dependent on the expertise of the staff available to accurately interpret the images.

## Introduction

Obstetric anal sphincter injuries (OASIS) can have a devastating effect on a woman's mental, physical and social wellbeing<sup>1,2</sup> and the management of subsequent pregnancies is influenced by this diagnosis<sup>2-4</sup>. It is therefore imperative that an accurate diagnosis of OASIS is made<sup>5</sup>. EAUS is a validated technique<sup>6</sup> and is considered to be the gold standard in the diagnosis of anal sphincter defects<sup>7</sup>. In 1993, the first prospective study using anal endosonography and anorectal physiology tests 7 weeks before and after childbirth revealed that up to one third of women sustained OASIS that was not clinically diagnosed at the time of delivery. As this was only apparent on ultrasound that was performed 7 weeks after delivery, it was believed to be "occult"<sup>8</sup>. Andrews et al (2006) conducted another prospective study in which women having their first vaginal delivery had their perineum re-examined by an experienced research fellow and also had endoanal ultrasound performed immediately after delivery and repeated 7 weeks postpartum. This study concluded that most, if not all sphincter defects that have previously been designated as "occult" OASIS were in fact injuries that should have been recognisable at delivery. No *de novo* defects were identified by ultrasound at seven weeks postpartum<sup>9</sup>.

It has previously been shown that knowledge of perineal and anal sphincter anatomy amongst doctors and midwives is suboptimal<sup>10</sup>. Furthermore, in a national systematic review, considerable variations in classification and management of OASIS were identified<sup>11</sup>. A prospective audit of the effect of dedicated workshops on the diagnosis and management of OASIS has revealed a significant improvement. However, the rising rates of OASIS<sup>12,13</sup> has raised concern as it has been suggested that OASIS should be considered a performance indicator of obstetric practice<sup>14</sup>.

Although many attribute this increase to improved diagnosis and classification, Schizas et al have reported that doctors were over diagnosing OASIS by 20%<sup>15</sup>.

Our aim was firstly, to identify the accuracy of clinically diagnosed OASIS using 3D endoanal ultrasound. Secondly, we aimed to compare symptoms and anal manometry between those whose anal sphincters were adequately repaired to those who had persistent anal sphincter defects.

## Methods

Over a 10 year period (2003 – 2013) data was entered prospectively of women with clinically diagnosed and repaired OASIS. These women attended the perineal clinic as part of a routine 3-month postpartum follow-up, or during the third trimester of a subsequent pregnancy. The Croydon University Hospital perineal clinic is an one-stop consultant led clinic where women who are pregnant or up to 16 weeks post partum with any pelvic floor or perineal disorder are seen. For the purposes of this study only women who sustained OASIS (3rd and 4th degree tears) were included. Third degree perineal tears are sub-classified, depending on the depth of the injury into: 3a involving <50% of the external anal sphincter (EAS) thickness, 3b involving >50% of the EAS thickness, and 3c involving the internal anal sphincter<sup>16-18</sup>. Fourth degree tears are third degree tears plus involvement of the anorectal mucosa. The validated St Mark's bowel symptom score which includes symptoms of anal incontinence, faecal urgency and impact on quality of life was completed for each woman<sup>19-20</sup>. The St. Mark's Score, ranges from 0 (no anal continence or urgency) to 24 (severe anal incontinence). It also includes a question on the impact of the bowel symptoms on quality of life. Anal manometry was performed using the validated Stryker-295 modified intra-

compartmental monitor with an air-filled catheter balloon<sup>8</sup>. The anal length, maximum resting and maximum squeeze pressures were measured. Three dimensional endoanal ultrasound (B-K Medical, Denmark, 2050 rotating endoprobe) was performed to image the anal sphincter. All the acquired datasets were stored for subsequent evaluation. In order to avoid over diagnosis of sphincter defects, it has been our practice following the original prospective study that only gaps in the anal sphincter that were > one hour (>30 degrees) were classified as defects<sup>4</sup>. If there were no gaps or if the gap was < one hour, it was classified as ‘no defect’ as it was uncertain whether this was a scar at the site of repair or whether it was a genuine defect.

In 2013, all scan datasets for the previous 10 year period that were classified as no defect were reviewed and reported independently by an endoanal scan expert (AS) who was blinded to the symptoms and manometry results. Those images that had no sonographic evidence of any injury to the anal sphincter were re-classified as intact (Group A). Images with a gap of < one hour in the EAS were classified as a scar (Group B) and those with a gap > one hour were labelled as a defect (Group C) as shown in Figure 1. Internal (IAS) and external (EAS) sphincter defects were reported separately. We then compared the St Mark’s score and anal manometry in the three subgroups. The Mann-Whitney U test was used in order to compare the anal manometry findings and the St. Mark’s score between women from groups A and B and between women from groups A and C. The same test was also used to analyse the differences in manometry findings between women who had an EAS defect and those with an IAS defect. Statistical analysis was performed using the SPSS for Windows (Version 17.0; SPSS Inc.; Chicago, IL, USA) and the significance level was set to < 0.05.

An Ethics approval waiver was obtained by the Research and Development Committee.

## Results

Data was available for 908 women who attended follow-up at the perineal clinic. The mean age was 30 years (range 16-45). Seventy four percent (n= 674) were primiparous and 64% (n= 580) had a normal vaginal delivery. Thirty four percent (n=314) had an instrumental delivery (vacuum extraction = 14%; forceps delivery = 20%).

The group distribution based on the EAUS re-analysis is as follows: of the 908 women we found that there was no evidence of OASIS (Group A) = 64 (7%); EAS scar alone (Group B) = 520 (57.3%); anal sphincter defect (Group C) = 324 (35.7%). Of the 324 women with a defect, 112 had an EAS defect and 90 had an IAS defect and 122 had a combined IAS + EAS defect (Table 2).

We found that 7% of women with clinically reported OASIS were in fact 2nd degree tears that were wrongly diagnosed as 3rd degree tears, as there was no evidence of anal sphincter disruption or repair on the EAUS images.

The St. Mark's incontinence score was recorded in 806 patients (89% of the study group). As shown in Figure 2, the score is significantly higher in women with a defect compared to women with no evidence of OASIS, (p= 0.018). However, there was no significant difference in scores between women with an intact sphincter and women with a scar.

Anal manometry measurements were compared in the three groups and are shown in Table 1. Compared to women who had an intact anal sphincter, the anal length was significantly shorter in woman who had an anal sphincter defect. Compared to the intact

group, both the maximum resting and maximum squeeze pressures were significantly lower in women with a defect but less so with a scar.

A comparison in manometry measurements between women with IAS defect (n=90) and women with EAS defect (n=112) (group 1 vs group 2) is shown in Table 2 .

There was no significant difference in anal manometry measurements between women with an IAS defect and those with an EAS defect although there was a trend towards a lower resting pressure in women with an IAS defects. Compared to women who had an IAS defect, those who had a combined IAS & EAS defect had a significantly lower maximum resting and lower maximum squeeze pressures. Compared to women who had an EAS defect, those who had a combined IAS & EAS defect had a significantly shorter anal length, lower maximum resting and lower maximum squeeze pressures.

## Discussion

Using anal endosonography, we found that 7% of women in our unit were wrongly diagnosed as having sustained OASIS when in reality they sustained second degree tears. The endosonographic interpretation of EAS and IAS anatomy and defects have been validated histologically<sup>6,21,22</sup>. Sultan et al first demonstrated that one third of OASIS seen on ultrasound were not identified clinically. At that time they assumed that these injuries were not clinically visible and therefore called it ‘occult’ OASIS<sup>8</sup>. However, a study 15 years later demonstrated that virtually all presumed ‘occult’ EAS injuries could be detected clinically if the accoucher was appropriately trained<sup>9</sup>. Another study showed that perineal re-examination doubled the OASIS rate<sup>23</sup>. Increased



awareness and implementation of training programs resulted in a rise in the OASIS rate. In England, the OASIS rate in primiparae has risen 3 fold from 1.8 to 5.9% over a 10 year period<sup>13</sup>. It is possible that anxiety and fear of missing OASIS amongst doctors may have resulted in over diagnosis as other studies have reported rates as high as 20%<sup>15</sup> to 32%<sup>24</sup>. As shown in Figure 3, the torn EAS can be misconstrued for the torn superficial transverse perineal muscle of a similar colour. The only distinguishing feature of the latter is that it arises laterally from the pubic rami. By contrast, the torn EAS surrounds the anal canal and upward traction on the torn muscle ends will result in elevation of anal canal<sup>25</sup>. Moreover, failure to identify the EAS ends and consequent inadvertent repair of the superficial transverse perineal muscle could explain the high rates of severe sphincter defects following primary repair<sup>25</sup>. This highlights the need for focused training and direct senior supervision during diagnosis and repair of OASIS.

Similar to other studies<sup>26,27</sup>, we found that women with a defect had significantly lower St. Mark's incontinence scores. Vaccaro et al reported that incontinence symptoms persists in 11% of women after repaired OASIS<sup>28</sup>.

By combining 3D endoanal ultrasound and manometry, we found that compared to women with a defect, those with an intact sphincter had significantly higher pressures, and a reduction to a lesser extent in women with a scar. This supports the hypothesis that even with good apposition, there is a small degree of functional compromise but not to the same extent a sphincter defect. Moreover, the pressures were significantly lower in those who had a defect compared to those with a scar (Table 1). In this large study we have differentiated a linear scar from a defect. In our experience, particularly from verified sphincter injuries<sup>9</sup>, including repaired 3a tears, we have invariably seen evidence of a scar or distortion of sphincter anatomy. In this study, if there was any

doubt, it was not classified as a missed tear. Other studies have shown reduced manometry pressures only in women with a defect and combined EAS and IAS injury<sup>29</sup>. This has clinical relevance as the endosonographic and manometric findings are useful in providing feedback to obstetricians on the adequacy of their repairs. It also has added value in women who have previously sustained OASIS and require counselling regarding future mode of delivery<sup>4,30,31</sup>. Ideally, this should be done in a dedicated one-stop perineal clinic with anal ultrasound and manometry facilities<sup>32</sup> and those women without evidence of OASIS can be reassured.

Our study showed a positive correlation between combined sonographic defects and impaired manometry (shorter anal length and lower pressures). IAS defects have been independently correlated to severe incontinence symptoms<sup>33</sup>. These results concur with previous studies<sup>34-36</sup>, highlighting the importance of accurate diagnosis of IAS injuries, and adequate repair<sup>29</sup>. Structured hands-on training workshops have been shown to improve doctors' ability to identify and repair OASIS<sup>38</sup>.

Compared to women with an intact sphincter or scar, the anal length was significantly shorter in women with any defect (Table 1). This has clinical relevance as it indicates that the full length of the disrupted sphincter was not approximated during the repair. Nordeval et al have shown that a short sphincter is associated with a poorer outcome and there was an inverse correlation between the sphincter length and the degree of incontinence<sup>39</sup>. Furthermore, Hool et al reported that the post-operative anal length after secondary sphincter repair best predicted continence<sup>40</sup>. The importance of restoring the full length of the ruptured sphincter during primary repair has been previously

highlighted<sup>16,35</sup>. Furthermore, inadequate repair of the appropriate muscle could explain the low pressures and persistent defects in one third of women with OASIS. However, a better understanding and re-enforcement of this important principle during repair is best implemented during hands-on training workshops that incorporate understanding of applied anatomy and physiology ([www.perineum.net](http://www.perineum.net); [www.IUGA.org](http://www.IUGA.org): PROTECT). In the UK, over a period of 10 years, perineal trauma accounted for 9% of total obstetric claims, and £31 million were awarded in legal payouts<sup>41</sup>. The morbidity associated with perineal trauma and the consequent burden to the National Health Service highlights the need to focus on prevention (as avoiding midline episiotomy, vacuum extraction in preference to forceps, and adopting techniques in the second stage of labour such as perineal support<sup>42</sup>), accurate identification and appropriate management of perineal and sphincter trauma.

It has been suggested that endoanal/perineal ultrasound in the post partum period may improve clinical detection of OASIS<sup>43,44</sup>. Faltin et al performed a randomised controlled trial and reported that severe faecal incontinence was significantly lower (3.3% vs 8.7%)<sup>43</sup> in women who had anal ultrasound in addition to clinical assessment. However, OASIS that were diagnosed sonographically, were not identified clinically in 5 women and the unnecessary exploration resulted in additional morbidity.

In conclusion, we have shown that seven percent of women in our unit who had a clinical diagnosis of OASIS were wrongly diagnosed as they only sustained a second degree tear. We believe that training methods and competency assessment tools for the diagnosis and repair of OASIS need urgent reappraisal. The role of anal ultrasound in the immediate post-partum period needs further evaluation as it will be dependent on

the expertise of the staff available in the acute situation to accurately interpret the images.

### Acknowledgments

We would like to thank Margarita Papakonstantinou, the statistician for the support in statistical analysis.

### References

1. Soerensen MM, Buntzen S, Bek KM, Laurberg S. Complete obstetric anal sphincter tear and risk of long-term fecal incontinence: a cohort study. *Dis Colon Rectum* 2013;56:992-1001.
2. Williams A, Lavender T, Richmond DH, Tincello DG. Women's experiences after a third-degree obstetric anal sphincter tear: a qualitative study. *Birth* 2005 ;32:129-36.
3. Fynes M, Donnelly V, Behan M, O'Connell PR, O'Herlihy C. Effect of second vaginal delivery on anorectal physiology and faecal continence: a prospective study. *Lancet* 1999;354:983-6
4. Scheer I, Thakar R, Sultan AH. Mode of delivery after previous obstetric anal sphincter injuries (OASIS) – a reappraisal. *Int Urogynecol J* 2009; 20:1095-1101.
5. Sultan AH, Kettle C. Diagnosis of perineal trauma. In *Perineal and anal sphincter trauma*, Sultan AH, Thakar R, Fenner D. Springer:London 2007: 13.
6. Sultan AH, Kamm MA, Talbot IC, Nicholls RJ, Bartram CI. Anal endosonography for identifying external sphincter defects confirmed histologically. *Br J Surg* 1994;81:463-5.
7. Santoro GA, Wieczorek AP, Dietz HP, Mellgren A, Sultan AH, Shobeiri SA, Stankiewicz A, Bartram C. State of the art: an integrated approach to pelvic floor ultrasonography. *Ultrasound Obstet Gynecol* 2011;37:381-96.
8. Sultan AH, Kamm MA, Hudson CN, Thomas JM, Bartram CI. Anal-sphincter disruption during vaginal delivery. *N Engl J Med* 1993 23;329:1905-11.
9. Andrews V, Thakar R, Sultan AH, Jones PW. Occult anal sphincter injuries -- myth or reality? *BJOG* 2006;113:195-200.

10. Sultan AH, Kamm MA, Hudson CN. Obstetric perineal tears: an audit of training. *J Obstet Gynaecol* 1995;15:19-23.
11. Fernando RJ, Sultan AH, Radley S, Jones PW, Johanson RB. Management of obstetric anal sphincter injury: a systematic review & national practice survey. *BMC Health Serv Res* 2002 ;2:9.
12. Ekéus C, Nilsson E, Gottvall K. Increasing incidence of anal sphincter tears among primiparas in Sweden: a population-based register study. *Acta Obstet Gynecol Scand* 2008;87:564-73.
13. Gurol-Urganci I, Cromwell DA, Edozien LC, Mahmood TA, Adams EJ, Richmond DH, Templeton A, van der Meulen JH. Third- and fourth-degree perineal tears among primiparous women in England between 2000 and 2012: time trends and risk factors. *BJOG* 2013 ;120:1516-25.
14. Dietz HP, Pardey J, Murray H. Pelvic floor and anal sphincter trauma should be key performance indicators of maternity services. *Int Urogynecol J* 2015;26:29-32.
15. Schizas A, Igualada-Martinez P, Lyons M, Darakhshan A, Oteng-Ntim E, Williams A. Anal endosonographic assessment of the accuracy of clinical diagnosis of obstetric anal sphincter injury and correlation with anal function and symptoms. Abstracts of the 42nd Annual Meeting of the International Continence Society (ICS), 15 – 19 October 2012, Beijing, China. *Neurourol Urodyn* 2012 ;31:709-1102.
16. Royal College of Obstetricians and Gynaecologists. The Management of Third and Fourth Degree Perineal Tears. Guideline No 29. London: RCOG Press, 2015.
17. Igawa Ty, Koebel H, Salvatore S, Laterza RM, Lowry A, Sievert K-D, Sultan A, 'Pathophysiology of Urinary Incontinence, Fecal Incontinence and Pelvic Organ Prolapse'. In *Incontinence*, Cardozo L Abrams P, Khoury, Wein A (eds). Plymouth: Health Publication Ltd: 2013; 261-360.
18. Sultan AH, Thakar R. Third and Fourth degree tears. In *Perineal and anal sphincter trauma*, Sultan AH, Thakar R, Fenner D. 33-51
19. Roos AM, Sultan AH, Thakar R. St. Mark's incontinence score for assessment of anal incontinence following obstetric anal sphincter injuries (OASIS). *Int Urogynecol J* 2009 ;20:407-10.
20. Vaizey CJ, Carapeti E, Cahill JA, Kamm MA. Prospective comparison of faecal incontinence grading systems. *Gut* 1999 ;44:77-80.

21. Sultan AH, Nicholls RJ, Kamm MA, Hudson CN, Beynon J, Bartram CI. Anal Endosonography and correlation with in vitro and in vivo anatomy. *Brit J Surg* 1992; 80:808-811.
22. Sultan AH, Kamm MA, Nicholls RJ, Bartram CI. Internal anal sphincter division during lateral sphincterotomy. Prospective ultrasound study. *Dis Colon Rectum* 1994;37:1031-1033
23. Groom KM, Paterson-Brown S. Can we improve on the diagnosis of third degree tears? *Europ J Obstet Gynecol Rep Biol* 2002;101:19-21.
24. Williams AB, Spencer JA, Bartram CI. Assessment of third degree tears using three-dimensional anal endosonography with combined anal manometry: a novel technique. *BJOG* 2002 ;109:833-5.
25. Sultan AH, Kettle C. Diagnosis of perineal trauma. In *Perineal and anal sphincter trauma*,. Sultan AH, Thakar R, Fenner D. Springer: London 2007:13-19
26. Sultan AH, Kamm MA, Hudson CN, Bartram CI. Third degree obstetric anal sphincter tears: risk factors and outcome of primary repair. *BMJ* 1994 2;308:887-91.
27. Norderval S, Marksog A, Røssaak K, Vonen B. Correlation between anal sphincter defects and anal incontinence following obstetric sphincter tears: assessment using scoring systems for sonographic classification of defects. *Ultrasound Obstet Gynecol* 2008 Jan;31:78-84.
28. Vaccaro C, Clemons JL. Anal sphincter defects and anal incontinence symptoms after repair of obstetric anal sphincter lacerations in primiparous women. *Int Urogynecol J* 2008 Nov;19:1503-8.
29. Roos A.-M., Thakar R, Sultan AH. Outcome of primary repair of obstetric anal sphincter injuries (OASIS): does the grade of tear matter? *Ultrasound Obstet Gynecol* 2010;36:368–374.
30. Fitzpatrick M, Cassidy M, Barassaud ML, Hehir MP, Hanly AM, O'Connell PR, O'Herlihy C. Does anal sphincter injury preclude subsequent vaginal delivery? *Eur J Obstet Gynecol Reprod Biol* 2016 ;198:30-34.
31. Karmarkar R, Bhide A, Digesu A, Khullar V, Fernando R. Mode of delivery after obstetric anal sphincter injury. *Eur J Obstet Gynecol Reprod Biol* 2015 ;194:7-10.
32. Thakar R, Sultan AH. Post partum problems and the role of a perineal clinic. In *Perineal and anal sphincter trauma*,. Sultan AH, Thakar R, Fenner D. Springer: London 2007:65-79

33. Mahony, M. Behan, L. Daly, C. Kirwan, C. O'Herlihy, and P. R. O'Connell, Internal Anal Sphincter Defect Influences Continence Outcome Following Obstetric Anal Sphincter Injury. *Am J Obstet Gynecol* 2007;196: 217 e1-5.
34. Nichols CM, Nam M, Ramakrishnan V, Lamb EH, Currie N. Anal sphincter defects and bowel symptoms in women with and without recognized anal sphincter trauma. *Am J Obstet Gynecol* 2006;194:1450-4.
35. Sultan AH, Monga AK, Kumar D, Stanton SL. Primary repair of obstetric anal sphincter rupture using the overlap technique. *BJOG* 1999 ;106:318-23.
36. Valsky DV, Cohen SM, Lipschuetz M, Hochner-Celnikier D, Yagel S. Three-dimensional transperineal ultrasound findings associated with anal incontinence after intrapartum sphincter tears in primiparous women. *Ultrasound Obstet Gynecol* 2012 ;39:83-90.
37. Roos AM, Abdool Z, Thakar R, Sultan AH. Predicting anal sphincter defects: the value of clinical examination and manometry. *Int Urogynecol J* 2012 ;23:755-63.
38. Andrews V, Thakar R, Sultan AH. Structured hands-on training in repair of obstetric anal sphincter injuries (OASIS): an audit of clinical practice. *Int Urogynecol J* 2009; 20:193-9.
39. Norderval S, Oian P, Revhaug A, Vonon B. Anal incontinence after obstetric sphincter tears: outcome of anatomic primary repairs. *Dis Colon Rectum* 2005;48:1055-61.
40. Hool GR, Lieber ML, Church JM. Postoperative anal canal length predicts outcome in patients having sphincter repair for fecal incontinence. *Dis Colon Rectum*. 1999 ;42:313-8.
41. Jha S, Sultan AH. Obstetric anal sphincter injury: the changing landscape. *BJOG*. 2015 ;122:931
42. Thakar R, Eason E. Prevention of perineal trauma. In *Perineal and anal sphincter trauma*,. Sultan AH, Thakar R, Fenner D. Springer: London 2007:65-79
43. Faltin DL, Boulvain M, Floris LA, Irion O. Diagnosis of anal sphincter tears to prevent fecal incontinence. A randomised controlled trial. *Obstet Gynecol* 2005;106:6-13.
44. Shek KL, Guzman-Rojas R, Dietz HP. Residual defects of external anal sphincter following primary repair: an observational study using transperineal ultrasound. *Ultrasound Obstet Gynaecol* 2014; 44: 704-9.

# Accepted Article



**Table 1:** Differences in anal manometry amongst the three groups using Mann-Whitney U Test (Group A = intact; Group B = scar; Group C= defect).

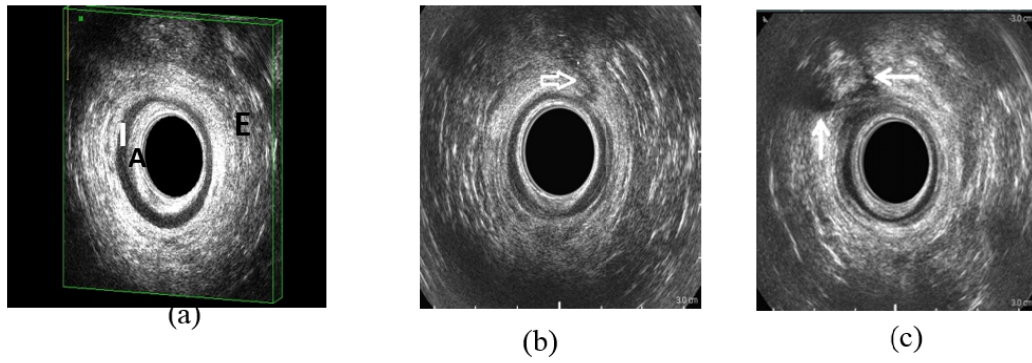
	<i>A</i>		<i>B</i>		<i>C</i>		<i>A vs B</i>	<i>A vs C</i>	<i>B vs C</i>
<i>Manometry findings</i>	N	Median (Range)	N	Median (Range)	N	Median (Range)			
<i>Anal Length (mm)</i>	61	25 (10-40)	514	25 (10-40)	305	20 (10-40)	P=0.226	<b>P=0.003</b>	<b>p&lt;0.001</b>
<i>Resting Pressure (mm Hg)</i>	61	55 (29-86)	515	50 (14-98)	312	43.5 (8-106)	<b>P=0.001</b>	<b>p&lt;0.001</b>	<b>p&lt;0.001</b>
<i>Squeeze Pressure (mm Hg)</i>	61	103 (44-185)	512	83.5 (20-194)	310	73.5 (23-180)	<b>p&lt;0.001</b>	<b>p&lt;0.001</b>	<b>p&lt;0.001</b>

**Table 2:** Differences in anal manometry measurements (median and range) among women with only IAS defect, only EAS Defect and EAS and IAS defect (Mann-Whitney U Test).

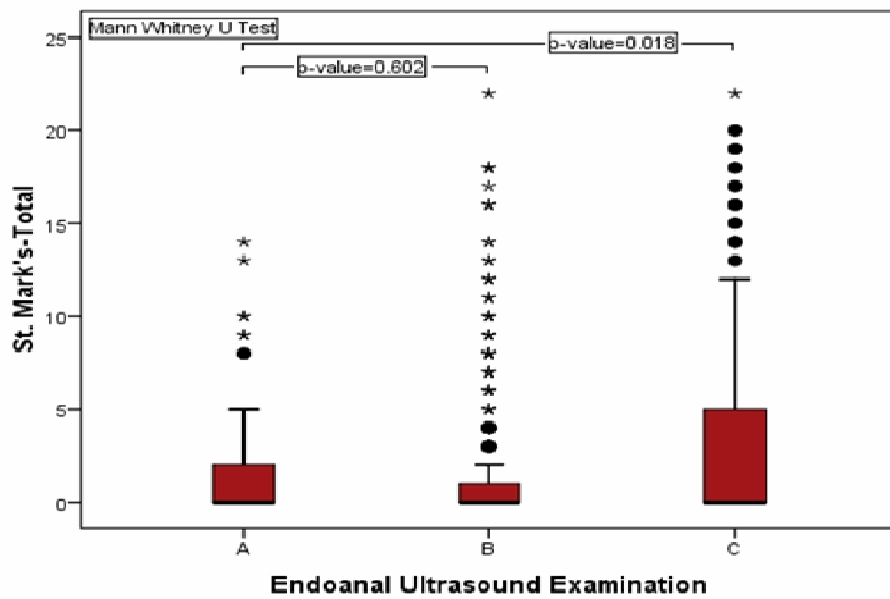
	<i>IAS defect (Group 1)</i>	<i>EAS defect (Group 2)</i>	<i>IAS + EAS defect (Group 3)</i>	<i>Comparison between groups 1 &amp; 2</i>	<i>Comparison between groups 1 &amp; 3</i>	<i>Comparison between groups 2 &amp; 3</i>
<i>Anal Manometry</i>	n=90	n=112	n=122			
<i>Anal Length (mm)</i>	87      20 (10-40)	110      20 (10-40)	108      20 (10-40)	P=0.24	P=0.293	<b>P=0.02</b>
<i>Resting Pressure (mm Hg)</i>	89      48 (15-88)	110      48.5 (15-88)	113      38 (8-106)	P=0.06	<b>p&lt;0.001</b>	<b>p&lt;0.001</b>
<i>Squeeze Pressure (mm Hg)</i>	89      78 (38-144)	110      77 (30-180)	111      64 (23-177)	P=0.90	<b>p&lt;0.001</b>	<b>p&lt;0.001</b>

The variable numbers in each group reflect missing data

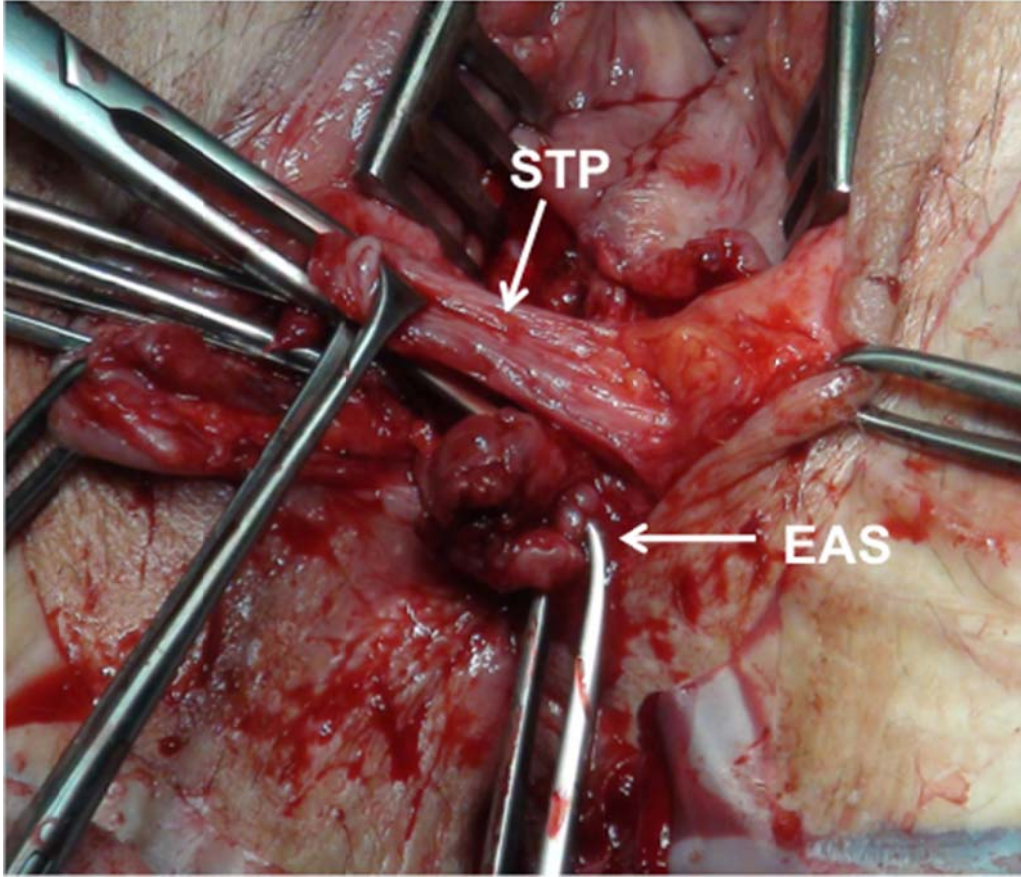
Figure Legends:



**Figure 1:** Endoanal ultrasound images. (a) Intact anal sphincter (no evidence of OASIS) E= external sphincter; I = internal sphincter; A= anal mucosa (b) External sphincter scar at 1 o'clock. (c) External sphincter defect between 10-12 o'clock.



**Figure 2:** Box-plot diagram showing the St. Mark's score distribution (Group A = intact; Group B = scar; Group C= defect).



**Figure 3:** Photograph of a third degree tear. Note how easily the superficial transverse perineal (STP) can be confused with the external anal sphincter (EAS) muscles. The main difference between the EAS and the STP is the direction of the STP muscle attachment laterally.