



## University of Dundee

### Surface anatomy of major anatomical landmarks of the neck in an adult population

Badshah, Masroor; Soames, Roger; Marwat, Muhammad Ibrahim; Khan, Muhammad Jaffar; Khan, Adnan

*Published in:*  
Clinical Anatomy

*DOI:*  
[10.1002/ca.22907](https://doi.org/10.1002/ca.22907)

*Publication date:*  
2017

*Document Version*  
Peer reviewed version

[Link to publication in Discovery Research Portal](#)

#### *Citation for published version (APA):*

Badshah, M., Soames, R., Marwat, M. I., Khan, M. J., & Khan, A. (2017). Surface anatomy of major anatomical landmarks of the neck in an adult population: a CT evaluation of vertebral level. *Clinical Anatomy*, 30(6), 781-787. <https://doi.org/10.1002/ca.22907>

#### **General rights**

Copyright and moral rights for the publications made accessible in Discovery Research Portal are retained by the authors and/or other copyright owners and it is a condition of accessing publications that users recognise and abide by the legal requirements associated with these rights.


- Users may download and print one copy of any publication from Discovery Research Portal for the purpose of private study or research.
- You may not further distribute the material or use it for any profit-making activity or commercial gain.
- You may freely distribute the URL identifying the publication in the public portal.

#### **Take down policy**

If you believe that this document breaches copyright please contact us providing details, and we will remove access to the work immediately and investigate your claim.

# **SURFACE ANATOMY OF MAJOR ANATOMICAL LANDMARKS OF THE NECK IN AN ADULT POPULATION: A CT EVALUATION OF VERTEBRAL LEVEL**

## **Authors Name:**

1. Masroor Badshah<sup>1, 2</sup> 
2. Roger Soames<sup>1</sup>
3. Muhammad Ibrahim<sup>3</sup>
4. Muhammad Jaffar Khan<sup>4</sup>
5. Adnan Khan<sup>5</sup>

## **Institutions:**

<sup>1</sup>Centre for Anatomy and Human Identification, University of Dundee, Scotland DD1 4HN, UK.

<sup>2</sup>North West School of Medicine, Sector A 3 Phase 5, Hayatabad Peshawar KP 25000, Pakistan.

<sup>3</sup>Department of Surgery, Khyber Teaching Hospital, Peshawar KP 25000, Pakistan.

<sup>4</sup>Department of Biochemistry, Khyber Medical University, Peshawar KP 25000, Pakistan.

<sup>5</sup>Department of Radiology, As Suwaidi Hospital, Shar-e- Hamza bin mutalib, Az zahra, Riyadh, Saudi Arabia.

## **\*Correspondence to:**

Dr. Masroor Badshah, Department of Anatomy, North West School of Medicine, Sector A 3 Phase 5, Hayatabad Peshawar KP 25000, Pakistan.

Cell no. 00923339236872

E-mail: [masroorbadshah@outlook.com](mailto:masroorbadshah@outlook.com)

This is the peer reviewed version of the following article: 'Surface anatomy of major anatomical landmarks of the neck in an adult population: a CT evaluation of vertebral level', *Clinical Anatomy*, which has been published in final form at <http://doi.org/10.1002/ca.22907>. This article may be used for non-commercial purposes in accordance with Wiley Terms and Conditions for Self-Archiving.

This article has been accepted for publication and undergone full peer review but has not been through the copyediting, typesetting, pagination and proofreading process which may lead to differences between this version and the Version of Record. Please cite this article as an 'Accepted Article', doi: 10.1002/ca.22907

# **SURFACE ANATOMY OF MAJOR ANATOMICAL LANDMARKS OF THE NECK IN AN ADULT POPULATION: A CT STUDY**

## **Abstract**

## **Introduction**

To compare the projectional surface anatomy of healthy individuals in an adult population with those with a thyroid mass, using computed tomography (CT).

## **Methods**

Sixteen slice CT images of 101 individuals were analyzed using a 32-bit Radiant DICOM viewer to establish the relationships among major anatomical landmarks in the neck and their vertebral levels. The structures investigated included: hard palate (HP), hyoid bone (HB) including body and lesser horns, soft palate (SP), thyroid gland (TG) (both superior and inferior poles), thyroid gland anteroposterior (APD) and superoinferior (SID) diameters, thyroid isthmus (TI) superoinferior dimension, epiglottis, vertebral arteries (right and left), and both right and left parotid glands (superior and inferior extents).

## **Results**

The vertebral levels noted most frequently were: body of hyoid bone (C4, 42.71%); lesser horns of hyoid bone (C3, 36.46%); thyroid gland superior pole (C6, 31.25%); and thyroid gland inferior pole (T2, 30.2%). TG-ID, TG-APD, and TG-SID were not significantly different between males and females in the healthy group; however, there was a significant gender difference in thyroid gland inferior diameter in the pathology group (males 2.16( $\pm$ 1.16) vs. females 3.37( $\pm$ 1.30),  $p=0.01$ , paired sample t-test).

## **Conclusion**

Further studies are needed to determine whether neck pathology in those with a thyroid mass affects the dimensions of the thyroid gland. Moreover, the surface anatomy of the neck should be revisited using modern imaging techniques to address inconsistencies in anatomy and clinical reference texts.

**Key words:** cross-sectional anatomy; neck surface anatomy; ethnic group; CT scans

## Introduction

Understanding the surface anatomy of the neck is important for clinical examination, diagnostic and therapeutic intervention, and various types of surgery (excisional biopsy, lobectomy and thyroidectomy) involving the neck (Mirjalili et al., 2012). Standard anatomical texts describe the positions of deeper neck structures in relation to bony or cartilaginous landmarks such as the hyoid bone and the thyroid and cricoid cartilages (Standring, 2008; Drake et al., 2010; Moore et al., 2010; Sinnatamby, 2011).

Most anatomical landmarks in the neck were initially defined in cadavers (Burns, 1809; Quain, 1844) and later supplemented using plain and contrast radiography (Bench, 1963; Stepovich, 1965; Gustavsson et al., 1972; Smith and Larsen, 1979; Espalieu et al., 1986). Modern imaging techniques including ultrasonography, computed tomography, and magnetic resonance imaging provide an opportunity to reassess neck surface anatomy *in vivo* with good precision in reasonably large numbers of individuals under relatively controlled conditions. Owing to the increasing availability of these techniques, the use of physical examination and the demand for accurate surface anatomy have declined (Mirjalili et al, 2012).

To date, there has been no detailed comparison of the vertebral levels of major anatomical landmarks in the neck between healthy individuals and those with neck pathology in an Indian subcontinent population using computed tomography (CT). The main aims of the present study are: (i) to reassess and compare the surface anatomy in terms of vertebral level of occurrence of neck structures in a healthy population with those with neck pathology; and (ii) to compare the data collected with those reported in the literature.

## Methods

CT scans of 101 individuals, categorized into a healthy group (n= 64) and a diseased group (having suspected thyroid mass (Fig. 3) in the neck (n= 35)), were taken in a supine orientation with the head placed in a standardized position. Sixteen slice CT images from each individual were acquired from Northwest General Hospital using a Light RT-16 CT scanner with slice thickness 1mm (General Electronics® USA), and a 16 slice scanner (Toshiba® Alexion Japan) with slice thickness 0.5mm. Two patients were excluded from further analysis owing to severe cervical spine deformity. For access to the archived CT scans, ethical approval was requested from and granted by the ethics committee of the respective institution under Ref No. NwGH/Res/Eth/2723.

Each image was analyzed using a 32-bit Radiant DICOM viewer to establish the relationships of major anatomical landmarks to their vertebral levels. The structures studied included: the hard palate (HP), hyoid bone (HB) including body and lesser horns, soft palate (SP), thyroid gland (TG) (both superior and inferior poles), thyroid gland anteroposterior (APD) and superoinferior (SID) diameters, thyroid isthmus superoinferior dimension (TG-SID), epiglottis, vertebral arteries (right and left), and the superior and inferior extents of the right and left parotid glands.

**Hard palate:** defined in the sagittal plane as the free edge against the corresponding specific vertebra or foramen magnum.

**Hyoid:** the body (Fig. 2) and lesser horn were selected as the most prominent portion against the specific vertebra or intervening intervertebral disc, identified in sagittal sections.

**Soft palate:** identified in the sagittal plane as the free edge extending from the hard palate, noted against the specific vertebra or intervening intervertebral disc.

**Thyroid gland:** both superior and inferior poles were identified in coronal sections as the upper and lower extents against the specific vertebra or intervening intervertebral disc.

**Thyroid gland anteroposterior dimension:** identified in the sagittal plane as the maximum diameter of the thyroid gland from front to back.

**Thyroid gland superoinferior dimension:** identified in the coronal plane as the maximum dimension extending from uppermost to lowermost pole.

**Thyroid isthmus superoinferior dimension:** identified in the coronal plane as the longitudinal dimension extending across the midline from superior to inferior extent anterior to the 2<sup>nd</sup>, 3<sup>rd</sup> and 4<sup>th</sup> tracheal rings (Fig. 3).

**Epiglottis:** the free end was taken as the reference and recorded against the specific vertebra or intervening intervertebral disc, identified in the sagittal plane.

**Vertebral arteries:** defined in the coronal plane as the point from where each arose from the subclavian artery (Fig. 4): the vertebral level was noted against the specific vertebra or intervening intervertebral disc.

**Parotid gland:** the superior and inferior extents were recorded in the coronal plane against the specific vertebra or intervening intervertebral disc.

### **Statistical analysis**

All the data collected were analyzed using Minitab version 17. Categorical data were expressed as frequencies and percentages, while numerical data were expressed as means and standard deviations. Differences between numerical CT variables of males and females in the healthy group, and between the healthy and 'thyroid mass' groups, were calculated using a two-sample t-test. P-values less than 0.05 were considered to indicate significance.

### **Results**

The healthy group comprised 64 individuals of whom 45 were male (70.31%) and 19 female (29.69%), and the 33 individuals in the 'thyroid mass' group of patients comprised 11 males (34.38%) and 21

females (65.63%). The mean age of the healthy group was 47.77( $\pm$ 15.65) years and of the 'thyroid mass' group 54.81( $\pm$ 13.92).

The vertebral levels of occurrence of neck structures in both groups are given in Table 1. The levels observed corresponded well with previous literature.

The vertebral level of the hard palate (anterior arch C1) corresponded with current descriptions. Other anatomical landmarks were most commonly observed at the following vertebral levels: body of the hyoid bone (C4, 42.71%); lesser horns of the hyoid bone (C3, 36.46%); superior pole of the thyroid gland (C6, 31.25%); inferior pole of the thyroid gland (T2, 30.2%); epiglottis (C3, 51.04%); soft palate (C1-2, 62.5%); right and left vertebral arteries (T1, 60.42%); superior and inferior extents of the right parotid gland (C1-3; 53.12%); and left parotid gland (C1-3; 55.21%).

TGI-D [SEE ABOVE], TG-APD, and TG-SID were not significantly different between males and females in the healthy group. However, thyroid gland inferior diameter was significantly different between males and female in the 'thyroid mass' group (males 2.16( $\pm$ 1.16) and females 3.37( $\pm$ 1.30),  $p=0.01$ , paired sample t-test) (Table 2).

A mass in the thyroid gland significantly influenced the anteroposterior, isthmus and superoinferior diameters of the thyroid ( $p<0.001$ , two-sample t-test) (Table 3).

## Discussion

The present study examined various anatomical landmarks in the neck by determining their vertebral levels in both healthy and 'thyroid mass' groups in an Indian subcontinent population. This is the first study to address the dimensions of the thyroid gland in this population and to consider how they could be affected in cases of thyroid pathology. Some differences from current anatomy and clinical reference texts were noted, and these need to be addressed (Hale et al., 2010).

Using the criteria stated above to determine the vertebral level of anatomical landmarks in the neck the following observations can be made:

**Hard palate:** The findings in the current study are similar to those reported by Mirjalili et al. (2012), i.e. the anterior arch of C1 (Atlas), and standard reference texts (Sinnatamby, 2011).

**Hyoid:** the body of the hyoid was most commonly observed at C4, much as reported by Mirjalili et al. (2012) but differing from standard anatomy texts (Standring, 2008; Sinnatamby, 2011; Moore et al., 2014). In the current study, the level of the tip of the lesser horn was most frequently C3. However, standard anatomy texts describe the lesser horn as a small bony projection originating from the superior part of the body near its junction with the greater horn (Moore et al., 2014). Previous studies recorded the most frequent vertebral level of the hyoid as C4 (King, 1952; Kollias and Krogstad, 1999).

**Thyroid gland:** The current findings differ from standard texts (Moore et al., 2014).

**Thyroid gland dimensions:** In the present study, various dimensions of thyroid gland including anteroposterior and superoinferior (and the dimensions of the thyroid isthmus) did not differ between males and females in the healthy group. However, among individuals with a thyroid mass, there was a significant gender difference in the inferior diameter of the thyroid gland (males 2.16 ( $\pm$ 1.16) and females 3.37 ( $\pm$ 1.30),  $p=0.01$ , paired sample t-test). Bann et al. (2017) observed that the position of the thyroid gland depends on changes in cervical spine height, hyoid to hard palate distance and tracheal angle ( $p=1.7 \times 10^{-11}$ ;  $r^2=0.37$ ). They also reported that the distance between the thyroid gland and the sternal notch decreased with age ( $p<0.001$ ). However, Bann et al. (2017) found no difference between age groups in thyroid position relative to the hyoid or cricoid cartilage.

**Epiglottis:** In the current study the most frequent level of occurrence was C3. Standard texts locate it just behind the root of the tongue and attached by its stalk to the back of the thyroid cartilage (Snell, 2012).

**Soft palate:** In the current study the most frequent level of occurrence was C1-2. One standard text locates it in the posterior third of the hard palate, suspended from its posterior border (Moore et al., 2014).

**Vertebral arteries:** In the current study the most frequent level of occurrence of both the right and left vertebral arteries was T1. However, standard texts refer to its origin from the first part of the subclavian artery as it enters the root of the neck (Drake et al., 2015).

**Parotid gland:** The superior and inferior extents of the right and left parotid glands in the current study were C1 and C3, respectively. However, anatomical texts refer to its extension from the zygomatic arch to the upper part of the neck (Sinnatamby, 2011).

It is clear from these findings that most anatomical texts locate the structures investigated in the current study in relation to structures other than vertebral level. This can cause confusion, as the structure used as a reference landmark could itself vary in its vertebral level of occurrence.

## Conclusion

The surface anatomy of the neck should be reappraised using modern imaging techniques and compared between healthy subjects and those with a thyroid mass, as the presence of thyroid pathology can influence thyroid dimensions and the locations of related structures. Furthermore, in light of the data presented in this study, neck surface anatomy should be revisited to address the discrepancies in anatomical and clinical texts.

## Acknowledgments

The authors would like to thank Ahsan Shafiq, Chief Medical Transcriptionist, for his invaluable assistance in arranging the CT scans.

## Funding

This research received no specific grant from funding agencies in the public, commercial, or not-for-profit sectors.

### **Conflict of Interest**

None

### **Informed Consent**

This study received approval from the respective institution under Ref No.NwGH/Res/Eth/2723.

### **Contributions**

The study was designed by MB and RS; MB, MI and AK collected the data, which were analyzed by MJK; the manuscript was written by MB and RS.

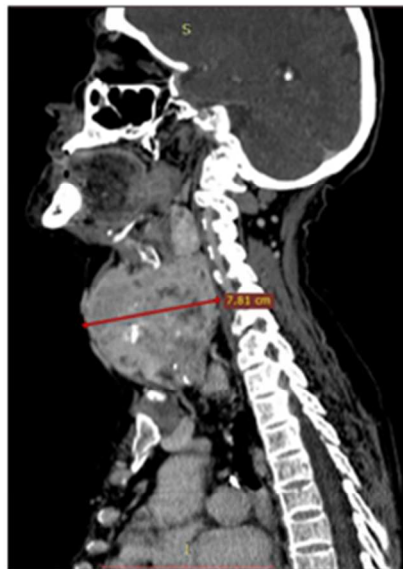### **References**

1. Bann DV, Kim Y, Zacharia T, Goldenberg D. 2017 The effect of aging on the anatomic position of the thyroid gland. *Clin Anat*30:205-212.
2. Bench RW. 1963. Growth of the cervical vertebrae as related to tongue, face and denture behavior. *Am J Orthod Dentofacial Orthop*49:183–214.
3. Burns A. 1809. Observation on some of the most frequent and important disease of heart. Edinburgh: Bryce. p 284.
4. Drake R, Vogl AW, Mitchell AW (2015) *Gray's Anatomy for Students*: Elsevier Health Science. pp. 803, 806, 1032, 1063.
5. Espalieu Ph, Cottier M, Relave M, Youvarlakis Ph, Cuilleret J. 1986. Radio-anatomic study of the carotid axis with regard to the implantation of microsurgical vascular anastomoses. *Surg Radiol Anat* 8:257–263.
6. Gustavsson U, Hansson G, Holmqvist A, Lundberg M. 1972. Hyoid bone position in relation to the head posture. *Sven Tandlak Tidskr* 65:423–430.
7. Hale SJ, Mirjalili SA, Stringer MD. 2010. Inconsistencies in surface anatomy: The need for an evidence-based reappraisal. *Clin Anat*23:922–930.
8. King EW. 1952. A roentgenographic study of pharyngeal growth. *Angle Orthod*22:23–37.
9. Kollias I, Krogstad O. 1999. Adult craniocervical and pharyngeal changes—a longitudinal cephalometric study between 22 and 42 years of age. I. Morphological craniocervical and hyoid bone changes. *Eur J Orthod*21:333–344.
10. Mirjalili SA, McFadden SL, Buckenham T, Stringer MD. Vertebral levels of key landmarks in the neck. *Clin Anat* 2012;25:851-7.
11. Moore KL, Dalley AF, Agur AMR (2014) *Clinically Oriented Anatomy*. Philadelphia, PA: Lippincott Williams & Wilkins. pp. 935, 984, 1000, 1010, 1018, 1023, 1039, 1040.
12. Quain R. 1844. *The Anatomy of the Arteries of Human Body*. London: Taylor and Walter.

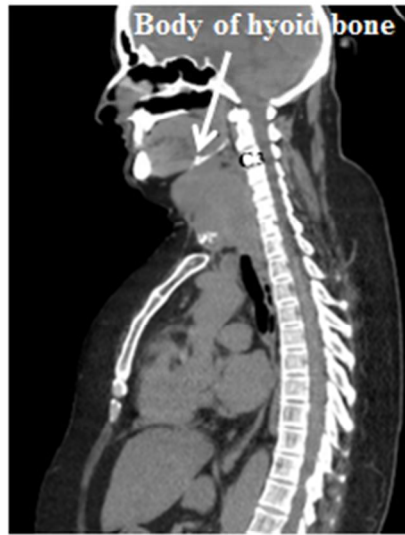

13. Sinnatamby CS. 2011 Last's Anatomy: Regional and Applied. Edinburgh: Churchill Livingstone, Elsevier. p 341, 345, 354, 356, 534.
14. Smith D, Larsen L. 1979. On the symmetry and asymmetry of the bifurcation of the common carotid artery. *Neuroradiol* 17:245– 247.
15. Snell RS (2012) *Clinical Anatomy by Regions* 9<sup>th</sup> Edition: Lippincott Williams & Wilkins pp. 184, 208, 458.
16. Standring S et al. 2008. *Gray's Anatomy: The Anatomical Basis of Clinical Practice*. Edinburgh: Churchill Livingstone. p397, 400, 405, 406.
17. Stepovich ML. 1965. A cephalic positional study of the hyoid bone. *Am J Orthod Dentofacial Orthop* 51:882–900.

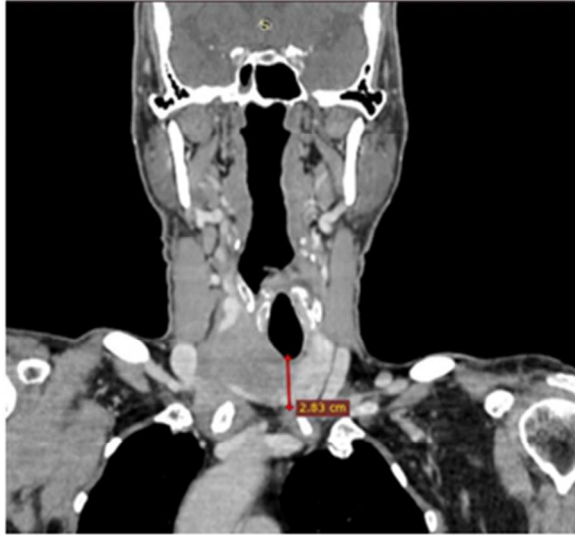Accepted Article



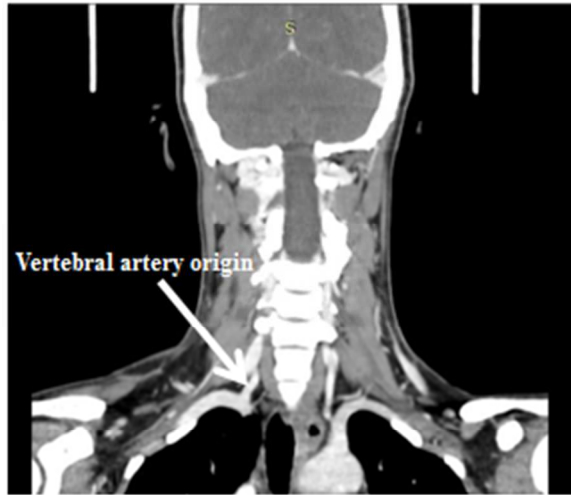
**Fig.1. Sagittal scan showing measurement of anteroposterior diameter of thyroid mass**



**Fig.2. White arrow in sagittal scan showing vertebral level of body of hyoid bone**



**Fig.3. Coronal scan showing measurement of superoinferior diameter of thyroid isthmus**



**Fig.4. White arrow in coronal scan showing vertebral level of origin of right vertebral artery**

**Table 1.** Comparison of the vertebral level of neck structures between healthy individuals and those with neck pathology.

Parameter	Level	Total		Healthy		Patient (Mass in thyroid)	
		N	%	N	%	N	%
<b>Hard Palate (HP)</b>							
	<b>C1 anterior arch</b>	<b>63</b>	<b>65.62</b>	<b>42</b>	<b>66.66</b>	<b>21</b>	<b>33.33</b>
	Clivus	29	30.21	18	28.13	11	34.38
	C1-2	2	3.13	0	0.000	2	2.08
	C2	1	1.04	1	1.56	0	0.000
<b>Body of Hyoid Bone (BHB)</b>							
	C2	1	1.04	1	1.56	0	0.000
	C3	12	12.50	8	12.50	4	12.50
	C3-4	8	8.33	6	9.38	2	6.25
	<b>C4</b>	<b>41</b>	<b>42.71</b>	<b>26</b>	<b>40.63</b>	<b>15</b>	<b>46.88</b>
	C4-5	9	9.38	4	6.25	5	15.63
	C5	23	23.96	17	26.56	6	18.75
	C6	2	2.08	2	3.13	0	0.00
<b>Horns of Hyoid Bone (HHB)</b>							
	C2	8	8.33	4	6.25	4	12.50
	C2-3	11	11.46	8	12.50	3	9.38
	<b>C3</b>	<b>35</b>	<b>36.46</b>	<b>25</b>	<b>39.06</b>	<b>10</b>	<b>31.25</b>
	C3-4	11	11.46	7	10.94	4	12.50
	C4	28	29.17	17	26.56	11	34.38
	C4-5	1	1.04	1	1.56	0	0.000
	C5	1	1.04	1	1.56	0	0.000
	C6	1	1.04	1	1.56	0	0.000
<b>Thyroid Gland Superior Pole (TGSP)</b>							
	C2	6	6.250	0	0.000	6	18.750

C2-3	2	2.083	0	0.000	2	6.250
C3	4	4.167	2	3.125	2	6.250
C3-4	1	1.042	0	0.000	1	3.125
C4	5	5.21	3	4.69	2	6.250
C4-5	6	6.250	5	7.813	1	3.125
C5	24	25.000	16	25.000	8	25.000
C5-6	7	7.292	4	6.250	3	9.375
<b>C6</b>	<b>30</b>	<b>31.250</b>	<b>26</b>	<b>40.625</b>	<b>4</b>	<b>12.500</b>
C6-7	2	2.083	2	3.125	0	0.000
C7	5	5.208	5	7.813	0	0.000
T1	1	1.042	1	1.563	0	0.000
<b>Thyroid Gland Inferior Pole (TGIP)</b>						
C6-7	1	1.04	1	1.56	0	0.000
C7	1	1.04	1	1.56	0	0.000
C7-T1	1	1.04	1	1.56	0	0.000
T1	26	27.083	21	32.813	5	15.625
T1-2	13	13.542	10	15.625	3	9.375
<b>T2</b>	<b>29</b>	<b>30.208</b>	<b>20</b>	<b>31.250</b>	<b>9</b>	<b>28.125</b>
T2-3	7	7.292	6	9.375	1	3.125
T3	9	9.375	2	3.125	7	21.875
T3-4	2	2.083	1	1.563	1	3.125
T4	3	3.125	1	1.563	2	6.250
T5	1	1.042	0	0.000	1	3.125
<b>Epiglottis (E)</b>						
C2	16	16.67	9	14.06	7	21.88
C2-3	10	10.42	7	10.94	3	9.38
<b>C3</b>	<b>49</b>	<b>51.04</b>	<b>35</b>	<b>54.69</b>	<b>14</b>	<b>43.75</b>
C3-4	6	6.25	4	6.25	2	6.25

C4	11	11.46	7	10.94	4	12.50
C5	1	1.04	1	1.56	0	0.000
<b>Soft Palate (SP)</b>						
<b>C1-2</b>	<b>60</b>	<b>62.50</b>	<b>41</b>	<b>64.06</b>	<b>19</b>	<b>59.38</b>
C1-3	3	3.13	0	0.000	3	9.38
C1-2-3	4	4.17	3	4.69	1	3.13
C2	1	1.04	1	1.56	0	0.000
Clivus-C1	1	1.04	1	1.56	0	0.000
Clivus-C2	25	26.04	17	26.56	8	25.00
Clivus-C2-3	1	1.04	0	0.000	1	3.13
<b>Right Vertebral Artery (RVA)</b>						
C7	2	2.08	2	3.13	0	0.000
C7-T1	3	3.13	3	4.69	0	0.000
<b>T1</b>	<b>58</b>	<b>60.42</b>	<b>40</b>	<b>62.50</b>	<b>18</b>	<b>56.25</b>
T1-2	15	15.63	11	17.19	4	12.50
T2	16	16.67	7	10.94	9	28.13
T2-3	1	1.04	1	1.56	0	0.000
<b>Left Vertebral Artery (LVA)</b>						
C7	2	2.08	2	3.13	0	0.000
C7-T1	3	3.13	3	4.69	0	0.000
<b>T1</b>	<b>58</b>	<b>60.42</b>	<b>39</b>	<b>60.94</b>	<b>19</b>	<b>59.38</b>
T1-2	16	16.67	12	18.75	4	12.50
T2	15	15.63	7	10.94	8	25.00
T2-3	1	1.04	1	1.56	0	0.000
<b>Right Parotid Gland Superior and Inferior Extents (RPGSIE)</b>						
C1-C2	1	1.04	1	1.56	0	0.000
<b>C1-C3</b>	<b>51</b>	<b>53.12</b>	<b>34</b>	<b>53.13</b>	<b>17</b>	<b>53.64</b>
C1 to C2-3	18	18.75	11	17.19	7	21.88
C2 to C2-3	1	1.04	1	1.56	0	0.000



C1 to C3-4	6	6.25	4	6.25	2	6.25
C1-C4	2	2.08	1	1.56	1	3.13
<b>Left Parotid Gland Superior and Inferior Extents (LPGSIE)</b>						
C1-C2	15	15.63	10	15.63	5	15.63
<b>C1-C3</b>	<b>53</b>	<b>55.21</b>	<b>35</b>	<b>54.69</b>	<b>18</b>	<b>56.25</b>
C1 to C2-3	18	18.75	11	17.19	7	21.88
C2 to C2-3	1	1.04	1	1.56	0	0.000
C1 to C3-4	6	6.25	4	6.25	2	6.25
C1-C4	2	2.08	2	3.13	0	0.000

**Table 2.** Comparison of means and standard deviations of various parameters of thyroid gland and thyroid gland isthmus between healthy and diseased male and female individuals.

<b>Parameter</b>	<b>Male</b>	<b>Female</b>	<b>p-value*</b>
	<b>Mean(SD)</b>	<b>Mean(SD)</b>	
<b>Healthy</b>			
Age (years)	48.2(14.7)	48.2(16.2)	0.712
TGI-D (cm)	1.43(0.6)	1.41(0.65)	0.903
TG-APD (cm)	2.6(0.61)	2.5(0.74)	0.670
TG-SID (cm)	5.2(1.10)	4.8(1.13)	0.178
<b>Pathology</b>			
Age (years)	53.8(13.0)	55.4(14.7)	0.769
TGI-D (cm)	2.16(1.16)	3.37(1.30)	0.012
TG-APD (cm)	4.69(1.64)	5.27(1.86)	0.385
TG-SID (cm)	8.02(2.13)	8.89(2.67)	0.341

\*p-value based on 2-sample t-test

**Table 3.** Comparison of means and standard deviations of various parameters of thyroid gland between healthy and diseased individuals.

<b>Variable</b>	<b>Healthy</b>	<b>Patient</b>	<b>p-value</b>
	<b>Mean(SD)</b>	<b>Mean(SD)</b>	
TG-APD	2.57(0.64)	5.09(1.78)	<0.001
TGI-D	1.42(0.61)	2.98(1.37)	<0.001
TG-SID	5.09(1.12)	8.60(2.50)	<0.001

TG; Thyroid gland, APD; Anteroposterior diameter, TGI; Thyroid gland isthmus, SID; Superoinferior diameter, D; Diameter