



**University of Dundee**

**Final results of a European, multi-centre, prospective, observational Study of Permacol<sup>™</sup> collagen paste injection for the treatment of anal fistula**

Giordano, Pasquale ; Sileri, Pierpaolo; Buntzen, Steen ; Stuto, Angelo ; Nunoo-Mensah, Joseph; Lenisa, Leonardo ; Singh, Baljit; Thorlacius-Ussing, Ole; Griffiths, Ben; Ziyaie, Dorin

*Published in:*  
Colorectal Disease

*DOI:*  
[10.1111/codi.13715](https://doi.org/10.1111/codi.13715)

*Publication date:*  
2018

*Document Version*  
Peer reviewed version

[Link to publication in Discovery Research Portal](#)

*Citation for published version (APA):*

Giordano, P., Sileri, P., Buntzen, S., Stuto, A., Nunoo-Mensah, J., Lenisa, L., ... Ziyaie, D. (2018). Final results of a European, multi-centre, prospective, observational Study of Permacol<sup>™</sup> collagen paste injection for the treatment of anal fistula. *Colorectal Disease*, 20(3), 243-251. <https://doi.org/10.1111/codi.13715>

**General rights**

Copyright and moral rights for the publications made accessible in Discovery Research Portal are retained by the authors and/or other copyright owners and it is a condition of accessing publications that users recognise and abide by the legal requirements associated with these rights.

- Users may download and print one copy of any publication from Discovery Research Portal for the purpose of private study or research.
- You may not further distribute the material or use it for any profit-making activity or commercial gain.
- You may freely distribute the URL identifying the publication in the public portal.

**Take down policy**

If you believe that this document breaches copyright please contact us providing details, and we will remove access to the work immediately and investigate your claim.

Article type : Original Article

493-2016.R2  
Original Article

**Final results of a European, multi-centre, prospective, observational Study of  
Permacol™ collagen paste injection for the treatment of anal fistula**

Pasquale Giordano, MD, FRCS(Eng), FRCS(Ed)<sup>1</sup>; Pierpaolo Sileri, MD, MS, PhD<sup>2</sup>, Steen Buntzen, MD, DMSc<sup>3</sup>, Angelo Stuto, MD<sup>4</sup>, Joseph Nunoo-Mensah, B Med Sci, BM BS, FRCS(Gen Surg), LLM<sup>5</sup>, Leonardo Lenisa, MD, PhD<sup>6</sup>, Baljit Singh, BA, BM, BCh, MA, DPhil, FRCS(I), FRCS(Eng)<sup>7</sup>, Ole Thorlacius-Ussing, MD, DMSc<sup>8</sup>, Ben Griffiths, MBChB, BSc, FRCS(Gen Surg)<sup>9</sup>, Dorin Ziyaie, MBChB, MD, FRCSEd(Gen Surg)<sup>10</sup>

<sup>1</sup>Consultant Surgeon & Honorary Senior Lecturer; Colorectal Department, Whipps Cross University Hospital, Barts Health, London, UK

<sup>2</sup>Assistant Professor of Surgery; University of Rome Tor Vergata, Rome, Italy

<sup>3</sup>Consultant Surgeon in Colorectal Surgery; Department of Surgery, Aarhus University Hospital, Aarhus, Denmark

<sup>4</sup>Chair; Coloproctology and Pelvic Floor Surgery, Policlinico Abano Terme, Padova, Italy

<sup>5</sup>Consultant Colorectal, Laparoscopic & General Surgeon; Department of Colorectal Surgery, King's College Hospital, London, UK

<sup>6</sup>Consultant Surgeon; General Surgery Unit, Casa di Cura Humanitas San Pio X, Milan, Italy

<sup>7</sup>Consultant Colorectal Surgeon; Leicester General Hospital, Leicester, UK

This article has been accepted for publication and undergone full peer review but has not been through the copyediting, typesetting, pagination and proofreading process, which may lead to differences between this version and the Version of Record. Please cite this article as doi: 10.1111/codi.13715

This article is protected by copyright. All rights reserved.

<sup>8</sup>Professor of Surgery and Consultant Surgeon; Department of Gastrointestinal Surgery,  
Aalborg University Hospital, Aalborg, Denmark

<sup>9</sup>Consultant Colorectal Surgeon; NUTH Foundation Trust, Newcastle, UK

<sup>10</sup>Consultant Colorectal Surgeon; Ninewells Hospital & Medical School, Dundee, Scotland,  
UK

**Conflicts of Interest and Source of Funding:** Study was sponsored and funded by Medtronic (Mansfield, MA). All authors (or their institutions) received research support from Medtronic to conduct this study. In addition, SB received personal fees from Covidien (now a subsidiary of Medtronic), and BS received honorarium as a speaker for Medtronic.

**Corresponding Author:**

Consultant Surgeon & Honorary Senior Lecturer  
Department of Colorectal Surgery Lead  
Barts Health NHS Trust  
Whipps Cross University Hospital  
Whipps Cross Rd.  
Leytonstone, London, UK, E11 1NR  
Office: +44 2085356656  
Mobile: +44 7736232118  
Fax: +44 2085356656  
pasquale.giordano@bartshealth.nhs.uk

**Running Title:** Permacol™ collagen paste for anal fistula

**Abstract**

*Aim:* Permacol™ collagen paste (Permacol™ paste) is an acellular cross-linked porcine dermal collagen matrix suspension for use in soft tissue repair. The use of Permacol™ paste in the filling of anorectal fistula tract is a new sphincter-preserving method for fistula repair. The MASERATI100 study was a prospective, observational clinical study with the objective to assess the efficacy of Permacol™ collagen paste for anal fistula repair in 100 patients.

*Method:* Patients (N=100) with anal fistula were treated at ten European surgical sites with a sphincter-preserving technique using Permacol™ paste. Fistula healing was assessed at 1, 3, 6, and 12 months post-treatment, with the primary endpoint being healing at 6 months. Faecal continence and patient satisfaction were surveyed at each follow-up; adverse events (AEs) were monitored throughout the follow-up.

*Results:* At 6 months post-surgery, 56.7% of patients were healed, and the percentage healed was largely maintained, with 53.5% healed at 12 months. 29.0% of patients had at least one AE, and 16.0% of patients had one or more procedure-related AE. Most AEs reported were minor and similar to those commonly observed after fistula treatment, and the incidence of serious adverse events was low (4.0% of patients). Regardless of treatment outcome, 73.0% of patients were satisfied or very satisfied with the procedure.

*Conclusion:* Permacol™ paste provides a promising sphincter-preserving treatment for anal fistulas with minimal adverse side-effects.

**ClinicalTrials.gov Identifier:** NCT01624350

**Key Words:** anal fistula, Permacol™ collagen paste, faecal continence, sphincter-preserving technique

**What does this paper add to the literature? (50 words max)**

This manuscript reports the final one year results of the one hundred patient cohort of the MASERATI100 study, the first study ever to assess the efficacy and safety of a sphincter preserving fistula repair technique using Permacol™ collagen paste in the treatment of intersphincteric and transsphincteric primary and recurrent fistula.

## Introduction

Treatment options for repair and eradication of anal fistula bear the risk of postoperative faecal incontinence. Minimally invasive, sphincter-preserving treatments minimize risk of postoperative faecal incontinence, but success rates have been low [1-4]. Biological infill materials used to fill and close the fistula tract can support and promote tissue healing without damage to the sphincter muscle or surrounding tissue. Such materials include fibrin glue, a fistula plug composed of lyophilised porcine-derived small intestinal submucosa (Biodesign<sup>®</sup> anal fistula plug, Cook Biotech Incorporated, West Lafayette, Indiana, USA), and autologous adipose cells, but their success rates vary widely [5-7]. Laying open the fistula tract of short intersphincteric fistulas is considered a relatively safe practice, but this method may still pose a small risk of faecal incontinence and wound complications [8]. Thus, the need for alternate treatment options is warranted.

The core technology of Permacol<sup>™</sup> collagen paste (Medtronic; Mansfield, MA, USA; henceforth, referred to as Permacol paste) is also the primary composition for Permacol<sup>™</sup> surgical implant (intended for soft tissue repair) and Permacol<sup>™</sup> collagen injection (intended for filling and bulking indications). Permacol paste is a sterile suspension of acellular cross-linked porcine dermal collagen matrix and saline. It may act as a scaffold to support cellular infiltration, promote tissue vascularization and enable fistula closure without damaging the anal sphincter.. As a paste, Permacol<sup>™</sup> is pliable and conforms to the unique shape of the fistula tract in contrast to other implant materials which may be too liquid or rigid.

The primary aim of the MASERATI100 clinical study was to assess anal fistula healing at 6 months using Permacol™ paste. The secondary aims were to evaluate fistula healing within one year, adverse events, pain, faecal continence, patient satisfaction, and quality of life. This manuscript reports the completed one year study results including all 100 patients enrolled from 10 investigative sites in Europe.

## Methods

The MASERATI100 study is a prospective, multi-centre, post-market, single-arm observational study on the use of Permacol™ paste in the treatment of anal fistulas in 100 patients. Ten European centres participated. This study received approval from both local and regional ethics committees and was conducted according to Good Clinical Practice (GCP) guidelines and with adherence to all European and national regulations.

### *Study Participants*

Patients with a clinical diagnosis of cryptoglandular anal fistula were invited to take part. Inclusion and exclusion criteria have been described in a previous study [9]. Patients with a solitary, primary or recurrent, transsphincteric or intersphincteric fistula tract of cryptoglandular origin were eligible. All underwent magnetic resonance imaging (MRI) of the perineum. MRI scans were anonymised and assessed externally by one radiologist. If the operating surgeon deemed that the intraoperative findings met the inclusion criteria, the patient was included in the study and treated with Permacol™ paste. Patients who gave informed consent but failed inclusion criteria or refused treatment were considered screen failures. Patients were reviewed at one, three, six, and 12 months following surgery.

## *Materials*

Permacol™ paste (Medtronic; Mansfield, MA) is contained within a sterile 3-mL syringe with a Luer-Lok connector. The milled collagen matrix suspension was injected into the fistula tract through a flexible cannula sheath (BD Angiocath™ 12GA; Becton Dickinson Medical Systems; Franklin Lakes, NJ, USA). Other materials used in the surgical procedure were standard and provided by the institution at which the patients were treated.

## *Surgical Procedure*

No other fistula surgery was to be performed between the MRI and treatment with Permacol™ paste, apart from placement of a draining/loose seton if deemed appropriate. After pre-operative eligibility was confirmed, the surgeon proceeded with the surgery using standard surgical procedures based on training provided by the study sponsor. The requirement for bowel preparation was at the surgeon's discretion. Examination under general anaesthesia was performed to confirm the patient's suitability for the study. The internal and external fistula openings were identified. The "Instructions for Use" for Permacol™ paste were followed, avoiding any dissection in or around the anal sphincter. Any seton was removed and then the fistula tract was de-epithelialised with a wire brush or equivalent to remove granulation tissue. The flexible cannula sheath was then inserted into the external opening of the fistula to the internal opening, which was closed by applying finger pressure. The paste was then injected to fill the tract completely (Figure 1). The tract was judged to be completely filled when paste was visualised at both internal and external openings. The internal opening was closed with a simple resorbable suture. The external opening was also loosely closed with an absorbable suture and this allowed drainage of the fistula, but not extrusion of the paste. A sterile dressing was applied to the wound. Standard post-operative care was provided based on the routines adopted by each investigational site.

### *Outcome Measures*

The primary endpoint was the rate of fistula healing at six months after surgery. Secondary outcome measures were safety, pain, faecal continence, patient satisfaction, and quality of life.

### *Outcome Assessments*

Patients were assessed for fistula healing and adverse events at one, three, six, and 12 months by the investigating surgeon. Fistula healing was defined as the absence of any anal symptom or discharge from the treated fistula with a closed external opening confirmed on clinical evaluation. If a patient exited the study after the 3-month follow-up visit with a non-healed fistula, that patient's fistula was considered to be unhealed at the 6-month and 12-month assessments. Incidence and severity of adverse events (AEs) were recorded up to 12 months. Pain was assessed using a 10-point Visual Analog Scale with the baseline at a screening visit prior to and within 60 days of scheduled surgery. It was reassessed at each follow-up visit. Faecal continence was assessed before surgery and at each follow-up using the Cleveland Clinical Florida Faecal Incontinence (CCF-FI) questionnaire. At each follow-up, patient satisfaction was measured by questionnaire and graded as "Very Satisfied," "Satisfied," "Dissatisfied," or "Very Dissatisfied" via a questionnaire. The EQ-5D Quality of Life (QOL) score was assessed at baseline, three, six, and 12 months.

### *Statistical Analysis*

The sample size of the MASERATI100 clinical study was based on an expected healing rate of 60% and a two-sided 95.0% confidence interval for a single proportion extended to 10% on either side, with an assumed drop-out rate of 7% at six months. The final



sample size was determined to be 100 for the evaluable population, and the final analysis included all 100 patients treated. Fistula healing was presented as the number and percentage of patients with a healed fistula at each of the follow-up visits, with a 95% confidence interval. A chi-squared test or Fisher's exact test was used to compare percentages of healing. Univariate and multivariate Cox regression analyses were performed to determine if any patient or fistula characteristic impacted fistula healing. The correlation between age and time taken to return to work and normal daily activities was analysed by a Spearman correlation test. CCF-FI scores and patient satisfaction were assessed at completion of the study: either the last visit before the exit in the case of patients who left the study early or the 12-month visit for the patients who completed the study. Differences in pain, CCF-FI score, and patient satisfaction from baseline to follow-up visits was compared by Wilcoxon signed rank tests or signed tests. The number and percentage of patients with an adverse event (AE) were analysed by severity and relationship to the paste or the procedure. All tests were two-sided and  $p < 0.05$  was considered statistically significant. All analyses were performed with SAS Version 9.2 (SAS Institute, Inc.; Cary, NC, USA).

## **Results**

### *Participants and Procedural Characteristics*

One hundred out of 143 screened patients were enrolled in the MASERATI100 study between September 18, 2012 and February 5, 2014 with a median follow-up of 50 (1.6 – 74.4) weeks. The median age of patients was 47.5 (range: ? ) yrs. The male to female ratio was 2.3:1 (Table 1). Fistula tracts ranged from 0.5 to 6.5 cm in length. Most (86%) patients had had previously undergone insertion of a loose seton, with median placement of 99 (14-1437) days.

Granulation tissue was removed from most patients (93%) (Table 1). A single unit of the paste ( $\leq 3$  mL Permacol<sup>TM</sup> paste) was sufficient to completely fill the fistula tract in 96/100 patients. Duration of surgery was 21 (10 – 55) mins. Although most patients (66%) were discharged on the day of the procedure, 29 stayed overnight, and five had a longer admission. The length of stay was influenced by the patient's age, the time of the procedure and the patient's proximity to the hospital. The median interval from the procedure to return to work and resume normal daily activity was 7 (1–35) days.

A total of 75 patients completed follow-up to 12 months (Figure 2). In 24 patients who exited the study early, the fistula failed to heal at the final assessment (N=18) or the fistula recurred after an initial apparent healing (N=7). Five patients exited the study at one month, 11 at three months, and eight at six months and were considered as unhealed at all subsequent follow-up time points. Only one patient was lost to follow-up after the three month visit and at that time the fistula had not healed.

#### *Efficacy of Permacol Paste*

Fistula healing is shown in Table 2. At 6 months post-surgery, 55 (56.7%; N=97) patients exhibited a clinically healed fistula. The healing rate was similar at both three months (53.2%; 50/94) and 12 months (53.5%; 53/99). The time to first healing, based on Kaplan-Meier estimates, was 76.0 days with a 95% confidence interval of 39.0–98.0 days. Most fistulae had healed within the first month. A total of 29 (29.0%) patients exhibited a recurrence within the 12 month follow-up.

Fistula healing at 12 months was associated with no Permacol™ paste extrusion, shorter fistula tract length ( $\leq 4$  cm), and an intersphincteric fistula (Table 3). Regression analysis did not confirm that intersphincteric fistulae were more likely to heal (Table 4). Patients with no evidence of expulsion or leakage of Permacol™ paste ( $P = 0.002$ ) or shorter fistula tract length ( $P = 0.030$ ) were more likely to heal (Table 4). Older patients and patients with a shorter time of seton implantation (among those with a previous seton) were also more likely to heal ( $P = 0.004$  and  $0.040$ , respectively). Patients with an anal abscess were more than four times more likely to experience treatment failure. Potential risk factors such as diabetes, obesity, smoking status and previous failed treatments, including fistulotomy and fistulectomy, did not influence the clinical outcome of Permacol™ paste injection.

#### *Adverse Events*

Twenty nine patients experienced at least one Adverse Event (Table 5). AEs experienced by more than two patients included anal abscess, fistula tract infection, postoperative wound infection, procedural pain, and proctalgia. Four patients experienced Serious Adverse Events (SAEs) such as new anal fistula, anal abscess, procedural pain, and complex regional pain syndrome. Device-related AEs and procedure-related AEs occurred in 16 (16.0%) patients.

#### *Pain, Faecal Continence, Patient Satisfaction and Quality of Life*

At baseline (within 60 days prior to surgery), 29 (29.6%) patients were pain free, increasing to 45 (45.9%) at one month. At 12 months, 66 (89%) patients had only mild pain or no pain at all. Overall, mean patient pain was reduced ( $P < 0.001$ ), relative to baseline, at all post-procedural follow-up assessments (Figure 3A).

The mean CCF-FI score was significantly less ( $P<0.05$ ) at the three, six, and 12 month follow-up visits compared to the preoperative baseline assessment (Figure 3B), indicating improved faecal continence at these stages. The mean CCF-FI scores at all patients' last visit, including scores for those 24 patients who exited the study early, was not significantly different from baseline.

The EQ-5D QOL questionnaire results are reported in Figure 3C. Relative to baseline, significantly fewer subjects reported problems engaging in usual activities or experienced problems with anxiety and depression at the six month follow-up. Moreover, significantly fewer subjects had problems with motility and pain/discomfort at all follow-up visits compared to baseline..

A total of 85 patients completed the satisfaction survey in at least two follow-up visits. Patient satisfaction was assessed at each patient's final visit in order to include patients who exited the study early with unhealed fistula. Regardless of healing status, 73.0% of patients (N=62) were satisfied or very satisfied with the procedure upon their last follow-up visit.

## **Discussion**

This study suggests that Permacol<sup>TM</sup> paste could be useful in managing anal fistula with healing rates of more than 50%, a low incidence of serious adverse events, and high patient satisfaction.. Fistula closure was fast with an average time to healing of just over two months. In fact, the majority of those who healed after 12 months had done so after one

month. These final results are largely unchanged from the 54% healing rate of the initial 30 patients reported previously from this study [9]. Pain levels were also satisfactory with 87.7% of all patients experiencing none or mild pain after one month.

The variety of procedures and biological materials available to treat anal fistula have shown unpredictable results (success rates of 16-85%), emphasizing the need for additional clinical data [10]. Too often studies reporting results of new modalities of treatment for fistula in ano have been based on a relatively small number of patients with limited follow up length from a single institution. A randomized control trial showed fistula healing rates of 35.3% (N=51 patients) with fibrin glue and 54.8% (N=42 patients) with adipose-derived adult stem cells plus fibrin glue [11], and systemic reviews found healing rates ranging from 16 - 92% for repairs with the anal fistula plug [5, 10, 12]. In many instances encouraging initial results have not been reproduced in subsequent studies and the variation in published outcome generates significant confusion. The MASERATI100 clinical study was designed to minimize any possible bias and produce reliable results reproducible in everyday clinical settings by recruiting patients in ten centres across Europe. Healing was assessed on clinical grounds using the absence of symptoms and the presence of a healed external opening as a surrogate of healing. MRI was not used to measure healing because this was not carried out routinely for this purpose in participating centres, would have added to the cost of the study. Furthermore there is no evidence as to what a healed fistula tract following collagen paste injection would look like on MRI. Prior to surgery, MRI was used to assess the anatomy and initial complexity of the fistula and to assure that patients met the inclusion criteria.

The MASERATI100 study highlights several novel, previously unknown factors associated with successful healing with Permacol™ paste. Patients with shorter fistula tracts were more likely to heal which is in contrast to the collagen fistula plug where a longer tract has a more favourable outcome, possibly due to a lower displacement risk [13]. Fistula tract anatomy had no impact on healing, with similar rates for intersphincteric and transsphincteric tracts. Perhaps the reduced healing observed in the longer tract is related to the resistance of the extrasphincteric tract to heal. If this is correct then a multi-step approach in patients with a long tract involving excision of the extrasphincteric tract and then the use of the Permacol™ paste at a later stage might improve overall healing rates..

Consistent with the interim data, older patients were more likely to heal, a condition possibly attributable to differences in activity levels between younger and older patients. However, patient physical activity levels after treatment was not assessed in the study.

Those patients who showed no evidence of paste expulsion were also more likely to heal. Treatment failure also occurred even when the implant remained, suggesting other biological factors may come in to play. Undetected sepsis and abscess formation has been previously implicated in treatment failure [14, 15], and indeed, patients treated with Permacol™ paste were more than four times more likely to fail if they had an anal abscess. Other factors that may contribute to successful healing may be patient populations and comorbidities, bowel preparation regimens, variations of implant placement technique, suture materials used, and closure of the primary opening [5, 16, 17].

The actual nature of any implant material used for fistula surgery must impact on healing. Fibrin glue, for example, has a fluid consistency that hinders secure fixation of the glue within the track preventing proper sealing. The collagen fistula plug has a rigid structure which may lead to a poor fit and extrusion as well as interfering with the healing process by leaving unrecognised secondary tracts untreated. Surgisis® biomaterial (Cook Biotech), is non-cross-linked, possibly leading to bacterial enzymatic degradation in complex environments [18]. In contrast, Permacol™ paste is cross-linked and more readily resists enzymatic degradation while facilitating fibroblast and vascular ingrowth [18-20]. It is more pliable than a solid implant, allowing better conformation with the unique shape of fistula tracts and minimizing the risk of extrusion.

As expected, Permacol™ paste injection did not negatively impact faecal continence. In fact CCF-FI scores showed improvement in faecal continence, an observation that may be explained by a reduction of secretion rather than an improvement of sphincter function.

While some adverse events were recorded, most were similar to those commonly observed after fistula treatment, such as anal abscess, new anal fistula, and procedural pain. The number of patients satisfied or very satisfied with the procedure at the last visit was greater than the number of patients healed, thus even patients in whom the treatment was not successful reported satisfaction. These results might reflect the benign nature of the procedure and therefore even a negative outcome is well accepted. A significant proportion of patients in the study had been previously exposed to more invasive treatments and failures, making the Permacol™ paste injection a much more appealing option, possibly contributing to the very high satisfaction rate following this treatment modality.

The results of this final one-year analysis suggest that Permacol<sup>TM</sup> paste is a safe, minimally-invasive, sphincter-preserving treatment for anal fistulas, that promotes a good healing rate and is well perceived by patients. The lack of a comparative arm is an inherent limitation which we recognise. However, the MASERATI100 study provides a useful assessment of the feasibility and safety of this technique and validates the rationale for future comparative studies between Permacol<sup>TM</sup> paste and alternative interventions.

### **Acknowledgements**

The study was sponsored and funded by Medtronic (Mansfield, MA, USA). The authors thank the study coordinators at each institution. They also thank the following individuals for assisting with the study: Dr. Krishna Kannappa and Dr. Vikas Shah (Leicester General Hospital, Leicester, UK); Andrea Braini and Prashanti Narisetty (Ospedale Santa Maria degli Angeli, Pordenone, Italy); Ilaria Ciangola and Ilaria Capuano (University of Rome Tor Vergata, Rome, Italy); Mr. Scott Barclay and Dr. Tim Hoare (Clinical Research Facility, Royal Victoria Infirmary, Newcastle, UK); Dr. Andrea Rusconi, Dr. Ettore Lillo, Dr. Cesare Ottonelli, and Dr. Mariangela Pagani (San Pio X Hospital, Milan, Italy); Lilli Lundby (Aarhus University Hospital, Aarhus, Denmark); Dr. Michele Droz (King's College Hospital, London, UK); and Miss Zorica Vujovic, Senior Surgical Fellow (Ninewells Hospital & Medical School, Scotland, UK). Medtronic provided medical writing (Emily Putiri, PhD), statistical (Sylvain Anselme), and editorial (Patrice Becker) support.



## References

1. Giamundo P, Geraci M, Tibaldi L, Valente M. (2014), Closure of fistula-in-ano with laser--FiLaC: an effective novel sphincter-saving procedure for complex disease. *Colorectal Dis*, 16: 110-5.
2. Haim N, Neufeld D, Ziv Y, Tulchinsky H, Koller M, Khaikin M, et al. (2011), Long-term results of fibrin glue treatment for cryptogenic perianal fistulas: a multicenter study. *Dis Colon Rectum*, 54: 1279-83.
3. Mishra A, Shah S, Nar AS, Bawa A. (2013), The role of fibrin glue in the treatment of high and low fistulas in ano. *J Clin Diagn Res*, 7: 876-9.
4. Sileri P, Giarratano G, Franceschilli L, Limura E, Perrone F, Stazi A, et al. (2013), Ligation of the Intersphincteric Fistula Tract (LIFT): A Minimally Invasive Procedure for Complex Anal Fistula: Two-Year Results of a Prospective Multicentric Study. *Surg Innov*.
5. Garg P, Song J, Bhatia A, Kalia H, Menon GR. (2010), The Efficacy of Anal Fistula Plug in Fistula-In-Ano: A Systematic Review. *Colorectal Dis*, 12: 965-70.
6. Tan KK, Kaur G, Byrne CM, Young CJ, Wright C, Solomon MJ. (2013), Long-term outcome of the anal fistula plug for anal fistula of cryptoglandular origin. *Colorectal Dis*, 15: 1510-4.
7. Guadalajara H, Herreros D, De-La-Quintana P, Trebol J, Garcia-Arranz M, Garcia-Olmo D. (2012), Long-term follow-up of patients undergoing adipose-derived adult stem cell administration to treat complex perianal fistulas. *Int J Colorectal Dis*, 27: 595-600.
8. Ommer A, Herold A, Berg E, Furst A, Sailer M, Schiedeck T, et al. (2011), Cryptoglandular anal fistulas. *Dtsch Arztebl Int*, 108: 707-13.
9. Giordano P, Sileri P, Buntzen S, Stuto A, Nunoo-Mensah J, Lenisa L, et al. (2015), A prospective, multicentre observational study of Permacol collagen paste for anorectal fistula: preliminary results. *Colorectal Dis*.
10. Lewis R, Lunniss PJ, Hammond TM. (2012), Novel biological strategies in the management of anal fistula. *Colorectal Dis*, 14: 1445-55.
11. Herreros MD, Garcia-Arranz M, Guadalajara H, De-La-Quintana P, Garcia-Olmo D, Group FC. (2012), Autologous expanded adipose-derived stem cells for the treatment of complex cryptoglandular perianal fistulas: a phase III randomized clinical trial (FATT 1: fistula Advanced Therapy Trial 1) and long-term evaluation. *Dis Colon Rectum*, 55: 762-72.
12. Nasserri Y, Cassella L, Berns M, Zaghiyan K, Cohen J. (2016), The anal fistula plug in Crohn's disease patients with fistula-in-ano: a systematic review. *Colorectal Dis*, 18: 351-6.
13. Lenisa L, Espin-Basany E, Rusconi A, Mascheroni L, Escoll-Rufino J, Lozoya-Trujillo R, et al. (2010), Anal fistula plug is a valid alternative option for the treatment of complex anal fistula in the long term. *Int J Colorectal Dis*, 25: 1487-93.
14. Lindsey I, Smilgin-Humphreys MM, Cunningham C, Mortensen NJ, George BD. (2002), A randomized, controlled trial of fibrin glue vs. conventional treatment for anal fistula. *Dis Colon Rectum*, 45: 1608-15.
15. Buchanan GN, Bartram CI, Phillips RK, Gould SW, Halligan S, Rockall TA, et al. (2003), Efficacy of fibrin sealant in the management of complex anal fistula: a prospective trial. *Dis Colon Rectum*, 46: 1167-74.
16. van Koperen PJ, Bemelman WA, Gerhards MF, Janssen LW, van Tets WF, van Dalsen AD, et al. (2011), The anal fistula plug treatment compared with the mucosal advancement flap for cryptoglandular high transsphincteric perianal fistula: a double-blinded multicenter randomized trial. *Dis Colon Rectum*, 54: 387-93.
17. Ortiz H, Marzo J, Ciga MA, Oteiza F, Armendariz P, de Miguel M. (2009), Randomized clinical trial of anal fistula plug versus endorectal advancement flap for the treatment of high cryptoglandular fistula in ano. *Br J Surg*, 96: 608-12.

18. Hammond TM, Porrett TR, Scott SM, Williams NS, Lunniss PJ. (2011), Management of idiopathic anal fistula using cross-linked collagen: a prospective phase 1 study. *Colorectal Dis*, 13: 94-104.
19. Himpson RC, Cohen CR, Sibbons P, Phillips RK. (2009), An experimentally successful new sphincter-conserving treatment for anal fistula. *Dis Colon Rectum*, 52: 602-8.
20. Sileri P, Franceschilli L, Del Vecchio Blanco G, Stolfi VM, Angelucci GP, Gaspari AL. (2011), Porcine dermal collagen matrix injection may enhance flap repair surgery for complex anal fistula. *Int J Colorectal Dis*, 26: 345-9.

**Table 1. Patient demographics, fistula characteristics, and operative details**

Parameter	Permacol paste (N=100)
Age	47.5 (20.0 – 78.0)
Gender	100
Female	30
Male	70
BMI (kg/m <sup>2</sup> ) [1]	26.3 (16.4 – 46.2)
Diabetes	2
Smoking	26
Steroids/Immunodepressants	4
ASA score	1.0 (1 – 3)
Recurrent fistula	39
Fistula type per Parks' Classification	100
Intersphincteric	27
Transsphincteric	73
Extent of External Sphincter Involvement	73
Greater than or Equal to 1/3	26 (35.6%)
Less than 1/3	47 (64.4%)
Level of Internal Opening	99
Above Dentate Line	11
At Dentate Line	66
Below Dentate Line	22
Length of Fistula Tract, cm	2.5 (0.5 – 6.5)
Prior treatment of fistula with draining/loose seton	86
Time between placement and removal of seton, days	99 (14 – 1437)
Granulation tissue removed	93 (93%)
Units of paste required per patient	100
1 Unit	96 (96%)
2 Units	4 (4%)
Duration of operation (minutes)	21 (10 – 55)

Data are expressed as n, n (%), or median (range).

[1] BMI = Weight/(Height/100)<sup>2</sup>

**Table 2. Rate of fistula healing by visit**

	Statistic	Permacol™ paste (N=100)			
		1 Month	3 Months	6 Months	12 Months
Clinical assessment performed					
Yes	n	99	89	81	75
Missing	n	1	6	3	1
Exited from study	n	0	5	16	24
Clinically healed fistula [1]	n/N (%)	47/99 (47.5)	50/94 (53.2)	55/97 (56.7)	53/99 (53.5)
	95% CI	37.3% – 57.8%	42.6% – 63.6%	46.3% – 66.7%	43.2% – 63.6%

[1] Data includes subjects whose assessment was performed and the final assessment of subjects who exited early from the study.

**Table 3. Sub-classification of fistula healing within 12 months**

	Paste extrusion/leakage		
Fistula healing	No	Yes	P-value [1]
Within 12 months	N=72	N=27	
Yes	46 (63.9%)	7 (25.9%)	<.001
	Fistula tract length		
Fistula healing	≤4 cm	>4 cm	P-value [1]
Within 12 months	N=84	N=15	
Yes	51 (60.7%)	2 (13.3%)	<.001
	Fistula Parks classification		
Fistula healing	Intersphincteric	Transsphincteric	P-value [1]
Within 12 months	N=27	N=72	
Yes	19 (70.4%)	34 (47.2%)	0.040

Data shown as N, n (%), or p-value

[1] P-value is from chi-square test (or fisher exact test)

**Table 4. Relationship between patient/fistula characteristics and healing rate**

<b>Variable</b>	<b><i>p</i>-value [1]</b>	<b>Hazard Ratio (95% CI)</b>
Evidence of expulsion/leakage within the follow-up (ref = No)	0.002*	3.133 (1.568-6.836)
Fistula is a previously recurrent fistula (ref = No)	0.406	1.219 [0.769-1.963]
Fistula Type per Parks' Classification (ref = Transsphincteric)	0.990	1.004 (0.534-1.943)
Diabetes (ref = No)	0.414	1.930 (0.478-13.077)
Smoker (ref = No)	0.644	0.859 (0.454-1.661)
Gender (ref = Male)	0.398	1.322 (0.703-2.584)
Occurrence of AE = Anal Abscess (ref = No)	0.050	4.240 (1.257-26.460)
Length of Fistula Tract, cm	0.030*	0.742 (0.558-0.959)
Age, yrs	0.004*	1.034 (1.011-1.059)
BMI, kg/m <sup>2</sup>	0.176	0.961 (0.904-1.016)
Time between placement and removal of seton	0.040*	0.999 (0.998-1.000)

[1] P-value is from a multivariate Cox regression model (Full Analysis Set).

\* P < 0.05

**Table 5. Device and procedure related AE and serious adverse events (SAEs)**

Variable	Permacol <sup>TM</sup> paste (N=48 AEs)
Device and procedure related AE [1]	
Anal abscess	4 (8.3%)
Anal fissure	1 (2.1%)
Anal fistula (new)	2 (4.2%)
Anal fistula infection, wound infection at the external fistula opening, or anal infection	9 (18.8%)
Complex regional pain syndrome	1 (2.1%)
Eczema	1 (2.1%)
Haemorrhage	1 (2.1%)
Hypertrophic scar	1 (2.1%)
Procedural pain	3 (6.3%)
Proctalgia	7 (14.6%)
Tachycardia	1 (2.1%)
Serious AE [1]	6 (12.5%)
Anal fistula	1 (1.0%)
Anal abscess	2 (2.0%)
Procedural pain	1 (1.0%)
Complex regional pain syndrome	1 (1.0%)
Pregnancy (Considered as SAE due to regulation)	1 (1.0%)
Patients with at least 1 AE [2]	29 (29.0%)
Patients with at least 1 SAE [2]	4 (4.0%)
Patients with at least 1 device-related AE [2]	16 (16.0%)
Patients with at least 1 procedure-related AE [2]	16 (16.0%)

Data are expressed as n (%).

[1] Percentages are based on the number of AEs in each category, N=48 AEs.

[2] Percentages are based on the number of patients in the full analysis set.

Accepted Article

Figure 1. Treatment of an anal fistula with Permacol™ paste. Illustration of fistula morphology and the site of application of the paste. After debridement and cleaning of the fistula tract, the flexible cannula sheath is inserted into the external opening. The paste is applied to fill the fistula tract completely and both the internal and external openings are sutured.

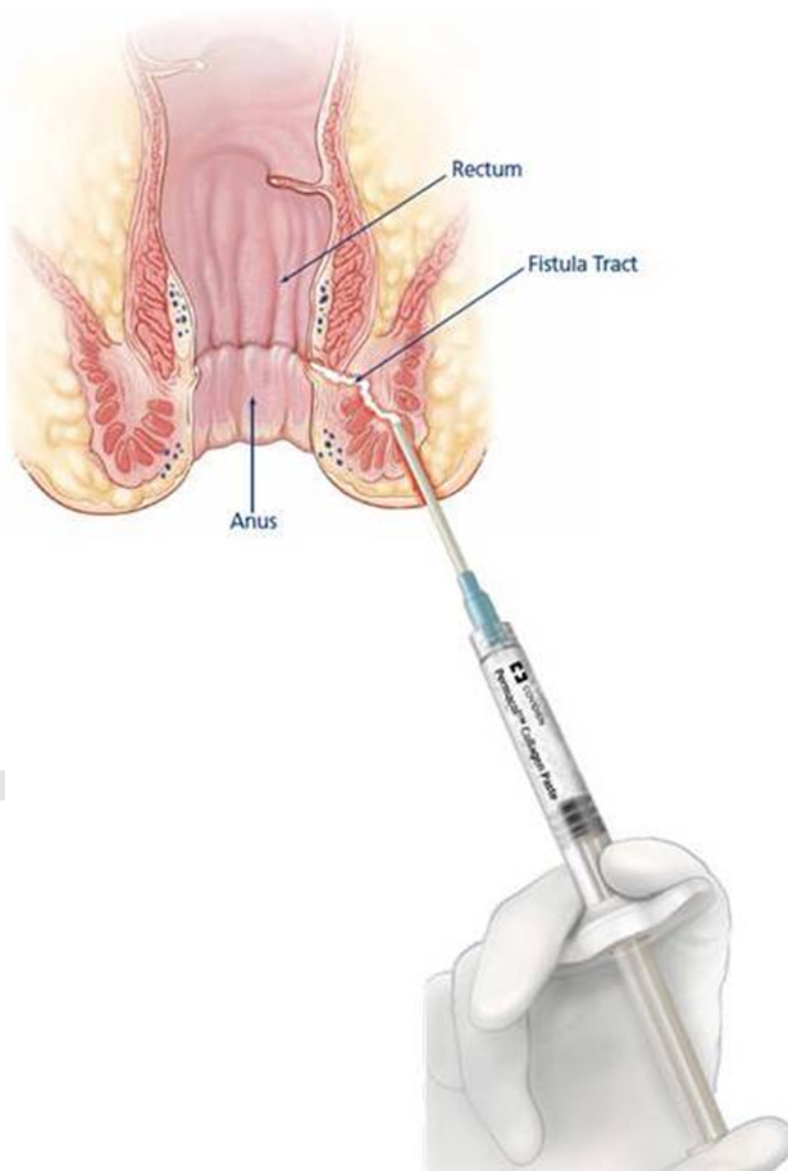


Figure 2. Subject Flow. Shown is the number of subjects who were assessed at each post-operative follow-up visit, excluding subjects who exited from the study before that follow-up visit.

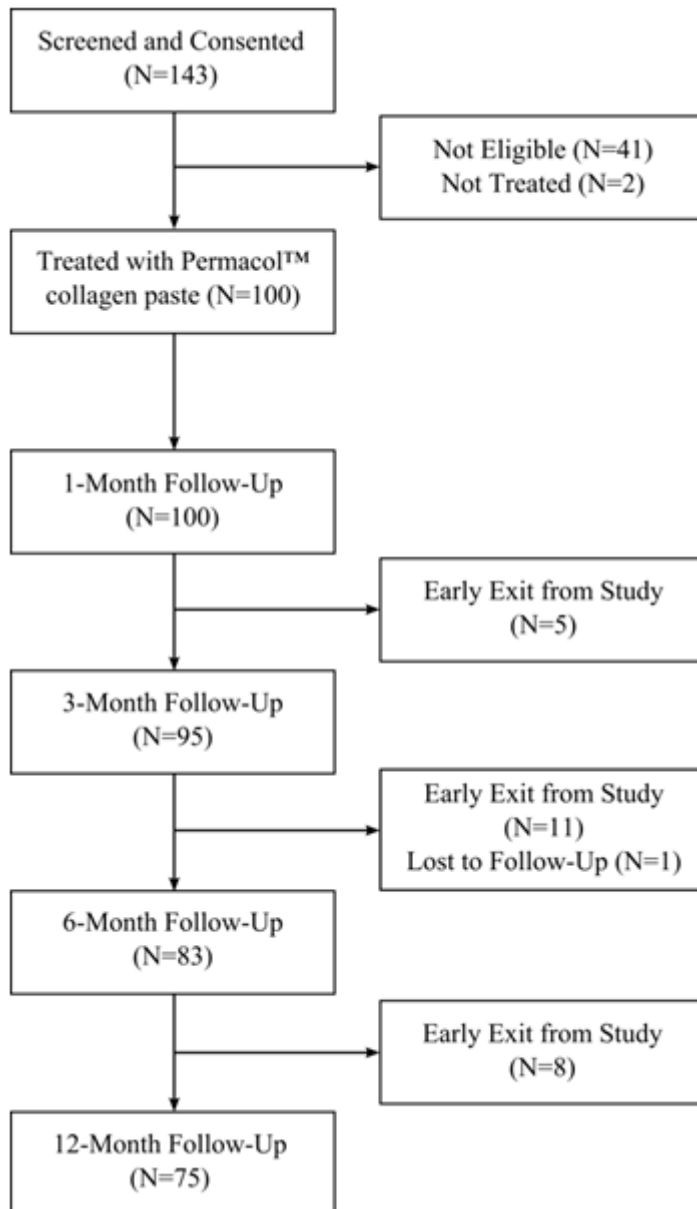




Figure 3. Patient Pain, Faecal Continence, and Quality of life. (A) Pain levels were assessed on a VAS scale at the baseline visit (prior to the surgical procedure) and at each follow-up visit. Mean pain was significantly reduced ( $*P < 0.001$ ) relative to baseline at all follow-up visits ( $P$ -values are from sign tests (3 Month – 12 Month) or Wilcoxon signed rank tests (1 Month – 6 month). (B) Faecal continence was assessed at baseline, 3, 6, and 12 months, and at all patients' last visit reached. The CCF-FI score was a combined assessment of the five types of incontinence; 0= Perfect; 20= Complete Incontinence. If a patient's CCFI-FI assessment was incomplete then the CCF-FI score was not calculated for that visit. Mean CCF-FI faecal continence scores were significantly reduced from baseline at 3, 6, and 12 months ( $*P < 0.05$  based on Wilcoxon signed rank tests (at 6 and 12 months) and sign test (3 months). (C) The EQ-5D Quality of Life questionnaire assessed the percentage of subjects experiencing slight, moderate, severe, or extreme problems with particular factors that affect overall quality of life. N = 97, 88, 79, and 74 subjects who completed the questionnaire at baseline and 3, 6, and 12 months post-operatively, respectively.  $*P < 0.05$ ;  $**P < 0.005$ , based on McNemar's test for rates comparison between Month X and Baseline.

