

Accuracy of Sentinel Lymph Node Mapping After Previous Hysterectomy in Patients with Occult Cervical Cancer

Andrea Papadia, MD, PhD¹, Sara Imboden, MD¹, Anja Fink, MD¹, Maria Luisa Gasparri, MD^{1,2}, Daniele Bolla, MD¹, and Michael D. Mueller, MD¹

¹Department of Obstetrics and Gynecology, University Hospital of Berne and University of Berne, Berne, Switzerland;

²Department of Gynecology and Obstetrics, “Sapienza” University of Rome, Rome, Italy

ABSTRACT

Background. In patients with a diagnosis of occult cervical cancer made on a hysterectomy specimen after surgery for a benign indication, lymph node assessment is crucial to determine treatment. We aimed to compare sentinel lymph node (SLN) mapping between patients with postoperative diagnosis of occult cervical carcinoma and patients with cervical cancer and uterus in situ.

Methods. A retrospective analysis of cervical cancer patients International Federation of Gynecology and Obstetrics (FIGO) stage IA–IIA disease undergoing laparoscopic SLN mapping was performed. Patients were divided into two groups: those with a diagnosis of occult cervical cancer made on a hysterectomy specimen (group 1) and those with a diagnosis of cervical cancer and uterus in situ (group 2). Tracers used for SLN mapping included technetium-99m (^{99m}Tc), blue dye, and indocyanine green. After detection and excision, the SLN was sent for frozen section analysis, and the planned surgical procedure was aborted in case of metastatic disease in favor of a chemoradiotherapeutic treatment.

Results. Groups 1 and 2 included 9 and 62 patients, respectively. Clinicopathologic characteristics were similar among the two groups. Overall and bilateral detection rates were 66.6 and 33.3 and 95.1 and 87 % in groups 1 and 2, respectively ($p < 0.05$). No false-negative SLNs were identified in either group, with a negative predictive value of 100 %.

Conclusions. SLN mapping in occult cervical cancer patients has lower detection rates compared to patients with

uterus in situ. In these patients, proper management of their disease has already failed before diagnosis, and additional mistakes may definitely compromise attempts at cure.

The diagnosis of occult cervical cancer made on a simple hysterectomy specimen after surgery for a benign indication is an unpleasant yet not uncommon finding. This clinical scenario leads to a decision management dilemma. Some authors recommend that a radical parametrectomy with systematic pelvic lymphadenectomy always be performed.^{1,2} On the other hand, several retrospective studies have identified a group of cervical cancer patients with lesions smaller than 2 cm in diameter, without lymphovascular space involvement and with negative lymph nodes, who are virtually at no risk of parametrial involvement.^{3–5} Consequently, some authors recommend avoiding a parametrectomy in these patients; a prospective trial is currently randomizing patients with early stage cervical cancer with these characteristics to a simple versus a radical hysterectomy, both in conjunction with pelvic lymphadenectomy.^{6–8} For patients with pathologic intermediate risk factors (a combination of tumor size, depth of stromal invasion, and lymphovascular space involvement) or high-risk factors (cut through, or parametrial or lymph node involvement), radiotherapy and chemoradiotherapy are indicated.^{9–11}

In either case, a lymph node assessment is indicated to determine pathologic risk factors that can determine need for adjuvant treatment. This is best performed laparoscopically to reduce surgical morbidity.^{12,13} There is increasing evidence suggesting that sentinel lymph node (SLN) biopsy may be safely integrated into the management of early stage cervical cancer.^{14–16} There is much experience with the use of blue dye and technetium-99m (^{99m}Tc) as mapping techniques for SLN biopsy in cervical

cancer, with an overall sensitivity and SLN detection rate of over 90%.¹⁷ More recently, indocyanine green (ICG) has shown promising results in gynecologic oncology.^{18–22} After submucosal injection, tracers used for SLN mapping are taken into the lymph ducts, through which they travel to the SLN, which can then be identified and sampled.

It has been demonstrated that a history of cervical conization does not influence detection rates, predictive value, or the distribution of SLNs.^{23,24} To our knowledge, SLN mapping for cervical cancer accidentally diagnosed on a hysterectomy specimen has not yet been reported. Several questions concerning this technique remain open: Is the vaginal apex a valid surrogate of the cervix for tracer injection? Have the surgical scars and inflammation process altered the anatomic structures and disrupted the lymphatic vessels to a point where the SLN mapping is no longer reliable?

The aim of this study was to compare overall and bilateral detection rates, false-negative rates, and localization of SLNs in patients undergoing SLN mapping after postoperative diagnosis of occult cervical carcinoma with cervical cancer patients undergoing SLN mapping with uterus in situ.

METHODS

A retrospective analysis of all cervical cancer patients with International Federation of Gynecology and Obstetrics (FIGO) stage IA–IIA disease undergoing laparoscopic SLN mapping at the University Hospital, Bern, between April 2008 and July 2015 was performed. Demographic, clinical, and pathologic data were retrieved from an electronic database. Missing data were integrated by surgical reports and clinical charts. Since January 2011, the data for all patients receiving ICG SLN mapping were prospectively collected. The study was approved by the institutional review board. All patients signed informed consent. Cervical cancer patients were then divided into two groups: those with occult cervical cancer diagnosed on a hysterectomy specimen and undergoing laparoscopic SLN biopsy with or without radical parametrectomy and systematic pelvic lymphadenectomy (group 1), and those with a preoperative diagnosis of cervical cancer on punch biopsy or conization and undergoing laparoscopic SLN mapping with or without radical hysterectomy and systematic pelvic with or without para-aortic lymphadenectomy (group 2).

Pretreatment evaluation consisted of collection of medical history, physical examination, examination under anesthesia, and positron emission tomography/computed tomography scan. Magnetic resonance imaging of the pelvis was performed to rule out parametrial invasion if the

clinical stage was unclear. From April 2008 until January 2011, SLN mapping was performed with a preoperative ^{99m}Tc injection and lymphoscintigram with fusion computer tomogram (single-photon emission computed tomography, SPECT) with or without intraoperative patent blue dye injection. From January 2011 until July 2015, SLN mapping was performed with intraoperative ICG injection. No other significant changes in patients' management occurred throughout the study period. For patients undergoing ^{99m}Tc SLN mapping, 120 MBq of ^{99m}Tc was injected into the quadrants of the cervix or in the anterior and posterior wall of the vaginal stump on the day before surgery. SPECT was performed to preoperatively locate the SLNs. On the day of surgery, in the operating room, the patient was injected in the cervix or in the vaginal stump with 5 ml of patent blue dye in the quadrants. Under gamma probe (Navigator; Autosuture) guidance and patent blue dye visual guidance, the SLNs were laparoscopically located and removed. For patients undergoing ICG SLN mapping, 8 ml of ICG (Pulsion) was injected in the operating room immediately before laparoscopy. ICG was injected in the quadrants of the cervix or in the anterior and posterior wall of the vaginal stump. Two vials of ICG (Pulsion) had been previously suspended with 10 ml of sterile water. Under the visual guidance of fluorescent light, and using a laparoscopic near-infrared fluorescent optic device (Storz), the SLN was located and removed (Fig. 1).

Excised SLNs were sent for frozen section analysis. In cases of negativity for metastatic disease, the planned surgical procedure was completed, including a full pelvic lymphadenectomy. The radical procedure was aborted in favor of concurrent chemoradiotherapy. In these cases, a para-aortic laparoscopic lymphadenectomy was performed in order to plan the extension of the radiation field. At final histopathologic analysis, a complete ultrastaging with immunohistochemistry was performed.

Demographic and clinicopathologic characteristics were evaluated using basic descriptive statistics. Overall and bilateral detection rates, false-negative rates, and negative predictive value of SLN mapping in the two groups were calculated and compared by Fisher's exact test. The false-positive rate was defined as 0. The overall detection rate was calculated by the number of procedures in which at least one SLN was identified divided by the total number of procedures performed; the bilateral detection rate was calculated by the number of procedures in which at least one SLN was identified on each side of the pelvis divided by the total number of procedures performed. A truly positive SLN was defined as a positive SLN identified by histopathologic techniques independent of regional lymph node status. A false-negative SLN was defined as a negative SLN in combination with metastatic non-SLNs

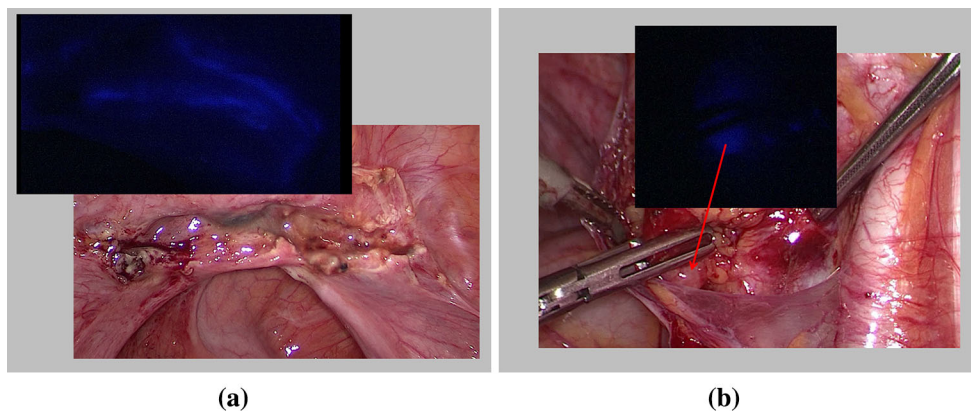


FIG. 1 **a** Laparoscopic view of **a** the vaginal stump in a patient who was diagnosed with occult cervical cancer after a simple hysterectomy was performed for a benign indication. Under visual guidance, using a laparoscopic near-infrared optic device (Storz), the fluorescent

light can be followed until the SLN is identified. **b** Under visual guidance, the SLN is identified on the right, medial to the external iliac vessels

(NSLN). Additionally, localization of SLNs among the two groups were compared by the Chi square test. Statistical analyses were performed by R software 3.1.0. All p values were two sided, and p values of <0.05 were considered statistically significant.

RESULTS

In the study period, 71 patients diagnosed with cervical cancer undergoing SLN mapping were identified. Of these, 9 patients were diagnosed with an occult cervical cancer after having undergone a simple hysterectomy and were referred to us for oncologic management (group 1). An abdominal, vaginal, or laparoscopic hysterectomy had been performed in 2, 3, and 4 patients, respectively. In every case, the hysterectomy was simple and did not include any parametrial resection. Median interval of time between the two surgeries was 45 days (range 10–80 days). The remaining 62 patients were diagnosed with cervical cancer on punch biopsy or cervical conization (group 2).

Clinicopathologic characteristics did not differ significantly among the two groups with regard to median age, body mass index, and tumor diameter. Patients with occult cervical carcinoma had an unusual histology and well-differentiated tumors significantly more often than the patients in group 2. The FIGO stage in patients in group 2 was IA, IB1, IB2, IIA1, and IIA2 in 6, 31, 13, 5, and 7 patients, respectively. Clinicopathologic characteristics are summarized in Table 1.

SLN mapping was performed with ^{99m}Tc , ^{99m}Tc and blue dye, and ICG in 22.2, 44.4, and 33.3 % and 3.2, 38.7, and 58.1 % of patients in groups 1 and 2, respectively. SLN mapping with ICG or a combination of ^{99m}Tc and blue dye was performed significantly more often in patients in group 2.

A mean of 1 (range 0–4) and 3 (range 0–15) SLNs were identified in groups 1 and 2, respectively. SLNs were located along the external iliac basins, the obturator fossa, and the common iliac basins in 33.3, 50, and 8.3 % and in 17, 58, and 19 % of the cases in groups 1 and 2, respectively (Fig. 2). No, overall and bilateral detection rates were 33.3, 66.6, and 33.3 % and 4.9, 95.1, and 87 % in groups 1 and 2, respectively. Overall and bilateral detection rates were significantly higher among patients in group 2 $p = 0.02$; $p = 0.0001$). No false-negative SLNs were seen in either group, with a negative predictive value of 100 %. No positive SLNs were identified in group 1, and one NSLN was positive in a patient in whom SLN mapping failed to detect any SLNs. Median number of NSLNs was 33 (range 24–46) and 34 (range 0–80) for group 1 and 2 respectively. Data on SLNs results are summarized in Table 2.

DISCUSSION

Because lymph node spread represents the most important prognostic factor in early stage cervical cancer, a systematic pelvic lymphadenectomy has been part of the surgical treatment for the last 70 years.²⁵ For 10 years, SLN biopsy in cervical cancer has consistently recorded good oncologic outcomes, and it is likely that in the near future, it will be routinely applied in early stage tumors.⁵ The incidence of occult invasive cervical cancer is not well established; however, Park et al. reported that 5.3 % of patients with cervical cancer managed at their referral center were diagnosed from a hysterectomy specimen after the uterus was removed for another benign indication.²⁶ In our series, occult cervical cancer patients accounted for 12.7 % of the entire cohort of cervical cancer patients. Both series show that although uncommon, the problem is relevant, and physicians working in referral centers will

TABLE 1 Patient characteristics

Characteristic	Group 1 (<i>n</i> = 9)	Group 2 (<i>n</i> = 62)	<i>p</i>
Age (year) median (range)	44.5 (37–78)	44 (25–72)	0.761
BMI (kg/m ²), median (range)	24.7 (19.6–39.3)	24.1 (17.4–41.5)	0.278
FIGO stage <i>n</i> (%)	NA		
IA		6 (9.7)	
IB1		31 (50)	
IB2		13 (20.1)	
IIA1		5 (8.1)	
IIA2		7 (11.3)	
Tumor diameter (mm), mean (range)	20 (3–60)	30 (2–80)	0.285
Histology <i>n</i> (%)			
Squamous cell carcinoma	4 (44.4)	43 (69.4)	0.003
Adenocarcinoma	3 (33.3)	17 (27.4)	
Clear cell carcinoma	1 (11.1)	0	
Carcinosarcoma	1 (11.1)	0	
Neuroendocrine tumor, <i>n</i> (%)	0	2 (3.2)	
Time to second surgery in days, median (range)	47 (10–80)	NA	
Grade, <i>n</i> (%)			0.001
NA	1 (11.1)	4 (6.4)	
1	2 (22.2)	0	
2	2 (22.2)	37 (59.7)	
3	4 (44.4)	21 (33.9)	

BMI body mass index, FIGO International Federation of Gynecology and Obstetrics, NA not available

FIG. 2 The SLNs were located along the external iliac basins, the obturator fossa, and the common iliac basins in 33.3, 50, and 8.3 % and in 17, 58, and 19 % of the cases in group 1 and 2 respectively

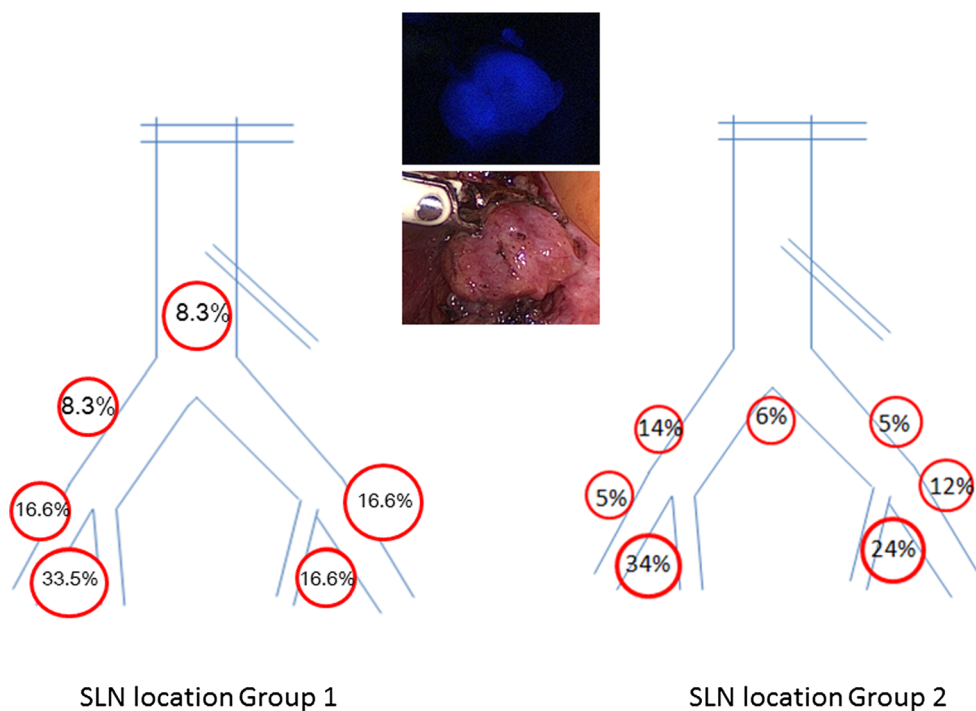


TABLE 2 SLN mapping data

Characteristic	Group 1 (n = 9)	Group 2 (n = 62)	p
Tracer used for SLN mapping, n (%)			0.007
^{99m} Tc	2 (22.2)	2 (3.2)	
^{99m} Tc + blue dye	4 (44.4)	24 (38.7)	
ICG	3 (33.3)	36 (58.1)	
Detection rate n (%)			0.0005
Overall detection	6 (66.6)	59 (95.1)	0.02
Unilateral detection	3 (33.3)	5 (8.1) ^a	0.05
Bilateral detection	3 (33.3)	54 (87.0)	0.0001
No detection	3 (33.3)	3 (4.9)	0.02
Number positive SLNs	0	14	
Number positive NSLNs	1	13	
False-negative rate	0	0	
NPV	100	100	
Number SLNs, median (range)	1 (0–4)	3 (0–15)	0.015
Number NSLNs, median (range)	33 (24–46)	34.5 (0–80)	0.03
Location of SLNs, %			NS
Obturator fossa	33.3	58	0.76
External iliac artery	50	17	0.23
Common iliac artery	8.3	19	0.7
Para-aortic region	8.3	6	0.54

SLN sentinel lymph node, ^{99m}Tc technetium-99m, ICG indocyanine green, NSLN non-sentinel lymph node, NPV negative predictive value

^a In 1 patient, SLN identification was unilateral due to positivity of SLN; the opposite side was not evaluated

have to manage this kind of patient. In these patients, lymph node status represents the most important prognostic factor driving oncologic decision making.

In our experience, SLN mapping seems to be feasible in the setting of laparoscopic parametrectomy performed after a simple hysterectomy, with an overall detection rate of 66%. In the absence of the uterus and the cervix, the vaginal vault represents the best tracer injection site for SLN mapping, as upper vagina and cervix drain through the same lymphatic routes via supraureteral, infraureteral, and neural pathway to the parametria and to the pelvic and para-aortic lymph nodes.^{27,28}

In our series, both overall and bilateral detection rates in the setting of occult cervical cancer status after simple hysterectomy were significantly lower compared to those recorded in patients who were injected in the cervix. This is most likely related to postoperative scarring and inflammation, which may clog or seal lymphatic vessels draining the area. However, the degree to which these postsurgical rearrangements affect SLN mapping is unclear and is likely influenced by the technique used as well as by postoperative events such as vaginal vault abscesses and dehiscences. In our series, 2 patients did not map. One of these patients presented with NSLN metastases, which has been reported to be a variable negatively influencing the

identification of SLN due to occlusion of lymphatic drainage.

In cutaneous melanoma, it is not unusual that a patient is referred to a tertiary care center for management after a wide local excision of the primary lesion has been performed. In these cases, SLN mapping is feasible and does not seem to be affected by the previous surgery unless an extensive reconstruction of the primary excision site has been performed.^{29–31} More recently, SLN mapping after a previous excision of the primary vulvar cancer has been shown to be feasible and accurate.³² In the literature, at least two studies have reported on cervical cancer SLN mapping after cervical conization.^{23,24} In these series, a previous conization did not seem to affect the outcome of SLN mapping. However, compared to a conization or a wide local excision, a simple hysterectomy not only removes the organ that is usually injected with the tracer but is also responsible for a greater disruption of the pelvic anatomy.

The tracers used influence the detection rates in SLN mapping, among other factors. Compared to ^{99m}Tc, the combination of ^{99m}Tc and blue dye has been associated with higher detection rates. More recently, we were able to show that the use of ICG improves bilateral detection rates of SLN mapping in cervical cancer patients compared to

^{99m}Tc and blue dye combined.³³ Although in our study patients in group 1 were significantly more often mapped with ^{99m}Tc alone and significantly less with ICG compared to group 2, we believe that postsurgical anatomic distortion rather than these differences resulted in the reduced detection rates. However, it can be speculated that performing ICG SLN mapping may increase detection rates in this scenario as well.

The location of the SLNs is consistent with those reported in larger cervical cancer series and is mainly along the external or internal iliac nodal basins.³⁴ In a few cases, SLNs are localized along the common iliac vessels or at the aortic bifurcation. No unusual or aberrant SLN locations were recorded, further confirming that tracer injection in the vaginal vault is a valid surrogate for the cervix in this setting; despite postoperative scarring, the lymphatic drainage of the vaginal cuff is sufficient to allow for a SLN identification in a large number of patients. In our series, the negative predictive value of SLN mapping was 100 % in both groups. In other words, if a SLN was identified and was negative for metastases at final pathologic analysis, all other lymph nodes were also negative.

Limitations of the study include the small number of patients with occult cervical cancer and the variety of tracers used. Occult cervical cancer is a relatively uncommon finding, and the long interval of time during which these patients were treated explains the differences in the tracers used. Strengths of the study include a comparison with a large number of SLN mapping in cervical cancer patients and the large median number of lymph nodes removed, providing sensitivity for the SLN mapping.

Although feasible and accurate, SLN mapping in occult cervical cancer patients has lower overall and bilateral detection rates compared to patients undergoing SLN mapping with their uterus in situ. Patients with occult cervical cancer diagnosed on a simple hysterectomy specimen represent a cohort of patients in whom a proper management of their disease has already failed before diagnosis, and in whom every additional mistake may compromise the curative intent of treatment. We believe that in this subset of patients, SLN mapping should be used cautiously in clinical practice. When adopted, it should be used in conjunction with a SLN mapping protocol that recommends the excision of any suspicious lymph nodes and the performance of a full lymphadenectomy in non-mapping hemipelvises.³⁵

DISCLOSURE The authors declare no conflict of interest.

REFERENCES

- Narducci F, Merlot B, Bresson L, et al. Occult invasive cervical cancer found after inadvertent simple hysterectomy: is the ideal management: systematic parametrectomy with or without radiotherapy or radiotherapy only? *Ann Surg Oncol*. 2015;22:1349–52.
- Jiang H, Qu L, Liu X et al. A comparison of laparoscopic and abdominal radical parametrectomy for cervical cancer or vaginal apex carcinoma and stage II endometrial cancer after hysterectomy. *JSLs*. 2013;17:249–62.
- Covens A, Rosen B, Murphy J, et al. How important is removal of the parametrium at surgery for carcinoma of the cervix? *Gynecol Oncol*. 2002;84:145–9.
- Pluta M, Rob L, Charvat M, et al. Less radical surgery than radical hysterectomy in early stage cervical cancer: a pilot study. *Gynecol Oncol*. 2009;113:181–4.
- Frumovitz M, Sun CC, Schmeler KM, et al. Parametrial involvement in radical hysterectomy specimens for women with early-stage cervical cancer. *Obstet Gynecol*. 2009;114:93–9.
- Jeon HW, Suh DH, Kim K, No JH, Kim YB. Lymphadenectomy alone is a feasible option in managing incidentally-detected early stage cervical cancer after simple hysterectomy without intermediate-risk factors: an application of the concept of less radical surgery. *Anticancer Res*. 2013;33:5135–41.
- Gemer O, Eitan R, Gdalevich M, et al. Can parametrectomy be avoided in cervical cancer? An algorithm for the identification of patients at low risk of patients for parametrial involvement. *Eur J Surg Oncol*. 2013;39:76–80.
- Schmeler KM, Frumovitz M, Ramirez PT. Conservative management of early stage cervical cancer: is there a role for less radical surgery? *Gynecol Oncol*. 2011;120:321–5.
- Sedlis A, Bundy BN, Rotman MZ, Lentz SS, Mudderspach LI, Zaino RJ. A randomized trial of pelvic radiation therapy versus no further therapy in selected patients with stage IB carcinoma of the cervix after radical hysterectomy and pelvic lymphadenectomy: a Gynecologic Oncology Group study. *Gynecol Oncol*. 1999;73:177–83.
- Rotman M, Sedlis A, Piedmonte MR, et al. A phase III randomized trial of postoperative pelvic irradiation in stage IB cervical carcinoma with poor prognostic features: follow-up of a Gynecologic Oncology Group study. *Int J Radiat Oncol Biol Phys*. 2006;65:196–76.
- Peters WA, Liu PY, Barret RJ, et al. Concurrent chemotherapy and pelvic radiation therapy compared with pelvic radiation therapy alone as adjuvant therapy after radical surgery in high-risk early-stage cancer of the cervix. *J Clin Oncol*. 2000;18:1606–13.
- Papadia A, Remorgida V, Salom EM, Ragni N. Laparoscopic pelvic and paraaortic lymphadenectomy in gynecologic oncology. *J Am Assoc Gynecol Laparosc*. 2004;11:297–306.
- Bogani G, Cromi A, Serati M, et al. Improving standard of care through introduction of laparoscopy for the surgical management of gynecological malignancies. *Int J Gynecol Cancer*. 2015;25:741–50.
- Lécuru F, Bats AS, Bensaid C, et al. Sentinel lymph node in low stage cervical cancers. Current data. Quality assurance. Prospects. *Bull Cancer*. 2014;101:349–53.
- Darlin L, Persson J, Bossmar T, et al. The sentinel node concept in early cervical cancer performs well in tumors smaller than 2 cm. *Gynecol Oncol*. 2010;117:266–9.
- Rob L, Strnad P, Robova H, et al. Study of lymphatic mapping and sentinel node identification in early stage cervical cancer. *Gynecol Oncol*. 2005;98:281–8.
- Rob L, Robova H, Halaska MJ, Hrudá M, Skapa P. Current status of sentinel lymph node mapping in the management of cervical cancer. *Expert Rev Anticancer Ther*. 2013;13:861–70.
- Alander JT, Kaartinen I, Laakso A, et al. A review of indocyanine green fluorescent imaging in surgery. *Int J Biomed Imaging*. 2012;2012:940585.
- Rossi EC, Ivanova A, Boggess JF. Robotically assisted fluorescence-guided lymph node mapping with ICG for gynecologic

- malignancies: a feasibility study. *Gynecol Oncol.* 2012;124:78–82.
20. Schaafsma BE, van der Vorst JR, Gaarenstroom KN, et al. Randomized comparison of near-infrared fluorescence lymphatic tracers for sentinel lymph node mapping of cervical cancer. *Gynecol Oncol.* 2012;127:126–30.
 21. Jewell EL, Huang JJ, Abu-Rustum NR, et al. Detection of sentinel lymph nodes in minimally invasive surgery using indocyanine green and near-infrared fluorescence imaging for uterine and cervical malignancies. *Gynecol Oncol.* 2014;133:274–7.
 22. Ditto A, Martinelli F, Bogani G, et al. Sentinel node mapping using hysteroscopic injection of indocyanine green and laparoscopic near-infrared fluorescence imaging in endometrial cancer staging. *J Minim Invasive Gynecol.* 2015;22:132–3.
 23. Di Stefano AB, Acquaviva G, Garozzo G, et al. Lymph node mapping and sentinel node detection in patients with cervical carcinoma: a 2-year experience. *Gynecol Oncol.* 2005;99:671–9.
 24. Kato H, Todo Y, Minobe S, et al. Previous conization on patient eligibility of sentinel lymph node detection for early invasive cervical cancer. *Int J Gynaecol Cancer.* 2011;21:1491–4.
 25. Meigs JV. The radical operation for cancer of the cervix. *Am J Roentgenol Radium Ther.* 1947;57:679–84.
 26. Park JY, Kim DY, Kim JH et al. (2010) Management of occult invasive cervical cancer found after simple hysterectomy. *Ann Oncol.* 21:994–1000.
 27. Ercoli A, Delmas V, Iannone V, et al. The lymphatic drainage of the uterine cervix in adult fresh cadavers: anatomy and surgical implications. *Eur J Surg Oncol.* 2010;36:298–303.
 28. Karima AC, Derks M, Smit NN, et al. Lymphatic drainage from the cervix uteri: implications for radical hysterectomy? *Gynecol Oncol.* 2014;132:107–13.
 29. Woelber L, Grimm D, Vettorazzi E, et al. Secondary sentinel node biopsy after previous excision of the primary tumor in squamous cell carcinoma of the vulva. *Ann Surg Oncol.* 2013;20:1701–6.
 30. McCready DR, Ghazarian DM, Hershkop MS, Walker JA, Ambus U, Quirt IC. Sentinel lymph-node biopsy after previous wide local excision for melanoma. *Can J Surg.* 2001;44:432–4.
 31. Gannon CJ, Rousseau DL Jr, Ross MI, et al. Accuracy of lymphatic mapping and sentinel lymph node biopsy after previous wide local excision in patients with primary melanoma. *Cancer.* 2006;107:2647–52.
 32. Ariyan S, Ali-Salaam P, Cheng DW, Truini C. Reliability of lymphatic mapping after wide local excision of cutaneous melanoma. *Ann Surg Oncol.* 2007;14:2377–83.
 33. Imboden S, Papadia A, Nauverk M, et al. A comparison of radiocolloid and indocyanine green fluorescence imaging, sentinel lymph node mapping in patients with cervical cancer undergoing laparoscopic surgery. *Ann Surg Oncol.* 2015;22:4198–203.
 34. Holman LL, Levenback CF, Frumovitz M. Sentinel lymph node evaluation in women with cervical cancer. *J Minim Invasive Gynecol.* 2014;21:540–5.
 35. Diaz JP, Gemignani ML, Pandit-Taskar N, et al. Sentinel lymph node biopsy in the management of early-stage cervical carcinoma. *Gynecol Oncol.* 2011;120:347–52.