



LUND UNIVERSITY

Gastroesophageal Reflux after Vertical Banded Gastroplasty is Alleviated by Conversion to Gastric Bypass.

Ekelund, Mikael; Öberg, Stefan; Peterli, R; Frederiksen, S G; Hedenbro, Jan

Published in:
Obesity Surgery

DOI:
[10.1007/s11695-011-0540-9](https://doi.org/10.1007/s11695-011-0540-9)

2012

[Link to publication](#)

Citation for published version (APA):

Ekelund, M., Öberg, S., Peterli, R., Frederiksen, S. G., & Hedenbro, J. (2012). Gastroesophageal Reflux after Vertical Banded Gastroplasty is Alleviated by Conversion to Gastric Bypass. *Obesity Surgery*, 22(6), 851-854. <https://doi.org/10.1007/s11695-011-0540-9>

Total number of authors:
5

General rights

Unless other specific re-use rights are stated the following general rights apply:
Copyright and moral rights for the publications made accessible in the public portal are retained by the authors and/or other copyright owners and it is a condition of accessing publications that users recognise and abide by the legal requirements associated with these rights.

- Users may download and print one copy of any publication from the public portal for the purpose of private study or research.
- You may not further distribute the material or use it for any profit-making activity or commercial gain
- You may freely distribute the URL identifying the publication in the public portal

Read more about Creative commons licenses: <https://creativecommons.org/licenses/>

Take down policy

If you believe that this document breaches copyright please contact us providing details, and we will remove access to the work immediately and investigate your claim.

LUND UNIVERSITY

PO Box 117
221 00 Lund
+46 46-222 00 00

***Gastroesophageal reflux after Vertical Banded Gastroplasty is
alleviated by conversion to Gastric Bypass***

M Ekelund¹, S Öberg¹, R Peterli³, SG Frederiksen¹, JL Hedenbro^{1,2}

¹Department of Surgery, Clinical sciences, Lund University, and

Skåne University Hospital Lund, Sweden

²Aleris Obesity Skåne, Lund, Sweden

³Dept of Surgery Claraspital, Basel, Switzerland

Corresponding author:

JL Hedenbro
Dept of Surgery, Clinical Sciences
Lund University
SE-221 85 Lund, SWEDEN
jan.hedenbro@med.lu.se

Abstract

Background: Conversion operations after vertical banded gastroplasty (VBG) are sometimes performed because of vomiting and/or acid regurgitation. Primary operation with gastric bypass (GBP) is known to reduce gastroesophageal reflux (GERD). Previous studies have not been designed to differentiate between the effects of the altered anatomy and of the ensuing weight loss. No series has reported data on acid reflux before and after conversion from VBG to GBP.

Patients and methods: We invited eight VBG-patients with current symptoms of GERD. All had intact staple lines as assessed by barium meal and gastroscopy. Acid reflux was quantified using 48h Bravo-capsule measurements. Conversion operations were performed creating an isolated 15-20 ml pouch; the previously banded part of gastric wall was excised.

Gastrojejunostomy was made end-to-end with a 28 mm circular stapler. The study is based on five patients consenting to early postoperative endoscopy and pH measurement.

Results: All patients were women with a mean age of 49.5 years and BMI of 36.3. Time since VBG was 132.1 months. Time from conversion to second measurement was 46.6 days and BMI at that time 32.7. There was no mortality and no serious morbidity. All patients improved clinically and no patient had to go back on proton pump inhibition or antacids. Total time with pH < 4.0 was reduced from 18.4 to 3.3% ($p < 0.05$). DeMeester score was reduced from 58.1 to 15.9 ($p < 0.05$).

Conclusions: The effect of converting VBG-operated patients to GBP results in a near-normalisation of acid reflux parameters, and a discontinuation of proton pump inhibitor medication.

Background

Vertical Banded Gastroplasty (VBG) was once the most widely performed procedure for morbid obesity. Its ease of performance and relative safety made it an attractive choice. With increasing follow-up time it became evident that VBG was not without side effects and shortcomings.

Both insufficient weight loss and long term increase of gastroesophageal reflux have been reported after VBG [1,2]. Even the risk of progression of reflux to Barrett's oesophagus has been described for restrictive operations [3].

The conversion of VBG to gastric bypass is often offered to patients as a remedy not only for improved weight control but also for reflux. This practice is based on indirect evidence indicating that primary gastric bypass (GBP) has a more pronounced effect on gastroesophageal reflux disease (GERD) than does primary VBG [4,5], in addition to its well-known superior effect on body weight. No study has been published directly measuring the early effect on GERD by the conversion from VBG to GBP. The present study was undertaken to test the hypothesis that mechanics and not only weight loss affect patient outcome.

Patients and Methods

In 2009 we converted 32 patients from VBG to GBP. The indication for surgery was staple line dehiscence with poor weight development in 24 cases. Eight patients had symptoms indicative of increased gastroesophageal reflux and were shown to have neither endoscopic nor radiological proof of a disrupted vertical staple line in the preoperative work-up. In order to investigate only patients with intact pouches and without any possible acid contribution from the main stomach these eight patients were offered and accepted participation in the study. They all underwent a preoperative endoscopy and 48h pH measurement. All patients were on proton pump inhibitor therapy up to one week prior to acid measurements and then also prior to surgery. All eight patients were converted to GBP. Five patients accepted to undergo also a postoperative endoscopy and 48h pH measurement. All data are from those five only. There were no differences in terms of BMI, severity of symptoms or acid reflux data between patients participating in the study and those abstaining (not shown in table). Mean time from the initial VBG to conversion was 132.1 months, and time from revisional surgery to follow-up recording was 46.6 days. Mean body weight at inclusion was 99.7 kg which had been reduced to 90.0 kg at follow-up examination; corresponding BMI reduction was from 36.3 to 32.7 kg/m². These data are shown in figure 1.

Preoperative work-up included upper GI endoscopy and oesophageal pH-monitoring.

Endoscopy

Upper GI endoscopy was performed after an overnight fast. Patients were all offered topical anaesthetics and intravenous midazolam. Using a 9 mm endoscope (Olympus, Sweden) a complete examination of the oesophagus, stomach and proximal duodenum was performed. The presence of hiatal hernia, erosive oesophagitis and columnar lined oesophagus were

noted. No patient had a hernia at time of endoscopy. Findings were integrated and reported according to the DeMeester scoring system [6].

Oesophageal pH monitoring

With the endoscope in the oesophagus, the BRAVO catheter system [7,8] was introduced transorally. The pH capsule was first inserted to the level of the upper stomach and then gradually withdrawn until the pH electrode on the tip of the capsule was positioned 6 cm proximal to the squamocolumnar junction. Suction was applied through the delivery catheter for 45 seconds in order to capture the oesophageal mucosa into a cavity of the capsule. After securing the mucosa within the capsule with a stainless pin, the capsule was released from the catheter and the delivery system removed.

The pH recording was initiated immediately after placement of the capsules. All subjects were instructed to keep the receivers attached to a belt around the waist during the entire 48-hour study period. Study patients were encouraged to return to work and to engage in all normal daily activities. They were allowed to eat normal food but instructed to avoid acidic food products and alcohol, and also to keep tobacco consumption as low as possible during the study period. Prior to and during both study periods patients were also instructed to abstain from medications known to influence acid reflux. One week for proton pump inhibitors, and 24 hours for anticholinergics, antacids and metoclopramide. All subjects were asked to keep a diary documenting food intake and periods of supine body position. The receivers and diaries were returned after 48 hours. The data from the receivers were loaded into a computer and analyzed using the software Polygram™ NET, (Medtronic, MN, USA).

Revisional surgery

Operations were performed through an upper midline incision in a reverse Trendelenburg position. The main principles of our operative technique has been previously described [9]. In short, it involved first locating the band. Secondly, the pouch was calibrated to be 15-20 ml in volume. This was achieved by an application of a linear stapler vertically up to the angle of His. The tissue interposed between the old and the new staple line was excised. The band was opened in its ventral aspect and a gastrotomy performed at that level. The anvil was introduced into the pouch. After that, the previously banded area was excised using two applications of a linear stapler; one for the lower aspect of the pouch and the other to close towards the antrum. Finally the tip of the anvil was brought out through the lower staple row of the pouch.

The pouch was then anastomosed to a retrogastric, retrocolic Roux-en-Y limb, using a circular 28 mm stapler in all cases. The stapler was introduced through a longitudinal anti-mesenteric jejunotomy which was closed length-wise. The Roux-limb was made 100 cm long, at that time our standard length for patients with BMI at operation of $< 45 \text{ kg/m}^2$. The hiatal opening was left unaltered.

There was no mortality or serious morbidity in the series, mean hospital time was three days (range 2-5)

Statistics

The Wilcoxon Signed Rank test was used throughout; P-values < 0.05 were taken to be statistically significant.

Acknowledgement:

The present study was approved by the Lund University Ethics committee, and financed in part by the Crafoord foundation. The authors declare no conflict of interest.

Results

Mean time between revisional surgery and the postoperative endoscopy and pH-recording was 46.6 days. During that time patients lost an average of 3.6 BMI points; $p < 0.05$ (fig.1).

At the time of the postoperative endoscopy and measurement of acid reflux all patients had become free of reflux symptoms. Findings are given as individual data points in figs. 2 and 3. A tabular presentation is given in table I. The overall reduction in exposure to acid in the distal oesophagus was significantly reduced for total as well as for supine values.

All patients improved also in DeMeester score (fig 2, 3). They had all been on proton pump inhibitors preoperatively, and all could discontinue that use following conversion to GBP.

Discussion

Obesity surgery has become widespread in recent years, in Europe as well as in the US. The relative use of different methods varies between continents. Europe has gone from using restrictive methods towards a more widespread use of gastric bypass, whereas the restrictive method of gastric banding is gaining in popularity in the US. VBG was previously used as the restrictive method of choice. We have however with time grown aware of its drawbacks. It seems prudent to analyse whether conversion surgery can alleviate parts of the problems of restrictive bariatric surgery. And if so, by which mechanism, the altered anatomy or through enhanced weight-loss?

Gastroesophageal reflux is more common in obese than in lean patients [10,11]. The introduction of a stricture in the upper GI tract, such as a band, may counteract the beneficial effect of weight-loss. Over time, the gastric pouch is distended oral to such a stricture.

Whether this distension is reflected in an increased acid secretion is largely unknown. An alternative way of explaining the clinical problem of GERD after VBG is that pouch distension may distend also the lower oesophageal sphincter.

The present study was designed with a second measurement soon after conversion surgery to minimize the possible effects of weight loss and more clearly identify whether altered anatomy induced changes in reflux patterns.

We thus compared acid reflux in symptomatic patients before and soon after a conversion operation to gastric bypass. A new 15-20 ml pouch was constructed in all cases, and a wide anastomosis was ascertained by the use of a 28 mm circular cartridge. Before operation the clinical suspicion of GERD could be confirmed in all cases. The Bravo capsule recording has been shown to be sensitive and reproducible, and the addition of manometry is of little value [7,8] Postoperative recordings showed improvements in all patients in measured reflux, coupled to a reduction in DeMeester score and pronounced clinical improvement, expressed

as a discontinuation the PPI and antacid therapy in all cases. This scoring system takes into account factors such as hiatal hernia, mucosal appearance etc.

Time to second endoscopy and pH recordings was chosen so that all patients had had the time to go back on normal food, but not so long that the full weight-reducing effects of conversion had taken place. Our results thus seem to indicate that the altered anatomy plays a major role in the clinical improvement. This alteration involves both the restoration of the size of the pouch, but also the disappearance of the previous band-induced stricture.

The present study material is limited in size. This stems from the fact that most conversion operations are performed for staple line dehiscence and poor weight loss. To include such patients in the study would jeopardise the purity of design and thus make conclusions more uncertain. We used only 24 hour pH recordings, since manometry has been shown not to add discriminatory factors in the work-up of patients [2].

The idea that GBP is a superior procedure for treating GERD in obese patients is not new. Sugerman [12] described clinical improvement after conversion in 1996 using open surgery. Also two recent studies published in 2011 [13, 14] and a Mayo clinic study from Balsiger et al [15] in 2000 have shown the benefits of conversion . However, these studies have postoperative evaluation points 31 months, 8 years and 37 months resp., making it impossible to separate the effects of weight reduction from those of the altered anatomy. Also, previous evaluations have been based on symptomatology without acid reflux data. Converting VBG-operated patients to GBP results already short-term in a near-normalisation of acid reflux parameters. We conclude that the altered anatomy seems to be a main factor behind these beneficial effects.

References:

1. Balsiger BM, Poggio JL, Mai J, Kelly KA, Sarr MG. Ten and more years after vertical banded gastroplasty as primary operation for morbid obesity. *J Gastrointest Surg* 2000;4(6):598-605.
2. Ortega J, Escudero MD, Mora F, Sala C, Flor B, Martinez-Valls J, Sanchiz V, Martinez-Alzamora N, Benages A, Lledo S. Outcome of esophageal function and 24-hour esophageal pH monitoring after vertical banded gastroplasty and Roux-en-Y gastric bypass. *Obes Surg* 2004;14(8):1086-94.
3. Varela JE. Barrett's esophagus: a late complication of laparoscopic adjustable gastric banding. *Obes Surg* 2010;20(2):244-6.
4. Kalfarentzos F, Skroubis G, Kehagias I, Mead N, Vagenas K. A prospective comparison of vertical banded gastroplasty and Roux-en-Y gastric bypass in a non-superobese population. *Obes Surg* 2006;16(2):151-8.
5. Olbers T, Fagevik-Olsen M, Maleckas A, Lonroth H. Randomized clinical trial of laparoscopic Roux-en-Y gastric bypass versus laparoscopic vertical banded gastroplasty for obesity. *Br J Surg* 2005;92(5):557-62.
6. Johnson LF, DeMeester TR. Development of the 24-hour intraesophageal pH monitoring composite scoring system. *J Clin Gastroenterol* 1986;8 Suppl 1:52-8.
7. Wenner J, Johansson J, Johnsson F, Oberg S. Optimal thresholds and discriminatory power of 48-h wireless esophageal pH monitoring in the diagnosis of GERD. *Am J Gastroenterol* 2007;102(9):1862-9.
8. Wenner J, Johnsson F, Johansson J, Oberg S. Wireless oesophageal pH monitoring: feasibility, safety and normal values in healthy subjects. *Scand J Gastroenterol* 2005;40(7):768-74.

9. Hedenbro JL, Frederiksen SG. Fully stapled gastric bypass with isolated pouch and terminal anastomosis: 1-3 year results. *Obes Surg* 2002;12(4):546-50.
10. El-Serag HB, Ergun GA, Pandolfino J, Fitzgerald S, Tran T, Kramer JR. Obesity increases oesophageal acid exposure. *Gut* 2007;56(6):749-55.
11. Hampel H, Abraham NS, El-Serag HB. Meta-analysis: obesity and the risk for gastroesophageal reflux disease and its complications. *Ann Intern Med* 2005;143(3):199-211.
12. Sugerman HJ, Kellum JM Jr, DeMaria EJ, Reines HD. Conversion of failed or complicated vertical banded gastroplasty to gastric bypass in morbid obesity. *Am J Surg*. 1996 Feb;171(2):263-9.
13. Gagné DJ, Dovec E, Urbandt JE. Laparoscopic revision of vertical banded gastroplasty to Roux-en-Y gastric bypass: outcomes of 105 patients. *Surg Obes Relat Dis*. 2011 Jul-Aug;7(4):493-9. Epub 2010 Nov 5.
14. Srikanth MS, Oh KH, Fox SR. Revision to malabsorptive Roux-en-Y gastric bypass (MRNYGBP) provides long-term (10 years) durable weight loss in patients with failed anatomically intact gastric restrictive operations: long-term effectiveness of a malabsorptive Roux-en-Y gastric bypass in salvaging patients with poor weight loss or complications following gastroplasty and adjustable gastric bands. *Obes Surg*. 2011 Jul;21(7):825-31.
15. Balsiger BM, Murr MM, Mai J, Sarr MG. Gastroesophageal reflux after intact vertical banded gastroplasty: correction by conversion to Roux-en-Y gastric bypass. *J Gastrointest Surg*. 2000 May-Jun;4(3):276-81.

Fig 1: Time (days) between recording 1, operation and recording 2 and BMI development, plotted for individual patients; conversion operation at time 0.

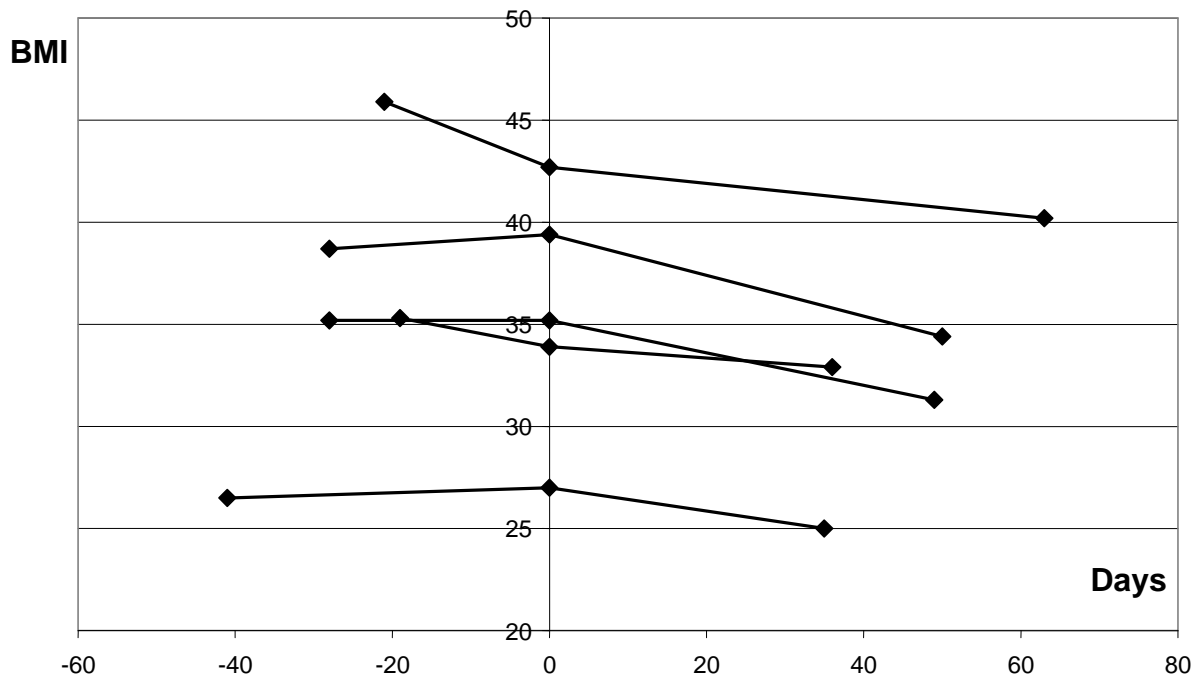


Table I: Reflux and oesophagitis data before and after revisional surgery.

N=5	Pre	Post	P value
<i>No reflux episodes</i>	119,0	75,0	0.78
<i>No. long refluxes</i>	10,0	2,8	<0.05
<i>Duration longest reflux</i>	55,4	22,4	<0.05
<i>%<pH4, total</i>	18,4	3,3	<0.05
<i>%<pH4, supine</i>	25,1	5,0	<0.05
<i>Percent reduction in acid exposure time</i>		74.2	Not applicable
<i>DeMeester score</i>	58,1	15,9	<0.05

Fig 2: Bravo capsule recording of percent time with a pH of < 4.0, plotted for individual patients.

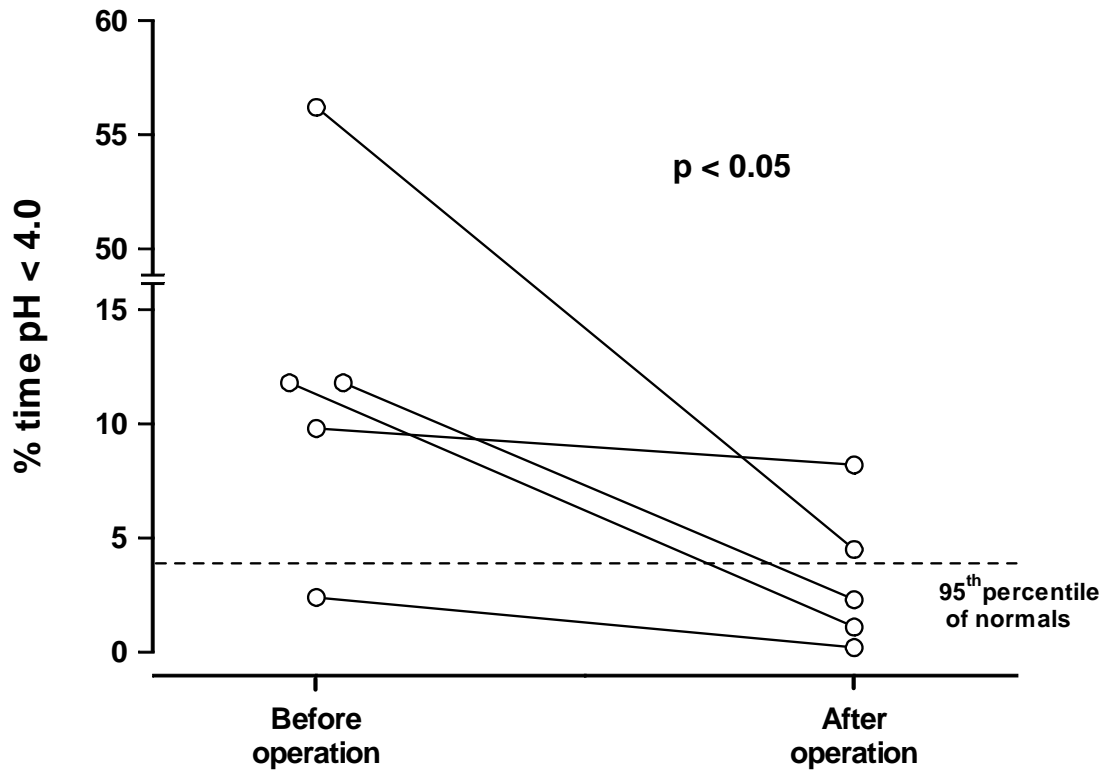


Fig 3: DeMeester score before and after revisional surgery, plotted for individual patients.

