



LUND UNIVERSITY

Indirect endoscopic photography of the larynx

Kitzing, Peter

Published in:
Journal of Audiovisual Media in Medicine

1978

[Link to publication](#)

Citation for published version (APA):
Kitzing, P. (1978). Indirect endoscopic photography of the larynx. *Journal of Audiovisual Media in Medicine*, 1(3), 121-130. <http://www.ncbi.nlm.nih.gov/pubmed/739117>

Total number of authors:
1

General rights

Unless other specific re-use rights are stated the following general rights apply:
Copyright and moral rights for the publications made accessible in the public portal are retained by the authors and/or other copyright owners and it is a condition of accessing publications that users recognise and abide by the legal requirements associated with these rights.

- Users may download and print one copy of any publication from the public portal for the purpose of private study or research.
- You may not further distribute the material or use it for any profit-making activity or commercial gain
- You may freely distribute the URL identifying the publication in the public portal

Read more about Creative commons licenses: <https://creativecommons.org/licenses/>

Take down policy

If you believe that this document breaches copyright please contact us providing details, and we will remove access to the work immediately and investigate your claim.

LUND UNIVERSITY

PO Box 117
221 00 Lund
+46 46-222 00 00

Indirect endoscopic photography of the larynx

A comparison between two newly constructed laryngoscopes

C. HAHN and P. KITZING

The larynx is of fundamental importance for the production of normal speech. The examination of its interior parts is complicated and so far no routine method exists for photographic documentation without general anesthesia. In recent years new optical systems for laryngeal endoscopes have been constructed which seem very promising. This is a description of two such endoscopes and an account of clinical and photographic tests performed on them.

The larynx is about the size of a matchbox. It consists of several cartilages and a number of muscles and ligaments. The interior aspect of the larynx is lined by a mucous membrane which is arranged in two pairs of folds: the vocal folds and the ventricular folds. Forming the upper end of the trachea, the principal and vital function of the larynx is to act as a valve for the respiratory tract. It keeps open the entrance to the lower airways during respiration, but provides an efficient closure when swallowing or increasing the intrathoracic pressure (for instance immediately before coughing). In addition to this vital function, the larynx can work as a sound generator through the vibrating vocal folds and produce phonation, which is a prerequisite for normal speech and singing.

Disturbance of voice function or hoarseness is a symptom of most pathological conditions of the larynx including acute and chronic inflammation, tumours (benign or malignant) and impairment of laryngeal movements by paresis of the vocal folds, which in turn may be a sign of serious disease in the neck or chest. Visual examination of the larynx is very important for the diagnosis of laryngeal disease and thus photographic documentation of the laryngoscopic findings may be of

C. Hahn is a Medical Photographer in the Department of Phoniatics, University ENT Clinic, General Hospital, Malmö, Sweden. P. Kitzing, MD, is the Head of the Department.

considerable value. The methods by which this may be performed can be divided into indirect and direct.

In 1854 the Spanish singing teacher Manuel Garcia managed to visualize his own vocal folds with the aid of a small dental mirror, using bright sunshine as a light source. This is usually considered as the start of *indirect laryngoscopy*, which is still the most common method by which the larynx is examined in clinical routine work. In this method, the examiner wears a head mirror, reflecting the light from a bright electric bulb behind the patient's head on to a small laryngeal mirror, which is held by its handle at the back of the patient's mouth, just above the entrance to the larynx (Figure 1a). Within six years of Garcia's invention of the laryngeal mirror, the Viennese laryngologist Czermak succeeded in taking a photograph of the larynx by indirect laryngoscopy. During the following century examiners went on to develop and modify this method (for details cf. Brown 1883, Albrecht 1956, Olbrich 1956, Fendel 1960 and Kleinsasser 1976). However, the technique falls down whenever the interior of the larynx cannot be visualized, either because of the patient's difficulty in cooperating or because of obstructing anatomy.

In these cases the investigation can only be done by *direct laryngoscopy*. This is usually carried out under general anesthesia. A metal tube, the laryngoscope, is passed through the patient's mouth down to the laryngeal structures (Figure 1b). Using elaborate photographic devices attached to the laryngoscope, Holinger obtained excellent illustrations of the larynx (Holinger 1972).

The view through the laryngoscope can be improved with an operating microscope, a technique called *micro-laryngoscopy* (Scalco et al. 1960 and

Kleinsasser 1976). It is easy to get photographs useful to the clinician, if a camera is attached to the microscope via a beam-splitter. This is now the most common method of photographic documentation in laryngological practice (Figure 1c). The most serious drawback to the method is the need for general anesthesia which cannot be justified for the purposes of photography alone.

During recent years it has become possible to photograph the internal structures of the larynx by means of flexible fibrescopes (Sawashima and Hirose 1968, Figure 1d). The fibrescope is best inserted through the nose as this does not interfere with normal articulation, but it can be inserted through the mouth if the nasal passages are obstructed. For both routes local anesthesia is sufficient. This would be an ideal method of visualizing and photographing the larynx, but the size of the photographic image produced is too small (circ. 6 x 6 mm) and the resolution is not sufficient for the photographs to be of clinical use in more than a few cases.

Many of these obstacles are overcome by the method of *indirect laryngeal endoscopy* (Figure 1e). An endoscopic telescope with a viewing angle of 90 degrees is introduced into the pharynx by the oral route and can be used for examination of the larynx as well as for photography. During the examination the patient and the operator sit in front of each other, the operator holding the instrument in one hand and using the other hand for holding the patient's tongue (Figure 2). The telescope in effect places the front lens of the camera close to the object under observation.

Initially, the endoscope was lit distally by small incandescent light bulbs (Sauer 1937). For photographic purposes the bulbs were electrically overloaded and could then emit sufficient

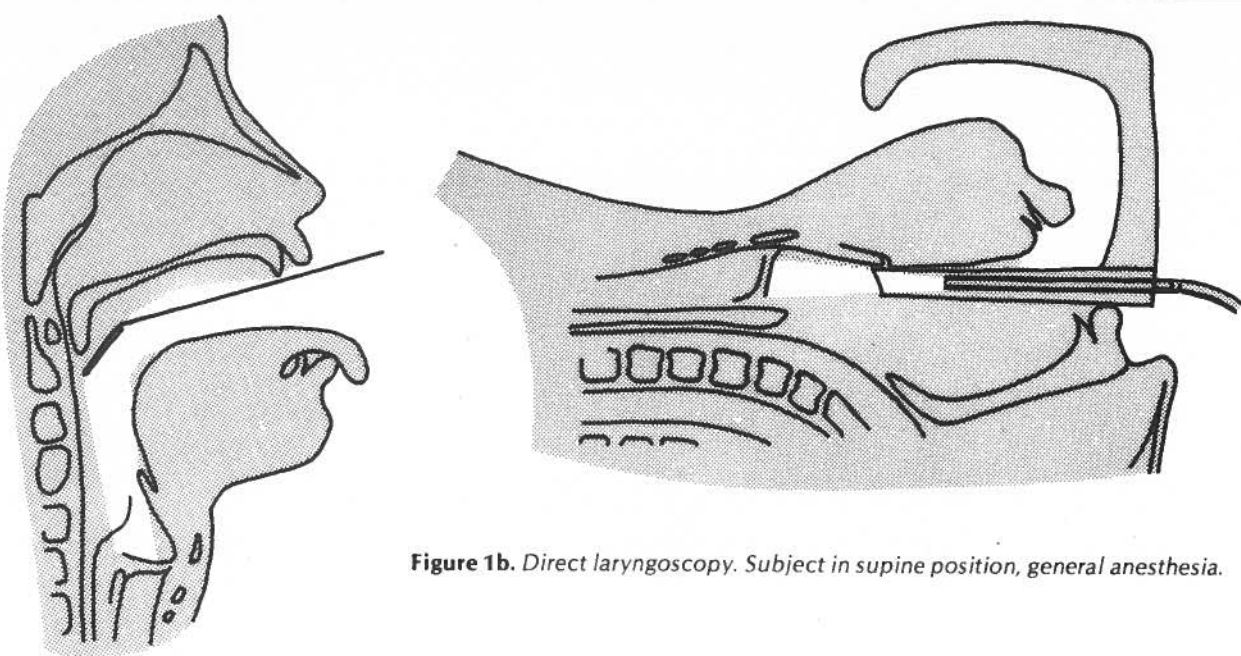


Figure 1b. Direct laryngoscopy. Subject in supine position, general anesthesia.

Figure 1a. Indirect laryngoscopy by aid of laryngeal mirror. May be combined with operating microscope.

Figure 1c. Direct laryngoscopy by aid of suspension laryngoscope and operating microscope, so called microlaryngoscopy.

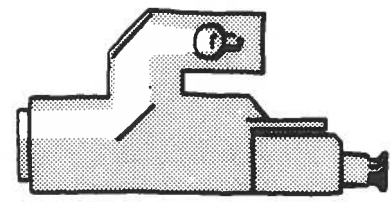
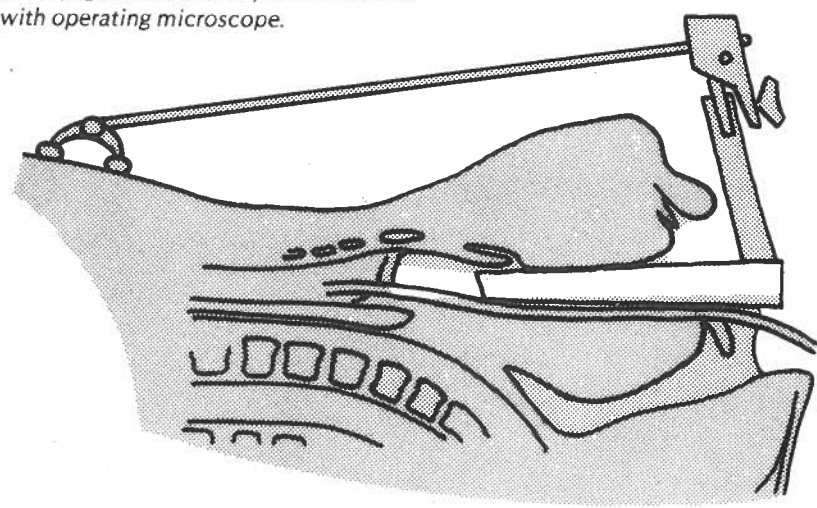
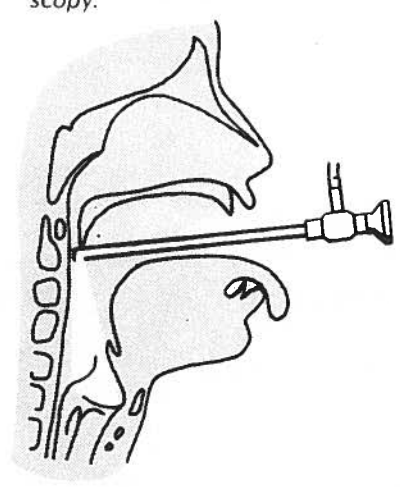
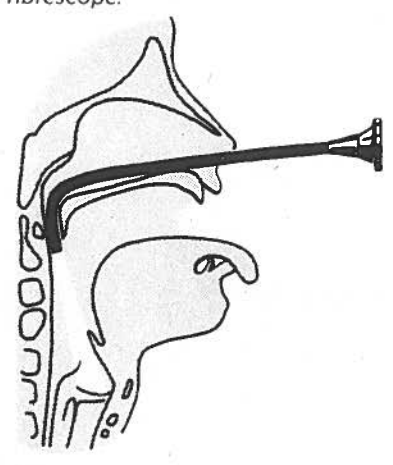


Figure 1d. Laryngeal examination by aid of fibrescope.

Figure 1e. Indirect laryngeal endoscopy.



light for taking colour photographs, with an exposure time of 0.5 to 0.2 seconds (Wieland 1957). Alternatively, a flash-light from an external source could be transmitted to the larynx by a quartz rod applied to the endoscope (Krugel 1959). During the last decade, the 'cold' light transmitted by fibre-optic bundles from an external light source combined with a flash has become standard equipment (Moser and Böhme 1969). The fibre-optic bundles are arranged to furnish light on either

side of the viewing lens of the endoscope (Figure 3). In this way, the objective lens of the endoscope can be placed very close to the distal end of the instrument and obstructions of the visual field can be eliminated (Gould 1973).

The larynx can also be illuminated with a stroboscopic light source, and an impression of the laryngeal vibrations can be obtained (Barth 1977). Furthermore, this apparatus can be made to trigger a flashlight and sharp photographs can be taken during phonation

and resolved in phase in spite of the fast vibrations of the vocal folds (Bjuggren 1960).

The method of indirect endoscopic examination and photography of the larynx has recently gained new impetus with the construction of two different laryngoscopes reported by Ward et al. (1974) and v. Stuckrad and Lakatos (1975). Both instruments can also be used for the examination of the nasopharyngeal cavities (Buitter 1976). This article describes these endoscopes and the authors give an account of their experiences for clinical and photographic purposes.

Instruments

The endoscope described by Ward et al. (1974) is equipped with a Hopkins telescope and manufactured by Karl Storz, KG, Tuttlingen, Germany (Federal Republic). The instrument described by v. Stuckrad and Lakatos (1975) is manufactured by Richard Wolf GmbH, Knittlingen, Germany (Federal Republic). The physical dimensions of both instruments are given in table 1.

The Berci and Ward (BW) endoscope (Figure 4) consists of two parts, a telescope and a light conducting tube which can be locked together with a bayonet socket. The telescope contains a series of fixed glass cylinders replacing the interspace between the lenses in the more conventional endoscopes and producing a set of small 'air-lenses' between them. This construction is reported to bring about a wider view angle in relation to the diameter of the optics (Berci 1976).

There are two different sizes of light conducting tubes, one of a smaller diameter for visual examination and flash photography only, and one of a larger diameter intended for cine-photography but also useful when the available light-source is insufficient. The larger light conducting tube has two connections for the fibre light cables so that either two separate cables or the two distal ends of a Y-shaped cable can be attached. In both tubes the light outlet is shaped into two rectangular areas on each side of the front lens. The instrument has an anti-mist airflow system by means of a small airchannel made by a groove along the inner aspect of the light conducting tube and the telescope. The groove has an air connection at the proximal end of the tube and is easy to reach for cleansing when the instrument is taken apart.

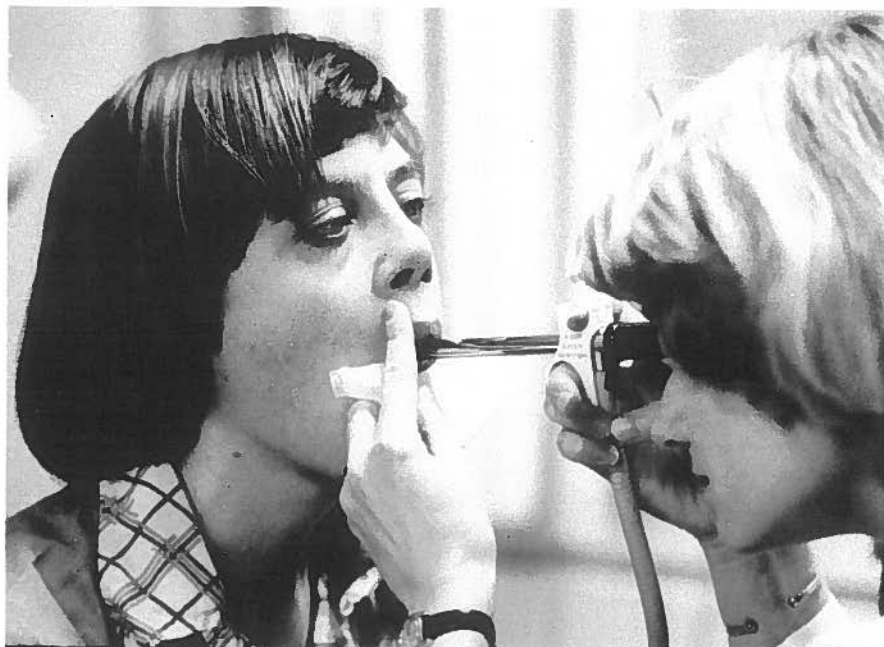

Figure 2. Examination of the larynx by indirect laryngeal endoscopy.

Figure 3. Detail of the von Stuckrad laryngoscope to the left and the Berci Ward laryngoscope to the right, showing the rectangular light outlets.




Table 1. Dimensions and weight of the tested laryngoscopes.

		Berci/Ward endoscope	v. Stuckrad endoscope	
Length		283 mm		243 mm
Diameter	optics	4.5 mm	horizontal	9 mm
	incl. light conducting tube I	8.5 mm	vertical (incl. ventilating tube)	10 mm
	incl. light conducting tube II	12 mm		
Eye piece diameter		32 mm		32 mm
Weight	Optics	110 g	Incl. fibre light cable	350 g
	Tube I	330 g		
	Tube II	400 g		
Area of light outlet	Tube I	8.4 mm ²		14.5 mm ²
	Tube II	32 mm ²		
Lens diameters	front lens	2.2 mm		3.9 mm
	ocular lens	6.9 mm		5.4 mm
Length of fibre-light cable	Optional (detachable)		Fixed or optional (detachable)	1500 mm

The endoscope described by v. Stuckrad (v S) also consists of a telescope, a light transmission system and an anti-mist device, but they cannot be taken apart (Figure 5). A fibre optic cable, which also includes an air tube for the anti-mist device, is fixed to the instrument. Connections for changing the fibre optic cables (and air tubes) are available. The instrument includes a plastic handle. The telescope has a relatively low weight as it contains groups of lenses instead of glass rods. With the aid of a knob (Figure 6) it is possible to change the relationship of these lenses to each other, which results in a change of magnification and focus of the object under observation. This construction should not be confused with a zoom lens which can change the angle of view continuously and without influencing the focus. The light transmission opens at two rectangular outlets on each side of the front lens of the telescope. The anti-mist device consists of an air conducting narrow metal tube, permanently fixed to the instrument and opening immediately behind the front lens.

Procedure

The two laryngoscopes were tested by taking black and white photographs of a test object. They were also used during the clinical examination of a number of adult patients, when colour photographs were taken. All photographs were taken with a Nikon SLR camera with a 105 mm Nikkor lens. As the stan-




Figure 4. The Berci Ward laryngoscope. From top to bottom are seen the larger and the smaller light conducting tubes, and the endoscope.

Figure 5. The von Stuckrad laryngoscope.

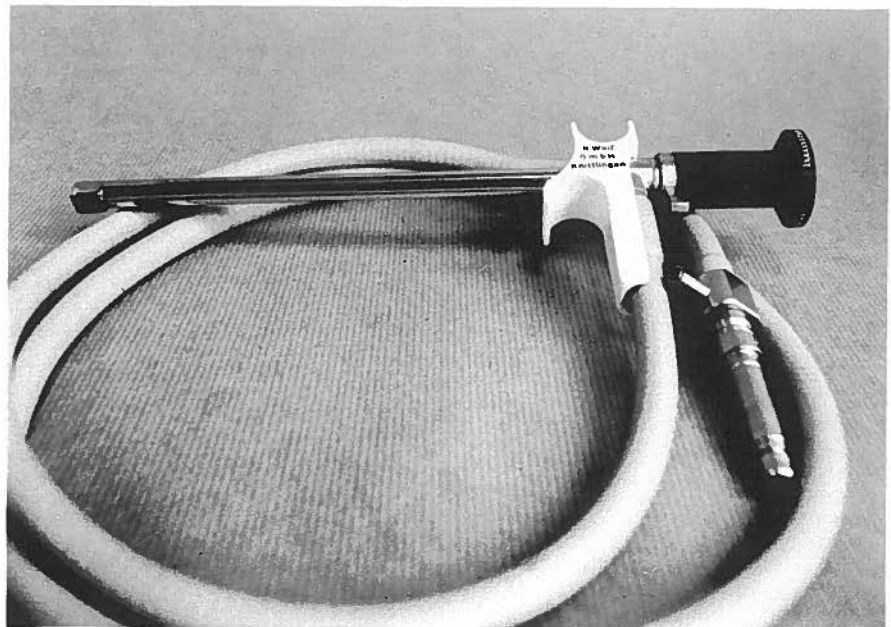


Figure 7a. Photograph of a regular dot pattern at constant distance to the front lens of the laryngoscopes. v S endoscope, survey setting.

dard focusing screen yielded too dark a viewing field, it had to be replaced by a Fresnel field on clear glass manufactured by Nikon.

For the formal testing of the optical performance of the laryngoscopes a dotted screen was used. Most of the test photographs were taken at a distance of 65 mm from the front lens of the laryngoscopes, but in one series of pictures the distance was varied to obtain exactly the same size image on the film with each instrument. Both possible degrees of magnification were tested in the v S laryngoscope. In the higher magnification setting the exposure time was increased by one stop to obtain a comparable degree of density in the pictures.

To minimize vibration and blurring of the image both the camera and the laryngoscope were mounted on a tripod during the tests. For the same reason the exposures were made with a cable release and with the mirror in a raised position. All the test photographs were made on 125 ASA fine-grained black and white film (Kodak Plus X), and the objects were illuminated by separate photo spotlights to avoid any influence

Figure 6. Detail of the von Stuckrad endoscope, showing the knob for adjusting magnification and sharpness. Two positions are possible, either for survey or for detail magnification.



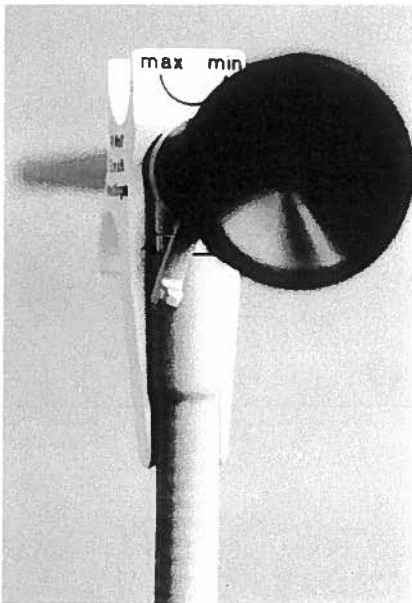



Figure 7b. Photograph of a regular dot pattern at constant distance to the front lens of the laryngoscopes. v S endoscope, detail setting.

Figure 7c. Photograph of a regular dot pattern at constant distance to the front lens of the laryngoscopes. BW endoscope.






Figure 8. Details of photographs at different distances to obtain the same degree of magnification. a) v S endoscope, survey setting. b) v S endoscope, detail setting. c) BW endoscope.

from differences in the light transmission of the laryngoscopes.

The clinical photographs were made on Kodak Ektachrome High Speed film which was developed to give 640 ASA. The fibre light projector (Wolf 5005) had a built in flash device which was synchronized with the camera.

To test the sterilization of the instruments they were cleaned in rinsing water and 70 per cent alcohol, soaked in a commercially available chemical soaking fluid (2 per cent Ivisol (R) solution) and finally washed with alcohol. After this standard procedure, several bacterial cultures were taken from both instruments. No growth of bacteria was apparent in any of the incubated cultures.

Results and discussion

Photographs of the dotted screen taken through the endoscopes at a constant distance of 65 mm are shown in Figure 7. The photographs give an impression of the differences in magnifying power between the endoscopes. From the photographs the degree of linear magnification of the BW endoscope, of the survey setting of the v S endoscope, and of the detail setting of the same endoscope were measured to be 1 : 1.9 : 3, respectively. The degree of blurring and distortion of the dots towards the periphery of the photograph as well as some marginal areas of diminished illumination can be seen. In all three photographs there is some barrel-shaped

distortion, which is most obvious in the picture from the survey setting of the v S endoscope (Figure 7a).

By changing the distances to the object the same degree of magnification could be obtained in all the three tested endoscope settings (Figure 8). In this figure, the degree of sharpness can be seen to decrease more or less rapidly from the top left corner of the pictures, representing the central part of the original photograph, to the bottom right corner of the pictures, representing the marginal parts of the photograph.

Most of the clinical testing of the endoscopes was carried out by one of the authors (PK), who has 10 years' experience of laryngological examinations as a specialist. The opinions of some medical students at the beginning of their laryngological training were also considered. Both endoscopes were very easy to handle and seemed to cause less inconvenience to the patients than unskilled laryngological mirror examinations. On the other hand, when the examination was difficult for anatomical reasons or because of enhanced gagging reflexes, the use of an endoscope did not seem to be of conspicuous advantage for a trained laryngologist and local anesthesia had to be used about as often as in examinations with a laryngeal mirror.

The available light source was not bright enough to produce sufficient illumination through the smaller light conducting tube of the BW endoscope in all cases. With the larger light conduct-

ing tube the light was sufficient, but in some female subjects of small stature the larger dimensions of this tube caused difficulties. In this respect, the v S endoscope was found to fall between the two options of the BW endoscope.

With the v S endoscope a bright and detailed image of the laryngeal structures was easily obtained, and the option of changing between a survey and a detail setting of the optics was a real advantage for the investigation. In practice, the degree of magnification in the detail setting of this endoscope was comparable to mirror laryngoscopy magnified with an operating microscope. On the other hand, limitations to the depth of focus of the v S endoscope required very exact adjustments for sharpness, which was not always easy to achieve.

It was generally much easier for an untrained observer to examine the internal structures of the larynx with the endoscope rather than with the laryngeal mirror. A trained laryngologist, however, can obtain as good information with the laryngeal mirror as with the endoscope. In any case, the difference does not seem to be great enough to justify the considerably higher costs of an endoscope for the sake of laryngeal examinations only. Therefore, the main advantage of the endoscopes is feasibility of obtaining photographic documentation of the larynx. This is illustrated in Figure 9. In the pictures from the BW endoscope a considerable depth of focus is evident, but there is

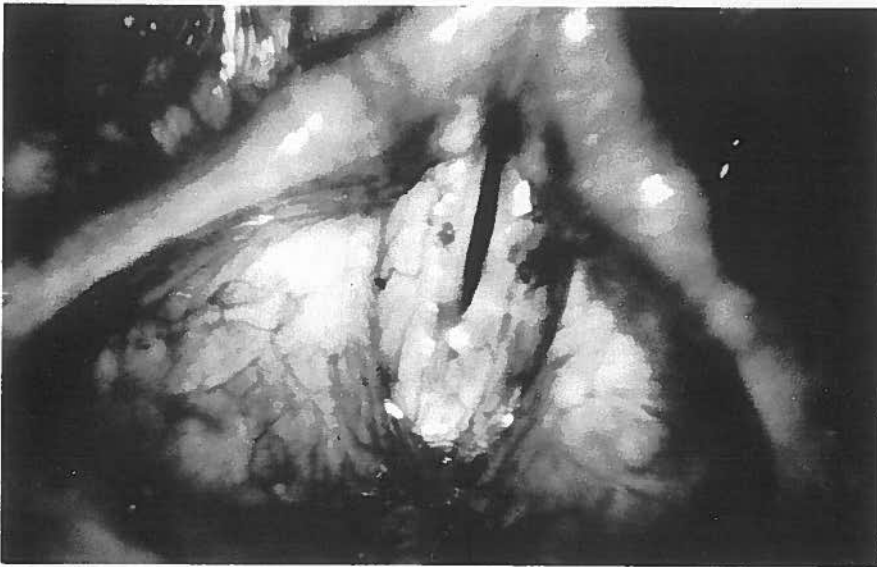


Figure 9a. *Photographic documentation of laryngological examination. v S endoscope, survey setting.*

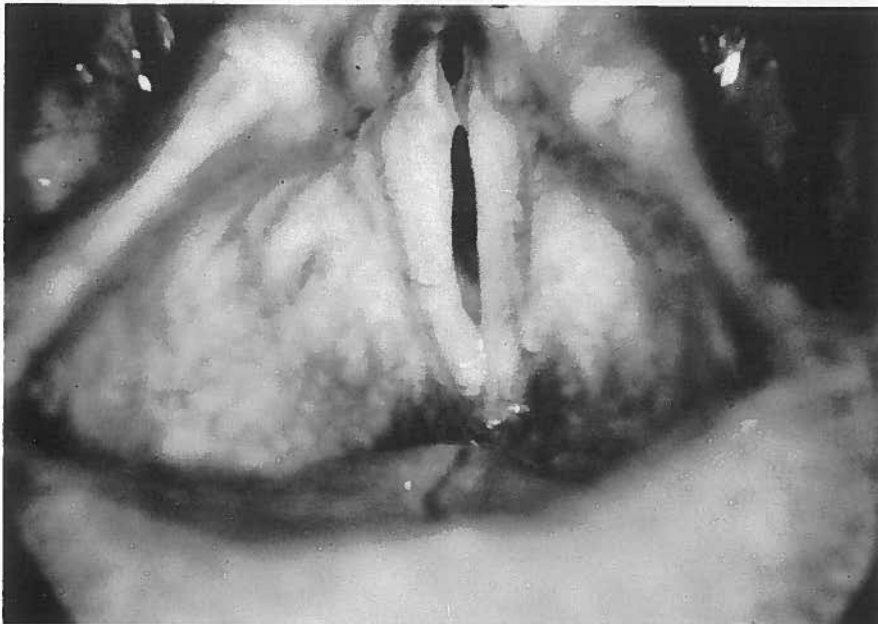


Figure 9b. *Photographic documentation of laryngological examination. v S endoscope, detail setting.*

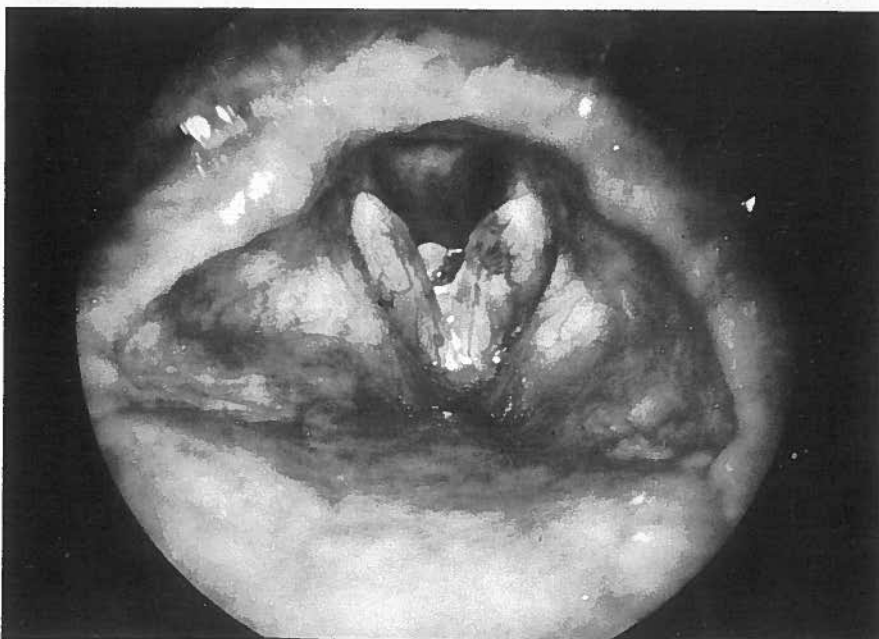


Figure 9c. *Photographic documentation of laryngological examination. BW endoscope, larger light conducting tube.*

some restriction in illumination of the photograph taken with the smaller light tube. In the illustrations from the v S endoscope the advantages of magnification can be studied.

Conclusion

In conclusion, both laryngoscopes were found to be very suitable for indirect endoscopic examinations of the larynx and their photographic documentation. They should be recognized as a substantial contribution to the arsenal of laryngological methods. The main practical difference between the instruments comes from their different degree of magnification and depth of focus. If higher degrees of magnification are chosen, the depth of focus becomes small and the distance setting of the endoscope must be very exact to obtain acceptable sharpness. With a larger depth of focus this is not so critical, but a smaller degree of magnification has to be accepted.

Acknowledgements

The von Stuckrad endoscope was put at our disposal for testing by the Wisex Company, Mölndal, Sweden, to whom we wish to express our sincere gratitude.

Thanks go also to MD Åke Cederberg, Department of Clinical Bacteriology, General Hospital, Malmö, for carrying through the bacteriological tests.

References

- Albrecht, R. (1956). Zur Photographie des Kehlkopfs. *HNO*, 5, 196-199.
- Barth, V. (1977). Die Lupenstroboskopie. *HNO*, 25, 35.
- Berci, G. (ed.) (1976). *Endoscopy*. Appleton Century Crofts, New York.
- Bjuggren, G. (1960). Device for Laryngeal Phase-Determinable Flash Photography. *Folia Phoniatica*, 12, 37-41.
- Brown, L. (1883). On photography of the larynx and soft palate. *Br. Med. J.*, 1, 811.
- Buiter, C.T. (1976). *Endoscopy of the upper airways*, Excerpta medica, Amsterdam, American Elsevier Publishing Comp., New York.
- Fendel, K. (1960). Der Kehlkopf und seine krankhaften Veränderungen im Bild. *Das medizinische Bild*, 3, 74-78.
- Gould, W.J. (1973). The Gould Laryngoscope. *Tr. Am. Acad. ophth. and otol.*, 77, 139-141.
- Holinger, P.H. and Brubaker, J.D. (1972). Still and motion picture photography of the tracheobronchial tree and oesophagus

through endoscopic telescope. *Trans. Am. Broncho-Esophagol Assoc.*, 52, 111.

Kleinsasser, O. (1963). Entwicklung und Methoden der Kehlkopfphotographie. *HNO*, 11, 171-176.

Kleinsasser, O. (1976). *Mikrolaryngoskopie und endolaryngeale Mikrochirurgie*, (2nd ed.), F K Schattauer Verlag, Stuttgart-New York.

Krugel, K. (1959). Ein neues Gerät zur Blitzphotographie des Larynx und Hypopharynx. *HNO*, 7, 334-335.

Moser, F. and Böhme, G. (1969). Erfahrungen mit der Elektronenblitz-Endofotoeinrichtung MGB 405 in der Laryngologie. *Medizintechnik*, 9, 49-51.

Olbrich, H. (1956). Die Photographie in der Hals-, Nasen-, Ohrenheilkunde. *Z. Laryng. Rhinol.*, 35, 711-727.

Sauer, G. (1937). Ein neues Photo-Laryngoskop. *HNO*, 41, 187-189.

Sawashima, M and Hirose, H. (1968). New Laryngoscopic Technique by use of Fiber Optics. *J. Acoust. Soc. Am.*, 43, 168-169.

Scalco, A.N., Shipman, W.F. and Tabb, H.B. (1960). Microscopic Suspension Laryngoscopy. *Ann. ORL.*, 69, 1134-1138.

v. Stuckrad, H. and Lakatos, I. (1975). Über ein neues Lupenlaryngoskop. *Laryng. Rhinol.*, 54, 336-340.

Ward, P.H., Berci, G. and Calcaterra, T.C. (1974). Advances in endoscopic examination of the respiratory system. *Ann. Otol.*, 83, 754-760.

Wieland, H. (1957). Über die indirekte Kehlkopfphotographie. *Z. Laryng. Rhinol. Otol.*, 36, 64-66.