



LUND UNIVERSITY

Doppler velocimetry for predicting fetal death in a twin pregnancy.

Soikkeli, Pia; Dubiel, Mariusz; Gudmundsson, Saemundur

Published in:
Acta Obstetrica et Gynecologica Scandinavica

DOI:
[10.1034/j.1600-0412.2002.810817.x](https://doi.org/10.1034/j.1600-0412.2002.810817.x)

2002

[Link to publication](#)

Citation for published version (APA):
Soikkeli, P., Dubiel, M., & Gudmundsson, S. (2002). Doppler velocimetry for predicting fetal death in a twin pregnancy. *Acta Obstetrica et Gynecologica Scandinavica*, 81(8), 783-785. <https://doi.org/10.1034/j.1600-0412.2002.810817.x>

Total number of authors:
3

General rights

Unless other specific re-use rights are stated the following general rights apply:
Copyright and moral rights for the publications made accessible in the public portal are retained by the authors and/or other copyright owners and it is a condition of accessing publications that users recognise and abide by the legal requirements associated with these rights.

- Users may download and print one copy of any publication from the public portal for the purpose of private study or research.
- You may not further distribute the material or use it for any profit-making activity or commercial gain
- You may freely distribute the URL identifying the publication in the public portal

Read more about Creative commons licenses: <https://creativecommons.org/licenses/>

Take down policy

If you believe that this document breaches copyright please contact us providing details, and we will remove access to the work immediately and investigate your claim.

LUND UNIVERSITY

PO Box 117
221 00 Lund
+46 46-222 00 00

CASE REPORT

Doppler velocimetry for predicting fetal death in a twin pregnancy

PIA SOIKKELI¹, MARIUSZ DUBIEL² AND
SAEMUNDUR GUDMUNDSSON¹

From the ¹Department of Obstetrics and Gynecology, University Hospital MAS, Malmö, Sweden, and ²Department of Perinatology and Gynecology, University School of Medical Sciences, Poznan, Poland

Acta Obstet Gynecol Scand 2002; 81: 783-785. © Acta Obstet Gynecol Scand 2002

Key words: Doppler; ultrasound; twin pregnancy; fetal hypoxia

Submitted 28 June, 2001

Accepted 7 January, 2002

Diagnosis of discordant twins is easily accomplished with modern ultrasound equipment, though diagnosing twin-to-twin transfusion syndrome (TTS) at an early stage might be a problem. The possibility of excluding TTS by Doppler ultrasound is demonstrated in a case with early severe growth restriction of one fetus. Characteristic blood velocity changes in a dying fetus are also illustrated.

The Doppler technique has become an accepted method in obstetrics for antenatal surveillance, permitting evaluation of fetal circulation in a non-invasive manner and providing important physiological information on the fetal condition. Absent end-diastolic flow in the umbilical artery (UA) can warrant operative delivery for fetal distress (1).

Perinatal mortality is increased fivefold in multiple gestation, as compared with singleton pregnancy (2). The major complications include preterm labor, intrauterine growth retardation (IUGR), TTS, polyhydramnios, oligohydramnios, fetal malformations, and pre-eclampsia. Twin fetuses are generally smaller than singletons and IUGR and intrauterine fetal deaths are more common (3).

Before the introduction of the Doppler technique, ultrasound-imaging evaluation of discordant fetal size in twin pregnancy was a problem. Differential diagnosis of TTS and a true growth retardation of one fetus was a frequent worry for the clinician. Doppler examination of the fetal venous circulation with pulsating flow in the umbilical vein has been found helpful in the diagnosis of fetal congestive heart failure (4, 5). The general ultrasound imaging and Doppler findings in TTS are listed in Fig.1. The information provided by ultrasound imaging and Doppler can thus distinguish between TTS and growth retardation of one fetus and assist the clinician in making a diagnosis and predict the outcome. The following case illustrates characteristic blood velocity findings in a dying fetus.

Case

The case focuses on a 23-year-old primigravid woman with a spontaneous twin pregnancy. In the 19th week of gestation a discrepancy in fetal size was noticed: 242 vs. 92 g, respectively. There was one placenta with rather thick amniotic membranes, suggesting a dichorionic pregnancy. The fetuses were of the same gender and the amniotic fluid was normal. Doppler examination showed normal blood flow in UA, umbilical vein and middle cerebral artery (MCA) in the larger twin. In the smaller twin, end-diastolic blood flow was found to be absent in the umbilical artery without signs of brain sparing in MCA. Umbilical venous flow was normal.

At 21 weeks of gestation, the discordance in growth became more pronounced, fetal weights estimated to be 415 and 166 g, respectively. Doppler examinations performed repeatedly, showed normal blood velocimetry in the larger twin and absent end-diastolic blood flow in the umbilical artery of the smaller one.

At 25 weeks of gestation, Doppler examination showed reversed end-diastolic blood flow in UA in the smaller twin as illustrated in Fig. 2, along with double pulsations in the umbilical vein, both in a free loop of the umbilical cord and in the intra-abdominal part, along with signs of brain sparing in MCA. Ductus venosus velocimetry was abnormal, with reversed flow during atrial contractions (Fig.2). These findings are associated with perinatal mortality (6). Oligohydramnios was present. The larger twin manifested normal blood velocimetry in all vessels studied. After discussion with the parents, their decision was to concentrate on long-term survival of the larger twin.

Serial twice-weekly Doppler measurements were performed, showing abnormal velocimetry in the smaller fetus, but normal

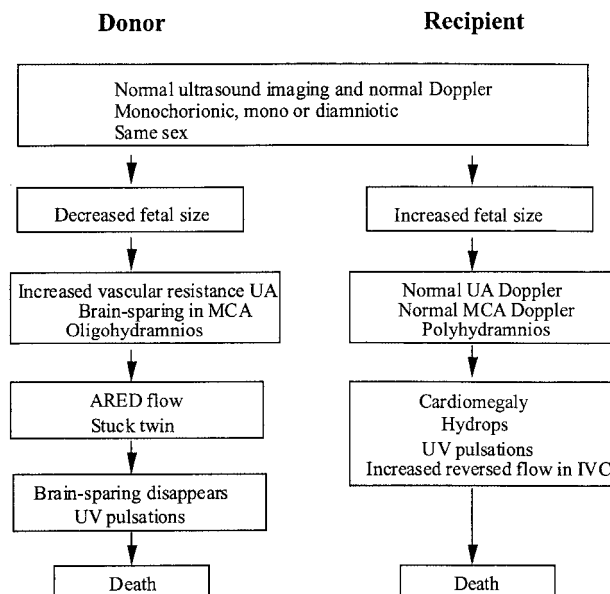


Fig. 1. A schematic time sequence of characteristic ultrasound findings in twin-to-twin transfusion syndrome (TTS). ARED: absent or reversed end diastolic in the umbilical artery; UV: umbilical vein; MCA: middle cerebral artery; IVC: inferior vena cava.

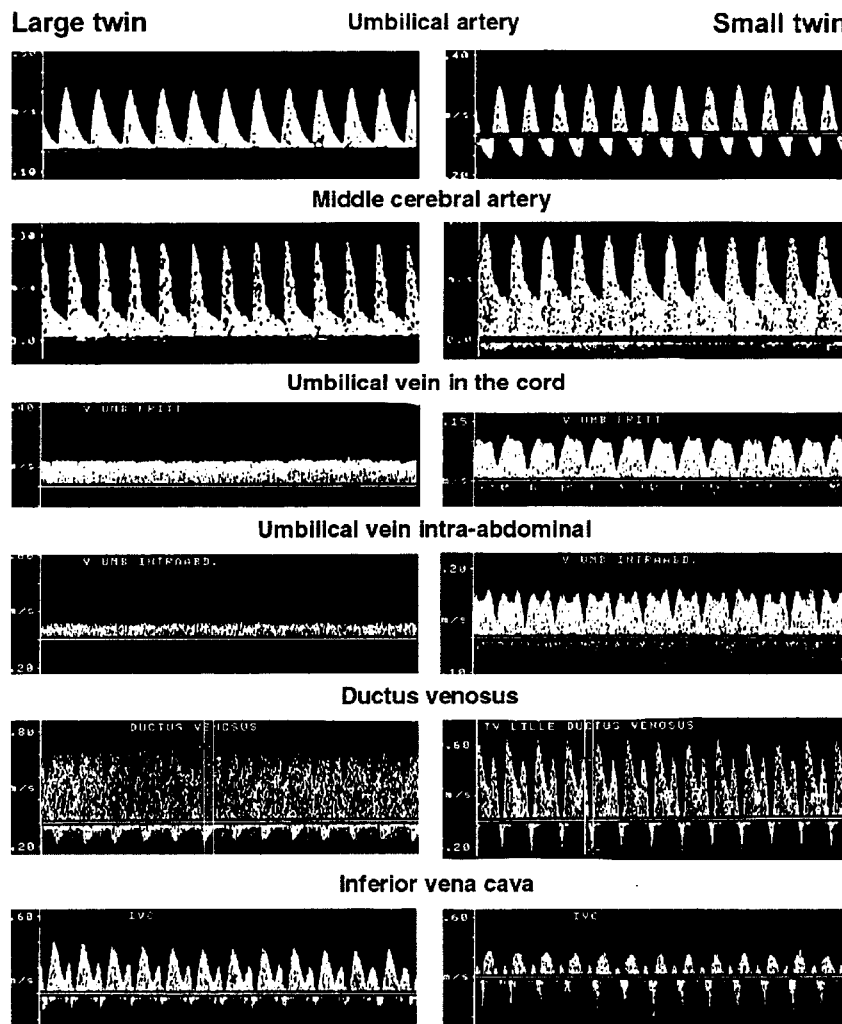


Fig. 2. Blood velocity recording at the last examination before intrauterine death of the small twin. Blood flow in the large twin is normal, but in the smaller twin reversal of flowing diastole is obvious in the umbilical artery, brain sparing in the middle cerebral artery, pulsations in umbilical venous flow, reversal of flow in ductus venosus and inferior vena cava.

in the larger. At 26 weeks of gestation, discordance in growth between twins was -8% (915 g) vs. -69% (318 g), respectively, from reference curves. Doppler velocimetry showed similar results to those presented at 25 weeks. Similar Doppler velocimetry results were recorded until 29 weeks of pregnancy, when the smaller twin was deemed to have died. Doppler velocimetry in the survivor was normal. The pregnancy continued uneventfully until 34 weeks of gestation, when a healthy girl weighing 2210 g, Apgar score 9–10, was born prematurely vaginally. The dead fetus, also a girl, had a velamentous cord placental insertion. The neonatal period was uneventful.

Discussion

Early ultrasound examination in twin pregnancy is of great value. The 'lambda sign' can define dichorionicity and thus exclude the possibility of TTS later in gestation. Thick amniotic membranes also suggest dichorionicity, and different gender will confirm the fetus to be dizygotic. Diagnosis of discordant twin size is thus not a clinical problem with modern ultrasound

equipment. However, differentiating between TTS and IUGR in one fetus is not so simple at mid-gestation if a dizygotic twin pregnancy cannot be confirmed. The likelihood of TTS increases, however, when oligo- and/or polyhydramnios develops. Hydrodramnios is also a characteristic sign of congestive heart failure in the large TTS fetus. Ultrasound examination of the larger twin can thus differentiate between TTS and true IUGR in the smaller twin.

Umbilical artery Doppler velocimetry can diagnose severe vascular resistance, which can be seen in the smaller twin in both IUGR and TTS. Signs of brain sparing in the MCA might also be seen in both twins. Venous Doppler flow examination in the larger twin can, however, distinguish between IUGR and TTS. In a case of a true IUGR, due to poor placental function or chromosomal aberration, venous blood flow in the larger twin is normal. However, abnormal flow in the ductus venosus and pulsations in the umbilical vein are characteristic signs of imminent fetal heart failure in TTS due to circulation overload in the recipient.

Blood flow in the fetal systemic veins pulsates normally in response to changes in central venous pressure. Umbilical ve-

nous flow is, however, even and without pulsations. By the development of the fetal heart failure, both due to overload as in TTS or during hypoxia as in IUGR, blood velocity pulsations in the venous system increase in strength. Especially reversal of flow during atrial contraction is magnified and can cause a reversal of flow in the ductus venosus and cause pulsations in the umbilical vein (Fig. 2). These findings are associated with increased perinatal mortality (6).

The Doppler ultrasound signs of imminent fetal death given in Fig. 2 lasted for 3 weeks. This is in agreement with our experience from the early third trimester of pregnancy (< 29 weeks) and in accordance with findings by Arduini et al. (7). A more mature fetus might not withstand this stress for such a long time. In our experience, a fetus of more than 34 weeks of gestation can usually not withstand similar circulation alternations for more than 3 days before intrauterine demise.

Signs of fetal brain sparing in the middle cerebral artery are known to disappear prior to fetal death (8). This might be due to cerebral autoregulation failure, cerebral edema, or heart failure. This reversal of compensation seems to be a sudden and a late sign of fetal compromise with poor prognosis (9). In the present study, the fetus was examined weekly. Signs of brain sparing were observed at the last examination. Reversal of compensation might thus have occurred later.

The clinical dilemma is whether and when to intervene – or not. If the larger twin is judged viable in TTS, the pregnancy should be terminated by caesarean section before the smaller twin dies, in order to minimize deleterious effects on the larger or recipient after death of the smaller twin. Longitudinal Doppler examination can thus be of value for predicting fetal death and timing of delivery in TTS.

In IUGR in one fetus, letting the growth-restricted fetus die *in utero* is of minimal risk for the larger twin. Passing 25 weeks of gestation is an obvious cause of anxiety. The clinical dilemma is trying to rescue one or both. Performing a caesarean section after 25 weeks might result in a small, severely injured newborn due to protracted hypoxemia. The unstressed larger twin might also suffer severely in the neonatal period, with varying degree of morbidity due to immaturity. In the present case, the parents were informed of the different options and chose to focus on one healthy baby. The decision is controversial and difficult for all parties concerned.

In conclusion, this case report illustrates characteristic blood velocity patterns in a dying fetus. The experience from this case report might also be of value in distinguishing between TTS and IUGR of a fetus.

References

1. Gudmundsson S, Marsal K. Blood velocity waveforms in fetal aorta and umbilical artery as predictors of fetal outcome – a comparison. *Am J Perinatol* 1991; 8: 1–6.
2. Jones JM, Sbarra AJ, Cetrulo CL. Antepartum management of twin gestation. *Clin Obstet Gynecol* 1990; 33: 32–41.
3. Manlan G, Scott KE. Contribution of twin pregnancy to perinatal mortality and fetal growth retardation; reversal of growth retardation after birth. *Can Med Assoc J* 1978; 118: 365–8.
4. Gudmundsson S, Tulzer G, Huhta JC, Marsal K. Venous Doppler in the fetus with absent end-diastolic flow in the umbilical artery. *Ultrasound Obstet Gynecol* 1996; 7: 262–7.
5. Gudmundsson S, Huhta JC, Wood DC, Tulzer G, Cohen AW, Weiner S. Venous Doppler ultrasonography in the fetus with non-immune hydrops. *Am J Obstet Gynecol* 1991; 164: 33–97.
6. Hofstaetter C, Dubiel M, Gudmundsson S. Two types of umbilical venous pulsations and outcome of high-risk pregnancy. *Early Human Dev* 2001; 61: 111–7.
7. Arduini D, Rizzo G, Romanini C. The development of abnormal heart rate patterns after absent end-diastolic velocity in umbilical artery: analysis of risk factors. *Am J Obstet Gynecol* 1993; 168: 43–50.
8. Weiner Z, Farmakides G, Schulman H, Penny B. Central and peripheral hemodynamic changes in fetuses with absent end-diastolic velocity in umbilical artery: correlation with computerized fetal heart rate pattern. *Am J Obstet Gynecol* 1994; 170: 509–15.
9. Konje JC, Bell SC, Taylor DJ. Abnormal Doppler velocimetry and blood flow Volume in the middle cerebral artery in very severe intrauterine growth restriction: is the occurrence of reversal of compensatory flow too late? *Br J Obstet Gynaecol* 2001; 108: 973–9.

Address for correspondence:

Saemundur Gudmundsson
University of Lund
Department of Obstetrics and Gynecology
University Hospital MAS
S – 205 02, Malmö
Sweden