



# LUND UNIVERSITY

## Lung fractional moving blood volume in normally grown and growth restricted foetuses.

Hernandez-Andrade, Edgar; Thuring, Ann; Jansson, Tomas; Lingman, Göran; Marsal, Karel

*Published in:*  
Clinical Physiology and Functional Imaging

*DOI:*  
[10.1111/j.1475-097X.2004.00532.x](https://doi.org/10.1111/j.1475-097X.2004.00532.x)

2004

[Link to publication](#)

*Citation for published version (APA):*  
Hernandez-Andrade, E., Thuring, A., Jansson, T., Lingman, G., & Marsal, K. (2004). Lung fractional moving blood volume in normally grown and growth restricted foetuses. *Clinical Physiology and Functional Imaging*, 24(2), 69-74. <https://doi.org/10.1111/j.1475-097X.2004.00532.x>

*Total number of authors:*  
5

### General rights

Unless other specific re-use rights are stated the following general rights apply:  
Copyright and moral rights for the publications made accessible in the public portal are retained by the authors and/or other copyright owners and it is a condition of accessing publications that users recognise and abide by the legal requirements associated with these rights.

- Users may download and print one copy of any publication from the public portal for the purpose of private study or research.
- You may not further distribute the material or use it for any profit-making activity or commercial gain
- You may freely distribute the URL identifying the publication in the public portal

Read more about Creative commons licenses: <https://creativecommons.org/licenses/>

### Take down policy

If you believe that this document breaches copyright please contact us providing details, and we will remove access to the work immediately and investigate your claim.

LUND UNIVERSITY

PO Box 117  
221 00 Lund  
+46 46-222 00 00

# Lung fractional moving blood volume in normally grown and growth restricted fetuses

Edgar Hernandez-Andrade<sup>1</sup>, Ann Thuring-Jönsson<sup>1</sup>, Tomas Jansson<sup>2</sup>, Göran Lingman<sup>1</sup> and Karel Maršál<sup>1</sup>

Departments of <sup>1</sup>Obstetrics and Gynecology, and <sup>2</sup>Electrical Measurements, University of Lund, Lund, Sweden

## Summary

### Correspondence

Edgar Hernandez-Andrade, Department of Obstetrics and Gynecology, Lund University Hospital, SE 221 85 Lund, Sweden  
E-mails: edgar.hernandez-andrade@gyn.lu.se; edgarhandrade@aol.com

### Accepted for publication

Received 22 September 2003;  
accepted 7 November 2003

### Key words

foetal lung; fractional moving blood volume; intrauterine growth restriction; mean pixel intensity; power Doppler ultrasound; respiratory complications

**Objective:** To examine foetal lung blood perfusion using power Doppler ultrasound (PDU) and to compare fractional moving blood volume (FMBV) and mean pixel intensity (MPI) estimations in the lungs of normally grown (NG) fetuses and fetuses with intrauterine growth restriction (IUGR) and also to correlate foetal lung FMBV and MPI with respiratory complications after birth.

**Methods:** Lungs of 47 NG and 25 IUGR fetuses after 32 weeks of gestation were examined with PDU. FMBV and MPI were estimated in a defined region in the posterior part of the foetal lung closest to maternal abdominal wall. FMBV and MPI were correlated to foetal weight deviation and gestational age. Perinatal outcome and respiratory complications after birth were recorded in both groups.

**Results:** There were significantly lower FMBV and MPI values in IUGR than in NG fetuses. The overall variation was lower for FMBV than for MPI. There was a slightly higher correlation between FMBV and foetal weight deviation [ $r = 0.33$ , 95% confidence intervals (CI) 0.11–0.52] than between MPI and foetal weight deviation ( $r = 0.26$ , 95% CI 0.03–0.46). There was no significant correlation between FMBV or MPI and gestational age. No differences between the groups were found in the rate of respiratory complications, and they were not correlated either to the FMBV or MPI.

**Conclusion:** FMBV and MPI, estimated from the PDU signals of foetal lung circulation, showed lower values in third-trimester pregnancies complicated by IUGR. The frequency of neonatal respiratory complications was not increased in cases with low pulmonary FMBV and MPI values.

## Introduction

Normal foetal lung development comprises proliferation and growth of airways and blood vessels throughout pregnancy. The development of oxygen interchange unit is closely related to the blood supply to foetal lung (Merkus *et al.*, 1996). Intrauterine growth restriction (IUGR) is associated with changes in foetal organ blood flow distribution with preferential supply of blood to the brain, heart, adrenals and liver, and reduction of the blood flow to the other organs (Maršál, 2002). However, it is uncertain whether IUGR can modify the foetal lung vascular development or its blood flow supply.

Power Doppler ultrasound (PDU) has been suggested as a non-invasive method for estimation of organ blood movement (Rubin *et al.*, 1995). PDU provides the possibility to evaluate slow blood movement in a defined region of interest, offering a better reflection of blood perfusion than measurement of blood velocities. Calculation of the mean pixel intensity (MPI) was the

first method for quantification of PDU signals from foetal organs (Dubiel *et al.*, 1997a). However, scanning depth was shown to have a large impact on recorded PDU signals. By using a normalization procedure (Rubin *et al.*, 1997), the effect of depth on PDU signals can be compensated for, giving a fractional moving blood volume (FMBV) which is a more accurate estimate of foetal organ blood perfusion than MPI (Hernandez-Andrade *et al.*, 2003).

The aim of this study was to evaluate lung blood perfusion with PDU in normally grown (NG) and IUGR fetuses after 32 weeks of gestation using FMBV and MPI estimations. In addition, the FMBV and MPI values were correlated with neonatal respiratory complications after birth.

## Methods

Lung blood perfusion of 47 NG fetuses and 25 IUGR fetuses was evaluated after 32 weeks of gestation. Suspected IUGR was

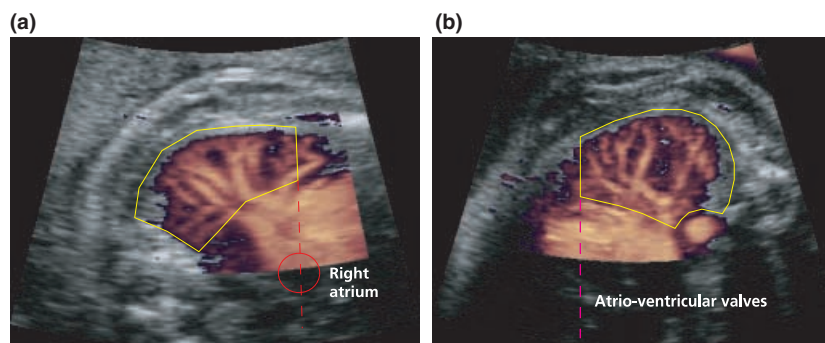
defined as an estimated foetal weight more than 2 SD ( $\geq 22\%$ ) below the mean of reference population (Maršál et al., 1996). Clinical complications associated with IUGR were: pregnancy-induced hypertension (defined as a systolic and/or diastolic blood pressure increase of at least 30 and 15 mmHg, respectively, after 20 weeks of gestation) or pre-eclampsia (blood pressure  $\geq 140/90$  mmHg and proteinuria  $>0.3$  g l<sup>-1</sup>) ( $n = 12$ ), oligohydramnios (amniotic fluid index  $<50$  mm) ( $n = 3$ ), and diabetes mellitus ( $n = 1$ ). In nine pregnancies there were no other clinical complications than suspicion of IUGR. The mean deviation from the expected foetal weight in the IUGR group was  $-26\%$  (range  $-22$  to  $-41\%$ ) and in the NG group  $-11\%$  (range  $+29$  to  $-21\%$ ). The median maternal age was 32 years for both groups (range 19–42 and 22–42 years for the NG and IUGR groups, respectively), the median parity was 0 for both groups (range 0–4 and 0–3 in the NG and IUGR groups, respectively), and the median gestational age at the time of the study was 34 weeks + 0 days (range 32 + 0 to 41 + 5) in the NG group and 33 weeks + 4 days (range 32 + 0 to 40 + 2) in the IUGR group.

Foetal lung PDU evaluation was performed using an ATL HDI-5000 (ATL Ultrasound; Philips Medical Systems, Bothell, WA, USA) ultrasound equipment with a 7–4-MHz curve array probe. A standardized image of a cross-sectional plane of the foetal thorax through the inter-costal space at the level of the four-chamber view of the heart was obtained. The foetal lung closest to the anterior maternal wall was examined. The PDU colour box was placed in the posterior half of the foetal thorax where the lung vessels were clearly visualized and the box was kept as small as possible to include most of the lung and minimum of flash artefacts from the heart. PDU settings were maintained identical for all examinations: high sensitivity, medium persistence, normal line density, normal image display, maximum dynamic range, high frame rate, high wall filter, 79–81% of gain and a pulse repetition frequency of 500 Hz. The mechanical and thermal indices were kept below 1.0. Recordings were performed during absence of foetal body and breathing movements and at voluntarily suspended maternal respiration.

The ultrasound digital data was transferred to a computer program (HDI-Lab 1.81; Philips Medical Systems) with a custom-designed plug-in for HDI-Lab. Six consecutive good-quality frames in each sequence were evaluated off-line. The region of interest (ROI) for each foetal lung was selected as follows: for the right lung, the baseline was defined as an extension of an imaginary line crossing the right atrium, the crux of the inter-ventricular and inter-atrial septa and prolonged to the left ventricle (Fig. 1a). For the left lung, the baseline was an extension of an imaginary line at the level of insertion of the atrio-ventricular valves (Fig. 1b). The lung tissue posterior to these boundaries was evaluated. The ROI was kept identical for all analysed frames. FMBV was estimated in each frame according to the algorithm proposed by Rubin et al. (1997). MPI was calculated as the average pixel intensity within the ROI in each frame. The mean values of both estimations were calculated for each sequence.

Perinatal outcome was recorded in both groups including the gestational age at delivery, preterm delivery ( $<37$  weeks), delivery mode, operative delivery for foetal distress (ODFD; indicated by an abnormal Doppler velocimetry of the umbilical artery and/or an abnormal antenatal or intrapartum cardiographic (CTG) trace and/or foetal scalp pH  $<7.20$ ), birth weight deviation from the expected value in percentage, weight small-for-gestational age (SGA; birth weight below mean  $-2$  SD of the reference population) (Maršál et al., 1996), Apgar score at 1 and 5 min and umbilical vein blood pH. Respiratory complications in the neonatal period were also registered.

Descriptive statistics were used for both groups and the differences tested with Wilcoxon–Mann–Whitney and chi-squared tests, as appropriate. A  $P$  value  $<0.05$  was considered significant. The variances of the FMBV and MPI results in the respective groups were given as coefficients of variation (CV). FMBV and MPI values were plotted against the percentage of foetal weight deviation (WD) and against gestational age (GA) at the time of the ultrasound study, and linear regression analysis and Pearson's correlation coefficient were calculated.



**Figure 1** Definition of the region of interest for fractional moving blood volume estimation in foetal lungs. In the right foetal lung (a) the baseline was defined as an extension of an imaginary line crossing the right atrium, the crux of the interventricular and interatrial septa and prolonged to the left ventricle. For the left lung (b) the baseline was an extension of an imaginary line at the level of insertion of the atrio-ventricular valves. The imaginary plane was that used for a four-chamber view of foetal heart.

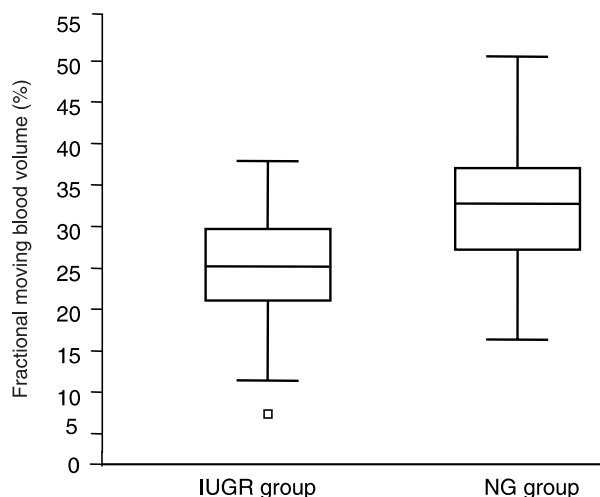
## Results

The perinatal outcome in both groups is presented in Table 1. Significant differences were found in the gestational age at delivery, birth weight, number of SGA newborns, and ODFD. Nine pregnancies of the IUGR group had ODFD, in seven of them an emergency Caesarean section was performed because of an abnormal CTG during labour, and in two, a ventouse extraction. All four pregnancies of the NG group with ODFD had an emergency Caesarean section due to an abnormal CTG during labour. In the IUGR group, three foetuses were delivered with elective Caesarean section because of the severity of the growth restriction. In the NG group one woman had an elective Caesarean section because of foetal macrosomy (birthweight 5000 g).

The results of foetal lung PDU evaluation showed higher values of FMBV ( $P = 0.0001$ ; Fig. 2) and MPI ( $P = 0.0003$ ; Fig. 3) in the NG than in IUGR foetuses. The CV was lower for FMBV (0.22 and 0.29) than for MPI (0.34 and 0.53) in the NG and IUGR groups, respectively.

For the total material, the linear regression equation for FMBV and foetal WD (%) was  $FMBV = 0.1893WD + 32.175$  ( $r = 0.33$ , 95% CI 0.11–0.52;  $P = 0.004$ ) (Fig. 4), and for MPI and WD,  $MPI = 0.0319WD + 4.851$  ( $r = 0.26$ , 95% CI 0.03–0.46;  $P = 0.02$ ) (Fig. 5). There was no significant correlation between either FMBV or MPI versus gestational age ( $P = 0.23$  and  $P = 0.37$ , respectively).

Respiratory complications were observed in three cases in the NG group and in two cases of the IUGR group. In the NG group, two newborns presented transitory tachypnea and one recurrent apnea. Their FMBV and MPI values did not differ from the values of the rest of the group. In the IUGR group, one newborn developed respiratory distress syndrome with low FMBV and MPI values (18.0% and 1.9 dB, respectively) and one transitory tachypnea with FMBV and MPI values of 38.8% and 7.2 dB, respectively.



**Figure 2** Box plot of foetal lung fractional moving blood volume values in the normally grown (NG) ( $n = 47$ ) and IUGR ( $n = 25$ ) groups ( $P < 0.0001$ ) (median, quartiles, 5th and 95th percentiles).

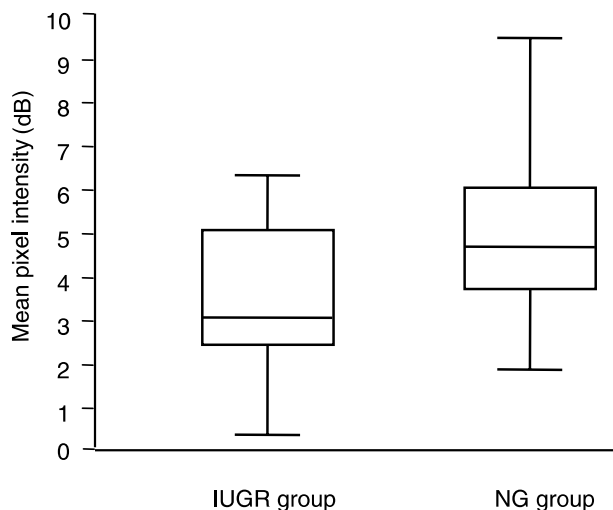
In one of the foetuses of the NG group, the Apgar scores at 1 and 5 min, were 2 and 6, respectively. This foetus had a normal delivery at 41 + 1 weeks of gestation with a normal umbilical vein blood pH value (7.22). FMBV and MPI values were lower than in the rest of the group (17.6% and 1.9 dB, respectively). The newborn did not develop any respiratory or other clinical complications after birth.

From seven cases in the IUGR group who had an acute Caesarean section, five were preterm deliveries, and only one of them developed respiratory complications after birth. In this case, delivery occurred at 34 + 2 weeks with birth weight 1600 g (34% below the expected weight), and umbilical vein pH 7.12. An emergency Caesarean section was performed because of an abnormal cardiotocographic trace and the newborn developed respiratory distress syndrome (RDS). In

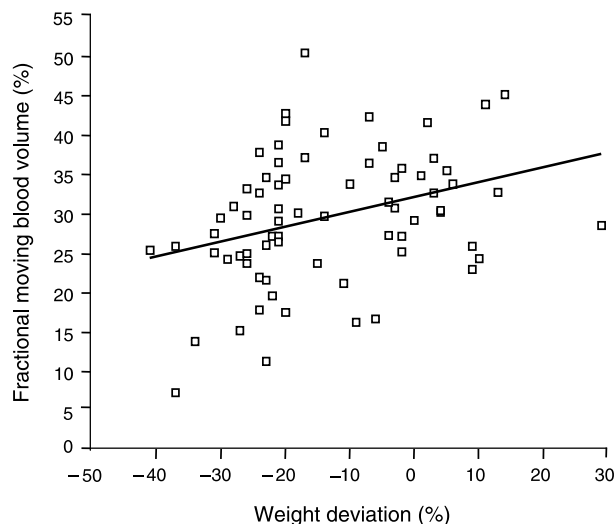
**Table 1** Perinatal outcome.

	Normally grown group ( $n = 47$ )		IUGR group ( $n = 25$ )		Significance of difference ( $P$ )
	Median or mean	Range	Median or mean	Range	
Gestational age at delivery (weeks + days) (median)	39 + 5	32 + 3 to 42 + 5	38 + 1	32 + 0 to 41 + 4	0.007
Weight at delivery (g) (mean)	3324	1230–5000	2585	1415–3425	0.001
Apgar 1 min (median)	9	2–10	9	6–10	ns
Apgar 5 min (median)	10	6–10	10	8–10	ns
pH umbilical vein (mean)	7.25	7.09–7.42	7.26	7.09–7.34	ns
	N		n		
SGA	4		19		0.0005
ODFD	4		9		0.03
Preterm deliveries	7		9		ns
Respiratory complications	3		2		ns

IUGR, intrauterine growth restriction group; SGA, small-for-gestational age; ODFD, operative delivery for foetal distress; ns, not significant.



**Figure 3** Box plot of mean pixel intensity in the normally grown (NG) ( $n = 47$ ) and IUGR ( $n = 25$ ) groups ( $P < 0.001$ ) (median, quartiles, 5th and 95th percentiles).



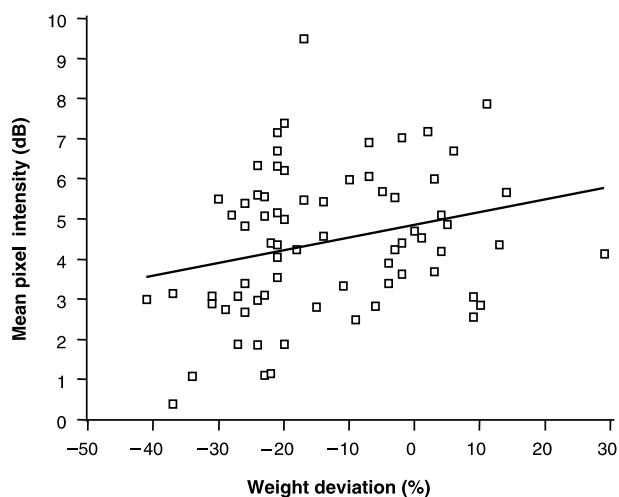
**Figure 4** Fractional moving blood volume (FMBV) plotted against the foetal weight deviation in the total material ( $n = 72$ ) ( $FMBV = 0.1893WD + 32.175$ ).

the NG group, all four foetuses who had an acute Caesarean section were delivered preterm, and two newborns developed respiratory complications.

## Discussion

Foetal lung blood circulation estimated with PDU showed reduced FMBV and MPI values in growth-restricted foetuses when compared with normally grown foetuses after 32 weeks of gestation. Low FMBV and MPI values were not associated with respiratory complications after birth.

During the foetal development, the lung blood vessels develop in close relation with the gas-exchanging unit. At 16 weeks, the branching of the conducting airways and the final



**Figure 5** Mean pixel intensity (MPI) plotted against the foetal weight deviation in the total material ( $n = 72$ ) ( $MPI = 0.0319WD + 4.851$ ).

number of the pre-acinar arteries is completed. Later, these arteries grow in length and diameter but do not increase in number. Between 16 and 28 weeks, an increment in the number of intra-acinar arteries is observed in close relation with the alveolar units (Hislop & Reid, 1972; Levin et al., 1976; Hislop, 2002). The final stage of lung vascular development is reached at around 28 weeks of gestation. After 28 weeks, lung maturation is mainly related to the further development of alveoli and surfactant production by pneumocytes. Later in pregnancy, changes in the lung blood flow are mainly related to the lung peripheral resistance (Laudy, 2000).

Several attempts have been made to evaluate the foetal lung circulation. Laudy et al. (1997), using PDU, reported a reduction in the systolic/diastolic ratio and an increment in the peak diastolic velocity and in the diastolic integral velocity with no changes in the pulsatility index (PI) in the main branches of pulmonary artery with advancing gestation. Similarly, Achiron et al. (1998) reported no changes in the PI of the right pulmonary artery during pregnancy, suggesting that the foetal lung circulation remains as a high resistance circulation despite maturational changes. Furthermore, Dubiel et al. (1997a) using PDU showed no changes in MPI intensity throughout gestation in the right foetal lung circulation. This is in accordance with our results where there was no significant association between FMBV or MPI with gestational age after 32 weeks of gestation. Interestingly, an increment in PDU signals from the foetal lung after steroid administration has been reported, suggesting an enhancement in lung blood perfusion of preterm foetuses (Dubiel et al., 1997b).

Our results showed a reduction in the lung fractional moving blood volume in foetuses suffering from IUGR. This is in accordance with Rizzo et al. (1996), who reported an increment in the resistance index in peripheral pulmonary arteries of foetuses complicated with IUGR. In our study there was also a significant correlation between the percentage of foetal WD at the time of ultrasound scan and the FMBV and MPI. Although

FMBV and MPI were able to show significant differences in the lung fractional blood movement between IUGR and normally grown fetuses, there was less variability in the FMBV results. FMBV comprises a two-step normalization procedure, which partially compensates for depth dependence and attenuation of the PDU signals, and for the rouleaux formation of the blood cells in the vessels. However, whether rouleaux is actually formed in foetal blood is not known (Welsh et al., 2001). If not, this may have an effect on the normalization procedure, especially in the second step of the algorithm, which, theoretically, is based on the assumption of rouleaux formation, with an increased variance in the FMBV estimates as consequence.

Intrauterine growth restriction caused by placental insufficiency is one of the main complications during pregnancy. The hypoxic insult induces changes in the blood flow supply to foetal organs maintaining or increasing the blood flow to the brain, liver, heart and adrenals and reducing the blood flow to the muscle, fat tissue and bones (Maršál, 2002). Mari & Deter (1992) reported increased diastolic flow in the middle cerebral artery and Baschat et al. (1998) reported increased diastolic flow in the right coronary artery in IUGR fetuses. In addition, a reduction in the femoral artery diastolic flow in growth-restricted fetuses has been reported (Mari, 1991). IUGR also induces release of hormones, e.g. cortisol, which promote foetal organ maturation (Mesiano & Jaffe, 1999). Therefore, IUGR might be seen as an adaptive-survival process that allows the foetus to reach further organ maturation and a more advanced gestational age.

During the normal foetal development, several organs complete vascular maturation at different times. As lung vascular proliferation is pronounced at around 28 weeks, it is possible that a reduction in blood flow after 32 weeks does not have a deep impact on the neonatal respiratory function. Lewis et al. (1976) showed that the foetal pulmonary circulation reacts differently to hypoxic insults according to the gestational age. They evaluated foetal lambs at around 100 days of gestation (0.66 of pregnancy) and showed an increment in the pulmonary vascular resistance related to reduced oxygen concentration. The same effect was not observed in near-term foetal lambs. They suggested that later in pregnancy, various hormonal pathways e.g. adrenocorticotrophic hormone (ACTH), contribute to maintain the normal pulmonary resistance when a hypoxic insult is present. This is in accordance with Murphy et al. (1986) who reported no changes in the vascular pulmonary resistance in relation to chronic hypoxemia in term guinea pigs.

In contrast, different authors reported changes in the foetal lung development in relation to chronic hypoxia. Hooper et al. (1991), showed a reduced lung DNA synthesis, and cell division in presence of intrauterine chronic hypoxia and, Wignarajah et al. (2002) reported a reduction in the number of bronchial sub-mucosal glands in IUGR foetal lambs. In addition, Joyce et al. (2001) described an increment in oxygen consumption and a reduction in pulmonary oxygen diffusion capacity in the neonatal period of growth restricted foetal lambs and, Harding et al. (2000) noted that in presence of late IUGR, neither lung weight, lung liquid concentration nor lung volume were

affected when they were corrected for total body weight; however, the air–blood barrier was thicker in growth-restricted newborn lambs.

The relationship between foetal lung vascular development and hypoxemia appears to be related to the gestational age. Gortner et al. (1999), reported no differences in the severity of RDS, time of intubation or surfactant administration between SGA and adequate-for-gestational age (AGA) newborns; however, prolonged nasal continuous positive airway pressure treatment, supplemental oxygen therapy and chronic lung disease were seen more frequently in SGA newborns. Ley et al. (1997) showed a significant increment in ventilator treatment, RDS, and application of surfactant in SGA newborns at 25–28 weeks, and a lower value in the fraction of inspired oxygen within the first 12 h of life in SGA than in AGA newborns at 29–32 weeks of gestation. Long-term respiratory sequels of IUGR have been explored in twin pregnancies where one twin was growth restricted (Nikolajev et al., 1998). The results showed an increment in oxygen consumption and a reduced ventilatory capacity in the twin affected with IUGR. The impact of IUGR on the lung maturation process seems to be mainly related to the severity and onset of the IUGR and the association with preterm delivery.

The reduced lung blood perfusion observed in IUGR fetuses after 32 weeks of gestation might be part of the redistribution process caused by hypoxia in which the blood flow to vital organs is maintained. As lung maturation is more intense before 32 weeks, a reduction in blood flow after that gestational age does not necessarily imply an abnormal respiratory function at birth.

Fractional moving blood volume is a potential tool to follow the foetal organ vascularity, and it should be evaluated further in normal and complicated pregnancies before clinical application. As seen in this study, the FMBV method compensates for depth and other factors influencing the power Doppler signal and it is superior to the MPI calculation (Jansson et al., 2003). FMBV may be considered as a kind of perfusion index that can be related to a reference population, in much the same way as various flow waveform indices in use today.

## Acknowledgments

Edgar Hernandez-Andrade was supported by the Mexican National Council for Science and Technology (CONACyT) and the National Institute of Perinatal Medicine (INPer) in Mexico City. The study was supported by the Swedish Research Council (grant number 5980). Also, the Swedish Foundation for Strategic Research (SSF, project CORTECH), is acknowledged for financial support.

## References

- Achiron R, Heggesh J, Mashiach S, Lipitz S, Rotstein Z. Peripheral right pulmonary artery blood flow velocimetry: Doppler sonography study of normal and abnormal fetuses. *J Ultrasound Med* (1998); **17**: 687–692.

- Baschat A, Gembruch U, Harman C. Coronary blood flow in fetuses with intrauterine growth restriction. *J Perinat Med* (1998); **26**: 143–156.
- Dubiel M, Gudmundson S, Kozber H et al. Lung tissue color Doppler energy in the prediction of lung maturity. *Arch Perinat Med* (1997a); **3**: 55–59.
- Dubiel M, Gudmundson S, Pirhonen J, Brebowicz G, Maršál K. Beta-methasone treatment and fetal lung perfusion evaluated with color Doppler energy imaging. *Ultrasound Obstet Gynecol* (1997b); **10**: 272–276.
- Gortner L, Wauer R, Stock G et al. Neonatal outcome in small for gestational age infants: do they really better? *J Perinat Med* (1999); **27**: 484–489.
- Harding R, Cock M, Louey S et al. The compromised intra-uterine environment: implications for future lung health. *Clin Exp Pharmacol Physiol* (2000); **27**: 965–974.
- Hernandez-Andrade E, Jansson T, Ley D et al. Validation of fractional moving blood volume measurement with power Doppler ultrasound in an experimental sheep model. *Ultrasound Obstet Gynecol* (2003); in press.
- Hislop A. Airway and blood vessel interaction during lung development. *J Anat* (2002); **201**: 325–334.
- Hislop A, Reid L. Intra-pulmonary arterial development during fetal life-branching pattern and structure. *J Anat* (1972); **113**: 35–48.
- Hooper S, Bocking A, White S, Challis J, Han V. DNA synthesis is reduced in selected fetal tissues during prolonged hypoxemia. *Am J Physiol* (1991); **261**: R508–R514.
- Jansson T, Hernandez-Andrade E, Lingman G, Maršál K. Estimation of fractional moving blood volume in fetal lung using power Doppler ultrasound. Methodological aspects. *Ultrasound Med Biol* (2003); **29**: 1551–1559.
- Joyce B, Louey S, Davey M, Cock M, Hooper S, Harding R. Compromised respiratory function in postnatal lambs after placental insufficiency and intrauterine growth restriction. *Pediatr Res* (2001); **50**: 641–649.
- Laudy J. Doppler ultrasonography of the human fetal pulmonary circulation. Ph.D. thesis (2000); pp. 18–26. Erasmus University, Rotterdam, The Netherlands.
- Laudy J, de Ridder M, Wladimiroff J. Doppler velocimetry in branch pulmonary arteries of normal human fetuses during the second half of gestation. *Pediatr Res* (1997); **41**: 897–901.
- Levin D, Rudolph A, Heymann M, Phibbs R. Morphological development of the pulmonary vascular bed in fetal lambs. *Circulation* (1976); **53**: 144–151.
- Lewis A, Heymann M, Rudolph AM. Gestational changes in pulmonary vascular responses in fetal lambs in utero. *Circ Res* (1976); **39**: 536–541.
- Ley D, Wide-Svensson D, Lindroth M, Svenningsen N, Maršál K. Respiratory distress syndrome in infants with impaired intrauterine growth. *Acta Paediatr* (1997); **10**: 1090–1096.
- Mari G. Arterial blood flow velocity waveforms of the pelvis and lower extremities in normal and growth-retarded fetuses. *Am J Obstet Gynecol* (1991); **165**: 143–151.
- Mari G, Deter R. Middle cerebral artery flow velocity waveforms in normal and small-for-gestational-age fetuses. *Am J Obstet Gynecol* (1992); **166**: 1262–1270.
- Maršál K. Intrauterine growth restriction. *Curr Opin Obstet Gynecol* (2002); **14**: 127–135.
- Maršál K, Persson P, Larsen T, Lilja H, Selbing A, Sultan B. Intrauterine growth curves based on ultrasonically estimated foetal weights. *Acta Paediatr* (1996); **85**: 843–848.
- Merkus P, ten Have-Opbroek A, Quanjer P. Human lung growth: a review. *Pediatr Pulmonol* (1996); **21**: 383–397.
- Mesiano S, Jaffe R. Fetal adrenals. In: *Encyclopedia of Reproduction*, Vol. 2, 1st edn (1999); pp. 265–271. Academic Press, USA.
- Murphy J, Aronovitz M, Reid L. Effects of chronic in utero hypoxia on the pulmonary vasculature of the newborn guinea pig. *Pediatr Res* (1986); **20**: 292–295.
- Nikolajev K, Heinonen K, Hakulinen A, Lansimies E. Effects of intrauterine growth retardation and prematurity on spirometric flow values and lung volumes at school ages in twin pairs. *Pediatric Pulmonol* (1998); **25**: 367–370.
- Rizzo G, Capponi A, Chaoui R, Taddei F, Arduini D, Romanini C. Blood flow velocity waveforms from peripheral pulmonary arteries in normally grown and growth-retarded fetuses. *Ultrasound Obstet Gynecol* (1996); **8**: 87–92.
- Rubin J, Bude R, Carson P, Bree R, Adler R. Power Doppler US: a potentially useful alternative to mean frequency-based color Doppler US. *Radiology* (1995); **190**: 853–856.
- Rubin J, Bude R, Fowlkes J, Spratt R, Carson P, Adler R. Normalizing fractional moving blood volume estimates with power Doppler US: defining a stable intravascular point with the cumulative power distribution function. *Radiology* (1997); **205**: 757–765.
- Welsh J, Rubin J, Fowlkes B, Fisk N. Quantification of fetal power Doppler: determination of the intravascular standardization point. *Ultrasound Obstet Gynecol* (2001); **18s1**: F12.
- Wignarajah D, Cock M, Pinkerton K, Harding R. Influence of intrauterine growth restriction on airway development in fetal and postnatal sheep. *Pediatr Res* (2002); **51**: 681–688.