



LUND UNIVERSITY

Continent urinary tract reconstruction - the Lund experience.

Månsson, Wiking; Davidsson, Thomas; Könyves, J; Liedberg, Fredrik; Månsson, Åsa; Wullt, Björn

Published in:
BJU International

DOI:
[10.1046/j.1464-410X.2003.04330.x](https://doi.org/10.1046/j.1464-410X.2003.04330.x)

2003

[Link to publication](#)

Citation for published version (APA):

Månsson, W., Davidsson, T., Könyves, J., Liedberg, F., Månsson, Å., & Wullt, B. (2003). Continent urinary tract reconstruction - the Lund experience. *BJU International*, 92(3), 271-276. <https://doi.org/10.1046/j.1464-410X.2003.04330.x>

Total number of authors:
6

General rights

Unless other specific re-use rights are stated the following general rights apply:

Copyright and moral rights for the publications made accessible in the public portal are retained by the authors and/or other copyright owners and it is a condition of accessing publications that users recognise and abide by the legal requirements associated with these rights.

- Users may download and print one copy of any publication from the public portal for the purpose of private study or research.
- You may not further distribute the material or use it for any profit-making activity or commercial gain
- You may freely distribute the URL identifying the publication in the public portal

Read more about Creative commons licenses: <https://creativecommons.org/licenses/>

Take down policy

If you believe that this document breaches copyright please contact us providing details, and we will remove access to the work immediately and investigate your claim.

LUND UNIVERSITY

PO Box 117
221 00 Lund
+46 46-222 00 00

Reconstructive Urology

The Department of Urology in Lund, Sweden, has a long association with innovations in reconstructive urology. The authors from that department describe their experience over a long period with orthotopic bladder substitution and continent cutaneous urinary diversion. They conclude that continent urinary tract reconstruction is associated with a high incidence of early and late complications. They also found that for storage and emptying, their Lundiana pouch was superior to the Goldwasser neobladder.

Continent urinary tract reconstruction – the Lund experience

W. MÅNSSON, T. DAVIDSSON, J. KÖNYVES, F. LIEBERG, Å. MÅNSSON* and B. WULLT

*Department of Urology, University Hospital and *Department of Nursing, Lund University, Lund, Sweden*

Accepted for publication 12 February 2003

OBJECTIVE

To assess the early and late complications and functional results in patients undergoing continent reconstruction of the urinary tract, i.e. orthotopic bladder substitution (OBS) or continent cutaneous diversion (CCD).

PATIENTS AND METHODS

The medical records of all patients undergoing OBS (Goldwasser technique) or CCD ('Lundiana' technique) for malignant or benign disease during 1987–1999 and followed to December 2001 were reviewed. There were 67 patients with neobladders, 77 with a Lundiana pouch who had undergone radical cystectomy and 22 with a Lundiana pouch operated for benign disorders.

RESULTS

Early complications requiring reoperation occurred in 12% of the cystectomy group, with no difference with type of reconstruction, and in 10% with benign diseases. Four patients (3%) undergoing radical cystectomy died from early cardiovascular complications, two after surgery for intra-abdominal complications. Intestinally related complications and wound dehiscence requiring re-operation occurred in nine and six patients, respectively. The incidence of late complications requiring open surgery was 22% and 23% after cystectomy with OBS and CCD, respectively. The value in patients with benign diseases

undergoing CCD was also 23%. Stone formation in the pouch was common, occurring in 12% in patients with OBS and in 10% after CCD. The pouch perforated or ruptured in four patients. The incidence of uretero-intestinal stricture using the Le Duc technique was 2.4% and renal function was well preserved. The incidence of revisional surgery of the Lundiana pouch outlet for incontinence was low and all patients but four were continent. The functional outcome in patients with OBS was less good; some needed pouch augmentation or an artificial urinary sphincter. Most patients used incontinence products and many needed clean intermittent self-catheterization.

CONCLUSION

Continent urinary tract reconstruction is associated with a high incidence of early and late complications. For storage and emptying, the CCD Lundiana pouch is superior to the OBS of Goldwasser.

KEYWORDS

orthotopic bladder substitution, continent cutaneous diversion, radical cystectomy, complications, functional results

INTRODUCTION

Although the concept of the continent reconstruction of the urinary tract is as old as that of urinary diversion, it was not until two

reports in the early 1980s that continent reconstruction became clinically accepted, i.e. Kock *et al.* [1] reported a continent cutaneous diversion (CCD) using an ileal reservoir and Lilien and Camey [2] reviewed the results from orthotopic bladder substitution (OBS). In the following 20 years there has been an astonishing development in techniques for continent reconstruction, and clinical and experimental research has elucidated the physiological aspects of such procedures.

After the initial surge in interest for continent reconstruction it has become obvious that these types of procedures have several problems; complication rates in some series seem high, continence is not always achieved and many studies showed no clear advantage of such reconstruction over the ileal conduit in adjustment and well-being [3].

The authors' department undertook its first CCD 25 years ago; since 1991 we have used a modification of the Indiana pouch, the 'Lundiana' pouch. For OBS we have also used the right colon. The present report includes all patients operated with these techniques and compares the functional results obtained.

PATIENTS AND METHODS

To select patients for continent reconstruction, age is a relative contraindication; the upper age limit is usually 75–80 years. The same is true for advanced disease, but if small positive nodes are found at surgery we usually proceed with the planned procedure. If renal function is low (serum creatinine > 150 µmol/L or GFR < 50 mL/min/1.73 m²) the patient is usually recommended to have an ileal conduit. Before cystectomy and deep transurethral biopsies of the prostate taken at the 3 and 9 o'clock positions from the bladder neck to the verumontanum. If there is widespread carcinoma *in situ* in the bladder, tumour or carcinoma *in situ* at the bladder neck, or tumour in the prostatic urethra/prostate, primary urethrectomy is recommended. Understanding the symptoms and signs of a full pouch is essential.

Between February 1987 and December 1999 OBS was performed in 73 patients, 67 of whom had a detubularized right colonic segment for the neobladder, and constitute the patients assessed in the present study (63 men and four women). All had a radical

cystectomy for locally advanced bladder cancer; early in the series 23 received 20 Gy of irradiation in the week before surgery. All patients were followed until death or December 2001; the patients' data are shown in Table 1.

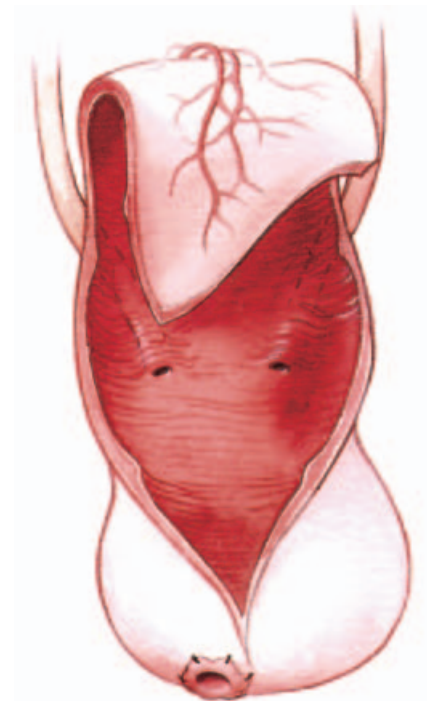
Between March 1991 (when the first Lundiana pouch was created) and December 1999, 130 patients had CCD, using the same pouch in all, i.e. a detubularized right colonic segment, the outlet being the appendix in 10, an intussuscepted ileal nipple valve in 21 and a stapled ileal outlet in 99, i.e. the Lundiana pouch. The present study focuses on the last group. Seventy-seven patients had a diversion for invasive bladder cancer or in one for recurrent cervical carcinoma necessitating radical cystectomy. Five of them had preoperative irradiation, one of 70 Gy after radical prostatectomy 5 years earlier, and the patient with cervical carcinoma of 30 Gy before hysterectomy 12 years earlier. All the women and all but five men had a urethrectomy.

Twenty-two patients had a diversion for benign conditions; the indications were interstitial cystitis in two (and they also had a simple cystectomy), a shrunken bladder caused by previous full-dose irradiation for prostate cancer in two, and in the others for various organic or functional bladder disturbances. Among these patients two were converted from an ileal conduit diversion and cutaneous ureterostomy, respectively. The stoma was in the right lower quadrant in 88 patients and in the umbilicus in 11. The patient's data are shown in Table 1.

SURGICAL TECHNIQUES

The neobladder is made from a detubularized right colonic segment as described by Goldwasser *et al.* [4] and modified by us [5] (Fig. 1). Thus, the ileum is divided just proximal to the ileocaecal valve and the colon divided ≈ 10 cm distal to the hepatic flexure, usually sacrificing a branch of the right colonic artery. Bowel continuity is by a side-to-side ileotransversostomy using a stapling technique. The isolated segment is dependent on the ileocaecal artery with its arcade along the right colon. The segment is rinsed and opened along the anterior taenia all the way to the bottom of the caecum. The ileocaecal junction is closed and the ureters implanted just below the middle of the isolate, with an antirefluxing technique. A hole is made in the

FIG. 1. Detubularized right colonic segment for orthotopic bladder substitution according to Goldwasser *et al.* [4].



most dependant part of the caecum and the mucosa everted through the opening to lessen the risk of urethrocaecal stricture. Then the segment is detubularized by folding the bowel plate so that the distal end of the isolate meets the proximal end. The anastomosis to the urethra is accomplished with six 4/0 polydioxanone sutures over a 22 F silicone Foley catheter. Baby-feeding catheters (8 F) are used for the ureters and brought through the neobladder and the abdominal wall. A 22 F silicone Foley catheter for suprapubic drainage was also brought through the anterior wall of the neobladder and the abdominal wall. The technique has remained unchanged.

To create a Lundiana pouch the distal 10 cm of the ileum and the right colonic segment, as described above, are isolated [6] (Fig. 2). The colonic segment is opened along the anterior taenia down to the level of the ileocaecal valve, from where the incision is transverse to the base of the valve. The ileal segment is tapered snugly over a 10 F catheter with a GIA 50 Premium stapler, using two or occasionally three cartridges of staples. Early in the series we noted stomal stenosis, so that now the first cartridge is placed obliquely to preserve as much as possible of the diameter of the

FIG. 2. Construction of the Lundiana pouch for continent cutaneous diversion. **a,** The caecum is opened transversely to the base of the ileocaecal valve. **b,** The ileocaecal valve is grasped together with the edges of the caecal wall. **c,** Positioning of the TA-55 stapler, incorporating part of the ileocaecal valve and closing the transverse caecal incision. Reproduced with permission from the *Journal of Urology* (Davidsson T, Barker SB, Mansson W. Tapering of intussuscepted ileal nipple valve or ileocaecal valve to correct secondary incontinence in patients with urinary reservoir. *J Urol* 1992; **147**: 144–6. © American Urological Association, Inc.).

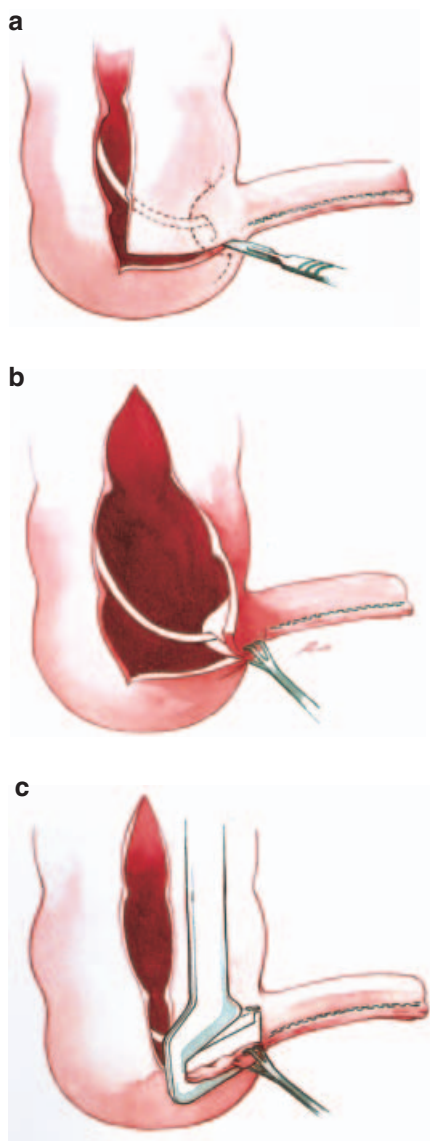


TABLE 1 The characteristics of the patients, the early and late complications, and causes of death in the three groups

Variable	OBS	CCD	
		malignant	benign
No.	67	77	22
M/F	63/4	62/15	8/14
Mean (range):			
Age at surgery, years	61 (53–74)	63 (26–78)	40 (13–73)
Follow-up, months	70 (4–172)	47 (2–129)	69 (25–127)
Early complications, n			
Cardiac insufficiency	2 (++)		
Pulmonary embolism	1		
Insuff. bowel anastomosis		1 (+)	
Intestinal fistula		2	
Intestinal obstruction	2	3 (+)	1 (paralysis)
Perforated acute cholecystitis	1		
Intra-abdominal bleeding			1
Wound dehiscence	4	2	
Intra-abdominal abscess*		2	
Neobladder-rectal fistula	1		
Partial necrosis of pouch		1	
Fistula pouch-vagina†		1	
Ureteric obstruction‡		1	
Acute pyelonephritis			2
Septicaemia:			
<i>Staphylococci</i>	1		
<i>Candida</i>	1		
Deep vein thrombosis		3	
Injury to brachial plexus	2		
Acute psychosis	1		
Causes of death during the follow-up			
No.	65	75	22
Recurrent malignancy	20	32	
Cancer of the renal pelvis or ureter	3		
Renal abscess	1¶		
Progressive uraemia	1		
Other causes	4	2	1
Late complications			
Fistula neobladder-bowel	4 ^a		
Bowel obstruction/fistula		5 ^b	
Incisional hernia		2	
Parastomal hernia awaiting surgery	1		
Bile acid-induced diarrhoea		1	
Rupture/perforation of pouch	1	2	1
Stone formation in pouch	8 ^c	7 ^c	3
Septicaemia	1		
Acute pyelonephritis/febrile UTI	1	3	1
Ureteric stone	1		
Pyocystitis			3
Ureteric stricture	3 ^d	4 ^e	1

Problem solved by *drainage of abscess, †drainage of pouch and ‡percutaneous nephrostomy; ¶At autopsy there was renal pelvic cancer of the contralateral kidney with lymph node metastases; ^atwo had tumour recurrence and one had received full-dose irradiation for tumour recurrence; ^bfour had tumour recurrence; ^cManaged endoscopically except in one patient; ^done reimplantation; ^etwo reimplantations.

ileal opening, as this will create the future stoma. This is the only change in technique over the years. The edges of the caecal wall incision are then grasped with two Babcock clamps and a third Babcock is used to grasp the ileocaecal valve, and it is pulled out between the previous two clamps, or only one clamp is used. A TA-55 stapler with 4.8 mm staples is placed to incorporate the edges of the caecal wall and part of the valve. The fired staple line closes the caecum, tapers the valve and tethers the narrowed ileocaecal valve to the caecal wall. A uniform narrowed diameter is thus achieved in the entire length of the outlet and a small flap valve created at the junction to the pouch. The ileocaecal segment is rotated 180° counter-clockwise so that the colonic end dips down into the pelvic cavity. The ureters are implanted, the pouch closed and ureteric stents and a 22 F Foley reservoir catheter placed as described above. The stoma is in the right lower quadrant or in the umbilicus, according to the wish of the patient. A 16 F Foley catheter passes through the reservoir inlet into the pouch.

In the 166 patients, 328 ureters were implanted; 301 according to Le Duc, 22 with submucosal tunnels, three according to Turner-Warwick and two implanted end-to-side.

Before surgery all patients were assessed using IVU and renal function determined by serum creatinine; if the latter was equivocal, the total and separate GFR was estimated. CT was used in patients with advanced malignant disease, but not routinely. The patients were fully counselled by a urologist and stoma nurse. The bowel was prepared the day before surgery with 4 L of polyethylene glycol and a low-molecular weight heparin analogue administered at the start of surgery; 1–2 h before the bowel was opened 2 g of mefoxitin was given intravenously.

After surgery the pouches were irrigated two to three times daily until all catheters were removed. Ureteric stents were removed after 13–14 days and IVU performed. The patient was discharged and readmitted 2 weeks later for a couple of days, when the urethral and stomal catheter were removed, the patient assessed for the ability to empty the neobladder or catheterize the pouch, after which the suprapubic catheter to the pouch was removed. Antibiotics were given only preoperatively and for 2 days when the ureteric stents were removed, but not otherwise.

For the follow-up, IVU was used after 3 and 12 months, after 2 years and then biannually if there were no signs of abnormality. Regular laboratory assessments included serum creatinine, sodium, chloride and venous base excess. Serum vitamin B12 was checked annually/biannually after 5 years.

RESULTS

As shown in Table 1 there were many early complications, with 12% requiring open surgical intervention in patients undergoing radical cystectomy, with no difference with the method of reconstruction; 10% of patients with benign disorders required further surgery. Of the 144 patients undergoing radical cystectomy four (3%) died from postoperative cardiovascular complications, which in two patients followed surgery for intra-abdominal complications. There were serious intestinally related complications but they were unrelated to preoperative irradiation or age.

Table 1 also lists the causes of death during the follow-up; 52 of the 140 surviving patients with malignancy (37%) died from recurrent disease at a mean (range) of 29 (2–118) months after surgery. Seven patients developed upper tract tumours, causing death in three. One patient developed a urethral recurrence 38 months after radical cystectomy and OBS, and was treated conservatively; 9 months later pelvic pain began, caused by tumour recurrence.

Several patients developed one or more complications during the later follow-up (Table 1). In patients with OBS, 22% had late complications requiring open surgery, and 23% did so in the CCD groups, excepting revision for stomal stenosis. Intestinal obstruction and/or fistula occurred mainly in patients with recurrent cancer. Stone formation was common, in 12% of OBS and 10% of Lundiana pouches, occurring more than once in some, and the problem was managed endoscopically in all but two patients. In four patients rupture/perforation of the pouch necessitated emergency surgery.

The ureter became obstructed in eight of 318 ureteric anastomoses (eight of 162 patients); of these, seven were in 291 Le Duc anastomoses (2.4%). Obstruction resulted in three nonfunctioning kidneys. Balloon dilatation was successful in two strictures, primary reimplantation in two ureters and

reimplantation of another ureter after unsuccessful dilatation.

The serum creatinine level increased from normal values (< 120 µmol/L) in 11 patients (7%); one patient died from uraemia, who had an initial GFR of 39 mL/min/1.73 m². One patient required chronic haemodialysis for Goodpasture's syndrome. Another patient who developed a nonfunctioning kidney has hypertension, a contralateral kidney with no obstruction, and a serum creatinine level of 250–300 µmol/L. Eight other patients developed increased serum creatinine to 121–165 µmol/L; three had normal IVU findings, one had a kidney resected for renal cancer, two had nephrectomy for a nonfunctioning kidney (stricture), one a reimplanted ureter (stricture) and one nephroureterectomy for ureteric cancer. The other patients had or have a serum creatinine of < 120 µmol/L at end of the follow-up.

Two patients, both with Lundiana pouches, developed low serum B12 values and were prescribed vitamin B12 substitution therapy.

In several patients with OBS, endoscopic or open surgery was needed for stenosis of the urethral anastomosis or urine leakage (incision at the urethrocaecal anastomosis in three, an artificial urinary sphincter in four, augmentation for intermittent high pressure in two and conversion to a conduit in one). In addition, clean intermittent self-catheterization (CISC) was used by 23 patients (37%) and most patients needed pad(s) and/or condom drainage (Table 2). Only 14 patients (22%) had perfect control of storage and emptying and needed no protection, although some used CISC.

In patients with a Lundiana Pouch, none required surgery for difficulties in emptying the pouch, but in two percutaneous punctures were necessary for episodes of inability to catheterize a full reservoir (once in one and three times in the other). The other procedures were dilatation of stoma for stenosis (one), revision of the stoma for stenosis (six patients; twice in two and three times in one), revision of the outlet because of urine leakage (six patients; twice in one and three times in two) and augmentation for an inadequate pouch capacity (two). Stomal stenosis occurred early in the series before modifying the technique. Continence was achieved in all but four patients (two of whom had the pouch continuously drained

TABLE 2 The use of incontinence products in 63 patients with OBS (excluding one who received an ileal conduit and one who was on chronic haemodialysis); two patients had permanent indwelling catheters and 23 used CISC.

Night-time	Daytime		
	No pad	Pad	Condom drainage
No pad	14	2	0
Pad	7	22	0
Condom drainage	3	11	2

because of rapidly recurring malignancy). Patients who had more than one revision for incontinence were all diverted for benign diseases. The common finding at re-operation was a wide diameter of the outlet at the caecal junction, which was then narrowed.

DISCUSSION

There are some major findings from this series: (i) Continent reconstruction of the urinary tract, especially in conjunction with radical cystectomy, is associated with considerable early morbidity; (ii) the most common late complication is stone formation in the pouch; (iii) the Le Duc procedure for ureteric implantation into colonic segments has a low stricture rate; (iv) renal function is well preserved during the follow-up; (v) the functional results with the Lundiana pouch for CCD are satisfactory, but less so are the results after OBS using the right colon.

Radical cystectomy with continent urinary tract reconstruction remains a major undertaking, in this series shown by the 3% mortality rate and several re-operations for intra-abdominal complications and wound dehiscence. Similar contemporary results were reported from other European centres [7–9], in contrast to some lower values published [10,11]. There is some association between patients' physical condition, as measured by the ASA score, and the likelihood of major postoperative complications [9,11]. Two patients in the present series, one of whom ultimately died, had leakage of intestinal content from the stapled ileocolonic anastomosis, indicating that expertise with the stapling technique is mandatory, and that the stapling instrument may expedite the procedure but 'it is an adjunct to, and not a substitute for, meticulous surgical technique' [12].

Continent pouches, be it for CCD or OBS, are prone to stone formation. Not surprisingly,

this is common after surgical techniques using staples exposed to urine, as in the Kock ileal neobladder, and a third of such patients have developed stones after 5 years [10]. We are not using staples for neobladder construction and for the Lundiana pouch they are placed on the outside of the bowel, but the incidence of stones was still 10% in both procedures. In addition to foreign material, residual urine, bacteria, hypercalciuria and hypocitraturia seem to be important [10,13], and measures to prevent stone formation are avoiding staples and emptying the reservoir completely. Incomplete emptying and bacteriuria, with or without CISC, were possibly the main risk factors among the present patients. Regular irrigation has been suggested, but its true value remains unclear [14].

Less common, but more serious, is perforation/rupture of the pouch, in this series occurring in 3% of those with CCD, but also in OBS. In a Scandinavian hospital survey this complication was noted in 1.5%, occurring in any segment of intestine used [15]. Causal factors may be blunt or sharp trauma (e.g. catheterization) to an overdistended pouch. This complication must be suspected in all patients with continent pouches who present with acute abdominal pain.

Whether ureters should be implanted with or without reflux protection is in continuous debate; we consider strongly that an antirefluxing technique should be used, also in OBS [16]. We continue to feel that the Le Duc technique is excellent, with a low incidence of anastomotic stricture, contrary to some clinical and experimental studies. The 2-week period with intubated ureters and irrigation of the pouch provides tissue cover for the exposed ureteric adventitia, followed by ingrowth of colonic mucosa. The unobstructed, nonrefluxing ureter is probably the main factor for satisfactory renal function

in this series. Although serum creatinine is a rather crude measure of renal function, the present results support studies reporting the GFR of well-preserved renal function after continent reconstruction of the urinary tract [10,17–19]. Similar to findings by others, renal function was lost mostly in patients with identifiable, and, in some, potentially remediable causes [18].

Renal function, or worse, life, may also be lost by upper tract recurrence of urothelial cancer, with an incidence of 5% in the present series. This is one reason for following these patients with regular IVU, the other being that IVU provides an acceptable measure to evaluate function. We disagree with the European guidelines in which the follow-up is by ultrasonography and plain films [20], as obstruction can be present with no dilatation and vice versa, in addition to ultrasonography being user-dependent.

Stomal stenosis is common after diversion using small-bore outlets, i.e. the appendix [21]. Although the stoma most often can be revised as an outpatient procedure, it is nevertheless annoying to the patient. By placing the first staple instrument obliquely when tapering the ileal segment of the Lundiana pouch, we were able to preserve an adequate diameter of the ileal stoma, thereby lowering the risk of stenosis.

From the functional results obtained it is obvious that the Lundiana pouch is superior to the right colonic neobladder. Storage is better, because the outlet closure mechanism is adequate, resulting in longer intervals between emptying and patients having less difficulty in controlling urine than those with a neobladder [22]. Only a few of the latter needed no protection. The other patients had pad/s and many had condom drainage at night. This does not mean that all of those who used pads had severe leakage; most had small leakage only and some did not usually leak, but they felt insecure with no protection. CISC was used by 23 patients because of inadequate emptying, something not exclusively associated with the use of colon, but reported to be equally common after an ileal neobladder [10]. Although there are no proper prospective studies comparing ileum and colon, some retrospective studies failed to show major functional differences, although the urodynamic findings seem to be more favourable using ileum [23,24]. True comparative studies are needed, including the

use of validated outcome instruments and voiding diaries [25], and such a study is now underway in the Scandinavian countries as a multicentre study comparing different types of neobladders.

Although there were differences in functional outcome between CCD and OBS, a 'quality-of-life' study in these patients using instruments tested for validity and reliability showed no differences [22]. This may at least partly be explained by the provision of honest information to the patient before surgery, and the adaptation that takes place afterward.

Is radical cystectomy associated with more complications when combined with continent reconstruction than in conjunction with ileal conduit? Some studies fail to find such differences even when stratifying according to comorbidity index [9,11,26,27]. We are sceptical as to whether these findings have general applicability within this field. The more complicated the surgery, the higher the likelihood of complications, early and late. This should also be part of the preoperative information to the patient.

ACKNOWLEDGEMENTS

This study was supported by grants from The Swedish Cancer Society (3789-B98-03XAC), Gunnar Nilsson Cancer Foundation and the Swedish Foundation for Health Care Sciences and Allergy Research.

REFERENCES

- Kock NG, Nilson AE, Nilsson LO, Norlen LJ, Philipson BM. Urinary diversion via a continent ileal reservoir: clinical results in 12 patients. *J Urol* 1982; **128**: 469-75
- Lilien OM, Camey M. 25-year experience with replacement of the human bladder (Camey procedure). *J Urol* 1984; **132**: 886-91
- Månsson Å, Månsson W. When the bladder is gone: quality of life following different types of urinary diversion. *World J Urol* 1999; **17**: 211-8
- Goldwasser B, Barrett DM, Benson RC Jr. Bladder replacement with use of a detubularized right colonic segment: preliminary report of a new technique. *Mayo Clin Proc* 1986; **61**: 615-21
- Månsson W, Colleen S. Experience with a detubularized right colonic segment for bladder replacement. *Scand J Urol Nephrol* 1990; **24**: 53-6
- Davidsson T, Hedlund H, Månsson W. Detubularized right colonic reservoir with intussuscepted ileal nipple valve or stapled ileal ('Lundiana') outlet. *World J Urol* 1996; **14**: 78-84
- Venn SN, Popert RM, Mundy AR. 'Nerve-sparing' cystectomy and substitution cystoplasty in patients of either sex: limitations and techniques. *Br J Urol* 1998; **82**: 361-5
- Hautmann RE, de Petriconi R, Gottfried HW, Kleinschmidt K, Mattes R, Paiss T. The ileal neobladder: complications and functional results in 363 patients after 11 years of followup. *J Urol* 1999; **161**: 422-7
- Malavaud B, Vaessen C, Mouzin M, Rischmann P, Sarramon JP, Schulman C. Complications for radical cystectomy. Impact of the American Society of Anesthesiologists score. *Eur Urol* 2001; **39**: 79-84
- Steven K, Poulsen AL. The orthotopic Kock ileal neobladder: functional results, urodynamic features, complications and survival in 166 men. *J Urol* 2000; **164**: 288-95
- Chang SS, Cookson MS, Baumgartner RG, Wells N, Smith JA. Analysis of early complications after radical cystectomy: results of a collaborative care pathway. *J Urol* 2002; **167**: 2012-6
- Moran BJ. Stapling instruments for intestinal anastomosis in colorectal surgery. *Br J Surg* 1996; **83**: 902-9
- Edin-Liljegren A, Grenabo L, Hedelin H, Jonsson O, Akerlund, S, Pettersson S. Concrement formation and urease-induced crystallization in urine from patients with continent ileal reservoirs. *Br J Urol* 1996; **78**: 57-63
- Brough RJ, O'Flynn KJ, Fishwick J, Gough DH. Bladder washout and stone formation in pediatric enterocystoplasty. *Eur Urol* 1998; **33**: 500-2
- Månsson W, Bakke A, Bergman B *et al*. Perforation of continent urinary reservoirs. Scandinavian experience. *Scand J Urol Nephrol* 1997; **31**: 529-32
- Månsson W, Davidsson T, Liedberg F, Månsson Å, Wullt B. Lower urinary tract reconstruction in patients with bladder cancer. In Pagano F, Bassi P eds, *Invasive Bladder Cancer*. Oxfordshire: Bladon Medical Publishing, 2003
- Kristjansson A, Wallin L, Månsson W. Renal function up to 16 years after conduit (refluxing or anti-reflux anastomosis) or continent urinary diversion. I. Glomerular filtration rate and patency of uretero-intestinal anastomosis. *Br J Urol* 1995; **76**: 539-45
- Fontaine E, Leaver R, Woodhouse CR. The effect of intestinal urinary reservoirs on renal function: a 10-year follow-up. *BJU Int* 2000; **86**: 195-8
- Jonsson O, Olofsson G, Lindholm E, Tornqvist H. Long-time experience with the Kock ileal reservoir for continent urinary diversion. *Eur Urol* 2001; **40**: 632-40
- Oosterlink W, Lobel B, Jakse G, Malmström P-U, Steckle M, Sternberg C. Guidelines on Bladder Cancer. EAU, 2001
- Gerharz EW, Kohl UN, Melekos MD, Bonfig R, Weingartner K, Riedmiller H. Ten years' experience with the submucosally embedded in situ appendix in continent urinary diversion. *Eur Urol* 2001; **40**: 625-31
- Månsson Å, Davidsson T, Hunt S, Månsson W. Quality of life in men after radical cystectomy with continent cutaneous diversion or orthotopic bladder substitution - is there a difference? *BJU Int* 2002; **90**: 386-90
- Månsson Å, Caruso A, Capovilla E *et al*. Quality of life after radical cystectomy and orthotopic bladder substitution: a comparison between Italian and Swedish men. *BJU Int* 2000; **85**: 26-31
- Paananen I, Ottelin J, Hellström P. Early cystometric findings in patients with Goldwasser's or Studer's bladder substitution. *Scand J Urol Nephrol* 2001; **35** (Suppl. 208): 32
- Steers WD. Voiding dysfunction in the orthotopic neobladder. *World J Urol* 2000; **18**: 330-7
- Benson MC, Slawin KM, Wechsler MH *et al*. Analysis of continent versus standard urinary diversion. *Br J Urol* 1992; **69**: 156-62
- Gburek BM, Lieber MM, Blute ML. Comparisons of Studer ileal neobladder and ileal conduit diversion with respect to perioperative outcome and late complications. *J Urol* 1998; **160**: 721-3

Correspondence: W. Månsson, Department of Urology, University Hospital, S-221 85 Lund, Sweden.
e-mail: wiking.mansson@urokir.lu.se

Abbreviations: CCD, continent cutaneous diversion; OBS, orthotopic bladder substitution; CISC, clean intermittent self-catheterization.