



LUND UNIVERSITY

Long-term remission in idiopathic Castleman's disease with tocilizumab followed by consolidation with high-dose melphalan-two case studies.

Jerkeman, Mats; Lindén, Ola

Published in:
European Journal of Haematology

DOI:
[10.1111/ejh.12646](https://doi.org/10.1111/ejh.12646)

2015

[Link to publication](#)

Citation for published version (APA):
Jerkeman, M., & Lindén, O. (2015). Long-term remission in idiopathic Castleman's disease with tocilizumab followed by consolidation with high-dose melphalan-two case studies. *European Journal of Haematology*.
<https://doi.org/10.1111/ejh.12646>

Total number of authors:
2

General rights

Unless other specific re-use rights are stated the following general rights apply:
Copyright and moral rights for the publications made accessible in the public portal are retained by the authors and/or other copyright owners and it is a condition of accessing publications that users recognise and abide by the legal requirements associated with these rights.

- Users may download and print one copy of any publication from the public portal for the purpose of private study or research.
- You may not further distribute the material or use it for any profit-making activity or commercial gain
- You may freely distribute the URL identifying the publication in the public portal

Read more about Creative commons licenses: <https://creativecommons.org/licenses/>

Take down policy

If you believe that this document breaches copyright please contact us providing details, and we will remove access to the work immediately and investigate your claim.

LUND UNIVERSITY

PO Box 117
221 00 Lund
+46 46-222 00 00

1 **Long term remission in idiopathic Castleman’s disease with tocilizumab followed by**
2 **consolidation with high dose melphalan – two case studies**

3 Jerkeman M¹, Lindén O¹

4 ¹Department of Oncology, Skane University Hospital, Lund, Sweden

5

6

7 **Corresponding author:**

8 Mats Jerkeman, MD, PhD

9 Department of Oncology

10 Skane University Hospital

11 SE-221 85 Lund

12 SWEDEN

13 Phone: +46 46 17 75 20

14 Fax: +46 46 17 60 80

15 Email: mats.jerkeman@med.lu.se

16

17

18

19 **Manuscript word count:** 1234

20 **Abstract word count** 117

21 **Number of references:** 11

22 **Number of figures:** 1

23 **Running title:** Tocilizumab and high-dose melphalan in MCD

1 **Abstract**

2 Multicentric Castleman’s disease (MCD) is an uncommon lymphoproliferative disorder, often
3 associated with a clinically aggressive behavior. No standard treatment has been
4 established, but patients are usually treated with lymphoma-type regimens such as
5 rituximab or combination chemotherapy. Recently, immunotherapies targeting IL-6 have
6 proven effective and have been approved for this indication. However, these agents require
7 long-term administration. Here, we describe the clinical course of two patients, refractory to
8 rituximab and chemotherapy, showing long-term remission (18 and 24 months), following an
9 induction phase with tocilizumab (an anti-IL-6 receptor antibody) and a consolidative phase
10 with high-dose melphalan accompanied by autologous stem cell support. This may prove to
11 be an effective option for this group of patients with an orphan disorder.

12

13 **Key words**

14 Castleman’s disease, tocilizumab, autologous stem cell transplantation

1 **Introduction**

2 Castleman's disease, an uncommon non-clonal lymphadenopathic disorder, was first
3 described by Dr Benjamin Castleman in 1956[1], and is divided into unicentric and
4 multicentric forms, based on the extent of local lymph node involvement[2]. The unicentric
5 form usually manifests as an asymptomatic mass lesion with a benign course, most often in
6 young adults, and may be treated with surgical resection. Multicentric Castleman's disease
7 (MCD), on the other hand, is normally seen in adults in their sixties, is frequently associated
8 with systemic manifestations such as fever, night sweats, and malaise, and multiple organ
9 system impairment as a result of excessive production of interleukin-6 (IL-6) and other
10 proinflammatory cytokines.

11 The disease is associated with Human herpes virus-8 (HHV-8) in all HIV-positive patients and
12 in some HIV-negative patients. However, another, probably larger group of HIV-negative
13 MCD patients, who are HHV-8 negative has recently been described and referred, in which
14 the disease is referred to as idiopathic MCD (iMCD)[3].

15 There is currently no standard treatment for iMCD, and patients have have been given
16 various forms of lymphoma-type treatment, including rituximab or combinations of
17 chemotherapy such as CHOP (cyclophosphamide, doxorubicin, vincristine, prednisone)[4],
18 as well as high dose chemotherapy (melphalan) with autologous stem cell support[5].

19 However, rituximab has mainly been used in the HIV-associated population [6]. Based on the
20 observation that IL-6 hypercytokinemia is central in the pathogenesis of this disorder,
21 prospective trials have been performed using antibodies targeting the IL-6 signaling cascade,
22 such as tocilizumab[7] and siltuximab, showing efficacy[8]. However, these antibodies
23 require long-term administration and are not effective in all patients.

1 Here, we describe long-term control in two patients with multiple relapsed iMCD using anti-
2 IL6 receptor immunotherapy (tocilizumab), consolidated with high dose melphalan.

3

4 **Patients**

5

6 **Patient A**

7 Patient A is a female patient, born in 1966, diagnosed with Crohn's disease in 2004, who has
8 been treated with mesalazine per os. In August 2011, she experienced progressive fatigue,
9 abdominal pain, dyspnea and intermittent fever. A CT scan showed general
10 lymphadenopathy, hepatosplenomegaly, and pericardial and bilateral pleural effusion. Her
11 CRP was elevated to 100 mg/L. A lymph node biopsy showed MCD, plasma cell variant,
12 negative for HHV-8 ORF26. Serology for HIV was negative.

13 Due to the aggressive clinical picture, treatment with R-CHOP-21 was started in October
14 2011. The patient received three cycles, followed by four weekly courses of single-agent
15 rituximab. No improvement in symptoms was seen as a result of this therapy, and an FDG-
16 PET-CT showed unchanged lymphadenopathy and hepatosplenomegaly, and an elevated
17 creatinine level. She suffered from repeated episodes of epistaxis, that were difficult to
18 control despite of her platelet count was 70 or above. Lymph nodes showed a moderate
19 FDG uptake. She received corticosteroids, and in February 2012 treatment with tocilizumab
20 8 mg/kg at 2-week intervals was initiated. After one cycle, her symptoms resolved
21 completely, and her CRP level normalized. An FDG PET-CT scan after 3 months of treatment
22 showed complete resolution of pleural effusion, and normal FDG uptake in lymph nodes.

1 lymph nodes and spleen had decreased in size, whereas hepatomegaly was unchanged
2 (Deauville 1). She received in total 17 doses of tocilizumab. In October 2012, the patient
3 underwent a peripheral stem cell harvest, after G-CSF mobilization, of 4.1×10^6 CD34+
4 cells/kg. In November 2012, the patient received high-dose melphalan (200 mg/m^2), with
5 autologous stem cell support. The treatment course was uneventful, with a total hospital
6 stay of 12 days. CT scans performed at 3-month intervals show gradual normalization of the
7 lymph nodes and spleen, but the liver has remained enlarged.

8 At the most recent follow-up visit in April 2015, 30 months post therapy, the patient was
9 asymptomatic, no longer taking steroids and her CRP and s-albumin were normal.

10

11 **Patient B**

12 Patient B is a male of Chinese origin, born in 1958. In 1979, he had a stroke causing left-sided
13 hemiparesis. In 2003, he was diagnosed with cutaneous plasmocytosis. In 2009, he
14 experienced progressive fatigue and weight loss, and a CT scan showed general
15 lymphadenopathy. Lymph node biopsies (cervical and inguinal) showed follicular hyperplasia
16 with prominent plasma cell infiltration, consistent with MCD and PCR was negative for HHV-
17 8. Serological testing showed positivity for anti-HBc, but negativity for HIV. His CRP was
18 markedly elevated, 150 mg/L and polyclonal IgG was elevated, 41 g/L . After diagnosis, he
19 initially received four doses of rituximab, 375 mg/m^2 , but without any effect on his
20 symptoms, skin lesions, or lymphadenopathy, and only a marginal decrease in CRP level
21 (Figure 1).

1 In 2011, the fatigue worsened, and was accompanied by profuse nightly sweats, and
2 elevation of CRP to 200 mg/L. In addition, an elevation in s-creatinine was noted, to 280 μ M.
3 A renal biopsy showed IgA mesangioproliferative glomerulopathy, but no plasma cell
4 infiltration, and was thought to be secondary to MCD. The patient then received six courses
5 of R-CHOP-21, completing his treatment in April 2012. During this course of treatment, his
6 renal function improved and his s-creatinine fell from 280 to 180 μ M, but there was no
7 improvement in symptoms, or in CRP or S-albumin levels. The patient was bedridden >75%
8 during the daytime. A second renal biopsy now showed prominent plasma cell infiltration
9 with Russell bodies. An FDG-PET scan showed enlarged, metabolically active lymph nodes
10 bilaterally (SUV max 5.9 units) on the neck and in the axillae.

11 In October 2012, treatment was started with tocilizumab 8 mg/kg at two-weeks intervals.
12 After two courses, the fatigue was markedly improved, his CRP level was normalized, and s-
13 creatinine was reduced from 154 to 138 μ M. An FDG-PET scan after three months of
14 treatment showed complete resolution of hypermetabolic lesions (Deauville 1). In total, 12
15 courses of tocilizumab were given. In April 2013, the patient received 2000 mg/m²
16 cyclophosphamide, followed by peripheral stem cell harvest of 16.7×10^6 CD34+ cells/kg. In
17 May 2013, the patient received high-dose melphalan (200 mg/m²), with autologous stem cell
18 support. The treatment course was without unexpected complications, and the total hospital
19 stay was 18 days.

20 At the most recent follow-up visit in January 2015, 18 months post-therapy, the patient was
21 asymptomatic, and CRP and s-albumin were normal, while his S-creatinine remained slightly
22 elevated at, 127 μ mol/L.

1 **Discussion**

2 These two cases demonstrate that a combination of anti-IL-6R immunotherapy and
3 melphalan consolidation, can induce long term remission in patients with iMCD, refractory
4 to rituximab and CHOP. It is perhaps not surprising that rituximab shows little efficacy in this
5 disorder, as plasma cells, which constitute the main component of the disease-specific cells
6 in the plasma cell variant of MCD, are CD20 negative. The use of high-dose melphalan in
7 refractory MCD has been described previously in four cases[5, 9], in two of these in
8 conjunction with POEMS syndrome (polyneuropathy, organomegaly, endocrinopathy,
9 monoclonal gammopathy, skin changes)[10, 11]. Tocilizumab as a single agent has been
10 shown to provide effective treatment for MCD in alleviating symptoms and producing
11 objective remissions [7], and has been approved for this indication in Japan. Similarly, an
12 antibody against IL-6, siltuximab, has recently been approved for the treatment of MCD in
13 Europe and the U.S. based on a phase III trial, comparing this agent to best supportive
14 care[8]. However, both these agents need to be administered for an indeterminate time,
15 making it a very costly treatment. With the present approach, using an anti-IL-6R antibody
16 for remission induction followed by consolidation with high-dose melphalan, patients with
17 MCD may instead be free from treatment for a considerable period of time. Further studies
18 are required to determine whether this treatment could develop into a curative treatment.

19

1 **References**

2

3 1. Castleman B, Iverson L, Menendez VP. Localized mediastinal lymphnode
4 hyperplasia resembling thymoma. *Cancer* 1956; 9: 822-830.

5 2. Menke DM, Camoriano JK, Banks PM. Angiofollicular lymph node hyperplasia: a
6 comparison of unicentric, multicentric, hyaline vascular, and plasma cell types of disease by
7 morphometric and clinical analysis. *Mod Pathol* 1992; 5: 525-530.

8 3. Fajgenbaum DC, van Rhee F, Nabel CS. HHV-8-negative, idiopathic multicentric
9 Castleman disease: novel insights into biology, pathogenesis, and therapy. *Blood* 2014; 123:
10 2924-2933.

11 4. Zhu SH, Yu YH, Zhang Y et al. Clinical features and outcome of patients with
12 HIV-negative multicentric Castleman's disease treated with combination chemotherapy: a
13 report on 10 patients. *Med Oncol* 2013; 30: 492.

14 5. Repetto L, Jaiprakash MP, Selby PJ et al. Aggressive angiofollicular lymph node
15 hyperplasia (Castleman's disease) treated with high dose melphalan and autologous bone
16 marrow transplantation. *Hematol Oncol* 1986; 4: 213-217.

17 6. Gerard L, Berezne A, Galicier L et al. Prospective study of rituximab in
18 chemotherapy-dependent human immunodeficiency virus associated multicentric
19 Castleman's disease: ANRS 117 CastlemaB Trial. *J Clin Oncol* 2007; 25: 3350-3356.

20 7. Nishimoto N, Kanakura Y, Aozasa K et al. Humanized anti-interleukin-6 receptor
21 antibody treatment of multicentric Castleman disease. *Blood* 2005; 106: 2627-2632.

- 1 8. van Rhee F, Wong RS, Munshi N et al. Siltuximab for multicentric Castleman's
2 disease: a randomised, double-blind, placebo-controlled trial. *Lancet Oncol* 2014; 15: 966-
3 974.
- 4 9. Ogita M, Hoshino J, Sogawa Y et al. Multicentric Castleman disease with
5 secondary AA renal amyloidosis, nephrotic syndrome and chronic renal failure, remission
6 after high-dose melphalan and autologous stem cell transplantation. *Clin Nephrol* 2007; 68:
7 171-176.
- 8 10. Ganti AK, Pipinos I, Culcea E et al. Successful hematopoietic stem-cell
9 transplantation in multicentric Castleman disease complicated by POEMS syndrome. *Am J*
10 *Hematol* 2005; 79: 206-210.
- 11 11. Szturz P, Adam Z, Rehak Z et al. [Castleman disease: retrospective single-center
12 study of therapeutic results in 10 patients]. *Klin Onkol* 2013; 26: 124-134.

13

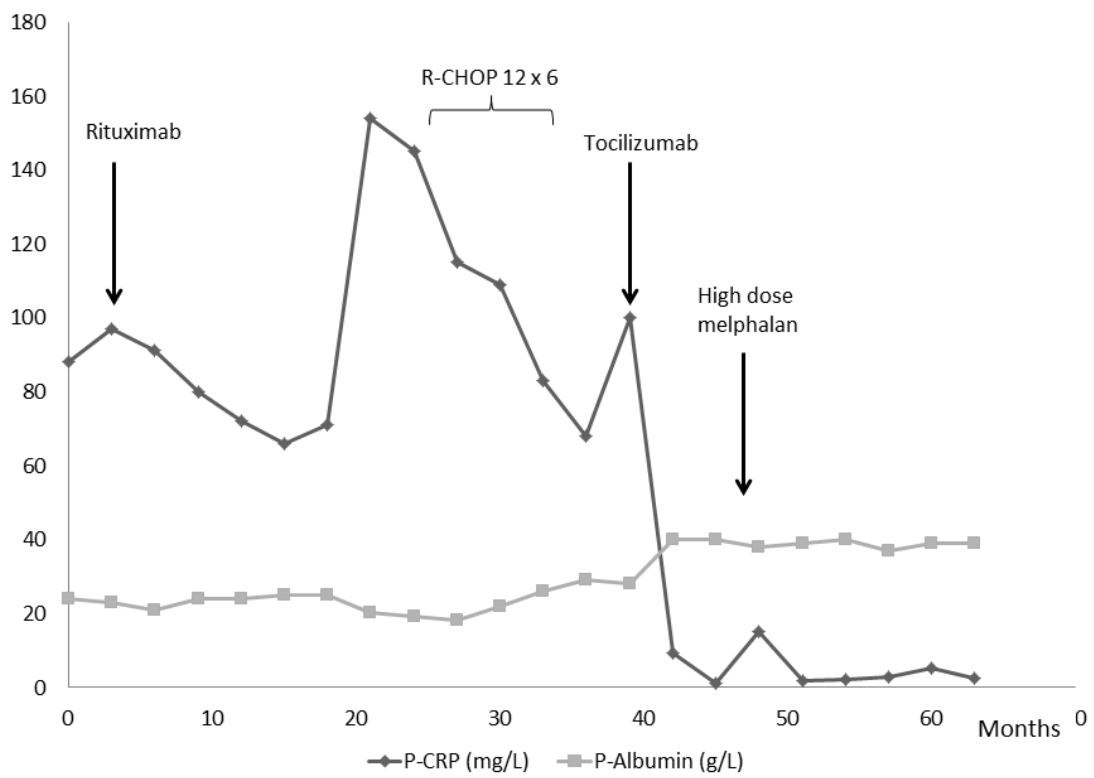
14

1 **Figure legend**

2 Plasma levels of C reactive protein (CRP) and albumin in Patient B during the course of
3 disease and in relation to treatment interventions.

4

1 **Figure 1**



2

3

4