



# LUND UNIVERSITY

## Evaluation of voice therapy by means of photoglottography

Kitzing, Peter; Löfqvist, Anders

*Published in:*  
Folia Phoniatica

1979

[Link to publication](#)

*Citation for published version (APA):*

Kitzing, P., & Löfqvist, A. (1979). Evaluation of voice therapy by means of photoglottography. *Folia Phoniatica*, 31, 103-109.

*Total number of authors:*

2

### General rights

Unless other specific re-use rights are stated the following general rights apply:

Copyright and moral rights for the publications made accessible in the public portal are retained by the authors and/or other copyright owners and it is a condition of accessing publications that users recognise and abide by the legal requirements associated with these rights.

- Users may download and print one copy of any publication from the public portal for the purpose of private study or research.
- You may not further distribute the material or use it for any profit-making activity or commercial gain
- You may freely distribute the URL identifying the publication in the public portal

Read more about Creative commons licenses: <https://creativecommons.org/licenses/>

### Take down policy

If you believe that this document breaches copyright please contact us providing details, and we will remove access to the work immediately and investigate your claim.

LUND UNIVERSITY

PO Box 117  
221 00 Lund  
+46 46-222 00 00

## Folia Phoniatica

Redactor principalis: E. Loebell, Bern  
Publishers: S. Karger, Basel  
Separatum (Printed in Switzerland)

7317

---

Folia phoniat. 31: 103-109 (1979)

### Evaluation of Voice Therapy by Means of Photoglottography

*Peter Kitzing and Anders Löfqvist*

Department of Phoniatics, University ENT Clinic, Malmö General Hospital, Malmö,  
and Department of Phonetics, of University Lund, Lund

#### Introduction

Photoglottography as a technique for investigating glottal vibrations was developed by *Sonesson* (1960) and applied to systematic studies of normal laryngeal behavior. Since its introduction, the method has been used to collect information both on laryngeal vibrations (e.g. *Kitzing and Sonesson*, 1974), and on laryngeal articulations (e.g. *Löfqvist*, 1976).

The question of the merits and limitations of the method is still unsettled, specifically concerning the accuracy with which it reproduces variations in the glottal opening area where the studies by *Coleman and Wendahl* (1968) and *Harden* (1975) present conflicting results although they used the same method of correlating the amplitude of the glottogram with area measurements made from simultaneous high-speed motion picture films of the glottis. Therefore, it appears unwise to draw any conclusions based on measurements of the glottal opening area made from photoglottograms (*Hutters*, 1976). In spite of this uncertainty, the temporal relationships within each vibratory cycle of the glottis appear to be accurately preserved in the glottogram (*Holmer*, 1978). The point of glottal closure is normally well defined as well as the point of peak glottal opening, whereas the point at which glottal opening starts can often be difficult to locate.

The present paper reports on some explorative work with photoglottography and specifically poses the following two questions: can photoglottography be used for routine purposes without technical difficulties and discomfort for the subject? Can the method provide meaningful results within the field of voice pathology?

## Method

The recordings comprised simultaneous registrations of electroglottogram (*Lecluse*, 1977), photoglottogram and the acoustic signal in patients suffering from various types of voice disorders before and after voice therapy and/or phonosurgery.

The photoglottograph was a standard, commercially available unit (F-J Electronics) but its mode of operation was modified before it was used for routine purposes. The ordinary light source of the instrument was found impractical to use and instead the light for the photoglottogram was supplied by a cold-light fountain (Stortz 482) and the light was directed to the subject's neck through a flexible fiberoptic bundle which was easy to handle and place in the correct position. The placement of the light was controlled by indirect laryngoscopy and care was taken to have an even illumination of the whole glottis. The light entered the subglottic space through the soft tissues of the neck from an almost vertical position.

The phototransistor was placed in a transparent, flexible plastic catheter which was introduced into the pharynx through the nose under light topical anesthesia. During the recordings, the transistor was kept at the level of the uvula.

The electroglottograph was custom built and the electrodes placed on each side of the neck at the level of the thyroid cartilage.

The audio signal was recorded through a Sennheiser MD 421 dynamic microphone and amplified by a custom-built amplifier.

The signals were recorded on an FM tape recorder (Lyrec TR 86) at a recording speed of 30 in/sec and simultaneously monitored on an oscilloscope.

The subjects were asked to produce sustained vowels of different fundamental frequencies and intensities and to repeat short passages of running text.

All the recorded material was written out on a Mingograph and the signals analyzed visually and auditorily. Representative passages were then recorded once more on the Mingograph with the tape recorder running at 16/32 in/sec thus providing good temporal resolution in the records. Twenty consecutive vibratory cycles were measured and the following calculations made: fundamental frequency ( $F_0$ ; Hz), open quotient ( $Oq = O/T$ ), and speed quotient ( $Sq = C-O/O-C$ ; fig. 1). Methodological and technical problems are further discussed in *Kitzing* (1977) and *Kitzing and Löfqvist* (1977).

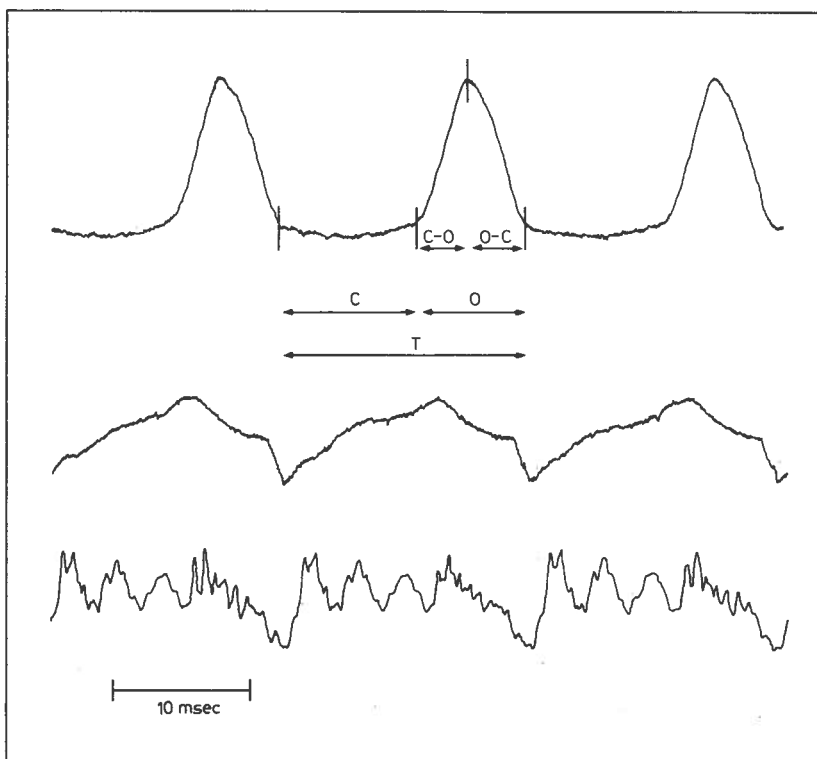
In addition to the glottographic registrations, the mean (Hz) and the range (semitones) of the subjects'  $F_0$ s were analyzed during their reading of a short story. The instrumentation for this analysis has been described by *Kitzing and Rundqvist* (1977).

## Results

Sample records are presented in figures 1 and 2 and the measurements are summarized in table I. We can first note a difference in  $F_0$  between the two recording situations. Mean  $F_0$  is generally higher during the glottographic regis-

trations than during the free reading. This holds true for all subjects. At the same time, the differences in  $F_o$  before and after therapy and/or surgery generally go in the same direction for the two recording situations.

Subject 1, a 45-year-old woman with an edema on the left vocal fold, shows an increase in  $F_o$  and an increase in both  $Oq$  and  $Sq$  after the removal of the edema and subsequent voice therapy. The change in  $F_o$  is most likely related to the decreased vibrating mass of the vocal fold after the operation. This has also caused an increase in the  $Oq$  indicating that the glottis stays open for a longer time during each vibratory cycle immediately after the operation. As a result of voice therapy  $F_o$  increases and  $Oq$  decreases again.



**Fig. 1.** Record of photoglottogram (top trace), electroglottogram (middle trace) and acoustic signal (bottom trace). The subdivision of the photoglottogram into various phases is indicated.

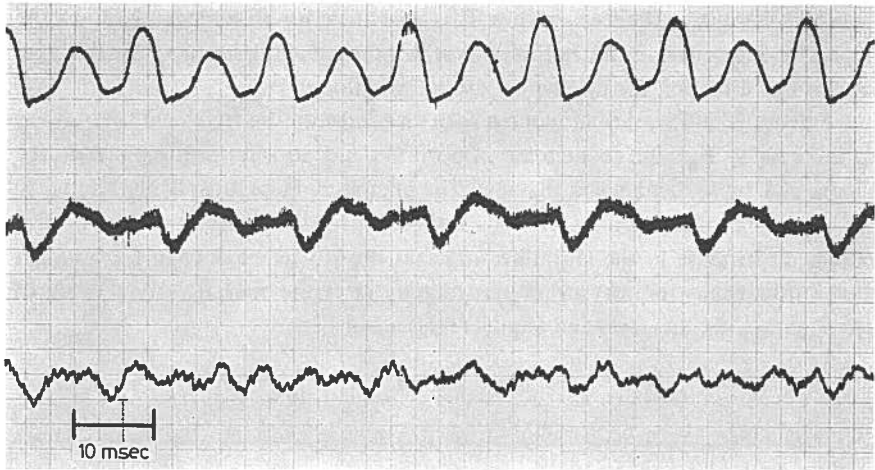


Fig. 2. Record of subject 1 producing vocal fry. The irregular vibrations are clearly visible. Traces as in figure 1.

Subject 2, a 47-year-old woman, suffered from vocal fatigue and received voice therapy. The most obvious change is a decrease in  $S_q$ , indicating that the glottis closes more slowly as a result of the therapy. This can be accounted for by reference to the forces responsible for glottal closure during phonation. Before the therapy, the subject mainly used muscular forces to accomplish the closure whereas after the therapy, the aerodynamic forces (the Bernoulli effect) were responsible for the closure. This is a stated goal of the 'accent' method used in voice therapy and it also correlates well with the perceptual evaluation of the subject's voice which had a less strained quality after therapy.

Subject 3, a 45-year-old woman, suffered from vocal fatigue and had voice therapy. No specific changes could be found in the glottogram and the results of the therapy were insignificant from a perceptual point of view.

Subject 4, a 43-year-old male, suffered from habitual dysphonia (strained voice) and received vocal therapy. In this case, the only measured effect was a decrease in  $F_0$ , whereas neither  $O_q$  nor  $S_q$  showed any changes although the voice had improved perceptually. Here the glottographic method was not sensitive enough, or the measurements did not relate to the changes due to therapy.

Subject 5 is a 23-year-old woman with vocal fatigue. Her voice was very strained but became normalized after therapy. The decrease in  $S_q$  can be related to the same causes as for subject 2 above. The contribution of the aerodynamic

**Table 1.** Mean  $F_o$  (Hz) and range (semitones) during reading, and  $F_o$ , Oq and Sq during the production of sustained vowels

Subject		Reading $F_o$	Glottography		
			$F_o$	Oq	Sq
1	pre	163/3	181	0.45	0.67
	post a	161/8	195	0.85	1.38
	post b	181/8	227	0.69	1.28
2	pre	186/5	193	0.55	1.27
	post	181/6	198	0.55	0.91
3	pre	177/7	199	0.76	0.78
	post	172/7	218	0.74	0.81
4	pre	133/9	151	0.50	1.25
	post	126/7	138	0.56	1.21
5	pre	185/5	210	0.62	2.11
	post	189/6	200	0.64	1.12
6	pre	159/6	198	0.72	2.00
	post	167/7	173	0.74	1.19
7	pre	190/4	203	0.62	1.08
	post	221/3	240	0.82	0.64
8	pre	213/4	244	0.63	1.53
	post	179/5	204	0.61	0.94

Pre and post refer to recordings before and after voice therapy and/or phonosurgery, respectively. For subject 1 two postoperative recordings were made, post a one week after the operation and post b after three months of subsequent voice therapy.

components to maintaining vocal vibrations has increased and that of the muscular components has diminished, resulting in a better balance between the two.

Subject 6 is a 28-year-old woman with habitual dysphonia (strained voice). She suffered from a leaky voice and tried to compensate for this, which resulted in a strained voice. Some leakage remained after the therapy and this is also evident from the glottographic measurements where Oq is about the same before and after therapy.

Subject 7 is an 18-year-old woman with bilateral vocal nodules. The glottographic registrations were made before and after the removal of the nodules and the results are consistent with those for subject 1 with  $F_o$  and Oq increasing after the operation.

Subject 8 is a 21-year-old woman with bilateral vocal nodules. The removal of the nodules and subsequent voice therapy resulted in a perceptually better voice but there was no clear change in the measurements apart from a decrease in  $F_0$ .

### Discussion

In the introduction two questions were raised, the first of which concerned the possibility of using photoglottography for routine purposes without technical difficulties and discomfort for the subject. We feel that this question can be answered in the affirmative. With a suitable light source and a sensitive phototransistor, it is quite easy to obtain good signals from most subjects. The use of a Nelaton catheter which is sealed at one end protects the transistor and makes the insertion of the transistor into the pharynx unproblematic. It also helps in maintaining the transistor in the same position during the recording session.

One might argue that the higher  $F_0$  levels encountered during the glottographic sessions compared to those found during free reading result from the strain put on the subjects during glottography. This is plausible but it is unclear whether the use of sustained vowel sounds contributes to this effect since subjects may tend to raise their  $F_0$  when producing isolated sounds.

The second question raised in the introduction concerned the meaningfulness of the results. Due to the explorative nature of the study, any firm conclusion seems premature but we feel that it is worthwhile to continue the investigations. Some of the results could be tentatively related to physiological and aerodynamic changes due to therapy and/or surgery whereas others could not be readily interpreted. In order to have a firmer base for the interpretation of the glottograms, they can be supplemented with simultaneous registrations of aerodynamic parameters such as pressure and flow. Since our understanding of the phonation process is far from complete, photoglottography appears to be one way of obtaining information which can contribute to a better understanding of this process both under normal and pathological conditions.

### Summary

This paper reports on some explorative work with photoglottography and specifically poses the following questions: Can the method be used for routine purposes and can it provide meaningful results within the field of voice pathology? Recordings before and after

therapy and/or phonosurgery are presented of patients suffering from various types of voice disorders. The results are discussed in relation to physiological and aerodynamic changes due to the treatment.

### References

- Coleman, R. and Wendahl, R.: On the validity of laryngeal photosensor monitoring. *J. acoust. Soc. Am.* 44: 1733–1735 (1968).
- Harden, R.J.: Comparison of glottal area changes as measured from ultrahigh-speed photographs and photoelectric glottographs. *J. Speech Hear. Res.* 18: 728–738 (1975).
- Homer, N.G.: Linearity control of the photoglottographic method; in Holmer and Lindström, *New methods in medical ultrasound*; diss., Institute of Technology, Lund (1978).
- Hutters, B.: Problems in the use of the photoelectric glottograph. *A. Rep. Inst. Phon., Univ. Copenh.*, vol. 10, pp. 275–312 (1976).
- Kitzing, P.: Methode zur kombinierten photo- und elektroglottographischen Registrierung von Stimmlippenschwingungen. *Folia phoniatic.* 29: 249–260 (1977).
- Kitzing, P. and Löfqvist, A.: Clinical application of combined electro- and photoglottography; in Buch, *Proc. 17th Int. Congr. Logoped. Phoniatic.* (Special-paedagogisk Forlag, Copenhagen 1978).
- Kitzing, P. and Rundqvist, H.-E.: Fundamental frequency of voice in continuous speech; in Buch, *Proc. 17th Int. Congr. Logoped. Phoniatic.* (Special-paedagogisk Forlag, Copenhagen 1978).
- Kitzing, P. and Sonesson, B.: A photoglottographical study of the female vocal folds during phonation. *Folia phoniatic.* 26: 138–149 (1974).
- Lecluse, F.L.E.: *Elektroglottografie*; diss. Amsterdam (1977).
- Löfqvist, A.: Closure duration and aspiration for Swedish stops. *Work. Pap. Phon. Lab., Dept. Gen. Ling., Univ. Lund*, vol. 13, pp. 1–39 (1976).
- Sonesson, B.: On the anatomy and vibratory pattern of the human vocal folds. *Acta oto-lar., suppl.* 156 (1960).

Received: June 29, 1978; accepted: July 14, 1978

Peter Kitzing, Department of Phoniatics, University ENT Clinic, Malmö General Hospital, S-214 01 Malmö (Sweden)