



LUND UNIVERSITY

Tissue characterization in some clinical specialities utilizing laser-induced fluorescence

Svanberg, Katarina; Andersson-Engels, Stefan; Baert, L; Bak Jensen, E; Berg, R; Brun, A; Collén, S; Idvall, I; d'Hallewin, MA; Ingvar, C; Johansson, Jonas; Karlsson, SE; Lundgren, R; Salford, LG; Stenram, U; Strömblad, LG; Svanberg, Sune; Wang, I

Published in:

ADVANCES IN LASER AND LIGHT SPECTROSCOPY TO DIAGNOSE CANCER AND OTHER DISEASES

DOI:

[10.1117/12.175982](https://doi.org/10.1117/12.175982)

1994

[Link to publication](#)

Citation for published version (APA):

Svanberg, K., Andersson-Engels, S., Baert, L., Bak Jensen, E., Berg, R., Brun, A., Collén, S., Idvall, I., d'Hallewin, MA., Ingvar, C., Johansson, J., Karlsson, SE., Lundgren, R., Salford, LG., Stenram, U., Strömblad, LG., Svanberg, S., & Wang, I. (1994). Tissue characterization in some clinical specialities utilizing laser-induced fluorescence. In RR. Alfano, & A. Katzir (Eds.), *ADVANCES IN LASER AND LIGHT SPECTROSCOPY TO DIAGNOSE CANCER AND OTHER DISEASES* (Vol. 2135, pp. 2-15). SPIE. <https://doi.org/10.1117/12.175982>

Total number of authors:

18

General rights

Unless other specific re-use rights are stated the following general rights apply:

Copyright and moral rights for the publications made accessible in the public portal are retained by the authors and/or other copyright owners and it is a condition of accessing publications that users recognise and abide by the legal requirements associated with these rights.

- Users may download and print one copy of any publication from the public portal for the purpose of private study or research.
- You may not further distribute the material or use it for any profit-making activity or commercial gain
- You may freely distribute the URL identifying the publication in the public portal

Read more about Creative commons licenses: <https://creativecommons.org/licenses/>

Take down policy

If you believe that this document breaches copyright please contact us providing details, and we will remove access to the work immediately and investigate your claim.

LUND UNIVERSITY

PO Box 117
221 00 Lund
+46 46-222 00 00

Tissue Characterization in some Clinical Specialities Utilizing Laser-Induced Fluorescence

Katarina Svanberg¹, Stefan Andersson-Engels¹, Luc Baert², Elisabeth Bak-Jensen¹, Roger Berg¹, Arne Brun¹, Stig Colleen¹, Ingrid Idvall¹, Marie-Ange D'Hallewin², Christian Ingvar¹, Jonas Johansson¹, Sven-Erik Karlsson¹, Rolf Lundgren¹, Leif G. Salford¹, Unne Stenram¹, Lars-Göran Strömblad¹, Sune Svanberg¹ and Ingrid Wang¹

¹Lund University Medical Laser Centre, Lund University, S-221 85 Lund, Sweden

²Department of Urology, St. Pieter Hospital, Leuven University, B-3000 Leuven, Belgium

ABSTRACT

Laser-induced fluorescence (LIF) can be used for non-invasive spectroscopic identification of biological tissue and is of special interest in early tumour detection. The basis for this "optical biopsy" method is the interaction of the laser light with tissue chromophores, such as tryptophan, collagen, elastin, NADH, β -carotene and haemoglobin. The UV-excited fluorescence that arises from the native chromophores, the autofluorescence, has a broad distribution, peaking at about 490 nm with a lower intensity in tumour compared to normal tissue. The tumour detection potential is enhanced with exogenously administered tumour marking agents, such as Haematoporphyrin (HPD, commercial name Photofrin), with two fluorescence peaks at about 630 and 690 nm. We have developed clinical instrumentation both for tissue point monitoring and for full real-time image processing. Seventy-one patients were investigated *in vivo* and surgical samples from additional 20 patients. In 46 patients the autofluorescence only was monitored. In 45 patients low-dose Photofrin injection was used. The *in vivo* investigations included different kinds of lung tumours (30 patients), urinary bladder tumours (21 patients) and malignant gliomas (20 patients). The *in vitro* measurements were performed in breast tumours (15 patients) and prostatic tumours (5 patients). Invasive and early tumours and also precancerous lesions can be revealed utilizing LIF in low-dose Photofrin injected patients.

1. INTRODUCTION

Early tumour localization is of great importance in the clinical diagnostic work as it has a major impact on the tumour treatment procedure and the prognosis for the patients. Standard clinical diagnostic methods rely on X-ray, CT-scanning and MR-images and, additional for hollow organs, white light endoscopy. If the tumours are in early stage the visualization might be limited utilizing conventional methods and the very early lesions, such as *in situ* cancer or dysplasia might even be ignored. Therefore, there is a need for a real-time non- or minimally invasive method for early tumour demarcation.

Laser spectroscopic techniques in tissue diagnostics have been developed during the past years and promising results have been presented. Laser-induced fluorescence (LIF) is one of the techniques

which has been applied in clinical tumour diagnostic research. The method relies on the fluorescence emission either from the endogenous chromophores in the tissue, such as collagen, elastin, sphingomyelin, β -carotene, flavins and nicotinamide adenine dinucleotide (NADH) or its oxidized form NAD⁺ or in conjunction with exogenously added tumour markers, such as different porphyrin containing substances.

The autofluorescence, consisting of the total emission from all intrinsic chromophores, has a broad wavelength distribution peaking at about 490 nm, when excited in the UV- or near-UV region, and does not show any specific spectral characteristics. However, it has been shown that the overall autofluorescence intensity decreases in manifest malignant tumours and also in tissue undergoing malignant transformation as compared to surrounding normal tissue¹⁻³. This is a general phenomenon in all types of malignant tissue with only a few exceptions, such as scirrotic breast cancer, which is characterized by a high collagen content and thus exhibits a higher endogenous fluorescence compared to the surrounding parenchyma. Because of this consistent behaviour the autofluorescence is of great importance as an intrinsic marker of malignant tumours.

By adding different tumour-marking substances, such as various porphyrin containing drugs, the demarcation between malignant and normal tissue can be further enhanced. The most commonly used substance up till now has been a haematoporphyrin derivative (HPD, Photofrin®) which has an emission in the red wavelength region with a dual-peaked fluorescence at 630 and 690 nm. As malignant tumour tissue retains the substance to a higher degree compared to normal tissue, the fluorescence signal in the red wavelength region is specifically related to tumour tissue. By forming the ratio between the red exogenous-related fluorescence, which increases in tumour tissue and the autofluorescence, which decreases, the tumour demarcation criterion is enhanced. If sensitive detection equipment is used, low-dose administration of the tumour-markers is sufficient^{4,5}. Besides the enhanced contrast, the evaluation of two intensities yields dimensionless data, reducing influences of certain artefacts of particular importance in clinical situations, such as all kinds of uncontrolled movements caused by the patient's breathing and heart and vessel pulsation. Furthermore, it also cancels out variations in the excitation light energy and detection system sensitivity, tumour topology and distances between the optical probe and the tissue under investigation.

In the present paper several examples from clinical fluorescence diagnostic studies, employing a point monitoring and a multi-colour fluorescence imaging system, will be presented. Detailed information from the different clinical specialities is presented elsewhere⁵⁻⁷.

2. MATERIALS AND METHOD

A fibre optically based mobile clinical fluorosensor as shown in Figure 1 was utilized for the spectral characterisation of different malignant lesions and surrounding normal tissue in connection with the administration of tumour marking substances or utilizing the autofluorescence only⁸. The fluorescence monitoring was performed with a 600 μ m fibre as point measurements most often along a line to form scans through the tumour lesions with normal tissue on the side. The fluorosensor is equipped with a small sealed-off pulsed nitrogen laser which is used alone or in

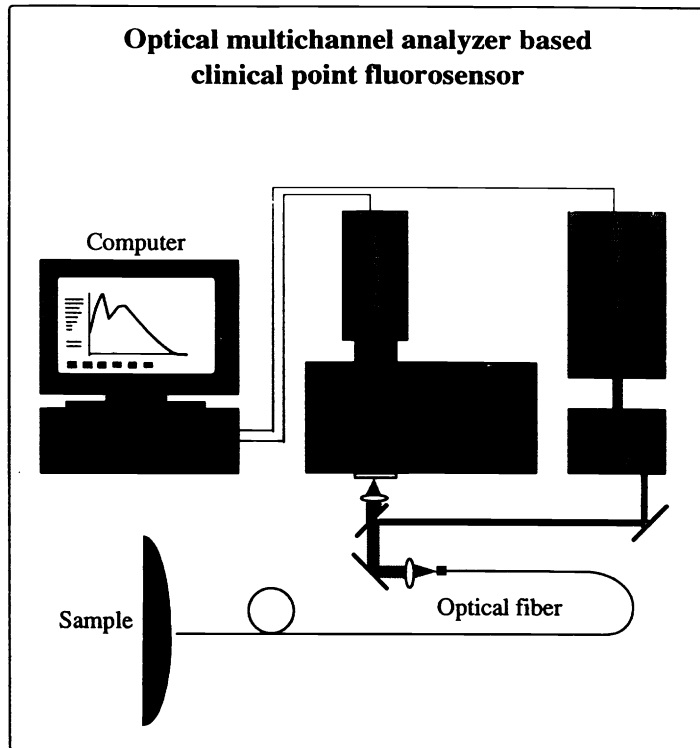


Figure 1. Schematic diagram of the optical arrangement of the mobile laser-based fluorosensor for clinical use.

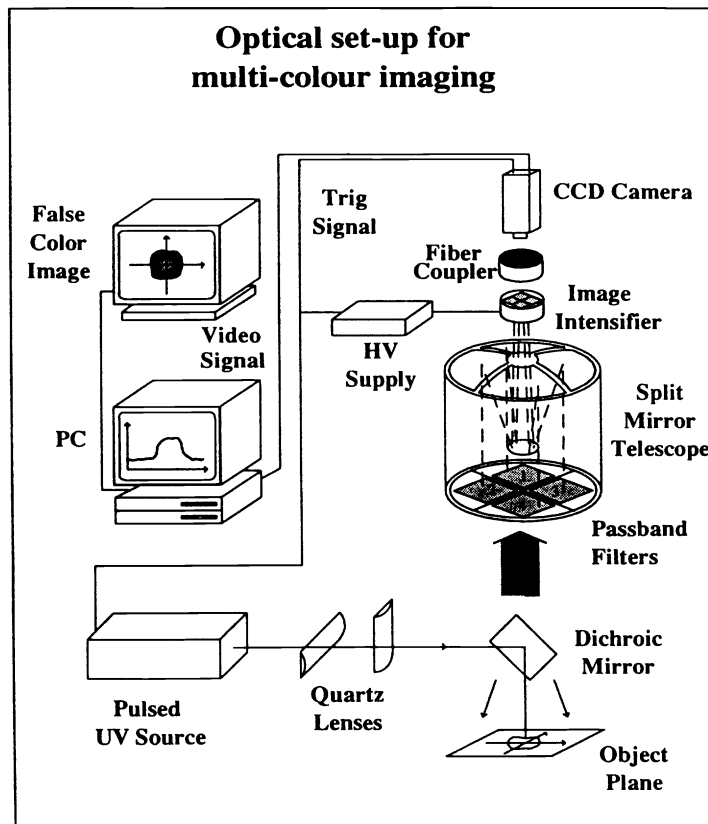


Figure 2. Schematic arrangement of the fluorescence imaging system. The split mirror arrangement in the Cassegrainian telescope is seen with suitable filters (marked 1-4) arranged to form four identical images on the image intensifier. Contrast functions are formed and a processed image presented as a false colour image on the screen.

conjunction with a dye laser as an excitation source. The excitation light is transmitted to the sample through an optical fibre, out of which the last part can be sterilized as required. The fluorescence light is collected in the same fibre and filtered through a cut-off filter to suppress the laser light and focused onto the entrance slit of a polychromator. An EG&G OMA III multichannel analyzer equipped with an intensified array detector was used to record the spectra. The spectra were stored on floppy disks for evaluation. Figure 2 shows a multi-colour fluorescence system that was used for images of larger tissue areas of about 2 cm². The system is a prototype of a system being developed for clinical use. It is equipped with a Cassegrainian telescope with a split mirror arrangements in order to produce four identical images of the tissue under investigation. By placing suitable filters in front of each segment the images are produced in different colour bands. Contrast functions are formed and an enhanced tumour image is processed⁹.

The investigations were performed *in vivo* in 71 patients and *in vitro* in additional 20 surgical samples from patients. The *in vivo* measurements included 51 patients going through endoscopic procedures (bronchoscopy in 30; cystoscopy in 21 patients). Twenty further patients were investigated in connection with surgical resection of different types of malignant glioma brain tumours. In 46 of the patients the autofluorescence only was monitored. In 45 patients Photofrin injection was performed 24-48 hours prior to the investigation normally in a low-dose (0.35-0.5 mg/kg b.w.). Out of the 20 *in vitro* investigations performed on surgically removed tissue samples sensitized with low-dose Photofrin, 15 patients were treated for breast tumours and 5 for tumours in the prostatic gland.

In the *in vivo* investigations biopsies were collected from spots monitored by fluorescence and afterwards the fluorescence signals were correlated to the histopathological results. The surgical samples were investigated directly after the removal and the point monitoring was performed along a line marked with tattoo ink and with a ruler for distance control. In some of these samples, tissue images were also recorded. Full-size sections were prepared afterwards and the spectral characterization was correlated with the histopathological investigation.

3. TISSUE FLUORESCENCE

3.1. Malignant urinary bladder tumours

Superficial papillary tumours of the urinary bladder are easy to recognize by the naked eye. The localization of severe dysplasia and carcinoma *in situ* in the bladder is much more difficult and the routine work has to rely on randomized biopsy sampling without any guiding if the lesions do not show any visible sign. Although very small and thin lesions, carcinoma *in situ* is potentially a dangerous disease. Therefore, it would be of great value to be able to identify the lesion and guide the biopsy sampling to the malignant spots in the bladder wall. Laser-induced fluorescence might be such a diagnostic tool, as the fluorescence emission from transforming tissue seems to be altered before changes in the cell architecture result in changes in the reflected light characteristics identified as reddening areas or irregularities in the tissue structure.

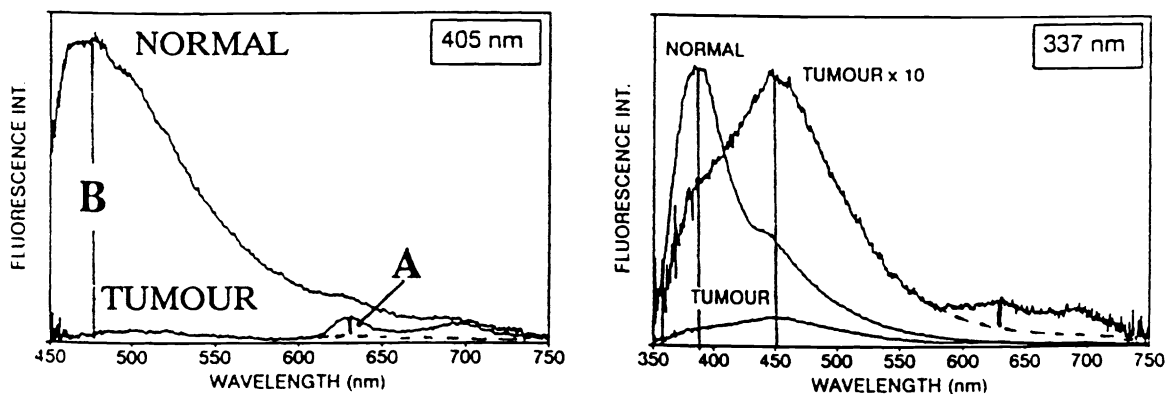


Figure 3. Illustration of *in vivo* recorded fluorescence spectra of a bladder tumour and normal bladder wall excited with 405 and 337 nm laser light, respectively. The patient had received 0.35 mg/kg b.w. of Photofrin 48 hours prior to the cystoscopic procedure. The Photofrin-related signal is seen as a dual-peaked fluorescence with its first peak at 630 nm marked with an A to the right in the figure. The autofluorescence (marked B) shows a clear decrease in tumour tissue. A wavelength shift of about 60 nm towards the red wavelength region is seen in the tumour as compared to normal tissue when excited with the nitrogen laser (337 nm).

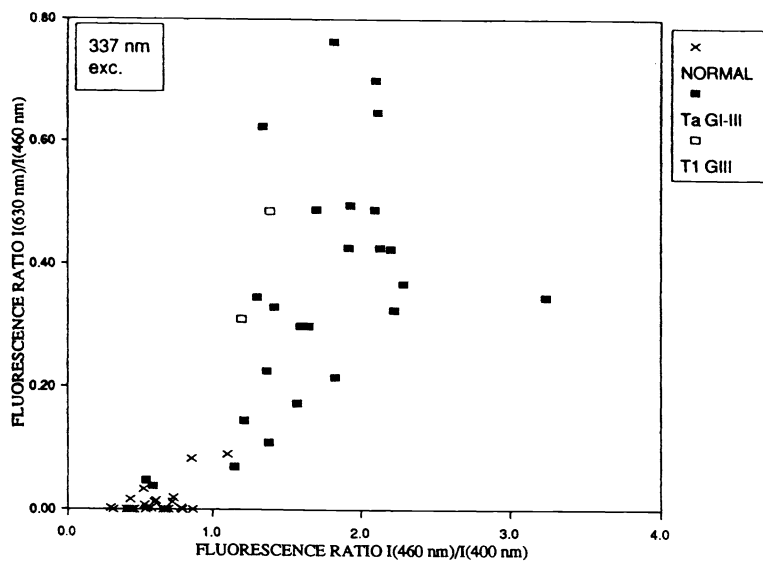


Figure 4. Diagram of data evaluated for two spectral ratios, one Photofrin-dependent ratio (630/460 nm) and one Photofrin independent ratio (460/400 nm) in bladder tumour patients injected with a low dose (0,35 mg/kg b.w.) of Photofrin 24 hours prior to the *in vivo* investigation.

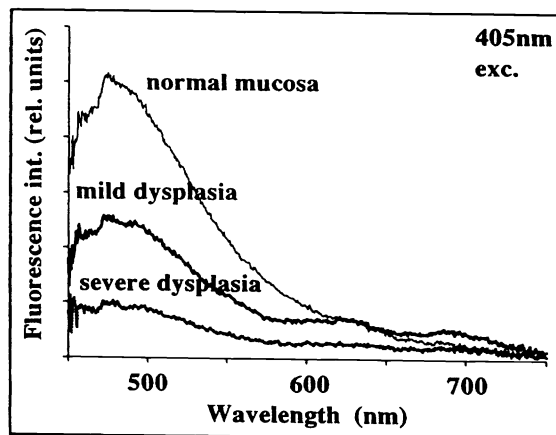


Figure 5. Fluorescence spectra from normal mucosa and different degree of dysplastic bladder mucosa. The excitation wavelength used was 405 nm and the patient was pretreated as described in Figure 3.

The urinary bladder was investigated *in vivo* in twenty-one patients to whom Photofrin in a low dose of 0.5 or 0.35 mg/kg b.w. was administered 48 hour prior to the fluorescence monitoring⁷. The diagnostic investigation was performed in connection with planned cystoscopic procedures for the purpose of tumour treatment utilizing a thermal Nd:YAG laser of already known tumours or in cases with positive exfoliative cytology tests. The fluorescence investigation was performed with the optical fibre placed in the biopsy channel of a straight cystoscope. The diagnostic part of the investigation took place before the laser treatment started. After the Nd:YAG treatment the fluorescence investigation was repeated in the treated areas and in cases of remaining tumour signal a second round of thermal shaving was performed in the area.

Fluorescence excitation light at two different wavelengths, 337 and 405 nm, was used in order to investigate the fluorescence both from the autofluorescence and the sensitizer. Examples of *in vivo* fluorescence spectra from a superficial bladder tumour and surrounding normal mucosa are shown for the two excitation wavelengths in Figure 3. As can be seen, the autofluorescence intensity in tumour tissue at about 490 nm (denoted B) is very low for both excitation wavelengths. In the magnified tumour spectrum to the right also a wavelength shift of about 60 nm towards the red region is seen for the tumour tissue. The explanation of this phenomenon might be a lack of one or two chromophore types in the tumour surface as compared to the normal bladder mucosa. The drug-related signal at 630 nm (marked with an A) is easily recognizable in the spectrum excited at 405 and also seen with the 337 nm excitation. The ratio A/B for the excitation of 405 nm is about 2 and 0.025 for tumour and normal tissue, respectively. Thus, the tumour demarcation ($(A/B)_{\text{tumour}}/(A/B)_{\text{normal}}$) is about 80 as compared with about 2 if only the A signal is used as a demarcation criterion.

In Figure 4 two different fluorescence intensity ratios are presented for the excitation at 337 nm. One $I(630)/I(460)$ represents the drug dependent ratio, while the other, $I(460)/I(400)$, only takes into account the variation in autofluorescence. The ratios are formed in a way that tumour tissue results in high numbers and normal in low values. As can be seen, all the normal tissue points, with only a few exceptions, fall within the lower left while the tumour tissue exhibits higher values and thus locate themselves within the right upper part.

Figure 5 shows fluorescence spectra from normal bladder mucosa and early transformed tissue with two different grades of dysplasia. As can be seen the autofluorescence intensity exhibits a gradual fall-off going from normal mucosa to severe dysplasia. Drug-related fluorescence is seen in the two spectra from the dysplasia while the normal mucosa does not show any red fluorescence signal. It should be noted that dysplasia is located superficially above the basal membrane and is thus not directly supplied with blood vessels.

3.2. Malignant tumours of the prostatic gland

Specimen of excised prostatic glandular tissue was investigated in five patients who had been injected with a low dose (0.35 mg/kg b.w.) of Photofrin 24 hours before the surgical procedure. The specimen were cut in slices and the fluorescence was monitored. Afterwards full-size sections were prepared for histopathology and the fluorescence characteristics were correlated to tissue type.

In vitro fluorescence spectra in a tumour bearing prostatic gland using low dose Photofrin injection (0.35 mg/kg b.w.)

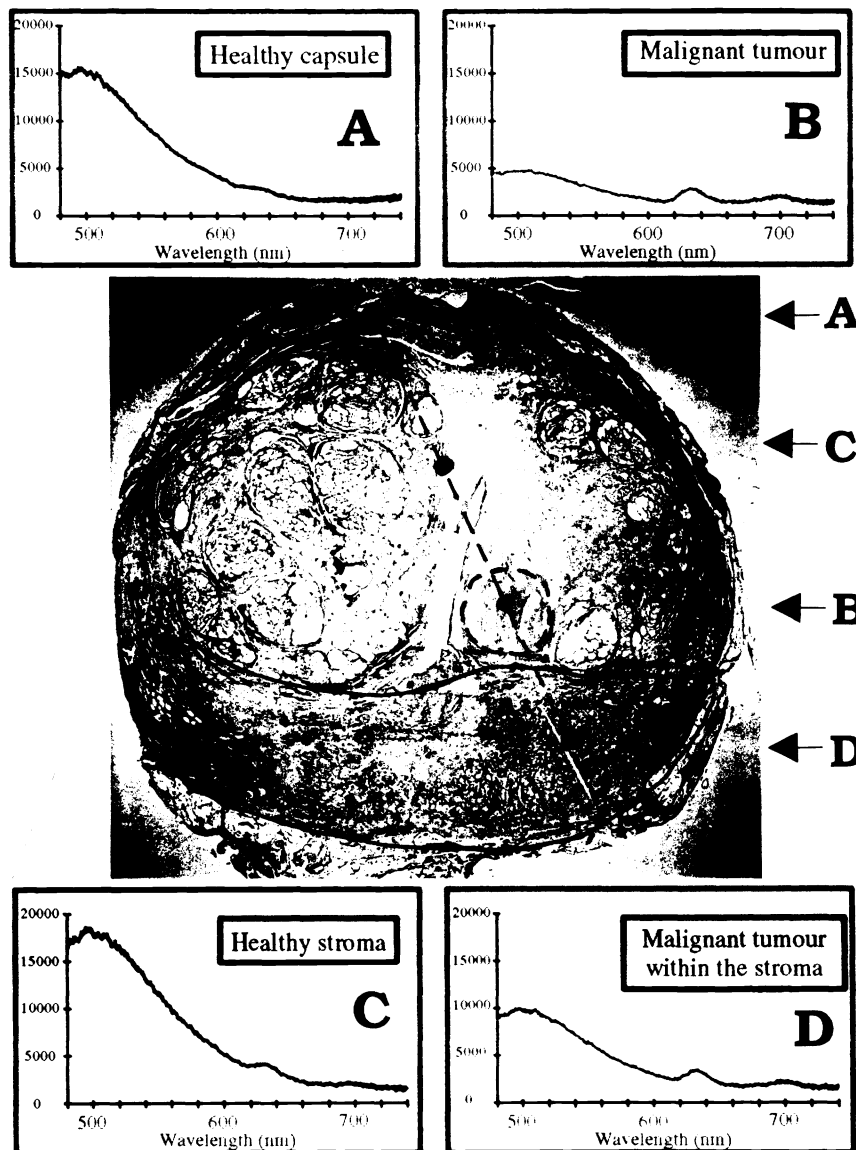


Figure 6. Four different fluorescence spectra recorded *in vitro* in prostatic glandular tissue from a patient pretreated with low-dose Photofrin (0.35 mg/kg b.w.) 24 hours before the investigation. The full-size histopathological section marked with the points investigated (A-D) is shown together with the previously know tumour area (B) and the area (D), which shows tumour suspicious fluorescence signals *in vitro* and later was verified as tissue with tumour infiltration.

In Figure 6 an example from one patient is shown with the histopathological section of the whole prostatic gland in the middle and surrounding the photo four different fluorescence spectra. When the patient was planned for the surgical procedure the tumour located to the right in the figure (B) was known and also verified with a cytological aspiration test. The specimen was investigated by fluorescence along a line with measurements every 2 mm out of which four are marked in the figure. As can be seen the healthy capsule tissue (marked with an A) is characterized by a high autofluorescence intensity and almost no porphyrin-related fluorescence. The same signature is seen also for the healthy stroma (marked C) even if the spot that was measured is located at the border of a hyperplastic region with higher biological activity compared to the capsule region. The malignant tumour (B) is characterized by a very low autofluorescence intensity and a clear porphyrin-related signal. The last spot (marked D) showed up in the fluorescence measurements as a suspicious area but was not at the time for fluorescence monitoring known as malignant. However, the histopathology revealed tumour invasion into the slight hyperplastic region within all the marked area.

3.3. Malignant lung tumours

Fluorescence bronchoscopy was performed in 30 patients with different kinds of lung tumours⁷. In three cases the investigation was performed in connection with Photofrin injection at two doses, 1 and 2 mg/kg b.w, out of which the higher dose was used in connection with photodynamic treatment. One of the 30 patients was referred for fluorescence bronchoscopy because he had an occult tumour meaning that only cytological tests had shown malignant cells but no known tumour site, since it was impossible to localize with conventional diagnostic procedures. The patient had received 1 mg/kg b.w. of Photofrin 48 hours before the bronchoscopy. The fluorescence investigation revealed one area in the bronchus with suspicious spectral characteristics in the region in between the distal part of the right upper main bronchus and one of the three smaller as seen in Figure 7. The autofluorescence shows about half intensity in the early tumour as compared to the normal mucosa and the porphyrin related background-free signal about 3 times higher intensity in tumour tissue. Biopsy sampling was performed from the region and the malignancy had developed into a minimal invasive tumour and the upper right lobe had to be removed.

Another example from a fluorescence bronchoscopy investigation is shown in Figure 8. Also in this case the autofluorescence shows about half the intensity in tumour as compared to normal surrounding mucosa. Beside the peak in the autofluorescence at about 490 nm (B) and the porphyrin related dual-peaked background-free fluorescence at 630 and 690 nm (A and C) the wavelength at 600 nm (D) is marked. In the multi-colour fluorescence imaging system the fluorescence intensity at 600 nm is used for the subtraction of the background signal at 630 nm.

3.4. Malignant tumours of the breast

Cancer of the breast is the most common malignancy in the female population. The diagnostic procedure of the suspicious tissue in the breast relies on manual palpation, X-ray mammography

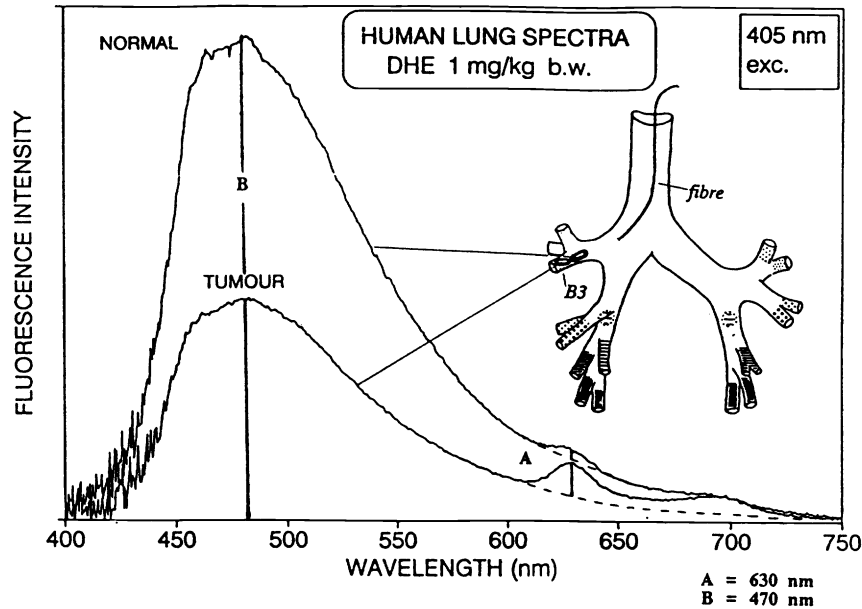


Figure 7. *In vivo* fluorescence spectra following 405 nm excitation recorded from an early bronchial squamous cell carcinoma lesion and normal surrounding mucosa in a patient who was injected with 1 mg/kg Photofrin 48 h prior to the examination. The location of the minimal invasive squamous cell carcinoma lesion in the right bronchus (marked B3) and the corresponding fluorescence spectrum as well as the normal mucosal area and spectrum are shown. The fibre was placed in the biopsy channel of a standard bronchoscope.

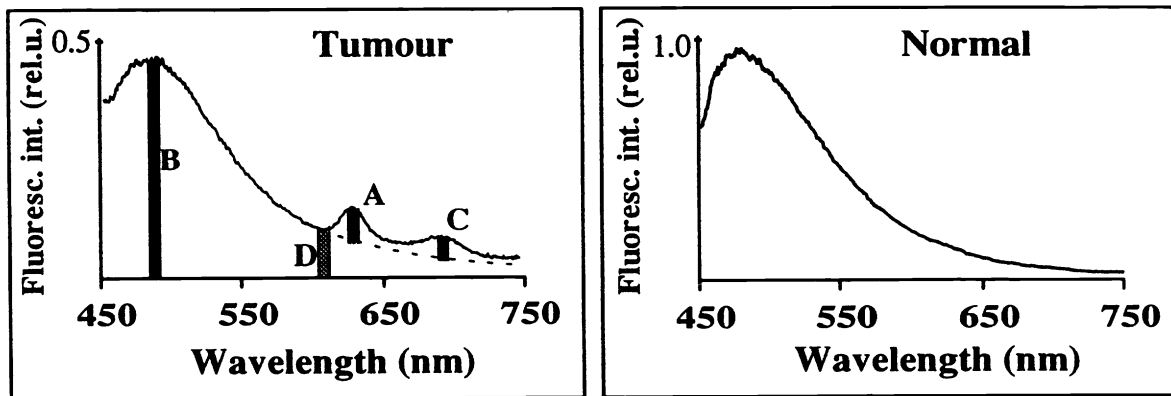


Figure 8. *In vivo* fluorescence spectra recorded during a bronchoscopy procedure in a patient with an early squamous cell carcinoma. The patient was injected with a low dose of (1 mg/kg b.w.) of Photofrin 24 hours before the investigation. The tumour spectrum is characterized by the dual-peaked Photofrin-related fluorescence in the red wavelength region. The total intensity at about 600, and the background-free signal at 630 and 690 nm are marked (D, A and C). The dotted line delineates the slope of the autofluorescence showing the background that is subtracted from the total intensity at 630 and 690 nm. The intensity at 600 nm (D) multiplied with an empirically calculated constant is used in the imaging system for the background subtraction.

and fine needle aspiration for cytological investigation. The X-ray mammography examination is itself under debate due to recent findings about a specific gene (Ataxia-telangiectasia gene) which predisposes the individuals carrying this autosomal recessive syndrome to develop cancer, especially breast cancer. The risk increase is about 100 times as compared with the population not carrying the specific gene and the risk is further increased in connection with diagnostic radiology¹¹. It is also known, that the X-ray mammography is less valuable in women under the age of about forty years, due to the fact, that they often have dense breast tissue with decreased possibility for tumour visualization. The tumour visibility in X-ray produced images is also related to indirect signs of tumour, such as microcalcifications and retraction phenomenon. The lobular cancers and also some ductal tumours with comedo (necrosis) structures are sometimes difficult to visualize by X-ray mammography as they do not show these indirect tumour signs. The fine needle aspiration may also fail to hit the diseased area. A complementary diagnostic method in the characterization of breast tissue might be laser-induced fluorescence to be used interstitially in connection with the cytological probing or per-operatively to visualize the tumour borders and thus revealing the degree of surgical radicality.

Laser-induced fluorescence was utilized for the postoperative monitoring of the fluorescence emission from breast specimen in patients undergoing surgical excision of their tumours⁶. The patients were pretreated with a low dose (0.35 mg/kg b.w.) of Photofrin 24 hours prior to the investigation. Figure 9 shows four *in vitro* fluorescence spectra from a patient with a small ductal carcinoma with surrounding normal breast parenchyma. The healthy breast tissue is characterized by a high autofluorescence signal and a very small drug-related signal. The tumour border shows a drastic decrease in the endogenous fluorescence signal. The two spectra recorded in tumour areas are characterized by a low intrinsic fluorescence signal and a marked dual-peaked fluorescence.

Multi-colour fluorescence images in the wavelength bands 470, 600 and 630 nm are shown together with the processed image of a 2 cm² breast specimen in Figure 10. The autofluorescence at 470 nm shows an uneven spread of the fluorescence intensity over the whole area. An area of high autofluorescence signal can be identified in the lower right part of the 470 nm image corresponding to a bundle of collagen structures outside the tumour area. Also a ring-like structure with higher intensity can be identified in the upper part of the image. This area with high intensity is located just outside the visible tumour border zone and might reflect a high content of the reduced form of nicotinamide adenine dinucleotide (NADH), known to be present in tissue of high biological activity¹¹. The tumour area inside the ring-like structure on the other hand shows a low intensity in the 470 nm fluorescence band, which might be explained by a low content of NADH and a high content of the oxidized form, NAD⁺.

The fluorescence image at 630 nm gives an illustration of what already was illustrated in Figure 7. The total fluorescence light emission at 630 nm is as high in normal tissue as is malignant tumours due to the higher over-all fluorescence intensity. The processed image show the small tumour surrounded by the collagenous tissue.

In vitro fluorescence spectra in resected breast
using low dose Photofrin injection (0.35 mg/kg b.w.)

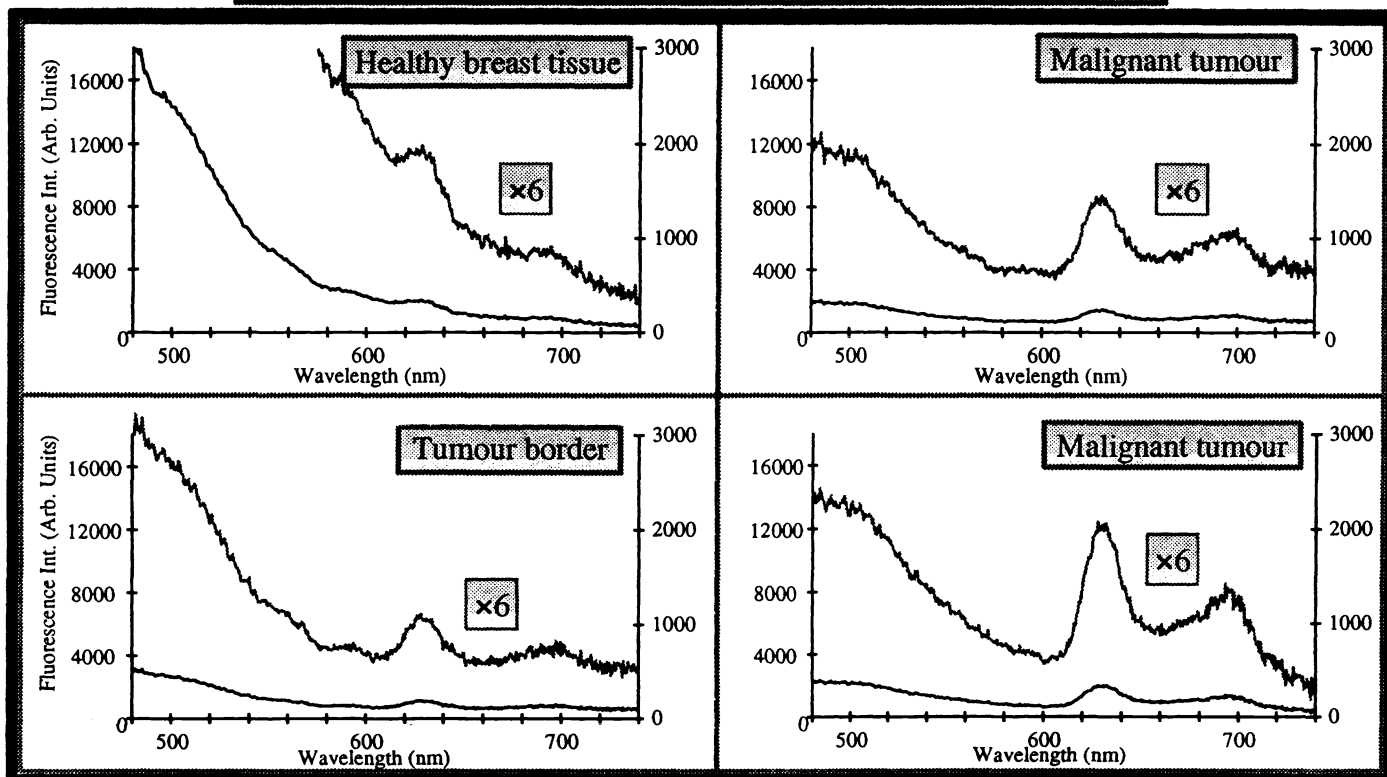


Figure 9. *In vitro* fluorescence spectra from a resected breast specimen with an invasive ductal carcinoma. All spectra are also shown with a six-fold magnification. The healthy breast parenchyma is seen with a high fluorescence intensity. The malignant tumour and the tumour border exhibit a very low autofluorescence signal and a clear porphyrin-related dual-peaked signal. The patient was injected with low-dose Photofrin (0.35 mg/kg b.w.) 24 hours before the investigation.

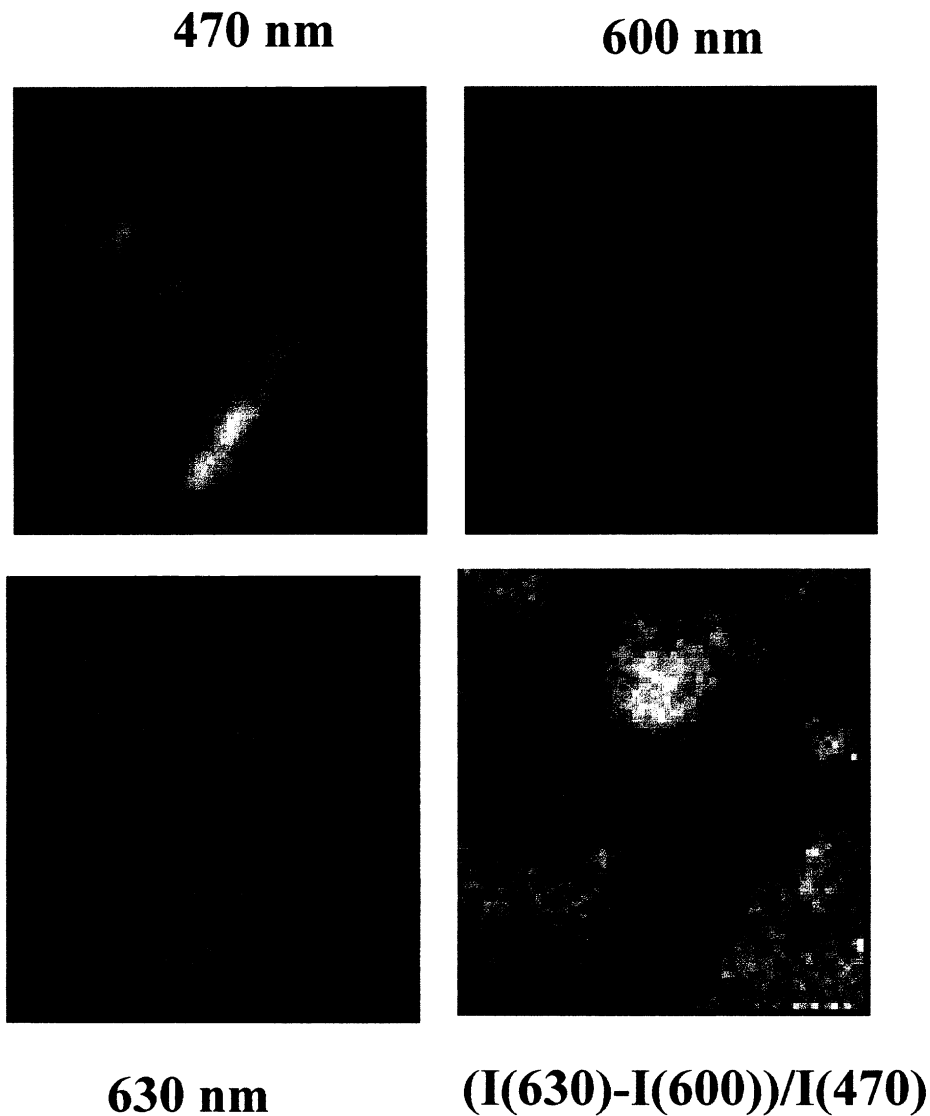


Figure 10. Three images at different wavelength bands (470, 600 and 630 nm) and a tumour contrast enhanced image of an identical tissue area in an excised breast specimen in a low-dose Photofrin injected patient with an invasive ductal carcinoma. The tumour is seen at the upper part of the contrast enhanced image.

4. CONCLUSION

In many clinical situations there is a specific need for a real-time working non-invasive instrumentation for early tumour detection and for directed guiding of the biopsy sampling. Laser-induced fluorescence has been proven efficient to demarcate tumour lesions including very early malignancies and might be developed into a powerful complementary diagnostic tool. It has been shown that the intrinsic fluorescence characteristics alter very early in the biological process from normal to malignant tissue. By adding tumour-marking substances, the tumour identification can be further enhanced. The clinical application of the method relies on the possibility to develop feasible instrumentation. Comparatively inexpensive point monitoring systems are available. The multi-colour fluorescence equipment is expensive but exhibits a versatility for the use in many different clinical situations.

5. ACKNOWLEDGEMENTS

The collaboration with all the researchers and clinicians within the Lund Medical Laser Centre is highly appreciated. Special thanks are due to Professor Dick Killander for his enthusiasm and support within the field of early tumour diagnostics. We are grateful for the economical support from the Swedish Cancer Society, the Board for Industrial and Technical Development, and the Kamprad Foundation.

6. REFERENCES

1. A.E. Profio and O.J. Balchum, "Fluorescence Diagnosis of Cancer", *Methods in Porphyrin Photosensitization* (D. Kessel, ed.), Plenum Press, New York, pp. 43-50 (1985).
2. J. Ankerst, S. Montán, K. Svanberg and S. Svanberg, "Laser-Induced Fluorescence Studies of Hematoporphyrin Derivative (HPD) in Normal and Tumor Tissue of Rat", *Appl. Spectr.*, 38, 890-96 (1984).
3. K. Svanberg, E. Kjellén, J. Ankerst, S. Montán, E. Sjöholm and S. Svanberg, "Fluorescence Studies of Hematoporphyrin Derivative in Normal and Malignant Rat Tissue", *Cancer Res.*, 46, 3803-08 (1985).
4. S. Lam, B. Palcic, D. McLean, J. Hung, M. Kobelick, A.E. Profio, "Detection of Early Lung Cancer Using Low-Dose Photofrin II", *Chest*, 97, 333-37 (1990).
5. L. Baert, R. Berg, B. van Damme, M.-A. D'Hallewin, J. Johansson, K. Svanberg and S. Svanberg, "Clinical Fluorescence Diagnosis of Human Bladder Carcinoma Following Low-Dose Photofrin Injection", *Urology*, 41, 322-30 (1993).
6. I. Wang, S. Andersson-Engels, I. Idwall, Ch. Ingvar and K. Svanberg, "In-Vitro Fluorescence Studies of Breast Tumours Following Low-Dose Injection of Photofrin", *SPIE*, 2135-37 (1994).

7. S. Andersson-Engels, R. Berg, S. Colleen, J. Johansson, S.-E. Karlsson, R. Lundgren, L.G. Salford, L.-G. Strömblad, K. Svanberg and S. Svanberg, "In vivo Fluorescence Spectra of Malignant Lesions in Various Specialities", *Photodynamic Therapy and Biomedical Lasers* P. Spinelli, M. Dal Fante and R. Marchesini (eds.), Excerpta Medica, Amsterdam, pp.871-75 (1992).
8. S. Andersson-Engels, Å. Elner, J. Johansson, S.-E. Karlsson, L.G. Salford, L.-G. Strömblad, K. Svanberg and S. Svanberg, "Clinical Recordings of Laser-Induced Fluorescence Spectra for Evaluation of Tumour Demarcation Feasibility in Selected Clinical Specialities", *Lasers Med. Sci.*, 6, 415-24 (1991).
9. P.S. Andersson, S. Montán and S. Svanberg, "Multispectral System for Medical Fluorescence Imaging", *IEEE J Quant. Electr.*, QE-23, 1798-805 (1987).
10. M. Swift, D. Morell, R.B. Massey, C.L. Chase, "Incidence of Cancer in 161 Families Affected by Ataxia-Telangiectasia", *New Engl. J Med.*, 325 1831 (1991).
11. W. Lohmann, J. Mussmann, C. Lohmann and W. Künzel, "Native Fluorescence of the Cervix Uteri as a Marker for Dysplasia and Invasive Carcinoma", *Eur. J Obstet. Gynecol, Reprod. Biol.*, 31, 249-53 (1989).