



LUND UNIVERSITY

Do mammographic tumor features in breast cancer relate to breast density and invasiveness, tumor size, and axillary lymph node involvement?

Sartor, Hanna; Borgquist, Signe; Werner Hartman, Linda; Olsson, Åsa; Jawdat, Faith; Zackrisson, Sophia

Published in:
Acta Radiologica

DOI:
[10.1177/0284185114532081](https://doi.org/10.1177/0284185114532081)

2015

[Link to publication](#)

Citation for published version (APA):

Sartor, H., Borgquist, S., Werner Hartman, L., Olsson, Å., Jawdat, F., & Zackrisson, S. (2015). Do mammographic tumor features in breast cancer relate to breast density and invasiveness, tumor size, and axillary lymph node involvement? *Acta Radiologica*, 56(5), 536-544. <https://doi.org/10.1177/0284185114532081>

Total number of authors:
6

General rights

Unless other specific re-use rights are stated the following general rights apply:
Copyright and moral rights for the publications made accessible in the public portal are retained by the authors and/or other copyright owners and it is a condition of accessing publications that users recognise and abide by the legal requirements associated with these rights.

- Users may download and print one copy of any publication from the public portal for the purpose of private study or research.
- You may not further distribute the material or use it for any profit-making activity or commercial gain
- You may freely distribute the URL identifying the publication in the public portal

Read more about Creative commons licenses: <https://creativecommons.org/licenses/>

Take down policy

If you believe that this document breaches copyright please contact us providing details, and we will remove access to the work immediately and investigate your claim.

LUND UNIVERSITY

PO Box 117
221 00 Lund
+46 46-222 00 00

Do mammographic tumor features in breast cancer relate to breast density and invasiveness, tumor size, and axillary lymph node involvement?

Hanna Sartor¹, Signe Borgquist^{2,3}, Linda Hartman^{2,4}, Åsa Olsson⁵, Faith Jawdat¹,
Sophia Zackrisson¹

¹Diagnostic Radiology, Lund University, Diagnostic Center for Imaging and Functional Medicine, Skåne University Hospital, Malmö, Sweden

²Division of Oncology, Department of Clinical Sciences, Lund University, Lund, Sweden

³Department of Oncology, Skåne University Hospital, Lund, Sweden

⁴Regional Cancer Center South, Lund, Sweden

⁵Department of Surgery, Lund University, Skåne University Hospital, Malmö, Sweden

Corresponding author:

Hanna Sartor, MD

Department of Clinical Sciences in Malmö

Diagnostic Radiology, Lund University

Diagnostic Center for Imaging and Functional Medicine

Skåne University Hospital

Inga Marie Nilssons gata 49

SE 205 02 Malmö, Sweden

Email: Hanna.Sartor@med.lu.se

Tel: +46-705217925, Fax: +46-40-337062

Do mammographic tumor features in breast cancer relate to breast density and invasiveness, tumor size, and axillary lymph node involvement?

Abstract

Background: Breast density and mammographic tumor features of breast cancer may carry prognostic information. The potential benefit of using the combined information obtained from breast density, mammographic tumor features, and pathological tumor characteristics has not been extensively studied.

Purpose: To investigate how mammographic tumor features relate to breast density and pathological tumor characteristics.

Material and Methods: This retrospective study was carried out within the Malmö Diet and Cancer Study: a population-based cohort study recruiting 17 035 women during 1991-1996. A total of 826 incident breast cancers were identified during follow-up. Mammography images were collected and analyzed according to breast density and tumor features at diagnosis. Pathological data were retrieved from medical reports. Mammographic tumor features in relation to invasiveness, tumor size, and axillary lymph node involvement were analyzed using logistic regression yielding odds ratios

(OR) with 95% confidence intervals (CI) and adjusted for age at diagnosis, mode of detection, and breast density.

Results: Tumors presenting as an ill-defined mass or calcifications were more common in dense breasts than tumors presenting as a distinct mass or with spiculated appearance. Invasive cancer was more common in tumors with spiculated appearance than tumors presenting as a distinct mass, (adjusted OR 5.68 (1.81-17.84)). Among invasive tumors, an ill-defined mass was more often large (>20mm) compared with a distinct mass, (adjusted OR 3.16 (1.80-5.55)).

Conclusion: Tumors presenting as an ill-defined mass or calcifications were more common in dense breasts. Spiculated appearance was related to invasiveness, and ill-defined mass to larger tumor size, regardless of mode of detection and breast density. The potential role of mammographic tumor features in clinical decision-making warrants further investigation.

Keywords

breast, mammography, epidemiology, adults, neoplasms-primary, pathology

Introduction

Mammography is the gold standard for breast imaging in the clinical setting and in population-based screening. Several studies have reported a higher breast cancer

incidence for women with dense breasts compared to women with less dense breasts (1). Mammography is less sensitive for the detection of breast cancer in women with dense breasts (2-4) as high breast density deteriorates mammographic detection of breast cancer, creating a masking effect. The likelihood of detecting breast cancer with mammography may also be affected by mammographic tumor growth features (5). Various mammographic tumor features have been found to be associated with histopathological findings (5-8) and may have prognostic value (7-10). Mammographic spiculation has been suggested as a positive prognostic marker due to the correlation with low-grade tumors and improved survival (7-9). The correlation between calcifications and survival has been inconsistent with some studies reporting comedo calcifications to be associated with poor prognosis (8, 10), whereas others report no association (7, 11). Ill-defined masses on mammography have been associated with prognostically unfavorable tumor factors, such as a high grade or large tumor size (6). Few previous studies have analyzed the potential benefit of using the combined information obtained from mammographic tumor features, breast density, and pathological tumor characteristics. Such associations may provide early prognostic information to facilitate adequate clinical decision-making.

The aim of this study was to investigate mammographic tumor features and breast density, and assess the correlation to established pathological tumor characteristics in

the cohort of incident breast cancer cases within the Malmö Diet and Cancer Study (MDCS).

Material and Methods

The Malmö Diet and Cancer Study

The Malmö Diet and Cancer Study (MDCS) is a population-based, prospective cohort study with the intent to explore the possible relations between life-style factors and cancer. A total of 28 098 individuals were enrolled between 1991 and 1996 with a participation rate of approximately 40% (12). The female cohort consisted of 17 035 women. The baseline examinations included anthropometric measures, blood samples and a questionnaire on socio-demographics, reproductive factors, life-style, medication, and health status. The details of MDCS have been described previously (13, 14). The participants in the MDCS signed written informed consent at the baseline. Through subsequent advertisements, information on additional planned analyses and the option to withdraw was provided. No renewed contacts with participants or their relatives were established for this study. The present retrospective study was approved by the Ethical Committee at Lund University (Dnr 652/2005 and Dnr 166/2007).

Identification of breast cancer cases within the MDCS cohort

The MDCS cohort is continuously updated regarding incident cancer cases and causes of death through record-linkage to national registries, i.e. the Regional Tumor Registry for Southern Sweden, the Swedish Cancer Registry and the Swedish Cause of Death Registry held by the National Board of Health and Welfare. Between 1991 and 2007, 826 incident breast cancer cases were diagnosed among women in the MDCS. Women with a history of breast cancer at baseline (n=576) were excluded in the present study as recurrent breast cancer may differ from incident breast cancer in terms of risk factors and biomarkers. Of the 826 incident breast cancer cases, 15 women with bilateral tumors were excluded due to the difficulty of retrospectively evaluating information on tumor characteristics and mammography data for these cases. The study population is illustrated in Fig. 1.

Clinical and pathology information

Tumor tissue was collected and stored in the biobank at the Department of Pathology, Skåne University Hospital, Malmö, Sweden. Clinical pathological tumor data, such as histological tumor type, tumor size at pathology (pT), histological grade, invasiveness, and axillary lymph node involvement (ALNI), were assessed. The cases diagnosed between 1991 and 2004 were re-evaluated regarding histological tumor type and histological grade by one senior breast pathologist (15). For the cases diagnosed between 2005 and 2007, the information was retrieved from pathology reports. For 129

cases, information on ALNI was missing, most likely since the pre-operative evaluation indicated no need for axillary dissection for most of these cases. If these 129 cases were to be excluded from analyses, a considerable risk of selection bias would be expected as most of these cases probably represented ALNI negative breast cancers. Consequently, 117 patients with a tumor size less than or equal to 20 mm who had no distant metastases at diagnosis or had a cancer *in situ* were re-classified as ALNI negative. Four cases with missing information on ALNI and with distant metastases at diagnosis were reclassified as ALNI positive. Eight cases retained the missing classification.

Mammographic information

We retrospectively collected information from the radiology reports at the incident mammogram (i.e., the mammogram closest to the date of diagnosis) at the institution. In case of insufficient information regarding breast density and mammographic tumor features, the images were ordered and re-read. A protocol was established to collect the following information from the reports: the mode of detection, breast density and mammographic tumor features. The variables are described in details below. The detection mode was defined as screening (including opportunistic screening) or clinical (i.e., cancers in women with symptoms in the breasts). For seven cases, information regarding the mode of detection (screening vs. clinical) was missing. The clinical cases included at least three images per breast (craniocaudal (CC), mediolateral oblique

(MLO) and mediolateral (ML) view) and additional special projections, e.g. magnification views, spot views. The tumors detected during screening had one set of screening mammograms (CC and MLO) and additional images from the diagnostic work-up at the recall, which usually included a ML view and special views of the affected breast. The breast-screening programme in Malmö was introduced in 1990, and during the study interval, all women age 50-69 (1990-1996) and 50-74 (1997-2007) were invited to participate at 1.5- to 2-year intervals. The MDCS women in the screening ages and living in Malmö have hence been invited. The attendance rate at screening in the MDCS cohort was high, ranging from 87.6% to 94.5% during the study period (16).

Breast density

Breast density was estimated qualitatively and reported by experienced breast radiologists during the initial evaluation of the diagnostic mammogram. Three categories were routinely reported: “fat involuted”, “moderately dense” and “dense”. The classification can be regarded as a modification of the Breast Imaging Reporting and Data System (BI-RADS) density categorisation (17); “fat involuted” corresponds to BI-RADS 1 (almost entirely fat), “moderately dense” to BI-RADS 2+3 (scattered fibroglandular densities and heterogeneously dense) and “dense” to BI-RADS 4 (extremely dense). Information on breast density was missing in about one third of the

cases; these mammograms were retrospectively re-read by one breast radiologist (SZ) and a trained, supervised resident in radiology (HS). A total of 64 cases retained the missing classification since no report and/or image could be located. The mammograms performed at the Department of Breast Radiology were analogue up until 2003 and digital since then.

Mammographic tumor features

For the present study, the dominant mammographic tumor feature was extracted from the mammography reports and defined according to the following classification: mass (well-defined, partly ill-defined or ill-defined/diffuse), spiculated mass, architectural distortion or asymmetric density. Micro-calcifications were categorized as either comedo-type or non-specific calcifications. These categories were based on the classification by Luck et al. (5). The most dominant mammographic tumor feature was defined as the most easily perceived abnormality, as determined by the interpreting radiologist. For the statistical analysis, the following categories were used: distinct mass (well-defined and partly ill-defined), ill-defined mass (ill-defined/diffuse), spiculated appearance, calcifications (comedo-type and non-specific calcifications), and tissue abnormality (architectural distortion and asymmetric density) (Fig. 2). The mammographic tumor feature was unclear from the reports in about one fifth of the cases; those images were re-read by one breast radiologist (SZ) and categorized

accordingly. A total of 90 cases retained the missing classification since no report and/or image could be located.

Statistical methods

The effect of each mammographic tumor feature (as a factor on 5 levels) on breast density (as an ordinal variable on 3 levels) was investigated using the Kruskal-Wallis test, followed by pairwise Mann-Whitney tests using Dunn's method. The p-values of the 10 pairwise tests are reported with and without Bonferroni correction for multiple testing. Though the latter method is overly conservative it will, together with the uncorrected p-values, help to reveal potential mass-significance. The effect of each mammographic tumor feature on the pathological factors was investigated using logistic regression yielding odds ratios (OR) with 95% confidence intervals (CI), with the mammographic tumor feature as a factor on 5 levels, and adjusted for age at diagnosis (as a linear covariate), mode of detection (binary) and breast density (as a linear covariate on levels 1, 2, and 3). The number of cases varies between analyses due to differing numbers of missing values (Table 1). A p-value of less than 0.05 was considered significant. All of the tests were two-sided. SPSS Statistics for Windows (Version 20.0. IBM Corp. Armonk, NY, USA) was used for the statistical analyses.

Results

Distribution of radiographic and pathological characteristics within the MDCS breast cancer cases

A larger proportion of the patients with a screening-detected cancer had smaller tumors (pT \leq 20mm), were less often ALNI positive, histological grade 3 or invasive, than patients with a clinically detected cancer (Table 1). No other considerable differences in proportions between the two modes of detection were identified.

Mammographic tumor features in relation to breast density

Heterogeneity in breast density across the mammographic tumor features was observed (Kruskal-Wallis p<0.001, Table 2). In all three breast density groups, tumors presenting with a spiculated appearance were the most common. In pairwise comparisons, however, a higher breast density was associated with a lower proportion of spiculated appearance. Consequently, there was a trend towards more tumors presenting with spiculated appearance in fat involuted breasts than in dense breasts. These trends with regard to breast density differed significantly among the different mammographic tumor features. Tumors presenting as an ill-defined mass, calcifications or tissue abnormality were more common in dense breasts than tumors presenting as a distinct mass or with spiculated appearance as the dominant feature. The analysis was also stratified by the mode of detection (screening- /clinical detection), invasiveness (cancer *in situ*/invasive) and tumor size in invasive cancer (small/large) (data not shown). Heterogeneity in

breast density across the mammographic tumor features was observed among screening-detected cancer (overall $p < 0.001$), invasive cancer (overall $p < 0.001$), and in invasive cancer with small tumor size (overall $p < 0.001$). However in clinically detected cancer (overall $p = 0.08$), cancer *in situ* (overall $p = 0.2$), and in invasive cancer with large tumor size (overall $p = 0.39$) no heterogeneity was observed, explained at least in part by the smaller sample size in these strata.

Mammographic tumor features in relation to established clinico-pathological factors

The impact of mammographic tumor features on the odds of the tumor being invasive, large ($pT > 20$ mm) or ALNI positive, was studied using logistic regression to adjust for age at diagnosis, mode of detection and breast density. As illustrated in Table 3, the differences found were that tumors presenting with a spiculated appearance were more likely to be invasive cancers than tumors presenting as a distinct mass. Further, tumors with calcifications as the dominant feature were significantly more likely to be a cancer *in situ* than tumors whose dominant feature was a distinct mass. Among invasive tumors, tumors presenting as an ill-defined mass or tissue abnormality appeared more often as large tumors ($pT > 20$ mm) than tumors presenting as a distinct mass. Tumors presenting with spiculated appearance were typically large at diagnosis, however, the difference to distinct mass was not statistically significant. Compared with tumors

appearing as a distinct mass, tumors appearing as calcifications were more often ALNI negative, (OR 0.52 (CI 0.26-1.05)) adjusted for age at diagnosis, mode of detection and breast density (data not shown). As shown in Table 3 when analyzing invasive cancers only, the mammographic tumor features did not differ significantly according to ALNI, although tumors presenting as an ill-defined mass and spiculated appearance tended to be ALNI positive more often than tumors whose dominant feature was a distinct mass.

Discussion

In this study, breast tumors presenting as an ill-defined tumor mass or with calcifications were more common in dense breasts. Spiculated tumor appearance was related to invasiveness, and ill-defined tumor mass and tissue abnormality to pathological tumor size, irrespective of adjustment for age at diagnosis, mode of detection, and breast density. These results may imply that variations between certain mammographic tumor features are not only an effect of masking, since the association with invasiveness and tumor size were consistent after adjustment for mode of detection and breast density. Spiculated appearance was the most common mammographic presentation, consistent with the results of previous studies (5, 6, 9). Furthermore, spiculated appearance was more common in fat involuted breasts than calcifications, tissue abnormality, or ill-defined mass, which were more common tumor presentations in dense breasts. Similar results were found among screening-detected, invasive, and

small tumors. Our results are in line with Porter et al. who reported a higher proportion of spiculated masses among women with fat involuted breasts, as well as a higher proportion of architectural distortions among women with dense breasts (18).

Furthermore, tissue abnormality, including architectural distortions, was more common in dense breasts than in fat involuted breasts which may, as suggested by Porter et al., be explained by a weakness of mammography and may not represent a biological phenomenon. A spiculated mass will appear as an architectural distortion due to the distortion of the central mass in a dense breast, whereas in a fat involuted breast, the central mass is less likely to be concealed. This theory is partly supported by initial findings in 3D mammography (breast tomosynthesis) studies, where comparisons of mammographic tumor features between 2D (mammography) and 3D showed that an ill-defined tumor in 2D is more likely to appear as a spiculated tumor in 3D, when overlapping tissues are removed (19). The fact that some mammographic tumor features are more common in dense breasts may thus be partly due to the masking effect (18).

High-contrast objects such as calcifications are less affected by increased density than low-contrast objects, such as tumor masses. This may explain why tumors presenting as calcifications in our study were more common in dense breasts than were tumors presenting as a distinct mass or with spiculated appearance. However, it still remains unclear what breast density represents at the cellular level, i.e., the potential effects of breast density on tumor initiation and growth. Previous studies have shown that tissue

from mammographically dense areas of the breast differ histologically from non-dense areas with greater proportions of both epithelial and stromal tissues in tissue from dense areas (20, 21). The stromal tissue may be of substantial importance since both epithelial benign and malignant cells interact with the surrounding stroma in cancer initiation, growth and progression (22, 23). The stroma contributes to the density (20) and the mammographic features of the tumor (24). Thus, the mammographic tumor features may reveal an epithelial-stromal interaction; further studies are needed to elucidate this phenomenon.

Furthermore, we aimed to assess whether certain mammographic tumor features relate to pathological tumor characteristics and breast density, providing prognostic information. We report that tumors presenting with spiculated appearance were more likely to be invasive than cancer *in situ*. In other studies of invasive cancers, spiculated tumors have been associated with longer breast cancer-free survival (7-9). Survival was, however, out of scope for this study. Additionally, among invasive cancers, tumors presenting as an ill-defined mass or tissue abnormality were more likely to be associated with larger tumor sizes than those presenting with a distinct mass. These findings are consistent with a previous study showing that tumors presenting as ill-defined masses and asymmetric densities tend to be larger (6), which is prognostically unfavorable as large tumor size is associated with an impaired breast cancer-specific survival (7). In this study, no statistically significant relationship between mammographic tumor

features and ALNI was detectable, consistent with similar findings reported by De Nunzio et al. (6).

Some methodological issues require consideration. This study was a retrospective study implying a risk of less stringent data compared to a prospective study, however, the vast majority of the breast cancer cases within the MDCS were diagnosed and treated at the same hospital reducing the risk of misclassifications and variations in data reporting. Further, there was a change from analogue to digital mammography at the institution in year 2004 and this study is consequently based on both analogue and digital mammography images which may be considered a back draw of this study.

Previous studies have assessed this potential problem and reported no effects on the results when using a qualitative density measure such as BI-RADS (25).

No formal assessment of intra- or interobserver variability was performed for the initial estimation of breast density and mammographic tumor features in this study, which is a limitation. However, the group of radiologists at the Department of Breast Radiology has been consistent during the study period, which is expected to have assured reliability over time. In a recent study at our institution, 1 200 screening mammograms were double-read by the same observers as in the present investigation using the BI-RADS classification of breast density with the modification described in methods-section of this paper (unpublished data). The agreement of breast density estimation between radiologists in our department yielded a quadratic-weighted kappa of 0.66

(95% CI 0.62-0.71). Studies using different populations and methods to investigate inter-observer reliability of BI-RADS have reported kappa values of 0.43–0.77 (26-30). This provides support of a substantial inter-observer agreement in our qualitative estimation of breast density. Previous studies have shown particularly low inter-observer reproducibility regarding the two intermediate groups of BI-RADS (26, 27, 29). By fusion of these two groups, we hope to diminish the risk for misclassification (27). The classification regarding mammographic tumor features were made using categories by Luck et al. (5). Classification of mammographic tumor features varies between studies, although they usually have the major groups such as spiculation or calcification in common. We believe the classification used in this study to be specific enough to distinguish between the major types of mammographic tumor features. In conclusion, the distribution of mammographic tumor features across breast density categories differed significantly and there was a significant relationship between spiculated appearance and invasiveness, as well as between ill-defined mass, tissue abnormality and tumor size, regardless of breast density, which to our knowledge has not been previously reported. Further studies assessing the clinical usefulness of mammographic tumor features are needed to verify whether such information can impact on clinical decision-making at an early stage.

Acknowledgements

The authors thank Anna Hwasser for excellent data-management, Elise Nilsson for committed assistance with tumor tissue handling, and Lola Anagnostaki for assistance with pathology assessments.

Declaration of Conflicting Interests

The Authors declare that there is no conflict of interest.

Funding Acknowledgement

This work has received governmental funding of clinical research within the National Health Services.

1.McCormack VA, dos Santos Silva I. Breast density and parenchymal patterns as markers of breast cancer risk: a meta-analysis. *Cancer Epidemiol Biomarkers Prev* 2006;15:1159-1169.

- 2.Olsen AH, Bihrmann K, Jensen MB, et al. Breast density and outcome of mammography screening: a cohort study. *Br J Cancer* 2009;100:1205-1208.
- 3.Ciatto S, Visioli C, Paci E, et al. Breast density as a determinant of interval cancer at mammographic screening. *Br J Cancer* 2004;90:393-396.
- 4.Mandelson MT, Oestreicher N, Porter PL, et al. Breast density as a predictor of mammographic detection: comparison of interval- and screen-detected cancers. *J Natl Cancer Inst* 2000;92:1081-1087.
- 5.Luck AA, Evans AJ, James JJ, et al. Breast carcinoma with basal phenotype: mammographic findings. *Am J Roentgenol* 2008;191:346-351.
- 6.De Nunzio MC, Evans AJ, Pinder SE, et al. Correlations between the mammographic features of screen detected invasive breast cancer and pathological prognostic factors. *Breast* 1997;6:146-149.
- 7.Evans AJ, Pinder SE, James JJ, et al. Is mammographic spiculation an independent, good prognostic factor in screening-detected invasive breast cancer? *Am J Roentgenol* 2006;187:1377-1380.
- 8.Tabar L, Tony Chen HH, Amy Yen MF, et al. Mammographic tumor features can predict long-term outcomes reliably in women with 1-14-mm invasive breast carcinoma. *Cancer* 2004;101:1745-1759.

9. Alexander MC, Yankaskas BC, Biesemier KW. Association of stellate mammographic pattern with survival in small invasive breast tumors. *Am J Roentgenol* 2006;187:29-37.
10. Thurfjell E, Thurfjell MG, Lindgren A. Mammographic finding as predictor of survival in 1-9 mm invasive breast cancers. worse prognosis for cases presenting as calcifications alone. *Breast Cancer Res Treat* 2001;67:177-180.
11. James JJ, Evans AJ, Pinder SE, et al. Is the presence of mammographic comedo calcification really a prognostic factor for small screen-detected invasive breast cancers? *Clin Radiol* 2003;58:54-62.
12. Manjer J, Elmstahl S, Janzon L, et al. Invitation to a population-based cohort study: differences between subjects recruited using various strategies. *Scand J Public Health* 2002;30:103-112.
13. Berglund G, Elmstahl S, Janzon L, et al. The Malmo Diet and Cancer Study. Design and feasibility. *J Intern Med* 1993;233:45-51.
14. Manjer J, Carlsson S, Elmstahl S, et al. The Malmo Diet and Cancer Study: representativity, cancer incidence and mortality in participants and non-participants. *Eur J Cancer Prev* 2001;10:489-499.
15. Borgquist S, Djerbi S, Ponten F, et al. HMG-CoA reductase expression in breast cancer is associated with a less aggressive phenotype and influenced by anthropometric factors. *Int J Cancer* 2008;123:1146-1153.

16.Lagerlund M, Sontrop, J, Zackrisson S. Do reproductive and hormonal risk factors for breast cancer associate with attendance at mammography screening? *Cancer Causes Control* 2013;24:1687-1694.

17. ACR. American College of Radiology.

<http://www.acr.org/Quality-Safety/Resources/BIRADS/Mammography> (accessed 12th February 2013).

18.Porter GJ, Evans AJ, Cornford EJ, et al. Influence of mammographic parenchymal pattern in screening-detected and interval invasive breast cancers on pathologic features, mammographic features, and patient survival. *Am J Roentgenol* 2007;188:676-683.

19.Andersson I, Ikeda DM, Zackrisson S, et al. Breast tomosynthesis and digital mammography: a comparison of breast cancer visibility and BIRADS classification in a population of cancers with subtle mammographic findings. *Europ Radiol* 2008;18:2817-2825.

20.Ghosh K, Brandt KR, Reynolds C, et al. Tissue composition of mammographically dense and non-dense breast tissue. *Breast Cancer Res Treat* 2012;131:267-275.

21.Li T, Sun L, Miller N, Nicklee T, et al. The association of measured breast tissue characteristics with mammographic density and other risk factors for breast cancer. *Cancer Epidemiol Biomarkers Prev* 2005;14:343-349.

22.Boyd NF, Martin LJ, Yaffe MJ, et al. Mammographic density and breast cancer risk: current understanding and future prospects. *Breast Cancer Res* 2011;13:223.

23. Pietras K, Ostman A. Hallmarks of cancer: interactions with the tumor stroma. *Exp Cell Res* 2010;316:1324-1331.
24. Franquet T, De Miguel C, Cozcolluela R, et al. Spiculated lesions of the breast: mammographic-pathologic correlation. *Radiographics* 1993;13:841-852.
25. Harvey JA, Gard CC, Miglioretti DL, et al. Reported mammographic density: film-screen versus digital acquisition. *Radiology* 2013;266:752-758.
26. Berg WA, Campassi C, Langenberg P, et al. Breast Imaging Reporting and Data System: inter- and intraobserver variability in feature analysis and final assessment. *Am J Roentgenol* 2000;174:1769-1777.
27. Ciatto S, Houssami N, Apruzzese A, et al. Categorizing breast mammographic density: intra- and interobserver reproducibility of BI-RADS density categories. *Breast* 2005;14:269-275.
28. Kerlikowske K, Grady D, Barclay J, et al. Variability and accuracy in mammographic interpretation using the American College of Radiology Breast Imaging Reporting and Data System. *J Natl Cancer Inst* 1998;90:1801-1809.
29. Nicholson BT, LoRusso AP, Smolkin M, et al. Accuracy of assigned BI-RADS breast density category definitions. *Acad Radiol* 2006;13:1143-1149.
30. Ooms EA, Zonderland HM, Eijkemans MJC, et al. Mammography: Interobserver variability in breast density assessment. *Breast* 2007;16:568-576.

Figure legends and Table headings

Fig. 1: Flowchart illustrating study population, exclusions, and subgroups

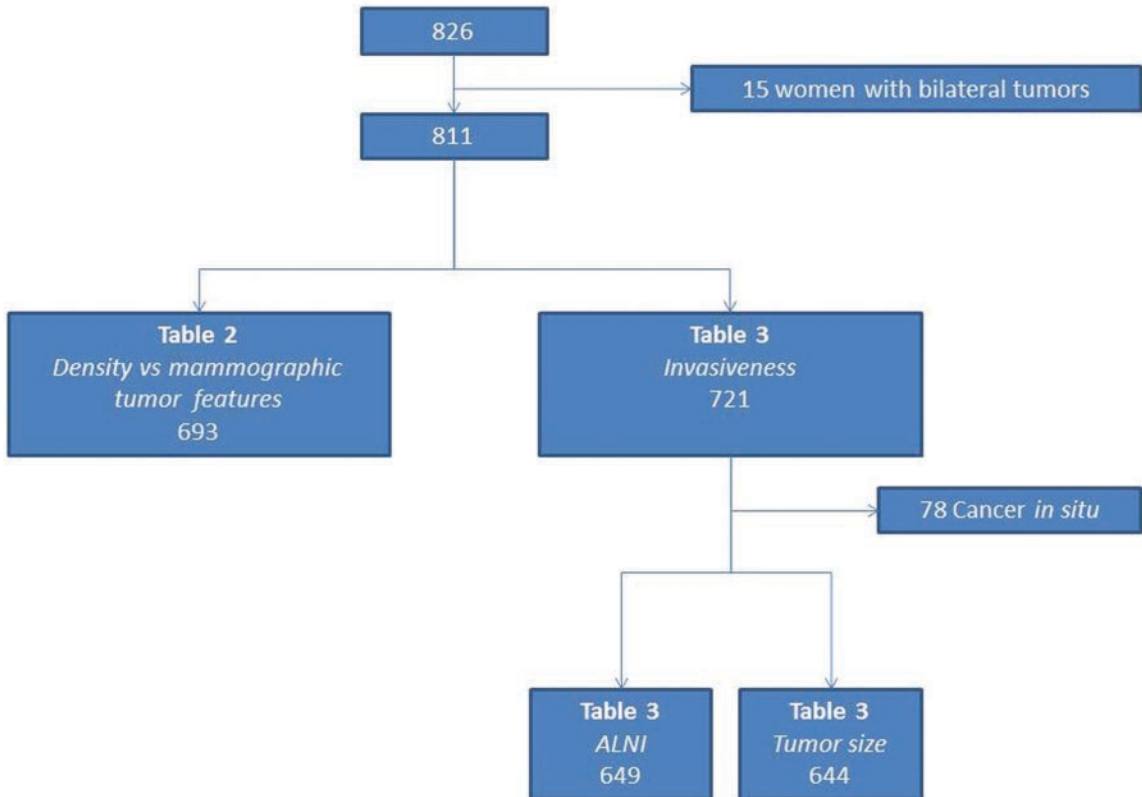
Fig. 2: Examples of some mammographic tumor features: (a) distinct mass, (b) calcifications, (c) ill-defined mass with slight retraction, (d) spiculated appearance, and

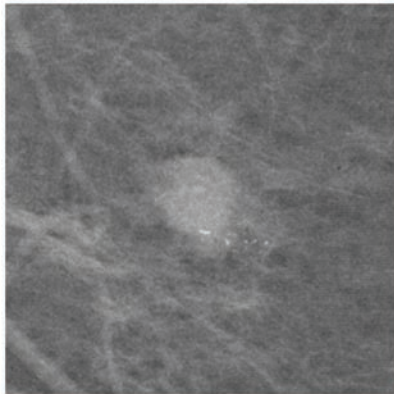
(e) architectural distortion (referred to in the study as the mammographic tumor feature tissue abnormality)

Table 1: Basic characteristics of the incident breast cancer cases in the Malmö Diet and Cancer Study according to the mode of detection

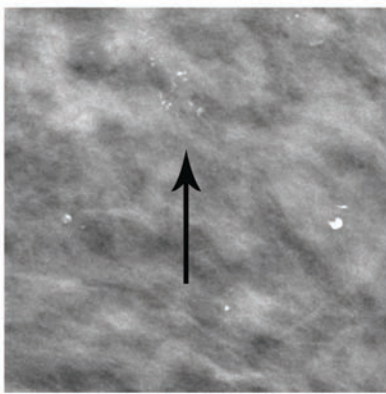
Table 2: Mammographic tumor features in relation to breast density

Table 3: Mammographic tumor features in relation to invasiveness, tumor size, and axillary lymph node involvement (ALNI)

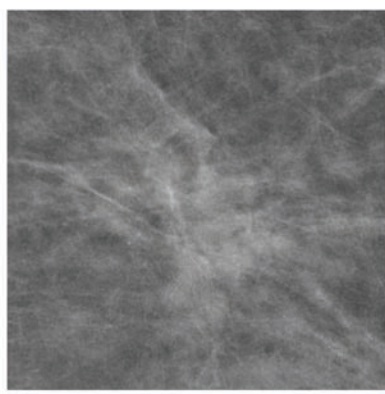




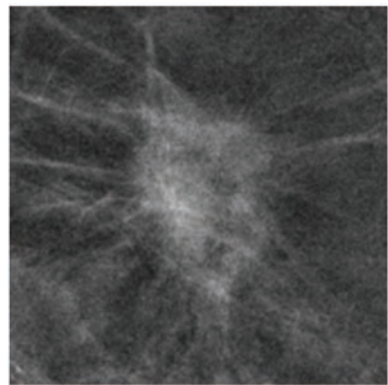
a



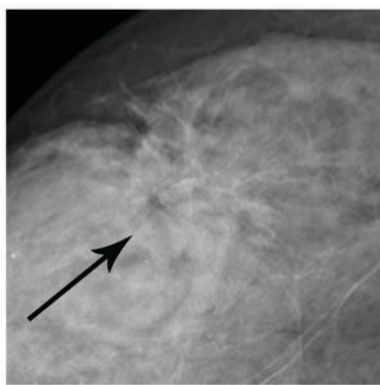
b



c



d



e

Table 1

		Mode of detection			
		Screening-detection	Clinical detection	Missing information	Total ^a
n(%)		443 (54.6)	361 (44.5)	7 (0.9)	811 (100.0)
Age at diagnosis (years)	Median	63.3	64.6	62.3	63.8
	(min/max)	(48.5 -81.3)	(45.7 – 84.7)	(47.8 – 80.5)	(45.7 – 84.7)
Age-class at diagnosis	45-49	6 (1.4)	15 (4.2)	2 (28.6)	23 (2.8)
	50-59	140 (31.6)	94 (26.0)	0 (0.0)	234 (28.9)
	60-69	214 (48.3)	125 (34.6)	3 (42.9)	342(42.2)
	70-	83 (18.7)	127 (35.2)	2 (28.6)	212 (26.1)
Breast density	Fat involuted	60 (13.5)	49 (13.6)	0 (0.0)	109 (13.4)
	Moderately dense	217 (49.0)	157 (43.5)	1 (14.3)	375 (46.2)
	Dense	144 (32.5)	119 (33.0)	0 (0.0)	263 (32.4)
	Missing	22 (5.0)	36 (10.0)	6 (85.7)	64 (7.9)
Dominant mammographic tumor features	Distinct mass	89 (20.1)	90 (24.9)	1 (14.3)	180 (22.2)
	Ill-defined mass	60 (13.5)	74 (20.5)	0 (0.0)	134 (16.5)
	Spiculated	175 (39.5)	98 (27.1)	0 (0.0)	273 (33.7)
	Calcifications	84 (19.0)	24 (6.6)	0 (0.0)	108 (13.3)
	Tissue abnormality	13 (2.9)	13 (3.6)	0 (0.0)	26 (3.2)
	Missing	22 (5.0)	62 (17.2)	6 (85.7)	90 (11.1)
Tumor size (pT)	Small (\leq 20mm)	364 (82.2)	200 (55.4)	4 (57.1)	568 (70.0)
	Large ($>$ 20mm)	71 (16.0)	142 (39.3)	1 (14.3)	214 (26.4)
	Missing	8 (1.8)	19 (5.2)	2 (28.6)	29 (3.6)
In situ/Invasive	Cancer <i>in situ</i>	54 (12.2)	24 (6.6)	0 (0.0)	78 (9.6)
	Invasive	389 (87.8)	337 (93.4)	7 (100.0)	733 (90.4)
Tumor type (invasive cancers)	Ductal	271 (69.7)	218 (64.7)	2 (28.6)	491 (67.0)
	Lobular	73 (18.8)	63 (18.7)	1 (14.3)	137 (18.7)
	Tubular	23 (5.9)	15 (4.5)	0 (0.0)	38 (5.2)
	All other	9 (2.3)	14 (4.2)	0 (0.0)	23 (3.1)
	Missing	13 (3.3)	27 (8.0)	4 (57.1)	44 (6.0)
Histological grade (invasive cancers)	Grade 1	123 (31.6)	63 (18.7)	0 (0.0)	186 (25.4)
	Grade 2	185 (47.6)	138 (40.9)	2 (28.6)	325 (44.3)
	Grade 3	64 (16.5)	104 (30.9)	1 (14.3)	169 (23.1)
	Missing	17 (4.4)	32 (9.5)	4 (57.1)	53 (7.3)
	Total	389 (100.0)	337 (100.0)	7 (100.0)	733 (100.0)
Axillary lymph node involvement (ALNI)	Negative (0)	354 (79.9)	221 (61.2)	3 (42.9)	578 (71.3)
	Postive (\geq 1)	88 (19.9)	135 (37.4)	2 (28.6)	225 (27.7)
	Missing	1 (0.2)	5 (1.4)	2 (28.6)	8 (1.0)
	Total	443 (100.0)	361 (100.0)	7 (100.0)	811 (100.0)

^a15 women with bilateral tumors were excluded

Table 2

Dominant mammographic tumor features	Breast density				p-value ^a	Corrected p-value ^b
	n(%)	Fat involuted	Moderately dense	Dense		
Distinct mass (DiM)	35 (32.7)	97 (26.8)	42 (18.8)	174 (25.1)		
DiM vs SA					0.56	1.00
DiM vs <i>IM</i> ^c					0.002	0.02
DiM vs <i>Ca</i>					<0.001	<0.001
DiM vs <i>TA</i>					0.001	0.01
Ill-defined mass (IM)	14 (13.1)	62 (17.1)	50 (22.3)	126 (18.2)		
<i>IM</i> vs SA					0.004	0.04
IM vs Ca					0.19	1.00
IM vs TA					0.13	1.00
Spiculated appearance (SA)	49 (45.8)	148 (40.9)	70 (31.2)	267 (38.5)		
SA vs <i>Ca</i>					<0.001	<0.001
SA vs <i>TA</i>					0.002	0.02
Calcifications (Ca)	7 (6.5)	47 (13.0)	48 (21.4)	102 (14.7)		
Ca vs TA					0.47	1.00
Tissue abnormality (TA)	2 (1.9)	8 (2.2)	14 (6.2)	24 (3.5)		
Total	107 (100)	362 (100)	224 (100)	693 (100)	<0.001 ^d	

^aDunn's method ^bCorrected with Bonferroni, ^cItalics indicates trend towards dense breasts, ^doverall p-value Kruskal-Wallis

Table 3

<i>All tumors</i>				
Dominant mammographic tumor features	Invasiveness			
n (%)	Cancer <i>in situ</i>	Invasive	Crude OR (CI)	Adj OR (CI) ^a
Distinct mass	13 (19.4)	167 (25.5)	1.00 ref.	1.00 ref.
Ill-defined mass	4 (6.0)	130 (19.9)	2.53 (0.81-7.94)	2.37 (0.75-7.53)
Spiculated appearance	4 (6.0)	269 (41.1)	5.24 (1.68-16.32)	5.68 (1.81-17.84)
Calcifications	42 (62.7)	66 (10.1)	0.12 (0.06-0.24)	0.13 (0.06-0.27)
Tissue abnormality	4 (6.0)	22 (3.4)	0.43 (0.13-1.43)	0.37 (0.11-1.27)
Total	67 (100)	654 (100)	p<0.001 ^b	p<0.001 ^b
<i>Invasive tumors</i>				
Dominant mammographic tumor features	Tumor size			
	Small (≤20 mm)	Large (>20 mm)	Crude OR (CI)	Adj OR (CI) ^a
Distinct mass	129 (27.4)	33 (19.0)	1.00 ref.	1.00 ref.
Ill-defined mass	71 (15.1)	56 (32.2)	3.08 (1.84-5.18)	3.16 (1.80-5.55)
Spiculated appearance	204 (43.4)	64 (36.8)	1.23 (0.76-1.97)	1.57 (0.94-2.60)
Calcifications	55 (11.7)	11 (6.3)	0.78 (0.37-1.66)	1.05 (0.46-2.40)
Tissue abnormality	11 (2.3)	10 (5.7)	3.55 (1.39-9.08)	4.05 (1.41-11.64)
Total	470 (100)	174 (100)	p<0.001 ^b	p<0.001 ^b
<i>Invasive tumors</i>				
Dominant mammographic tumor features	Axillary lymph node involvement (ALNI)			
	Negative	Positive	Crude OR (CI)	Adj OR (CI) ^a
Distinct mass	122 (26.8)	43 (22.3)	1.00 ref.	1.00 ref.
Ill-defined mass	83 (18.2)	45 (23.3)	1.54 (0.93-2.54)	1.36 (0.80-2.33)
Spiculated appearance	184 (40.4)	85 (44.0)	1.31 (0.85-2.02)	1.49 (0.95-2.36)
Calcifications	53 (11.6)	13 (6.7)	0.70 (0.35-1.40)	0.80 (0.38-1.71)
Tissue abnormality	14 (3.1)	7 (3.6)	1.42 (0.54-3.75)	1.24 (0.43-3.62)
Total	456 (100)	193 (100)	p=0.164 ^b	p=0.277 ^b

^aAdjusted for age at diagnosis, mode of detection and breast density, ^boverall p-value at 4df