

Diagnostic Ureteroscopy for Cases Clinically Suspected of Carcinoma *in Situ* of the Upper Urinary Tract

Katsumi Sasaki*, Koichiro Wada, Motoo Araki, Yasuyuki Kobayashi, Morito Sugimoto, Shin Ebara, Toyohiko Watanabe, and Yasutomo Nasu

Department of Urology, Okayama University Graduate School of Medicine,
Dentistry and Pharmaceutical Sciences, Okayama 700-8558, Japan

We elucidate the fate of cases clinically suspected of carcinoma *in situ* (Cis) of the upper tract with serial ureteroscopy. Of 143 patients who underwent ureteroscopy for suspected upper tract urothelial carcinoma (UTUC) between January 2008 and February 2016, 12 cases with consistently positive urine cytology and poorly detectable upper-tract malignancies by imaging were reviewed. In these 12 patients, 19 ureteroscopy procedures (25 renal units) were performed. Vesical random biopsy was performed before the 1st ureteroscopy to exclude malignancy of the bladder in all 12 cases. Median follow-up was 42 (13-67) months. Positive biopsy results at the 1st ureteroscopy were obtained in 3 (25%) patients and all were diagnosed with Cis of the upper tract. Two (17%) of 9 patients who were negative or inconclusive at the 1st ureteroscopy were finally diagnosed as UTUC, but plural ureteroscopy procedures were needed for the diagnoses in both. Carcinoma of the bladder appeared in 5 (42%) patients during follow-up, despite the earlier ruling out of vesical malignancy. Four (33%) of those 5 patients never developed upper-tract urothelial carcinoma during follow-up. Caution is required before undertaking radical surgery for cases clinically suspected of Cis of the upper tract. In our experience, only 42% of such patients developed UTUC; another 33% eventually developed carcinoma of the bladder without UTUC.

Key words: carcinoma *in situ*, carcinoma of the bladder, upper tract urothelial carcinoma, ureteroscopy, urine cytology

Urothelial carcinoma of the upper urinary tract (UTUC) is uncommon, accounting for less than 5% of all urothelial carcinomas (UCs) [1-2]. Standard diagnostic methods for UTUC include upper-tract imaging (CT urography [CTU] is the first-line) and urine cytology [3]. The detection rate of UTUC is satisfactory with high specificity for CT urography in parallel with the development of CT devices [4]. Current indications for nephro-ureterectomy with ipsilateral bladder cuff excision include cases of suspected UTUC based on imaging and positive urine cytology. However,

there are minor cases with consistently positive urine cytology that show poorly detectable lesions in the upper urinary tract, *i.e.*, filling defects and/or wall thickness, on imaging studies. Such cases in whom lower urinary tract malignancy has been excluded are suspected of flat UTUC or carcinoma *in situ* of the upper tract (UT-Cis). However, there is poor evidence of efficient diagnostic options for such cases.

Ureteroscopy (URS) for the upper urinary tract was previously a relatively invasive work-up with common adverse effects. Recently, small-diameter, flexible, high-resolution ureteroscopes have enabled safe access

to the upper tract and enable tissue to be obtained easily at biopsy; hence, current URS is a valuable tool for diagnosis of upper-urinary-tract disorders.

We have performed URS for upper-urinary-tract disorders for more than 2 decades, and have reported the usefulness of URS for diagnosing and treating idiopathic renal bleeding [5], and for detecting small, low-grade upper tract tumors and prescribing nephron-sparing treatment options [6]. In this study, we assess the usefulness of diagnostic URS for cases with consistently positive cytology and upper-urinary-tract lesions that are poorly detectable on imaging. We also report the final diagnoses of these cases during follow-up.

Materials and Methods

After approval from the Okayama University Hospital Institutional review board and an ethics committee review board (No. 1604-505-001), 143 clinical records of patients undergoing URS evaluation for suspected UTUC at our institution between January 2008 and February 2016 were reviewed. Of 143 patients, 12 cases were highlighted as having consistently positive urine cytology (class IV or V on cytological evaluation) and poorly detectable malignant lesions in the upper urinary tract on imaging. The standard imaging method was enhanced CT urography; in patients for

whom iodinated contrast media were contraindicated, MR urography was used instead. Cystoscopy and vesical mucosa random biopsy (including prostatic urethra in men) were performed in all 12 cases before the 1st URS to exclude malignancy of the bladder.

URS procedures at our institution are as follows. Under general anesthesia, ureteral orifice and lower ureter are first observed using a rigid ureteroscope (Fibre Uretero-Renoscope, Richard-Wolf, Knittlingen, Germany). The middle and upper ureter and pelvis are observed next using a flexible ureteroscope (URF-P5, URF-P6, Olympus, Tokyo, Japan). If clinicians detect lesions suspected of malignancy—*i.e.* irregular, edematous, reddish mucosa—a biopsy is performed with 3-Fr biopsy cup forceps (Cook Japan, Tokyo, Japan). Three tissue samples are usually obtained at biopsy.

We evaluated whether diagnostic URS could detect UTUC that imaging studies could not detect decisively. We also evaluated the final diagnoses of the 12 patients examined.

Results

Median follow-up was 42 (13-67) months. Patient backgrounds of the 12 cases are summarized in Table 1. Six of the 12 patients had a previous history of bladder cancer (Cis; 3 patients, Non-Cis; 3 patients). The 1st URS was performed after excluding present malignancy

Table 1 Patient characteristics, urine cytology, imaging findings and final diagnosis

Pt. No.	Sex	Age	Urine cytology before URS	Imaging before URS	Previous history of Bladder cancer	Final diagnosis
1	Male	73	V	CT	none	UTUC (non-Cis)
2	Male	70	V	CT	none	Cis of the bladder
3	Female	77	V	CT	non-Cis	UC of the bladder (non-Cis)
4	Female	63	V	CT	Cis	no malignancy (followed up)
5	Male	69	V	CT	non-Cis	Cis of the bladder
6	Male	69	V	CT	Cis	UT-Cis
7	Female	61	IV	CT, MRI	none	Cis of the bladder → UTUC (non-Cis)
8	Female	75	V	CT	Cis	UT-Cis
9	Male	43	IV	CT	none	no malignancy (followed up)
10	Female	62	V	CT	none	no malignancy (followed up)
11	Female	53	V	CT	non-Cis	Cis of the bladder
12	Male	66	V	CT, MRI	non	UT-Cis

of the bladder in each of the 12 patients. Three cases of UT-Cis were diagnosed histologically at the 1st URS. Two of these 3 UT-Cis cases diagnosed at the 1st URS had a previous history of Cis of the bladder. Two of the 9 patients who were not diagnosed with UTUC histologically at the 1st URS were considered to be clinical UT-Cis, and received intrarenal Bacillus Calmette-Guerin (BCG) therapy. In one patient the positive urine cytology disappeared, and this patient was followed up. Another patient showed a consistently positive cytology and a 2nd URS was considered. Another 7 of the 9 patients who were not diagnosed with UTUC histologically at the 1st URS were followed up; in 2 of these 7 patients, positive urine cytology disappeared but follow-up was continued. Another 3 of the 7 patients showed a new appearance of Cis of the bladder. Another 2 of the 7 patients continued positive cytology and a 2nd URS was considered. Ultimately 3 patients received a 2nd URS and all failed to diagnose UTUC histologically. One of the 3 patients who received a 2nd URS were considered to have clinical UT-Cis, and received intrarenal BCG therapy, but was finally diagnosed with UTUC (non-Cis) in imaging during follow-up. Another patient, who showed a new appearance of Cis of the bladder during follow-up, received intravesical BCG therapy with Cis disappearing histologically after treatment, but was finally considered for a 3rd URS because of recurrent positive cytology during follow-up. Another patient continued to show positive cytology and a 3rd URS was considered. Ultimately, 2 patients received a 3rd URS. One of these 2 patients who received a 3rd URS was histologically diagnosed with UTUC (non-cis). Another patient who was not diagnosed with UTUC histologically at the 3rd URS was ultimately diagnosed with bladder cancer (non-Cis) during follow-up. A summary of clinical progress and results are shown in Fig. 1.

In summary, a total of 19 URS procedures (25 renal units) were performed in 12 patients with consistently positive cytology and no or poorly detectable upper-urinary-tract lesions on imaging. In these 19 URS procedures, 17 biopsies (17 renal units) were performed. Of these 12 cases, UT-Cis was histologically diagnosed in 3 patients at 1st URS. Non-cis of the upper tract was ultimately diagnosed in 2 patients, but plural URS procedures were needed for the diagnosis in both. Five patients developed carcinoma of the bladder during follow-up, despite vesical malignancy having been

ruled out by mucosa biopsy. In 2 patients positive urine cytology disappeared after the 1st URS, and follow-up was continued without any symptoms or suspicions signs on imaging.

Discussion

The European Association of Urology (EAU) guideline on UTUC includes cytological evaluation of urine, cystoscopy to exclude malignancy of the bladder, and imaging as the standard diagnostic work-up [3]. CTU is the standard imaging method, and has replaced intravenous excretory urography. The detection rate of UTUC is satisfactory for CTU, with both high sensitivity and specificity. In addition, the wall thickness of the upper tract on CTU is considered to be a sign of UTUC, even when there is no luminal mass effect. However, sensitivity drops for small or flat lesions even with the latest CTU [7]. Patients who cannot undergo CTU due to contraindication of iodinated contrast media typically undergo MR urography, the detection rate of which is less than that of CTU [8]. The usefulness of diffusion-weighted MR for improving cancer detection has been reported [9]. The diffusion coefficient values of highly malignant tumors have been reported to be lower than those of less malignant tumors. However, diffusion-weighted MR cannot detect UT-Cis, which is a highly malignant tumor. Asai *et al.* reported an outstanding positive predictive value (PPV) of 95% in diagnoses of UTUC using fluorodeoxyglucose positron emission tomography/computed tomography (PET-CT), a new imaging option [10], but with the limitation that this sensitivity is lower in diabetic patients. PET-CT also cannot detect UT-Cis.

Application of diagnostic URS for evaluating suspected UTUC is controversial, with low-grade evidence supporting either view [3, 11]. Some updated reports value URS not only as a diagnostic tool but also as an endoscopic management tool for UTUC, with recent small-diameter, flexible, high-resolution ureteroscopes resulting in satisfactory safety and ease of work-up [12, 13]. One report found that the technical success rate of URS in UTUC patients was 95%, and that biopsies using such ureteroscopes could obtain a satisfactory accurate diagnostic tumor grade regardless of sample size [14]. Tsivian *et al.* reported that routine use of diagnostic URS in the evaluation of suspected UTUC reduced misdiagnoses (non-UC with final pathologic

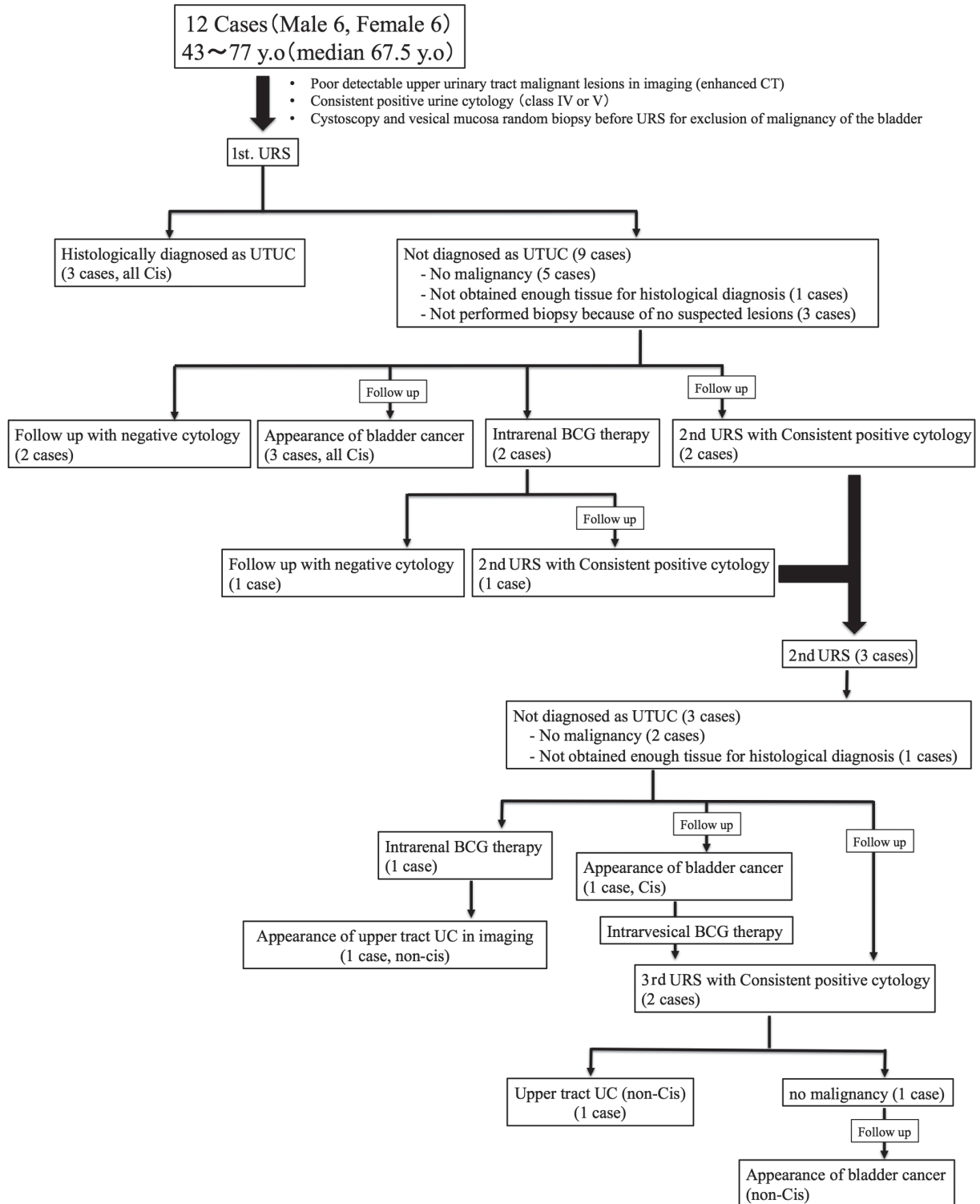


Fig. 1 Summary of clinical progress and results of 12 patients.

findings) [15]. They also emphasized that URS evaluation appeared to increase other nephron-sparing treatment options. However, these reports do not mention the type of UTUC, nor the definition of suspected UTUC (suspected with imaging study or urine cytology).

We have adopted routine URS in the evaluation of suspected UTUC, and have reported the possibility of cancer control for nephron-sparing treatment options under URS [16]. In the present report, we focus on cases with consistently positive cytology and upper-urinary-tract lesions poorly detectable by imaging such as CTU, and evaluated the usefulness of diagnostic URS for such cases. Cis of the upper tract was diagnosed histologically in only 3 of the 12 patients, but all 3 cases were diagnosed at the 1st URS. Two of these 3 UT-Cis cases had a previous history of Cis of the bladder. These results indicate that URS is useful and should be strongly considered for detecting UT-Cis in patients with a previous history of Cis of the bladder.

Another finding from our present data is that carcinoma of the bladder ultimately appeared in more than 40% of the patients during follow-up, regardless of vesical malignancy having been ruled out before URS. These cases must have had a very small area of carcinoma that could not be detected with a random vesical mucosa biopsy but produced the consistently positive cytology and were finally diagnosed as bladder cancer. The number of patients with carcinoma of the bladder was greater than that of patients with UT-Cis. Benign pathologic results were detected when these patients underwent radical nephro-ureterectomy. Indeed, Hong *et al.* report the incidence of benign results after laparoscopic radical nephro-ureterectomy with preoperative suspicion of UTUC, and indicate the need for careful and thorough preoperative counseling [16]. Our small sample of data may suggest that radical nephro-ureterectomy requires caution, and that frequent follow-up with urine cytology and imaging studies, and/or possible URS, should be considered for cases clinically suspected of UT-Cis due to consistently positive cytology and upper-urinary-tract lesions poorly detectable by imaging.

One concern from our data is that in 2 of 12 patients in whom URS did not detect UC lesions, positive urine cytology disappeared after URS. Reports that the PPV of urine cytology for UTUC is generally very high [17], and that identification of UT-Cis lesions under URS is

not satisfactory [12] suggest that these 2 patients would need strict follow-up.

The findings of this study have some limitations. First, the retrospective nature of the study must be taken into account. Second, the 12 patients evaluated in the study include those with a past history of bladder cancer, although the random biopsy of vesical mucosa ruled out malignancy of the bladder prior to URS. In addition, we did not evaluate upper tract selective cytology (UTC) because catheterization for collecting urine samples from the upper tract could produce misleading results. Namely, catheterization can affect the cellularity and nuclear morphology of a urine sample [18]. The procedure may also affect the morphology of the upper tract mucosa, making the mucosa mimic Cis. Finally, the small sample size prevents us from reaching statistical conclusions. Our results need to be confirmed with well-designed observational studies.

URS was performed only under white light (WL) in this study. Recent developments in optical diagnostics have been reported to improve the diagnostic accuracy of UTUC [19]. Traxer *et al.* report that the URS tumor detection rate was improved by 22.7% using narrow-band imaging (NBI) technology, and that in 27 patients, 5 additional tumors that were considered normal under WL could be detected under NBI, suggesting the usefulness of the technology for detecting UTUC by URS [20]. We should also consider routine URS using these new optical diagnostics technologies, although evidence of daily clinical use is still insufficient.

The present study concluded that radical surgery should be approached with caution, and frequent follow-up with urine cytology and imaging studies, and/or possible URS, should be considered in cases in whom UT-Cis is suspected due to consistently positive cytology and upper-urinary-tract lesions that are poorly detectable by imaging. Biopsy under URS should be strongly considered for cases with a previous history of Cis of the bladder.

References

1. Munoz JJ and Ellison LM: Upper tract urothelial neoplasms: incidence and survival during the last 2 decades. *J Urol* (2000) 164: 1523–1525.
2. Siegel RL, Miller KD and Jemal A: Cancer statistics, 2015. *CA Cancer J Clin* (2015) 65: 5–29.
3. Rouprêt M, Babjuk M, Compérat E, Zigeuner R, Sylvester R, Burger M, Cowan N, Böhle A, Van Rhijn BW, Kaasinen E, Palou

- J and Shariat SF: European guidelines on upper tract urothelial carcinomas: 2013 update. *Eur Urol* (2013) 63: 1059–1071.
4. Chlapoutakis K, Theocharopoulos N, Yarmenitis S and Damilakis J: Performance of computed tomographic urography in diagnosis of upper urinary tract urothelial carcinoma, in patients presenting with hematuria: Systematic review and meta-analysis. *Eur J Radiol* (2010) 73: 334–338.
 5. Araki M, Uehara S, Sasaki K, Monden K, Tsugawa M, Watanabe T, Monga M, Nasu Y and Kumon H: Ureteroscopic management of chronic unilateral hematuria: a single-center experience over 22 years. *PLoS One* (2012) 7: e36729.
 6. Kawauchi K, Uehara S, Wada K, Kobayashi Y, Sasaki K, Araki M, Watanabe T, Saika T, Nasu Y, Kumon H, Monden K, Ono N and Tsugawa M: Endoscopic treatment for upper urinary tract urothelial carcinoma; Indication and outcome. *The Nishinohon journal of urology* (2012) 74: 599–604.
 7. Xu AD, Ng CS, Kamat A, Grossman HB, Dinney C and Sandler CM: Significance of upper urinary tract urothelial thickening and filling defect seen on MDCT urography in patients with a history of urothelial neoplasms. *AJR Am J Roentgenol* (2010) 195: 959–965.
 8. Takahashi N, Glockner JF, Hartman RP, King BF, Leibovich BC, Stanley DW, Fitz-Gibbon PD and Kawashima A: Gadolinium enhanced magnetic resonance urography for upper urinary tract malignancy. *J Urol* (2010) 183: 1330–1365.
 9. Yoshida S, Masuda H, Ishii C, Tanaka H, Fujii Y, Kawakami S and Kihara K: Usefulness of diffusion-weighted MRI in diagnosis of upper urinary tract cancer. *AJR Am J Roentgenol* (2011) 196: 110–116.
 10. Asai S, Fukumoto T, Tanji N, Miura N, Miyagawa M, Nishimura K, Yanagihara Y, Shirato A, Miyauchi Y, Kikugawa T and Yokoyama M: Fluorodeoxyglucose positron emission tomography/computed tomography for diagnosis of upper urinary tract urothelial carcinoma. *Int J Clin Oncol* (2015) 20: 1042–1047.
 11. Sagalowsky AI, Jarrett TW and Flanigan RC: Ureteroscopic evaluation and biopsy; in *Urothelial Tumors of the Upper Urinary Tract and Ureter*: Campbell-Walsh Urology, McDougal WS, Wein AJ, Kavoussi LR, Novick AC, Partin AW, Peters CA and Ramchadani P eds, 10th Ed, Elsevier, Philadelphia (2012) pp1523–1524.
 12. Yamany T, van Batavia J, Ahn J, Shapiro E and Gupta M: Ureterorenoscopy for upper tract urothelial carcinoma: how often are we missing lesions? *Urology* (2015) 85: 311–315.
 13. Cutress ML, Stewart GD, Wells-Cole S, Phipps S, Thomas BG and Tolley DA: Long-term endoscopic management of upper tract urothelial carcinoma: 20-year single-centre experience. *BJU Int* (2012) 110: 1608–1617.
 14. Rojas CP, Castle SM, Llanos CA, Santos Cortes JA, Bird V, Rodriguez S, Reis IM, Zhao W, Gomez-Fernandez C, Leveillee RJ and Jorda M: Low biopsy volume in ureteroscopy does not affect tumor biopsy grading in upper tract urothelial carcinoma. *Urol Oncol* (2013) 31: 1696–1700.
 15. Tsivian A, Tsivian M, Stanevsky Y, Tavdy E and Sidi AA: Routine diagnostic ureteroscopy for suspected upper tract transitional-cell carcinoma. *J Endourol* (2014) 28: 922–925.
 16. Hong S, Kwon T, You D, Jeong IG, Hong B, Hong JH, Ahn H and Kim CS: Incidence of benign results after laparoscopic radical nephroureterectomy. *JLS* (2014) 18: pii: e2014.00335.
 17. Sverrisson EF, Kim T, Espiritu PN, Sexton WJ, Pow-Sang JM, Dhillon J and Spiess PE: The merits of cytology in the workup for upper tract urothelial carcinoma - a contemporary review of a perplexing issue. *Int Braz J Urol* (2014) 40: 493–498.
 18. Kapur U, Venkataraman G and Wojcik EM: Diagnostic significance of “atypia” in instrumented versus voided urine specimens. *Cancer* (2008) 114: 270–274.
 19. Bus MT, de Bruin DM, Faber DJ, Kamphuis GM, Zondervan PJ, Laguna Pes MP, de Reijke TM, Traxer O, van Leeuwen TG and de la Rosette JJ: Optical diagnostics for upper urinary tract urothelial cancer: technology, thresholds, and clinical applications. *J Endourol* (2015) 29: 113–123.
 20. Traxer O, Geavlete B, de Medina SGD, Sibony M and Al-Qahtani SM: Narrow-band imaging digital flexible ureteroscopy in detection of upper urinary tract transitional-cell carcinoma: initial experience. *J Endourol* (2011) 25: 19–23.