

## ***In Vivo* Analysis of Three-Dimensional Dynamic Scapular Dyskinesia in Scapular or Clavicular Fractures**

Eugene Kim<sup>a</sup>, Jai Hyung Park<sup>a</sup>, Byeong-Ryong Han<sup>a</sup>, Hee Jin Park<sup>b</sup>,  
So Yeon Lee<sup>b</sup>, Tsuyoshi Murase<sup>c</sup>, Kazuomi Sugamoto<sup>c</sup>, Sumika Ikemoto<sup>c</sup>, and Se-Jin Park<sup>a\*</sup>

<sup>a</sup>Department of Orthopaedic Surgery, Kangbuk Samsung Hospital, Sungkyunkwan University School of Medicine, Seoul 03181, Republic of Korea, <sup>b</sup>Department of Radiology, Kangbuk Samsung Hospital, Sungkyunkwan University School of Medicine, Seoul 03181, Republic of Korea, <sup>c</sup>Department of Orthopaedic Surgery, Osaka University Graduate School of Medicine, Suita, Osaka 565-0871, Japan

The three-dimensional (3D) kinematics of the scapula were analyzed *in vivo* in 10 patients with scapular and 10 patients with clavicular fracture. Both the injured shoulder and normal contralateral shoulder were evaluated by computed tomography in the neutral and fully elevated positions. 3D rotational and translational movements of the scapula relative to the thorax during arm elevation were analyzed. A computer simulation program was used to compare rotational elevation/depression in the coronal plane, anterior/posterior tilting in the sagittal plane and protraction/retraction in the axial plane between the normal and affected sides. Anterior/posterior translational movement along the X-axis, upward/downward movement along the Y-axis, and lateral/medial movement along the Z-axis in the Euler space during forward elevation were also compared. In scapular fracture, rotational elevation of the scapula decreased in the coronal plane and posterior tilting of the scapula increased in the sagittal plane. Anterior and superior translation were higher in scapular fracture than in the corresponding normal sides. However, no significant abnormal rotational and translational kinematic changes were observed during elevation in clavicular fracture. *In vivo* 3D computerized motion analysis was useful for evaluating scapular dyskinesia. Scapular fracture can cause scapular dyskinesia, but not all clavicular fractures alter scapular motion biomechanics.

**Key words:** 3-dimensional motion analysis, scapular dyskinesia, fracture, scapula, clavicle

Scapular dyskinesia (the prefix *dys* meaning “alteration of” plus *kinesis* meaning “movement”) is a collective term that refers to dysfunctional movement of the scapula [1]. These alterations are believed to affect normal scapula-humeral rhythm and thoraco-scapular movement, and have frequently been associated with shoulder injury and dysfunction [2-4]. Shoulder dyskinesia can be caused by alterations in bony stabilizers, alterations in muscle activation patterns, or damage to the dynamic muscle stabilizers [1].

Several studies have characterized scapular dyskinesia based on the findings of variable methods. For example, the relationship between scapular motion and humeral elevation has been assessed using a visual evaluation [5-8], the fringe projection technique [9], the double calibration method [10], an infrared camera [11], an electromagnetic three-dimensional (3D) tracking system [7, 12], and 3D wing computed tomography (CT) [13].

Several studies have identified factors causing scapular dyskinesia, including muscle weakness/imbalance,

nerve injury, acromioclavicular injury, superior labral tears, and rotator cuff injuries [5,14-16]. Clavicular nonunion might also cause shoulder dyskinesia and subsequent clinical symptoms, as suggested by a recent cadaveric study [17]. However, the relationship between scapular fracture and scapular dyskinesia has not been established. To address this knowledge gap, we investigated the relationship between scapular dyskinesia and fractures of the scapular or clavicle by means of 3D *in vivo* kinematic analysis.

The purposes of this study were thus (1) to assess and quantify dynamic scapular dyskinesia using a 3D motion analysis technique with a computerized simulation system; and (2) to determine whether scapular or clavicular fracture can cause scapular dyskinesia.

## Materials and Methods

This study was approved by the review board at Kangbuk Samsung Hospital IRB center. We obtained CT images from patients who had been treated for scapular or clavicular fracture at our institution between January 2012 and July 2014. Among them, 40 shoulders of 20 patients who were treated conservatively were enrolled in this study. CT images were obtained from 10 patients with scapular fractures and 10 patients with clavicular fractures who were able to elevate their arms forward to the same degree as the normal contralateral arm without pain. All the cases of scapular fracture involved the scapular body with angulation and translation deformity, and all were united with some deformity. The mean angulation angle and translation rate were 10.7 degrees (range, 5-36 degrees) and 11.9 percent (range, 0-30%). Several cases included nondisplaced glenoid or acromial fracture. All the cases of clavicular fracture were nonunion with pseudo-motion but no pain. The mean ages at evaluation were 48.2 years (range, 36-84 years) for patients with a scapular fracture, and 54.7 years (range, 26-72 years) for those with a clavicular nonunion. The mean times from the first trauma to assessment were 11.2 months (range, 6-12 months) for patients with a scapular fractures and 8.5 months (range, 6-18 months) for those with a clavicular nonunion. Patients who had fractured the contralateral upper extremities, such as the shoulder or elbow, were excluded from this study; those with a history of shoulder surgery and those with a brachial plexus injury were also excluded.

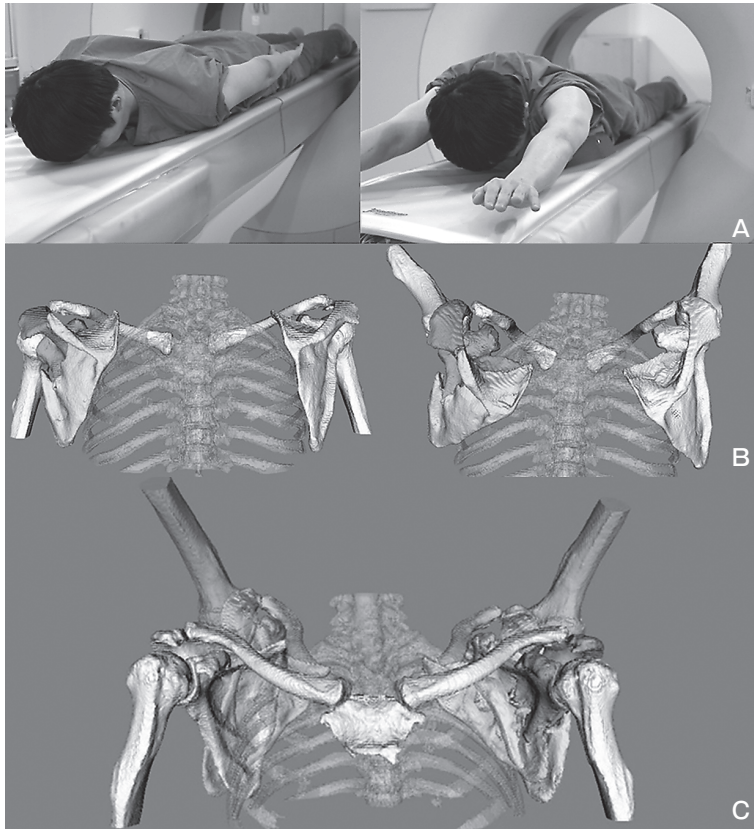
All patients underwent a CT scan of the injured and contralateral shoulders including the thorax. The CT scans were performed with the patient lifting both arms until they were able to do so without pain. To evaluate the scapular motion precisely, a CT scan was performed with the patient in the prone position with soft padding on the chest; this allowed the scapula to move freely without contacting the CT table.

Two CT DICOM images (LightSpeed pro64; Siemens, Erlangen, Germany) were obtained, including both shoulders and the thorax, in the neutral and full active forward elevated positions (Fig.1A). The scanning parameters were: scan time, 60 sec; scan pitch, 2 mm; tube voltage, 120 kv; tube current, 80-100 mA; and slice thickness, 0.5 mm. The CT images were processed into 3D surface models using a 3D simulation program (Bone Viewer<sup>TM</sup>, Bone Simulator<sup>TM</sup>; Orthree Co., Ltd., Osaka, Japan) (Fig.1B). Two bone models were superimposed on the thorax and analyzed using a markerless surface registration technique (Fig.1C) [18-20].

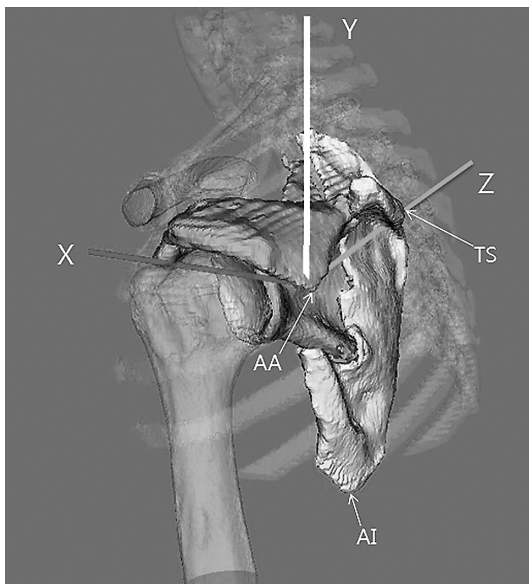
The motion of each bone was analyzed using a voxel-based registration technique. We calculated the rotation and translation of the scapula as 3D vectors using an anatomical orthogonal reference system modified from the scapular coordinate system of the International Society of Biomechanics [21]. When using this technique, we superimposed the 2 bone positions to minimize the sum of the squared intensity differences in the segmented voxels.

We defined the Z-axis as the line connecting the trigonum spinae scapulae (TS; the midpoint of the triangular surface on the medial border of the scapula in line with the scapular spine) and the angulus acromialis (AA; the most laterodorsal point of the scapula). We defined the X-axis as a line perpendicular to the plane formed by the Z-axis (AA and TS) and the angulus inferior (AI; the most caudal point of the scapula) pointing forward from the AA. Finally, we defined the Y-axis as a line perpendicular to the X- and Z-axes (Fig.2).

We calculated the rotational movement of the scapula relative to the thorax using the anatomical coordinate system defined above. Rotational motion of the scapula was investigated quantitatively based on Euler angle rotation. We quantified the rotation values for elevation (+)/depression (-) around the X-axis in the coronal plane (YZ), protraction (+)/retraction (-)



**Fig. 1** Image acquisition. (A) Computed tomography data were obtained in a neutral position and in full active forward elevation in prone subjects to eliminate any disturbance of scapular motion. (B) Two surface bone models including the thorax with an intact shoulder generated by the software. (C) The two bone surface models were superimposed on the thorax.



**Fig. 2** The anatomic coordination system. Three-dimensional rotational movement relative to the thorax was calculated based on the coronal (YZ), sagittal (XY), and axial (XZ) planes and translational movement along the X, Y, and Z axes in the Euler space.

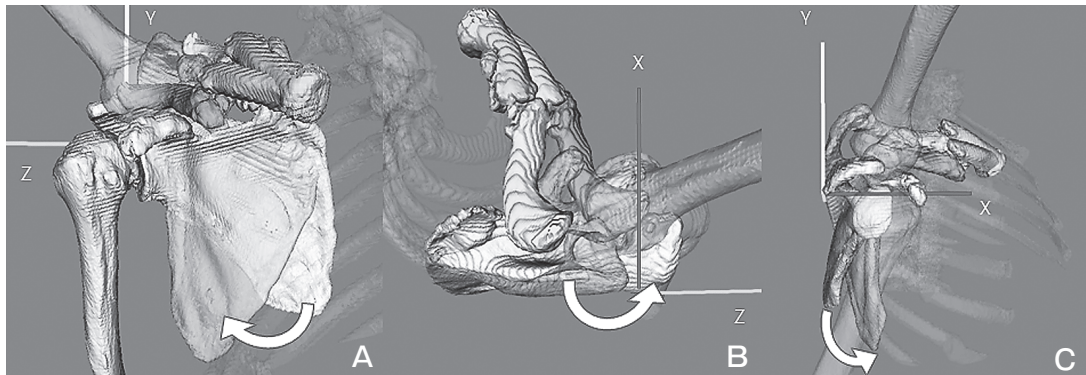
around the Y-axis in the axial plane (XZ), and anterior tilt (+)/posterior tilt (-) around the Z-axis in the sagittal plane (XY) in the Euler angle space, respectively (Fig. 3) [22].

In addition, we measured translational movement along the three axes. Posterior (+)/anterior (-) translation was measured along the X-axis, which was the distance from the coronal plane. Superior (+)/inferior (-) translation was checked along the Y-axis, which was the distance from the axial plane. Finally, medial (+)/lateral (-) translation was measured along the Z-axis, which was the distance from the sagittal plane (Fig. 4).

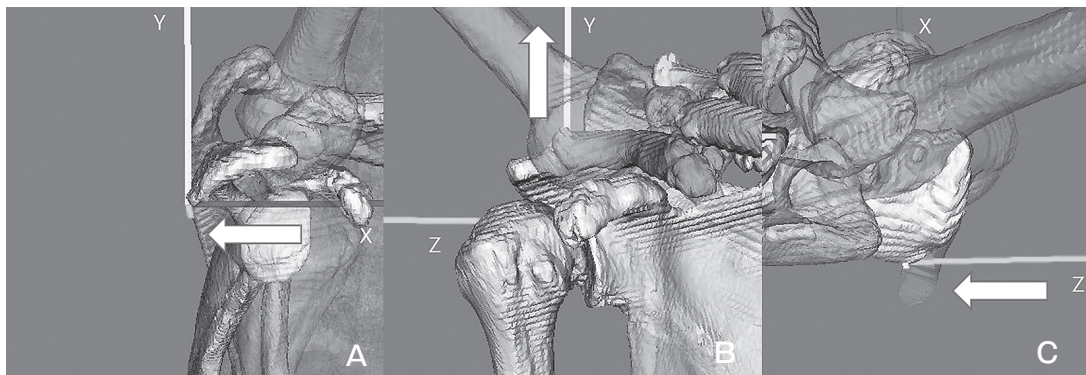
The paired *t*-test was used for the statistical analysis, and values of  $p < 0.05$  were considered significant. Data were analyzed using PASW Statistics for Windows, Version 18.0 (2009 release; SPSS Inc., Chicago, IL, USA).

## Results

In patients with scapular fractures, elevation was significantly decreased in the coronal plane (34.64°/



**Fig. 3** Three kinds of rotational movement in the Euler angle space. (A) Elevation and depression in the coronal plane (YZ). (B) Retraction and protraction in the axial plane (XZ). (C) Posterior and anterior tilt in the sagittal plane (YX) during forward elevation of the arm. Curved arrows indicate elevation, retraction, and posterior tilt in each plane.



**Fig. 4** Three kinds of translational movement in the Euler angle space. (A) Anterior and posterior translation along the X-axis. (B) Superior and inferior translation along the Y-axis. (C) Medial and lateral translation along the Z-axis. Arrows indicate anterior, superior, and medial translation for each axis.

43.73°) ( $p=0.030$ ) and anterior tilt was significantly increased in the sagittal plane (44.57°/29.12°) ( $p<0.001$ ) compared with that on the normal side, indicating that scapular dyskinesis occurred in the scapular fractures. However, no differences were observed during elevation of the arms in patients with clavicular fracture, indicating that clavicular fracture did not affect the scapular motion (Table 1, Fig. 5). Anterior translation (28.73 mm/18.56 mm) ( $p=0.040$ ) and superior translation were increased (33.85 mm/20.48 mm) ( $p=0.038$ ) in the patients with scapular fractures, compared with those on the normal side. However, no differences were observed in translational movement of the scapula during the elevation of arms in the patients with clavicular fractures (Table 2 and Fig. 6).

## Discussion

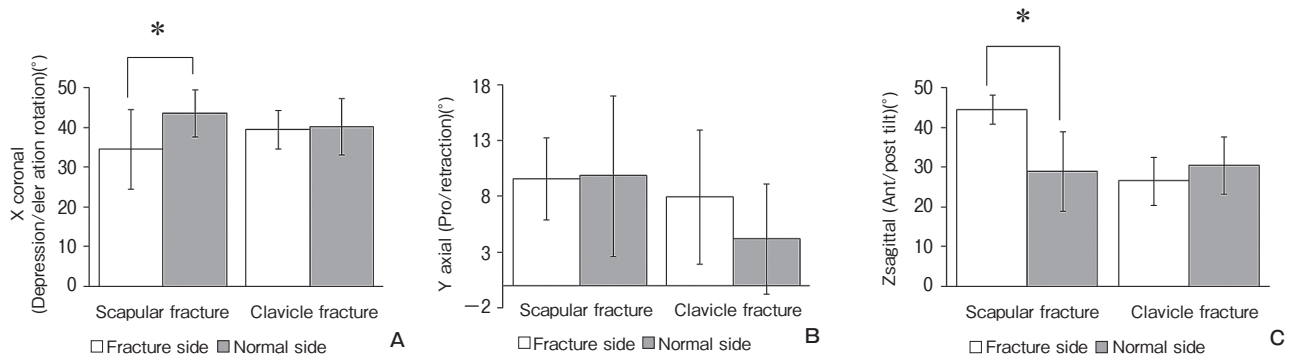
Scapular dyskinesis is an alteration of scapular kinematics and scapular motion due to a pathologic condition that leads to pain. Several studies have attempted to identify adequate methods for the evaluation of scapular dyskinesis [1,3,23]. Biomechanical and clinical knowledge regarding the role of the scapula in shoulder function is growing, and approaches to the evaluation and treatment of scapular dyskinesis are evolving [12,22].

However, all of these methods have several limitations and disadvantages that have not yet been resolved; 2D images do not produce accurate quantifiable data; cadaveric studies do not account for biomechanical compensation of muscular activity [17,24]; 3D electromagnetic findings [7,25], the fringe projection tech-

**Table 1** Three-dimensional rotational movement of the scapula

|                     |    | (+): Depression/(-): elevation<br>Coronal rotation (°) |              | (+): Protraction/(-): retraction<br>Axial rotation (°) |             | (+): Anterior/(-): posterior tilt<br>Sagittal rotation (°) |               |
|---------------------|----|--|--------------|--|-------------|--|---------------|
|                     |    | Injured  | Normal       | Injured  | Normal      | Injured  | Normal        |
| Scapular fracture   | 1  | 22.07  | 42.04        | 5.51   | 2.48        | 44.93  | 12.74         |
|                     | 2  | 34.57  | 45.22        | 1.94   | 5.47        | 42.41  | 33.32         |
|                     | 3  | 31.88  | 46.85        | 9.25   | 10.00       | 44.94  | 24.07         |
|                     | 4  | 36.29  | 32.65        | 17.67  | 16.11       | 51.70  | 30.21         |
|                     | 5  | 43.66  | 45.12        | 16.31  | 22.95       | 46.36  | 40.44         |
|                     | 6  | 38.75  | 52.07        | 14.18  | 3.72        | 37.30  | 15.17         |
|                     | 7  | 54.69  | 42.41        | 8.070  | 4.77        | 44.57  | 34.65         |
|                     | 8  | 22.63  | 36.99        | 2.71   | 8.07        | 46.39  | 39.06         |
|                     | 9  | 35.54  | 42.81        | 15.76  | 19.74       | 45.07  | 38.83         |
|                     | 10 | 26.30  | 51.10        | 4.45   | 5.14        | 41.98  | 22.73         |
| Mean ± SD           |    | 34.64 ± 9.91   | 43.73 ± 5.88 | 9.58 ± 5.97  | 9.84 ± 7.23 | 44.57 ± 3.68   | 29.12 ± 10.00 |
| Clavicular fracture | 1  | 46.49  | 51.14        | 5.42   | 2.58        | 33.38  | 43.61         |
|                     | 2  | 31.07  | 41.56        | 15.31  | 9.64        | 21.05  | 31.16         |
|                     | 3  | 46.11  | 46.34        | 8.27   | 10.85       | 34.13  | 35.24         |
|                     | 4  | 41.75  | 45.22        | 3.58   | 2.09        | 28.67  | 35.01         |
|                     | 5  | 39.47  | 42.69        | 20.84  | 7.50        | 36.19  | 35.52         |
|                     | 6  | 41.08  | 40.03        | 5.02   | 9.35        | 24.57  | 31.28         |
|                     | 7  | 39.41  | 41.75        | 5.43   | -3.10       | 20.23  | 52.64         |
|                     | 8  | 37.94  | 28.61        | 0.58   | 3.91        | 23.93  | 21.67         |
|                     | 9  | 33.72  | 31.13        | 14.57  | -2.37       | 23.95  | 21.65         |
|                     | 10 | 38.13  | 33.95        | 0.60   | 1.70        | 20.19  | 24.67         |
| Mean ± SD           |    | 39.52 ± 4.82   | 40.24 ± 7.06 | 7.96 ± 6.77  | 4.22 ± 4.96 | 26.63 ± 6.05   | 30.55 ± 7.11  |

A minus sign indicates the opposite direction of data in the same column. SD, standard deviation.

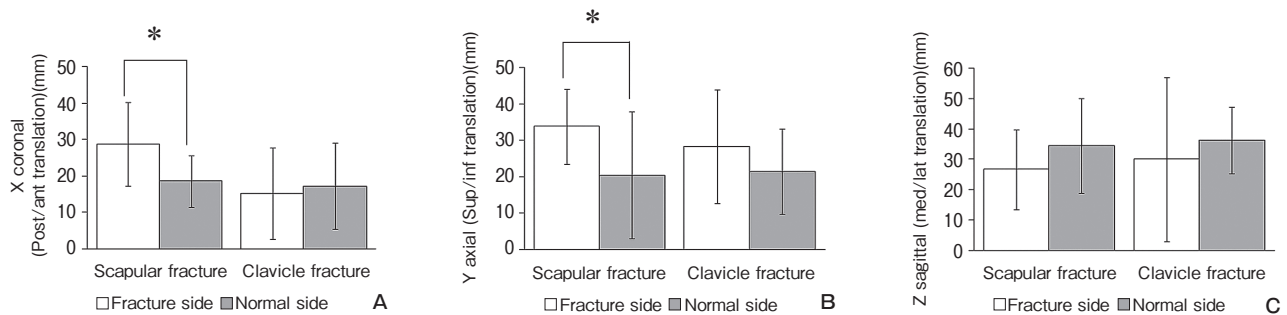


**Fig. 5** Three-dimensional rotational movement of the scapula measured during forward elevation. **(A)** Decreased elevation in the coronal plane in patients with a scapular fracture. **(B)** Slightly larger retraction in the axial plane in patients with a clavicular nonunion without statistical significance. **(C)** Increased posterior tilt in the sagittal plane in patients with a scapular fracture. An asterisk (\*) beyond the bar indicates statistical significance. A white box represents the fracture group, a shaded box represents the normal group, and the error bars show the standard deviation.

**Table 2** Three-dimensional translational movement of the scapula

|                     |    | (+): Posterior/(-): anterior translation (mm) X axis |               | (+): Superior/(-): inferior translation (mm) Y axis |               | (+): Medial/(-): lateral translation (mm) Z axis |               |
|---------------------|----|--|---------------|---|---------------|--|---------------|
|                     |    | Injured  | Normal        | Injured   | Normal        | Injured  | Normal        |
| Scapular fracture   | 1  | 48.81  | 17.80         | 25.62   | 46.49         | 18.05  | 40.76         |
|                     | 2  | 15.23  | 13.32         | 25.13   | 16.20         | 21.83  | 26.85         |
|                     | 3  | 25.06  | 20.92         | 24.35   | 4.04          | 34.74  | 46.29         |
|                     | 4  | 46.63  | 12.73         | 54.23   | 23.59         | 13.77  | 0.15          |
|                     | 5  | 29.89  | 26.62         | 34.20   | 39.75         | 49.92  | 32.71         |
|                     | 6  | 31.00  | 28.90         | 23.27   | 8.89          | 34.52  | 36.32         |
|                     | 7  | 23.22  | 19.33         | 46.87   | 45.49         | 33.94  | 50.96         |
|                     | 8  | 21.91  | 5.14          | 35.76   | 11.42         | 4.02   | 23.86         |
|                     | 9  | 29.89  | 17.59         | 38.29   | 5.76          | 33.96  | 54.29         |
|                     | 10 | 15.62  | 23.28         | 30.73   | 3.43          | 22.89  | 33.11         |
| Mean ± SD           |    | 28.73 ± 11.43  | 18.56 ± 7.02  | 33.85 ± 10.35                                       | 20.48 ± 17.32 | 26.76 ± 13.19                                    | 34.53 ± 5.64  |
| Clavicular fracture | 1  | 21.31  | 25.19         | 47.18   | 25.20         | 53.13  | 38.42         |
|                     | 2  | 24.44  | 35.75         | 7.42  | 11.76         | 67.14  | 56.93         |
|                     | 3  | 17.90  | 25.71         | 35.27   | 24.63         | 28.97  | 44.22         |
|                     | 4  | 3.58   | 18.71         | 28.67   | 30.72         | 10.24  | 34.39         |
|                     | 5  | 37.97  | 27.67         | 1.71  | 7.27          | 53.86  | 42.62         |
|                     | 6  | 0.48   | 1.94          | 52.18   | 34.47         | 29.56  | 37.09         |
|                     | 7  | 3.08   | 0.99          | 24.68   | 36.75         | 10.77  | 29.27         |
|                     | 8  | 8.41   | 9.95          | 30.79   | 6.50          | 39.20  | 34.54         |
|                     | 9  | 27.53  | 7.14          | 31.56   | 27.85         | 34.72  | 14.60         |
|                     | 10 | 7.05   | 18.82         | 24.31   | 9.02          | 26.89  | 31.40         |
| Mean ± SD           |    | 15.17 ± 12.52  | 17.19 ± 11.76 | 28.38 ± 15.51                                       | 21.42 ± 11.68 | 30.07 ± 27.06                                    | 36.35 ± 10.98 |

A minus sign indicates the opposite direction of data in the same column. SD, standard deviation.



**Fig. 6** Three-dimensional translational movement of the scapula measured during forward elevation. **(A)** Increased anterior translation along the X-axis in patients with a scapular fracture. **(B)** Increased superior translation along the Y-axis. **(C)** Slight decrease in medial translation along the Z-axis without statistical significance. An asterisk (\*) beyond the bar indicates statistical significance. A white box represents the injured group, a shaded box represents the normal group, and error bars show the standard deviation.

nique [9], the double calibration method [10], and infrared cameras [11] are useful to acquire *in vivo* data with muscular compensation, but tend to be subjective and inaccurate; and 3D wing CT is useful to acquire objective *in vivo* data, but only reflects the static state.

Park *et al.* [13] evaluated scapular dyskinesis by 3D wing CT in the static position. However, it is not possible to identify potential movement deficits by means of scapular kinematic measurements in their previous studies. scapular kinematic measurements which can

reveal potential movement deficits cannot be made. Thus, we used a well-organized 3D reconstruction system and a bone surface model. This technique produced an accurate 3D pattern video around 3 motion axes simultaneously. The accuracy of this 3D volume registration technique using CT data has been verified in a previous study [18,26].

Although nonsurgical management has been traditionally favored as the initial treatment modality for most clavicular fractures because of the high nonunion rates after operative treatment [27-29], contemporary studies are beginning to offer different perspectives on clavicular fractures [30-32]. They reported poorer outcomes resulting from conservative management compared to surgical treatment; these included high rates of nonunion, symptomatic malunion, and later functional return. Matsumura *et al.* [17,24] focused on scapular dyskinesia caused by kinematic changes in patients with clavicular nonunion. However, their study design using an *in vitro* cadaveric clavicle shortening model was completely passive with no muscle activity, did not reflect periscapular muscle activity or actual dynamics, and only showed bony movement. In contrast, our *in vivo* study has the advantage of clearly reflecting periscapular muscle activity, even during shortening or pseudo-motion due to nonunion.

Unlike in these previous studies [17,24], our *in vivo* analysis of three-dimensional dynamic scapular dyskinesia did not show any biomechanical differences in the scapular motion of patients with clavicular fractures. Furthermore, we found little abnormal scapular motion in patients with clavicular fractures, even during pseudo-motion and shortening of the clavicle. We believe that intact periscapular muscles compensated for the mechanical deformity with balance. So, despite the many advantages of surgical treatment for clavicle fracture, surgical treatment is not always necessary from the perspective of the restoration of scapular kinematics. Moreover, our present results suggest that conservative treatment could be a great alternative for patients with asymptomatic clavicular nonunion, without leading to scapular dyskinesia. Nonetheless, the relationship between clavicular nonunion and scapular dyskinesia should be evaluated by classifying subtypes of clavicular fractures.

Scapular fractures heal well due to the extensive muscular attachments and vascularity of the envelope. The large scapular-thoracic and glenohumeral motion

arc compensates for most deformities [33]. Insufficient bone stock, complex 3D anatomy, and difficult surgical exposures create internal fixation problems [34]. Therefore, a large number of scapular fractures end in malunion. No differences in the rates of patients returning to work, or experiencing pain or complications have been found between operative and non-operative treatment [33].

Our results suggest that a scapular fracture can cause scapular dyskinesia. Several studies with *in vivo* 3D scapular fracture motion analysis identified changes in thoraco-scapular motion. But the clinical prognosis of scapular fractures is excellent regardless of the state of the fracture union for the several reasons mentioned above [33,34]. This means that scapular dyskinesia caused by scapular fracture actually has little influence on various aspects of the clinical prognosis, including pain, complications, and return to work. We suggest that there are several factors complementing scapular dyskinesia, such as the periscapular function of the muscle and ligament. Patients with scapular fracture should thus be advised that rehabilitation is very important, since scapular fracture can cause shoulder dyskinesia.

Our study had several limitations. First, there was a small risk of radiation hazard. Our protocol required two CT scans, but we used a lower radiation dose than that in routine diagnostic CT. A previous experimental study showed that the radiation exposure required by this system is 1/30 that of the normal radiation dose associated with a conventional diagnostic CT scan with similar accuracy [35].

Another limitation was the relatively small number of patients. In addition, all the cases of clavicular fracture were nonunions without pain. Because, symptomatic clavicular fractures might be treated by surgery and it could be difficult to be involved our study. For this reason, we could not conclude from our results that fractures of the clavicle never cause scapular dyskinesia. It is also worth noting that the patients were not classified by the fracture subtypes of the clavicle and scapula. In a future study, it would be useful to evaluate scapular kinematics by fracture type.

Finally, we only evaluated thoraco-humeral motion. Scapular dyskinesia can alter scapula-humeral motion and shoulder arthrokinematics, both of which could play a role in producing dysfunction [12]. Scapular dyskinesia alters not only the scapular position but also

the dynamic scapula-thoracic motion. Thus, a future study should evaluate scapulo-humeral motion along with the scapula-thoracic pattern in order to improve our understanding of scapular dyskinesis.

In this unique study, we evaluated scapular dyskinesis using 3D *in vivo* kinematics and determined the relationship between scapular dyskinesis and fractures in the clavicle or scapula. Our results reveal the usefulness of *in vivo* 3D computerized motion analysis for evaluating scapular dyskinesis, and demonstrate that scapular dyskinesis can occur in patients with a scapular fracture. In the future, it will be necessary to classify fracture types and conduct a more accurate analysis using several positions or using a 3D motion capture method combined with a 2D one for a more detailed motion analysis.

Our results should help to improve the diagnostic methods for dynamic scapular dyskinesis *in vivo*.

In conclusion, an *in vivo* 3D computerized motion analysis was useful to evaluate dynamic scapular dyskinesis. Scapular fracture was shown to cause scapular dyskinesis, whereas clavicular fracture did not significantly alter the scapular kinematics.

**Acknowledgments.** The authors thank Mi-Yeon Lee, Biostatistician of the Medical Information Department, who performed the statistical analyses.

## References

- Kibler WB and Sciascia A: Current concepts: scapular dyskinesis. *Br J Sports Med* (2010) 44: 300–305.
- Kibler WB: Role of the scapula in the overhead throwing motion. *Contemp Orthop* (1991) 22: 525–532.
- Kibler WB and McMullen J: Scapular dyskinesis and its relation to shoulder pain. *J Am Acad Orthop Surg* (2003) 11: 142–151.
- Myers JB, Laudner KG, Pasquale MR, Bradley JP and Lephart SM: Glenohumeral range of motion deficits and posterior shoulder tightness in throwers with pathologic internal impingement. *Am J Sports Med* (2006) 34: 385–391.
- Ludewig PM and Cook TM: Alterations in shoulder kinematics and associated muscle activity in people with symptoms of shoulder impingement. *Phys Ther* (2000) 80: 276–291.
- Lukasiewicz AC, McClure P, Michener L, Pratt N and Sennett B: Comparison of 3-dimensional scapular position and orientation between subjects with and without shoulder impingement. *J Orthop Sports Phys Ther* (1999) 29: 574–583; discussion 584–576.
- McClure PW, Michener LA and Karduna AR: Shoulder function and 3-dimensional scapular kinematics in people with and without shoulder impingement syndrome. *Phys Ther* (2006) 86: 1075–1090.
- Pearl ML, Jackins S, Lippitt SB, Sidles JA and Matsen FA, 3rd: Humeroscapular positions in a shoulder range-of-motion-examination. *J Shoulder Elbow Surg* (1992) 1: 296–305.
- Gomes PF, Sesselmann M, Faria CD, Araujo PA and Teixeira-Salmela LF: Measurement of scapular kinematics with the moire fringe projection technique. *J Biomech* (2010) 43: 1215–1219.
- Brochard S, Lempereur M and Remy-Neris O: Double calibration: an accurate, reliable and easy-to-use method for 3D scapular motion analysis. *J Biomech* (2011) 44: 751–754.
- Yano Y, Hamada J, Tamai K, Yoshizaki K, Sahara R, Fujiwara T and Nohara Y: Different scapular kinematics in healthy subjects during arm elevation and lowering: glenohumeral and scapulothoracic patterns. *J Shoulder Elbow Surg* (2010) 19: 209–215.
- Uhl TL, Kibler WB, Gecewich B and Tripp BL: Evaluation of clinical assessment methods for scapular dyskinesis. *Arthroscopy* (2009) 25: 1240–1248.
- Park JY, Hwang JT, Kim KM, Makkar D, Moon SG and Han KJ: How to assess scapular dyskinesis precisely: 3-dimensional wing computer tomography—a new diagnostic modality. *J Shoulder Elbow Surg* (2013) 22: 1084–1091.
- de Groot JH: The variability of shoulder motions recorded by means of palpation. *Clin Biomech (Bristol, Avon)* (1997) 12: 461–472.
- Ludewig PM, Behrens SA, Meyer SM, Spoden SM and Wilson LA: Three-dimensional clavicular motion during arm elevation: reliability and descriptive data. *J Orthop Sports Phys Ther* (2004) 34: 140–149.
- Teece RM, Lunden JB, Lloyd AS, Kaiser AP, Cieminski CJ and Ludewig PM: Three-dimensional acromioclavicular joint motions during elevation of the arm. *J Orthop Sports Phys Ther* (2008) 38: 181–190.
- Matsumura N, Nakamichi N, Ikegami H, Nagura T, Imanishi N, Aiso S and Toyama Y: The function of the clavicle on scapular motion: a cadaveric study. *J Shoulder Elbow Surg* (2013) 22: 333–339.
- Kim E, Moritomo H, Murase T, Masatomi T, Miyake J and Sugamoto K: Three-dimensional analysis of acute plastic bowing deformity of ulna in radial head dislocation or radial shaft fracture using a computerized simulation system. *J Shoulder Elbow Surg* (2012) 21: 1644–1650.
- Lorensen WE and Cline HE: Marching cubes: A high resolution 3D surface construction algorithm. *ACM siggraph computer graphics* (1987) 21: 163–169.
- Murase T, Oka K, Moritomo H, Goto A, Yoshikawa H and Sugamoto K: Three-dimensional corrective osteotomy of malunited fractures of the upper extremity with use of a computer simulation system. *J Bone Joint Surg Am* (2008) 90: 2375–2389.
- Wu G, van der Helm FC, Veeger HE, Makhsous M, Van Roy P, Anglin C, Nagels J, Karduna AR, McQuade K, Wang X, Werner FW, Buchholz B and International Society of B: ISB recommendation on definitions of joint coordinate systems of various joints for the reporting of human joint motion—Part II: shoulder, elbow, wrist and hand. *J Biomech* (2005) 38: 981–992.
- Karduna AR, McClure PW and Michener LA: Scapular kinematics: effects of altering the Euler angle sequence of rotations. *J Biomech* (2000) 33: 1063–1068.
- Kibler WB, Ludewig PM, McClure PW, Michener LA, Bak K and Sciascia AD: Clinical implications of scapular dyskinesis in shoulder injury: the 2013 consensus statement from the ‘Scapular Summit’. *Br J Sports Med* (2013) 47: 877–885.
- Matsumura N, Ikegami H, Nakamichi N, Nakamura T, Nagura T, Imanishi N, Aiso S and Toyama Y: Effect of shortening deformity of the clavicle on scapular kinematics: a cadaveric study. *Am J Sports Med* (2010) 38: 1000–1006.
- McClure PW, Michener LA, Sennett BJ and Karduna AR: Direct



- 3-dimensional measurement of scapular kinematics during dynamic movements *in vivo*. *J Shoulder Elbow Surg* (2001) 10: 269–277.
26. Oka K, Doi K, Suzuki K, Murase T, Goto A, Yoshikawa H, Sugamoto K and Moritomo H: *In vivo* three-dimensional motion analysis of the forearm with radioulnar synostosis treated by the Kanaya procedure. *J Orthop Res* (2006) 24: 1028–1035.
  27. Jupiter JB and Leffert RD: Non-union of the clavicle. Associated complications and surgical management. *J Bone Joint Surg Am* (1987) 69: 753–760.
  28. Neer CS, 2nd: Nonunion of the clavicle. *J Am Med Assoc* (1960) 172: 1006–1011.
  29. Rowe CR: An atlas of anatomy and treatment of midclavicular fractures. *Clin Orthop Relat Res* (1968) 58: 29–42.
  30. Altamimi SA, McKee MD and Canadian Orthopaedic Trauma S: Nonoperative treatment compared with plate fixation of displaced midshaft clavicular fractures. Surgical technique. *J Bone Joint Surg Am* (2008) 90 Suppl 2 Pt 1: 1–8.
  31. Kulshrestha V, Roy T and Audige L: Operative versus nonoperative management of displaced midshaft clavicle fractures: a prospective cohort study. *J Orthop Trauma* (2011) 25: 31–38.
  32. McKee RC, Whelan DB, Schemitsch EH and McKee MD: Operative versus nonoperative care of displaced midshaft clavicular fractures: a meta-analysis of randomized clinical trials. *J Bone Joint Surg Am* (2012) 94: 675–684.
  33. Jones CB and Sietsema DL: Analysis of operative versus nonoperative treatment of displaced scapular fractures. *Clin Orthop Relat Res* (2011) 469: 3379–3389.
  34. Goss TP: Scapular Fractures and Dislocations: Diagnosis and Treatment. *J Am Acad Orthop Surg* (1995) 3: 22–33.
  35. Oka K, Murase T, Moritomo H, Goto A, Sugamoto K and Yoshikawa H: Accuracy analysis of three-dimensional bone surface models of the forearm constructed from multidetector computed tomography data. *Int J Med Robot* (2009) 5: 452–457.