

Evaluation of Urinary Stone Composition and Differentiation between Urinary Stones and Phleboliths Using Single-source Dual-energy Computed Tomography

Nanako Ogawa^{a,b*}, Shuhei Sato^b, Kentaro Ida^c, Katsuya Kato^d,
Yuichi Ariyoshi^e, Koichiro Wada^e, Yasutomo Nasu^e, and Susumu Kanazawa^b

^aDepartment of Radiology, Okayama Medical Center, Okayama 701-1192, Japan, Departments of ^bRadiology, and ^eUrology, Okayama University Graduate School of Medicine, Dentistry and Pharmaceutical Sciences, Okayama 700-8558, Japan,

^cDepartment of Radiologic Diagnosis and Interventional Radiology, Fukuyama City Hospital, Fukuyama, Hiroshima 721-8511, Japan, ^dDepartment of Diagnostic Radiology 2, Kawasaki Hospital, Kawasaki Medical School, Okayama 700-8505, Japan

The aim of this study was to investigate the utility of single-source dual-energy computed tomography (SS-DECT) composition analysis in characterizing different types of urinary stones and differentiating them from phleboliths. This study included 29 patients with urinary stones who were scheduled for surgery. All patients were scanned, first using single-energy computed tomography acquisition and then DECT acquisition on SS-DECT. Dual-energy data were archived to a Gemstone spectral imaging (GSI) viewer (GE Healthcare, Milwaukee, WI, USA). Hounsfield units (HU) and effective atomic numbers (Z_{eff}) were estimated using the GSI viewer. The results of dual-energy analysis were compared with the biochemical constitution of the stones. The chemical analysis determined that the stones included 32 calcium-based, 6 cystine and 1 struvite stone. Both HU and Z_{eff} values were helpful in differentiating calcium-based stones from cystine and struvite stones and phleboliths. The Z_{eff} values of phleboliths were significantly higher than those for struvite and cystine stones, whereas it was difficult to distinguish phleboliths from struvite and cystine stones using the HU values. Composition analysis using SS-DECT is helpful for distinguishing urinary stone types and discriminating phleboliths from urinary stones. Z_{eff} values may be more useful than HU values for differentiating urinary stones from phleboliths.

Key words: single-source dual-energy computed tomography, effective atomic number, urinary stone, phlebolith

Urinary stone disease is a common condition often encountered in clinical practice. The clinical management of urinary stones primarily depends on the patient's symptoms, stone size, and severity of urinary tract obstruction, but knowledge of stone hardness or fragility based on the stone composition is also significant [1]. Determining the precise chemical com-

position using computed tomography (CT) can help optimize the clinical management.

Single-energy CT (SECT) provides high accuracy for stone diagnosis and for confirming the stone location [2,3]. However, it is less effective for assessing stone composition [4-6]. On the other hand, we occasionally encounter small phleboliths that are difficult to discriminate from urinary stones in conventional SECT scans.

Recently, with the availability of dual-energy CT (DECT), it has become possible to obtain 2 image data sets with different X-ray spectra. Using this method, energy-dependent changes in the attenuation of the material can be analyzed, and materials having similar Hounsfield units (HU) but different chemical compositions can be distinguished [7].

In addition to dual-source DECT (DS-DECT), which employs two X-ray tubes and 2 detectors, single-source DECT (SS-DECT) has also become clinically available. SS-DECT can acquire both high-energy (140 kilovolts peak [kVp]) and low-energy (80 kVp) data with fast switching in less than 0.5-msec intervals [8]. Unlike DS-DECT, with its image-based dual-energy processing, SS-DECT features dual-energy processing of projection data. It has the advantage of permitting greater convenience in material decomposition, and it can obtain the effective atomic number (effective-Z: Z_{eff}) [9, 10]. The Z_{eff} conveys more detailed substance information than the HU value does.

Despite these advantages, few studies have reported on the composition analysis of urinary stones with SS-DECT using the Z_{eff} [9, 11]. To our knowledge, no published study has investigated the differentiation between urinary stones and phleboliths using SS-DECT composition analysis. The aim of this study was to investigate the utility of SS-DECT composition analysis in characterizing different types of urinary stones and in differentiating them from phleboliths.

Materials and Methods

The institutional review board approved this retrospective study with a waiver of the patient informed consent requirement (No. 1517).

This study included 29 patients with urinary stones who underwent surgery (16 men and 13 women; age \pm standard deviation, 55.7 ± 16.7 years). A total of 39 urinary stones were examined in these patients. Their locations were as follows: 20 renal stones, 16 ureter stones, and 3 bladder stones. All patients had undergone surgery after a DECT examination between April 2012 and October 2014 (transurethral lithotripsy (TUL), 25 cases; extracorporeal shock wave lithotripsy (ESWL), 2 cases; percutaneous nephrolithotripsy (PNL), 2 cases). One patient underwent treatment for bilateral urinary stones. All extracted stones had been chemically analyzed using Fourier transform

infrared (FTIR) spectroscopy (LSI Medience Corporation, Tokyo, Japan). Among the 29 patients, 19 phleboliths in 18 patients were detected on the limited DECT scan targeted at discovering urinary stones, and these 18 patients were enrolled in our study.

All patients underwent CT on a Discovery CT 750 HDCT (GE Healthcare, Milwaukee, WI, USA). First, a routine SECT acquisition with a scan range from the epiphrenal to the inguina was performed (tube voltage 120 kVp). Second, a targeted dual-energy acquisition around the region of the stones was performed (tube voltage 80 and 140 kV in less than 0.5 msec). The other parameters were as follows: an automated tube current modulation technique with a range of 250 to 700 mA; slice thickness of 1.25 mm; beam collimation of 40 mm; rotation speed of 0.6 sec; and pitch of 0.984 : 1.

A urinary stone was diagnosed based on calcification in the urinary tract. A phlebolith was diagnosed based on calcification in the pelvic cavity, outside of the urinary tract. Apparent arterial calcifications were excluded. The dual-energy data were archived to a workstation with a Gemstone spectral imaging (GSI) viewer (GE Healthcare). A monochromatic image series at 70 keV was reconstructed from dual-energy data at 1.25×1.25 mm in the axial plane. The HU values and Z_{eff} values were estimated by setting the region of interest (ROI) on the stones and phleboliths using the monochromatic image with the largest available cross-sectional area of the lesion. ROIs were created with a 1×1 -mm circle consisting of 4 pixels, and set on the center of the lesions. These measurements were repeated by the same radiologist to minimize variability. The results of dual-energy analysis were evaluated based on the biochemical constitution of the stone. Statistical analyses were performed using SPSS software, version 22, (SPSS, Chicago, IL, USA). The Kruskal-Wallis test was used to compare the HU values and the Z_{eff} values between the different stone groups and the phlebolith group. A value of $p < 0.05$ was considered statistically significant. All data are presented as means \pm standard deviation.

Results

The urinary tract was identified along its full length on the SECT images in all patients. Definitive stone composition results were available in all patients as determined by chemical analysis. Their compositions

were as follows: 32 calcium-based stones, 6 cystine stones and 1 struvite stone. The mean HU values for the stone types were as follows: calcium-based, $1,151 \pm 308$; cystine, 677 ± 64 ; struvite, 569 ± 63 ; and phlebolith, 722 ± 328 . The Z_{eff} values for the stone types were as follows: calcium-based, 13.1 ± 0.7 ; cystine, 11.4 ± 0.3 ; struvite, 10.6 ± 0.3 ; and phlebolith, 12.0 ± 1.3 . The mean sizes for the stone types were as follows: calcium-based, 9.2 ± 5.1 mm; cystine, 4.2 ± 0.4 mm; struvite, 20.0 mm; and phlebolith, 2.9 ± 1.2 mm (Table 1). There was a significant difference in HU values between calcium-based stones and the other stone types, whereas there was no significant difference among cystine, struvite and phleboliths (Fig. 1). There was a significant difference in Z_{eff} values between calcium-based stones and the other stone

types. The Z_{eff} value of phleboliths was significantly higher than those of struvite and cystine. There was no significant difference in Z_{eff} values between struvite and cystine stones (Fig. 2).

Discussion

Urinary stone disease is a common condition. The age-standardized annual incidence of upper urinary tract stones in Japan was 114.3 (per 100,000) in 2005. The peak age range of onset is the 30s to 60s in men and 50s to 70s in women [12]. Typical symptoms are colic pain and hematuria [13]. While selecting treatment options, stone size, location, the patient's symptoms, the anatomy of the urinary tract and the degree of obstruction remain important considerations, but

Table 1 Comparison of size, HU, and Z_{eff} for each stone type

Stone	Number of stones	HU at 70 keV	Z_{eff}	Size, mm
Calcium-based	32	$1,151 \pm 308$	13.1 ± 0.7	9.2 ± 5.1
Cystine	6	677 ± 64	11.4 ± 0.3	4.2 ± 0.4
Struvite	1	569 ± 63	10.6 ± 0.3	20.0
Phlebolith	19	722 ± 328	12.0 ± 1.3	2.9 ± 1.2

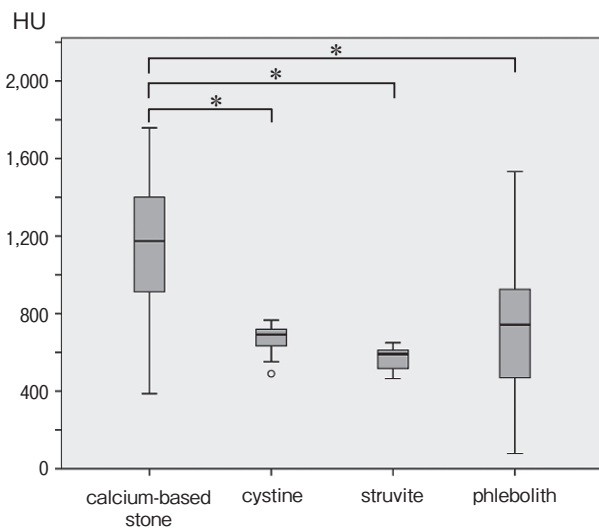


Fig. 1 Comparison of HU among calcium-based, cystine, and struvite stones and phleboliths. *P* values were determined using the Kruskal-Wallis test.

*Significant difference ($p < 0.05$) between the analyzed groups.

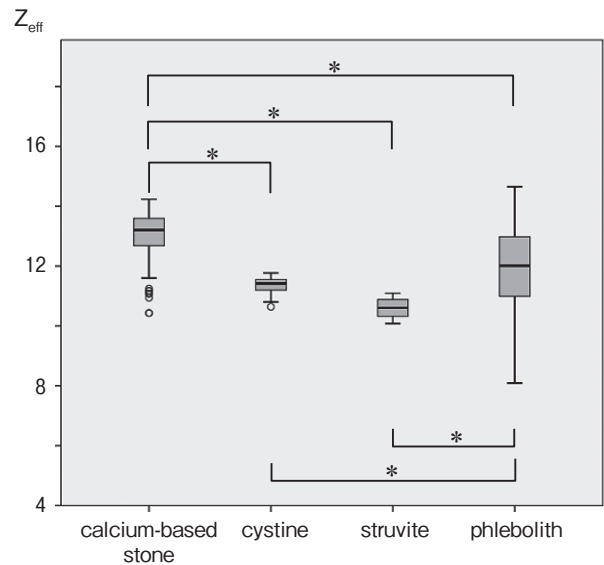


Fig. 2 Comparison of Z_{eff} values among calcium-based, cystine, and struvite stones and phleboliths. *P* values were determined using the Kruskal-Wallis test.

*Significant difference ($p < 0.05$) between the analyzed groups.

knowledge of the stone hardness or fragility based on its composition is also crucial [1]. Uric acid (UA) stones may be treated to facilitate stone dissolution, and patients with struvite stones will often be treated with antibiotics before any other intervention. On the other hand, calcium-based stones may require ESWL, ureteroscopy, or PNL, and typically do not require adjunct medical therapy [1, 14, 15]. Therefore, knowledge of the composition of urinary stones obtained through CT influences the treatment strategy.

Intrapelvic phleboliths, which are difficult to differentiate from urinary stones, are sometimes encountered in clinical practice. Phleboliths are calcified concretions within a vein wall that result from thrombosis [16]. Previous publications have reported some radiographic features of phleboliths, such as the “tail sign” or “central lucency” [16, 17]. However, clinicians occasionally have difficulty distinguishing phleboliths from urinary stones because of their adjacency to the ureter. Therefore, it would be useful to evaluate the utility of the composition analysis of calcifications using CT.

Unenhanced SECT is usually the preferred modality for the initial diagnosis of urinary stones, and it has high accuracy for stone diagnosis and for confirming the stone location. The specificity and sensitivity of SECT for stone diagnosis are both 90% to 100% [2, 3]. The advantages of SECT include a faster examination speed, the avoidance of intravenous contrast material and the ability to diagnose alternative abdominal diseases that cause the symptom of back pain [1]. However, SECT cannot be used to evaluate the chemical composition of the stones. Subsequent *in vivo* studies demonstrated substantial overlap in the HU values of UA, cystine, struvite, and calcium-based stones [4-6]. Dual-energy imaging, which can acquire different image data sets simultaneously, can be potentially used to assess the chemical composition of the stones more accurately [6, 7, 18]. With the introduction of DS-DECT, dual-energy imaging can now be used routinely. With DS-DECT, DECT scans can be simultaneously obtained using two X-ray tubes mounted in one gantry at a 90-degree angle from each other [19]. Numerous *in vitro* and *in vivo* studies have been conducted to determine the chemical composition of urinary stones using DS-DECT. These studies have shown excellent results with high sensitivity and specificity in differentiating multiple stone types [20-22].

In recent years, SS-DECT has become available.

SS-DECT uses one X-ray tube that rapidly switches between 80 and 140 kVp in less than 0.5 msec [8]. SS-DECT features dual-energy processing of projection data. With SS-DECT, the Z_{eff} , which is a descriptor of the density and atomic number of a material, can also be obtained from dual-energy data. To our knowledge, few studies have reported on the composition analysis of urinary stones using the Z_{eff} [9, 11]. Kulkarni *et al.* [11] showed that the Z_{eff} accurately stratified struvite, cystine, and calcium stones in a phantom, while in a group of patients, Z_{eff} values were reliable in identifying 100% of UA stones and 83% of calcium-based stones. In the current study, both HU and Z_{eff} values were helpful in differentiating calcium-based stones from struvite and cystine stones. These results are of clinical significance because the management of small stones is based on their chemical composition. There was no significant difference in HU and Z_{eff} values between struvite and cystine stones. In the current study, the Z_{eff} values of calcium-based, struvite, and cystine stones were approximated based on the values reported by Kulkarni *et al.* (Table 2) [11]. Therefore, despite the limited number of composition analyses of urinary stones using Z_{eff} values, the similarity of the Z_{eff} values between these two studies suggests that the Z_{eff} values would have good reproducibility.

In our study, both the HU and Z_{eff} values exhibited significant differences between phleboliths and calcium-based stone. In the case of HU values, it was difficult to distinguish phleboliths from struvite and cystine stones. However, using Z_{eff} values, there was a significant difference between phleboliths on one hand and struvite and cystine stones on the other. A semiquantitative chemical analysis of 14 phleboliths revealed a small central core of a blood clot with concentric layers of calcium-rich and calcium-poor oxides and phosphates [23]. Microscopic and chemical analysis of 20 phleboliths showed a small central “nucleus” surrounded by concentric laminations. Small phleboliths (≤ 4 mm in

Table 2 Comparison of mean Z_{eff} for each stone type estimated in Kulkarni’s study and present study

	Calcium-based stone	Cystine	Struvite	Uric acid
Kulkarni, <i>et al.</i> Z_{eff}	13.21	11.25	9.99	7.22
Present study Z_{eff}	13.1	11.4	10.6	—

diameter) contained very little if any calcium [23]. These findings imply that the central portions of phleboliths can be expected to be less calcified than the outer portions. This may be why there was a significant difference in Z_{eff} values between urinary stones and phleboliths in our study. However, both the HU and Z_{eff} values of phleboliths were quite variable in the present study. The cause of this variability may have been the small size of the phleboliths detected in this study. A previous study reported that composition analysis is less accurate for stones < 3 mm [24]. A larger patient population is required to minimize the variability.

One disadvantage of this examination was the increase of the radiation dose. The radiation dose reports of only 8 patients were recorded in the current study. Adding a dual-energy scan increased the CT dose index (CTDI) by an average of 91%, and the dose-length product (DLP) by an average of 72% in these 8 patients.

There were some limitations in our study. First, the number of non-calcium-based stones was small, and we did not encounter UA stones. In a future study, differentiating UA stones from other types of stones and phleboliths would be possible if the Z_{eff} value of UA stone were approximated based on the value reported by Kulkarni *et al.* ($Z_{\text{eff}} = 7.22$) [11]. Second, there was no pathological evidence of phleboliths. However, every calcification diagnosed as a phlebolith existed in ductal structures that were assumed to be vessels, and some calcifications were confirmed to be phleboliths by contrast-enhanced CT. Thus, the diagnosis was thought to be correct. Third, we set small ROIs on the centers of the lesions. However, because the stones and phleboliths were very small, we had no alternative way to avoid partial volume phenomena. Considering the constitution of the phleboliths, placing small ROIs at the centers of the lesions may be a reasonable approach. Fourth, our study was a retrospective study.

In conclusion, composition analysis using SS-DECT is helpful to distinguish between different urinary stone types. It also helps discriminate phleboliths from urinary stones. Z_{eff} values may be more useful for the quantitative differentiation of urinary stones and phleboliths than HU values. However, because few studies have used SS-DECT to analyze the composition of urinary stones, additional investigations will be needed to confirm the efficacy of this approach in clinical practice.

References

1. Kambadakone AR, Eisner BH, Catalano OA and Sahani DV: New and evolving concepts in the imaging and management of urolithiasis: urologists' perspective. *Radiographics* (2010) 30: 603–623.
2. Boulay I, Holtz P, Foley WD, White B and Begun FP: Ureteral calculi: diagnostic efficacy of helical CT and implications for treatment of patients. *AJR Am J Roentgenol* (1999) 172: 1485–1490.
3. Hamm M, Wawroschek F, Weckermann D, Knopfle E, Hackel T, Hauser H, Krawczak G and Harzmann R: Unenhanced helical computed tomography in the evaluation of acute flank pain. *Eur Urol* (2001) 39: 460–465.
4. Motley G, Dalrymple N, Keesling C, Fischer J and Harmon W: Hounsfield unit density in the determination of urinary stone composition. *Urology* (2001) 58: 170–173.
5. Saw KC, McAteer JA, Monga AG, Chua GT, Lingeman JE and Williams JC Jr: Helical CT of urinary calculi: effect of stone composition, stone size, and scan collimation. *AJR Am J Roentgenol* (2000) 175: 329–332.
6. Graser A, Johnson TR, Chandarana H and Macari M: Dual energy CT: preliminary observations and potential clinical applications in the abdomen. *Eur Radiol* (2009) 19: 13–23.
7. Johnson TR, Krauss B, Sedlmair M, Grasruck M, Bruder H, Morhard D, Fink C, Weckbach S, Lenhard M, Schmidt B, Flohr T, Reiser MF and Becker CR: Material differentiation by dual energy CT: initial experience. *Eur Radiol* (2007) 17: 1510–1517.
8. Silva AC, Morse BG, Hara AK, Paden RG, Hongo N and Pavlicek W: Dual-energy (spectral) CT: applications in abdominal imaging. *Radiographics* (2011) 31: 1031–1046.
9. Joshi M, Langan DA, Sahani DS, Kambadakone A, Aluri S, Procknow K, Wu X, Bhotika R, Okerlund D, Kulkarni N and Xu D: Effective atomic number accuracy for kidney stone characterization using spectral CT. *Proc SPIE Med Imag* (2010) 7622: pp76223K-1–12.
10. Mitchell MG, Emmanuel GC and Sandra CL: Accuracies of the synthesized monochromatic CT numbers and effective atomic numbers obtained with a rapid kVp switching dual energy CT scanner. *Med Phys* (2011) 38: 2222–2232.
11. Kulkarni NM, Eisner BH, Pinho DF, Joshi MC, Kambadakone AR and Sahani DV: Determination of renal stone composition in phantom and patients using single-source dual-energy computed tomography. *J Comput Assist Tomogr* (2013) 37: 37–45.
12. Yasui T, Iguchi M, Suzuki S and Kohri K: Prevalence and epidemiological characteristics of urolithiasis in Japan: national trends between 1965 and 2005. *Urology* (2008) 71: 209–213.
13. Goldfarb DS: In the clinic. Nephrolithiasis. *Ann Intern Med* (2009) 151: ITC2.
14. Ngo TC and Assimos DG: Uric Acid nephrolithiasis: recent progress and future directions. *Rev Urol* (2007) 9: 17–27.
15. Perks AE, Schuler TD, Lee J, Ghiculete D, Chung DG, D'A Honey RJ and Pace KT: Stone attenuation and skin-to-stone distance on computed tomography predicts for stone fragmentation by shock wave lithotripsy. *Urology* (2008) 72: 765–769.
16. Boridy IC, Nikolaidis P, Kawashima A, Goldman SM and Sandler CM: Ureterolithiasis: value of the tail sign in differentiating phleboliths from ureteral calculi at nonenhanced helical CT. *Radiology* (1999) 211: 619–621.
17. Kim JC: Central lucency of pelvic phleboliths: comparison of radiographs and noncontrast helical CT. *Clin Imaging* (2001) 25(2): 122–125.
18. Kaza RK, Platt JF, Cohan RH, Caoili EM, Al-Hawary MM and

- Wasnik A: Dual-energy CT with single- and dual-source scanners: current applications in evaluating the genitourinary tract. *Radiographics* (2012) 32: 353–369.
19. Flohr TG, McCollough CH, Bruder H, Patersilka M, Gruber K, Suss C, Grasruck M, Stierstorfer K, Krauss B, Raupach R, Primak AN, Kuttner A, Achenbach S, Becker C, Kopp A and Ohnesorge BM: First performance evaluation of a dual-source CT (DSCT) system. *Eur Radiol* (2006) 16: 256–268.
 20. Hidas G, Eliahou R, Duvdevani M, Coulon P, Lemaitre L, Gofrit ON, Pode D and Sosna J: Determination of renal stone composition with dual-energy CT: in vivo analysis and comparison with X-ray diffraction. *Radiology* (2010) 257: 394–401.
 21. Manglaviti G, Tresoldi S, Guerrer CS, Di Leo G, Montanari E, Sardanelli F and Cornalba G: In vivo evaluation of the chemical composition of urinary stones using dual-energy CT. *AJR Am J Roentgenol* (2011) 197: W76–83.
 22. Zilberman DE, Ferrandino MN, Preminger GM, Paulson EK, Lipkin ME and Boll DT: In vivo determination of urinary stone composition using dual energy computerized tomography with advanced post-acquisition processing. *J Urol* (2010) 184: 2354–2359.
 23. Traubici J, Neitlich JD and Smith RC: Distinguishing pelvic phleboliths from distal ureteral stones on routine unenhanced helical CT: is there a radiolucent center? *AJR Am J Roentgenol* (1999) 172: 13–17.
 24. Jepperson MA, Cernigliaro JG, Sella D, Ibrahim E, Thiel DD, Leng S and Haley WE: Dual-energy CT for the evaluation of urinary calculi: image interpretation, pitfalls and stone mimics. *Clin Radiol* (2013) 68: e707–714.