

Available online at www.pelagiarsearchlibrary.com



Pelagia Research Library

Advances in Applied Science Research, 2013, 4(4):145-151



Metabolism of precursors of N-nitrosamine *in vitro* and nitrosamine toxicology in wistar rat

Abebe E. F., Akpabio C. J. and Maduagwu E. N.

Department of Biochemistry, Basic Medical Sciences, University of Ibadan, Ibadan, Oyo State Nigeria

ABSTRACT

The aim of this study was to determine the level of nitrite in post mitochondrial fraction of liver and the toxicity in liver and kidney of wistar rat. Forty two male wistar rats were divided into six groups and each group was with varying doses of sodium nitrite and N-methylaniline. The following methods were employed, spectrophotometric, cell fractionation, centrifugation, dialysis, histopathology and ultra violet irradiation. There was a significant increase ($P < 0.05$) in the level of nitrite in the post mitochondrial fraction of liver in all the experimental groups compared to the control. After exposure to UV-light there was a decrease in the level of nitrite in all the groups, which indicates that the UV-light has degraded the precursors of N-nitrosamine. The histopathology study showed severe haemorrhage within sinusoid, the portal triad was infiltrated by inflammatory cells within the sinusoid of the liver and kidney. The present study showed that the concentration of nitrite in the post mitochondrial fraction of the liver of the rat depends on the dose of the toxins. The study also showed UV degradation of precursors of N-nitrosamine and the effect of the toxins on both liver and kidney.

Keywords: N-methylaniline, N-Nitrosamine, Sodium Nitrite, Toxicity, Ultra violet irradiation.

INTRODUCTION

Nitrite is known to be a precursor of toxic and carcinogenic N-nitrosamines [1] and induces cancer in experimental animals [2,3]. After ingestion, residual nitrite can form traces of certain N-nitroso compounds in stomach [where the $\text{pH} < 7$] on reacting with secondary amines which might also be present in the ingested food [4,17]. Nitrite can also interact with haemoglobin by oxidation of ferrous ion [Fe^{2+}] to ferric state [Fe^{3+}] preventing or reducing the ability of blood to transport oxygen, a condition known as methaemoglobinaemia [5,6].

N-Methylaniline is an aniline derivative and a precursor of nitrosamine. It is a toxic organic compound and it exists as a colourless or slightly yellow viscous liquid, which is insoluble in water and brown when exposed to air. It is used as a latent and coupling solvent and is also used as an intermediate for dyes, agrochemicals and to manufacture other organic products [7].

N-Methylaniline decomposes on heating and burning, producing toxic fumes including aniline and nitrogen oxides. N-methylaniline reacts violently with strong acids and oxidants.

N-methylaniline is harmful if swallowed or inhaled or absorbed through the skin can cause methaemoglobinaemia, central nervous system effects, eye and skin irritation, liver and kidney damage, gastrointestinal irritation with nausea, vomiting and diarrhoea [8].

N- Nitrosamines are extensively degraded when irradiated by UV light at room temperature [9]. They decompose to form aldehyde, nitrogen and nitrous oxides, or amine and nitrous acids. Nitrosamines are formed due to the interaction of various nitrosating agents (e.g. nitrite, nitrogen oxide) and amines in the foods [10]. The volatile N-nitroso-compounds most commonly encountered in foods are NDMA, NDEA and NPYR [11]. The extent of nitrosation in foods is affected both by the amount and the type of nitrosatable substances present in foods and the content of nitrosation catalysts and inhibitors. The nitrosating agents are formed from certain food additives and/or during specific processing conditions [12,18]. The Objective of this research is to investigate the *in vitro* metabolism of precursors of nitrosamine (sodium nitrite and N-Methylaniline) by the rats' post mitochondrial fraction and to evaluate the histopathology of different doses of the toxins (precursor of nitrosamine) in liver and kidney tissues of wistar rats.

MATERIALS AND METHODS

Chemical and reagents: Sodium nitrite (NaNO_2 , Mol.wt 69), N-Methylaniline ($\text{C}_6\text{H}_5\text{NH}(\text{CH}_3)$ Mol.wt 107.15) were obtained from Sigma (USA). All the other chemicals and test kits used were of analytical grade.

Experimental Animals

The experimental animals used in this work were healthy male albino rats (*Rattus norvegicus*) of the Wistar strain. They weighed between 180g and 200g, and were obtained from the animal house of Veterinary Physiology Department, University of Ibadan, where they had been fed commercial rat pellets *ad libitum* and allowed access to clean drinking water. Only those certified free of infection by the Veterinary pathologist were used. They were kept at room temperature (approximately 28°C) and all test animals were acclimatized to their environment before experiments were begun.

Animal treatment

Animals were divided into six groups and were given sodium nitrite [NaNO_2] and N-Methylaniline [NMA].

Group A- received a combination of 50mg of NMA and 200mg of NaNO_2/kg .

Group B- received a combination 25mg of NMA and 200mg NaNO_2/kg .

Group C- received a combination 25mg of NMA and 100mg NaNO_2/kg .

Group D- received normal feed with water (control).

Group E- received 50mg NaNO_2/kg .

Group F- received 25mg NaNO_2/kg .

Collection of blood samples for serum preparation:

The animals were sacrificed by cervical dislocation and blood was collected in dry plastic or glass centrifuge tubes. The blood was allowed to clot and immediately centrifuged at 2500rpm for 15 minutes in a table top centrifuge and serum was collected and preserved in a refrigerator at (at 4°C) for a short time before the analysis.

Histopathological analysis: Liver samples were immediately collected and fixed in 10% buffered formal saline solution for a period of at least 24 h before histopathological study. Samples were then embedded in paraffin wax and five-micron sections were prepared with a rotary microtome. These thin sections were stained with hematoxylin and eosin (H&E), mounted on glass slides with Canada balsam (Sigma, USA) and observed for pathological changes under a binocular microscope.

Preparation of liver post mitochondrial fraction (10,000 x g fraction)

Liver were quickly removed from animals and the blood mopped. The tissue was weighed and immediately cooled in ice-cold 0.15Mkcl. Gall bladder and extraneous tissues were early discarded. Liver tissue was homogenized with 4 volumes of 0.06 M phosphate buffer plus 0.15MKCL pH 7.4 using a Teflon glass homogenizer.

The homogenate was centrifuged at 800 x g for 15 minutes to remove cell debris and nuclei and the resulting supernatant was then centrifuged at 10,000 x g for 15 minutes in an MSE high speed refrigerated centrifuge. The resultant supernatant containing the post mitochondrial fraction was used for the *in vitro* studies.

Incubation assay

The complete incubation medium had a total volume of 6ml and contained NADP (0.2mM), glucose-6-phosphate (0.2mM), MgCL₂ (20mM), 0.06M phosphate buffer, 0.15MKCL and 2.5ml of post mitochondrial fraction of liver homogenate. Sodium nitrite and N-methylaniline were put in different concentration.

Concentration of N-methylaniline and sodium nitrite for Incubation

Group A was incubated with 5mM of N-methylaniline and 5mM of sodium nitrite.

Group B was incubated with 5mM of sodium nitrite and 2.5mM of NMA.

Group C was incubated with 2.5mM of sodium nitrite and 2.5mM of NMA.

Group D was not incubated with any toxin (control).

Group E was incubated with 5mM of NaNO₂ and F was incubated with 2.5mM of NaNO₂.

Data analysis

Statistical analysis was performed using the Microsoft excel 11.0 statistical package, all results were expressed as means \pm S.D. Comparisons within each group were performed using Student's T- test for paired and unpaired data.

RESULTS AND DISCUSSION

Table: 1 Nitrite concentrations before, after incubation and after exposure to UV light in post mitochondrial fraction of rats following incubation with NMA + NaNO₂ and NaNO₂ at 37°C, pH 7.4

ANIMAL GROUPS	Weight of liver(g)	Before incubation (μ g/ml)	After incubation (μ g/ml)	After exposure to UV light (μ g/ml)
Group A	5.91	5.088 \pm 0.119	138.545 \pm 0.033	134.457 \pm 0.043
Group B	6.93	4.867 \pm 0.179	137.663 \pm 0.507	135.600 \pm 2.630
Group C	7.18	3.144 \pm 0.062	136.680 \pm 0.253	99.563 \pm 1.0426
Group D	6.82	1.489 \pm 0.008	6.606 \pm 0.125	6.505 \pm 0.125
Group E	6.64	2.385 \pm 0.211	137.720 \pm 0.607	115.410 \pm 0.129
Group F	6.27	2.106 \pm 0.109	111.343 \pm 0.129	95.658 \pm 0.129

Values are mean \pm SD of 5 determinants

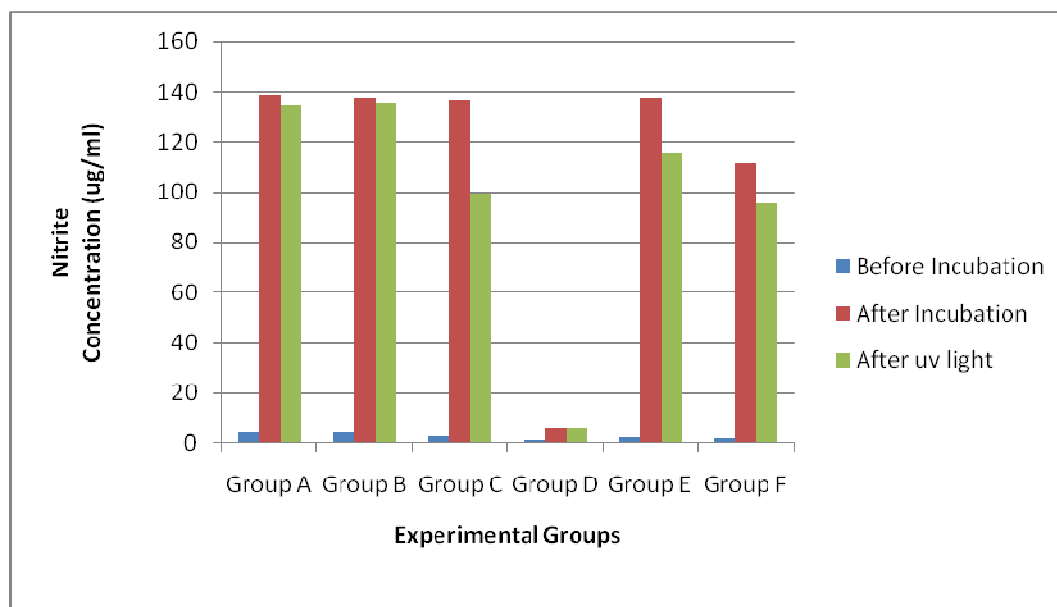
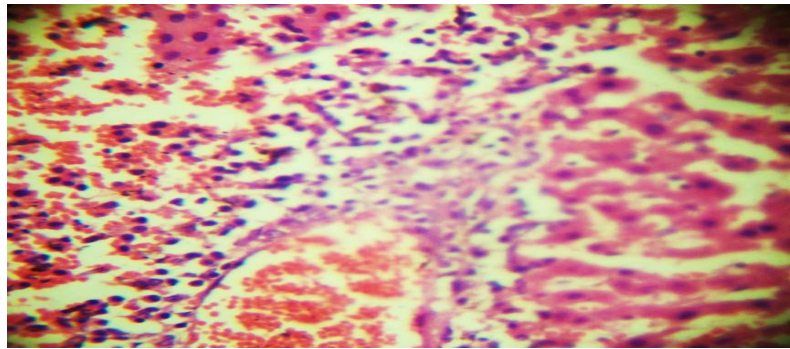


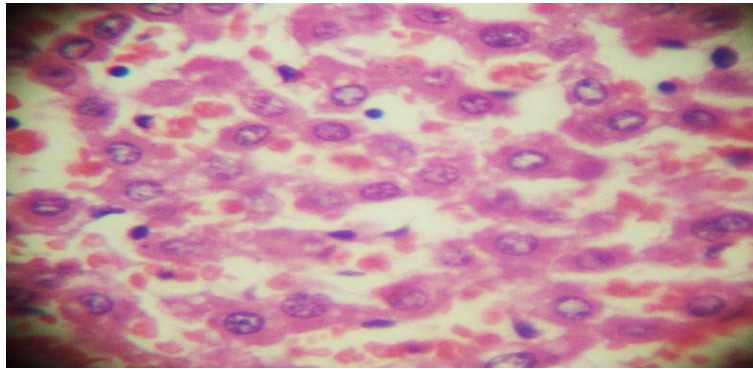
Figure: 1 Nitrite concentrations before, after incubation and after exposure to UV light in post mitochondrial fraction of rats following incubation with NMA + NaNO₂ and NaNO₂ at 37°C, pH 7.4

Histopathology sections of liver and kidney of rats administered with different doses of NMA and NaNO₂



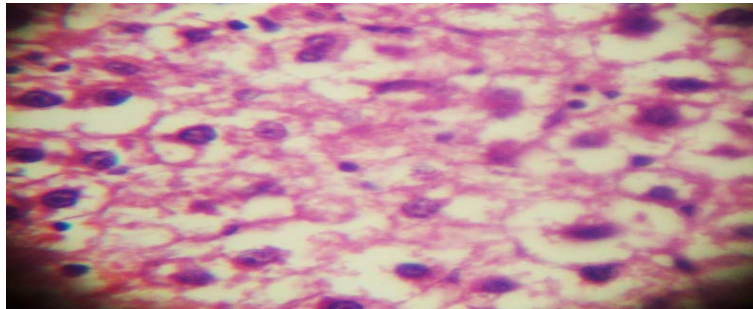
X400

Figure 2: A photomicrograph of liver section of rat given a dose of 50mg/kg of N-methylaniline and 200mg/kg of sodium nitrite showing severe heamorrhage within the sinusoid. The portal triad is infiltrated by inflammatory cells



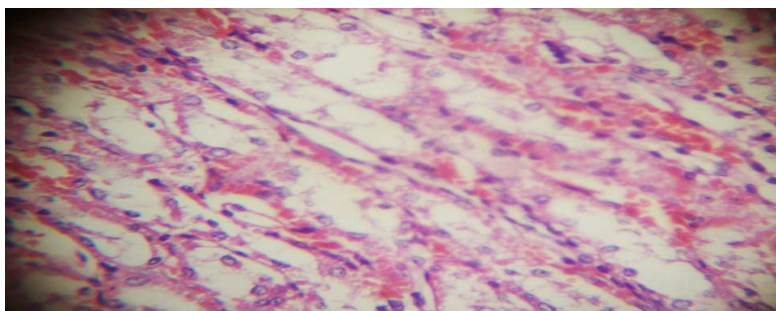
X400

Figure 3: A photomicrograph of liver section of rat given a dose of 25mg/kg of N-methylaniline and 200mg/kg of sodium nitrite showing infiltration of sinusoid by inflammatory cells



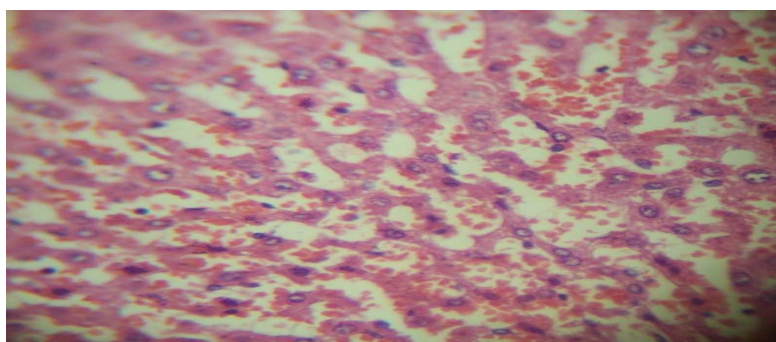
X400

Figure 4: A photomicrograph of liver section of rat given only water (control) showing normal hepatocytes. No hemorrhage is seen



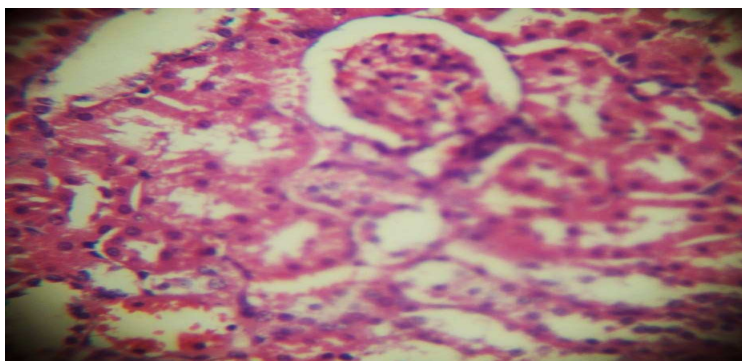
X400

Figure 5: A photomicrograph of kidney section of rat given a dose of 50mg/kg of sodium nitrite showing medullary ray with haemorrhage



X400

Figure 6: A photomicrograph of kidney section of rat given a dose of 25mg/kg of sodium nitrite showing haemorrhage and inflammatory cells within the sinusoid



X400

Figure 7: A photomicrograph of kidney section of rat given only water (control) showing normal tubules and glomerulus

DISCUSSION

When the post mitochondrial fraction was incubated with NMA + NaNO₂ for Group A, B, C and NaNO₂ only for Group E and Group F, there was a significant increase ($P < 0.05$) in the level of nitrite in all experimental groups compared with the control (table1). The high level of nitrite after incubation indicates that the microsomal enzyme (N-demethylase) in the liver metabolized N-methylaniline. After 15 minutes exposure to UV light there was a decrease in the level of nitrite in all the experimental groups, which indicates that the UV-light has degraded the precursors of N-nitrosamine. N-Nitrosamines are extensively degraded when irradiated by UV light at room temperature [13, 14,15].

In the histopathology examination, there was no visible lesion observed in the control group of rats. The characteristic liver lesion observed in the rats given concurrent dose of N-methylaniline and sodium nitrite were

infiltration in the portal traid, centrilobular hepatocellular damage, which exhibited a clear distinction between affected and unaffected cells.

However, rats given concurrent doses of 50mg/kg of N-Methylaniline and 200mg/kg of Sodium Nitrite produced severe haemorrhage within the sinusoid; the portal triad was infiltrated by inflammatory cells (fig.2). Rats given 25mg/kg of N-Methylaniline and 200mg/Kg of sodium nitrite indicated infiltration of sinusoid by inflammatory cells (fig.3). Rats given a dose of 50mg/kg of sodium nitrite showed medullary ray with haemorrhage in the kidney (fig.5). Rats given a dose of 25mg/kg of sodium nitrite showed haemorrhage and inflammatory cells within the sinusoid of the kidney (fig.6). It has been reported that there was a sequential histological changes when combined dose of N-methylaniline, dimethylaniline and sodium nitrite were administered to rats [16].

The metabolism of N-dimethylaniline has been studied in many species and in human tissues. It involves enzymatic N-demethylation, N-oxidation and ring hydroxylation. Aniline is a major metabolite. Chronic methaemoglobinaemia and erythrocyte haemolysis, with concomitant splenomegaly and other pathological lesions characteristic of aniline, were observed in mice and rats treated with N-dimethylaniline. The application of 3 grams or more per kg of body weight upon the intact skin of a rabbit for 1 hour or more always produced death. Increased blood methaemoglobin levels, slight erythropenia, decreased haemoglobin concentration, and reticulocytosis were observed in workers exposed to N, N-dimethylaniline [16].

CONCLUSION

The present study showed that the appearance of high nitrite concentration from N-methylaniline combined with NaNO₂ over NaNO₂ alone in incubation mediums shows that N-methylaniline undergoes a metabolism that contributes to high nitrite formation and metabolism. The higher the dose of the toxins, the higher the concentration of nitrite in the post mitochondrial fraction of the liver of the rat. The study also showed ultra violet degradation of precursors of N-nitrosamine and the metabolism of these toxins cause both liver and kidney derangement.

ABBREVIATION

mM	: Millimolar
NADP	: Nicotinateamide dinucleotide phosphate
Na ₂ CO ₃	: Sodium Carbonate
NaNO ₂	: Sodium Nitrite
NMA	: N-methylaniline
NDEA	: N-nitrosodiethylamine
NDMA	: N-nitrosodimethylamine
NEDA	: Naphthylenediamine
NO	: Nitric Oxide
NPYR	: Nitrosopyrine
NPRO	: Nitrosoproline
RPM	: Revolution per minute
TCA	: Trichloroacetic acid

REFERENCES

- [1] Bassir O, Maduagwu, E N, *J. Agric Fd. Chem.*, **1978**, **26**, 200.
- [2] Sen NP, Baddoo P A and Seaman S W, *J. Food Sci*, **1986**, **51**, 821 - 825.
- [3] Mirvish SS, Ramm MD, Sams JP, Babcock DM, *Cancer Res*, **1988**, **48**: 1095-1099.
- [4] O'Neill I K, Borstel R C, Miller CT, Long J, Bartsch H, IARC Scientific Publication, **1984**, **57**; Oxford University Press: Lyon,
- [5] Phillips WEJ, *Food and Cosmetics Toxicol.* **1971**, **9**:219-228.
- [6] Tannenbaum SR, Origin in human. *Science*, **1979**, **205**, 1333 - 1335.
- [7] Jenkins RL, JE Haskins, LG Carmona, and RB Baird, *Arch. Environm. Contam. Toxicol.* **1978**, **7**,301 – 315.
- [8] Gralla EJ, Bus JS, Reno F, Cushman J, lland BN, *Toxicol. Appl. Pharmacol*, **1979**, **48**:A97.
- [9] Hiramoto K, Ryumo Y, Kikuawa K, *Mutat Res*, **2002**, **520**,103 – 111.
- [10] Preussmann R, Stewart BW, ACS Monograph, **1984**, **182**,643.
- [11] Walker R, *Food. Add. Conto.* **1990**, **7**(b), 717 - 768.

- [12] Tricker A R, Preussmann R, *Mutat. Res*, **1991**, 259, 277 - 289.
- [13] Xu BB, Chen Z L, Qi F. and Yang L, *Chinese Science Bulletin*, **2008**, 53.21: 3395-3401.
- [14] Akpabio C, Augusta A, Adeleke E, Ogunsola M, Maduagwu E, *European J. of Expt. Bio*, **2013**, 3(2):94-103.
- [15] Abdo KM, Jokinen MP, Hiles R, *Toxicol. environ. Health*, **1990**, 29, 77-88.
- [16] Markel H, Jr Wilcox T, Health Hazard Evaluation Report No. HHE, **1981**, 79, 04-838.
- [17] Khodadady M, Shahryari T, Dorri H, Sharifzadah GR, Ziyazade A, *European Journal of Experimental Biology*, **2012**, 2 (6):2120-2124
- [18] Serag H, Edrees G, *European Journal of Experimental Biology*, **2011**, 1(4):87-92