

Research paper

Voluntary Bilateral Scapulothoracic Dissociation

Sebastián Cruz Morande¹, Julio Duart-Clemente², Rafael Llombart-Blanco³, José Luis Beguiristain -Gurpide⁴

¹ Department of Traumatology and Orthopaedic Surgery, University Clinic of Navarra
scruz@unav.es

² Pediatric Orthopedic Units, Orthopedic Surgery and Traumatology Department, Complejo Hospitalario de Navarra

³ Department of Traumatology and Orthopaedic Surgery, University Clinic of Navarra

⁴ Department of Traumatology and Orthopaedic Surgery, University Clinic of Navarra

ABSTRACT / Study design: Case report.

Objective: To report a rare case of voluntary scapulothoracic dislocation and its treatment.

Background data: Scapulothoracic dissociation is a rare condition. We report a case of a teenager who could voluntarily dislocate her scapulae.

Results: The patient was treated surgically by fixing her scapula to the contralateral transverse process and carrying out associated muscle plication. Now, after a 12-year follow-up, the patient is asymptomatic.

Conclusions: Fixation of the scapula to the contralateral transverse process and plication of associated muscles is a valid treatment for this condition.

Key words: perinatal outcomes, older women, pregnancy.

Introduction

The scapulothoracic joint forms part of the complex shoulder girdle and it contributes to a third of the arm's elevation¹. Codman has described this process as the scapulohumeral rhythm².

The scapulothoracic joint is formed by the ventral surface of the scapula covered by the subscapularis muscle, and the posterolateral aspect of the thoracic cage covered by the serratus (posterosuperior and inferior) muscles between the 2nd and 8th rib, and an intermediate fascial sheet that runs between them from the 4th to the 9th rib.

The scapula is attached to the rib cage through the insertion of different muscles (the trapezius, becoming a true suspensor ligament and the levator scapulae in the superior surface; rhomboideus minor and rhomboideus major and again the trapezius in the posterior surface restricting the anterior translation, antagonized by the serratus anterior inserted in the anterior lip of the scapula; meanwhile the latissimus dorsi as well as the teres major and minor inserted in the inferior angle apply the scapula against the thorax).³

Dislocation or scapulothoracic dissociation is a rare condition, occurring mainly in association with a high-energy trauma⁴; only a few reports of atraumatic or voluntary dislocation cases have been published.

We report the case of a teenager who could voluntarily dislocate both her scapulae.

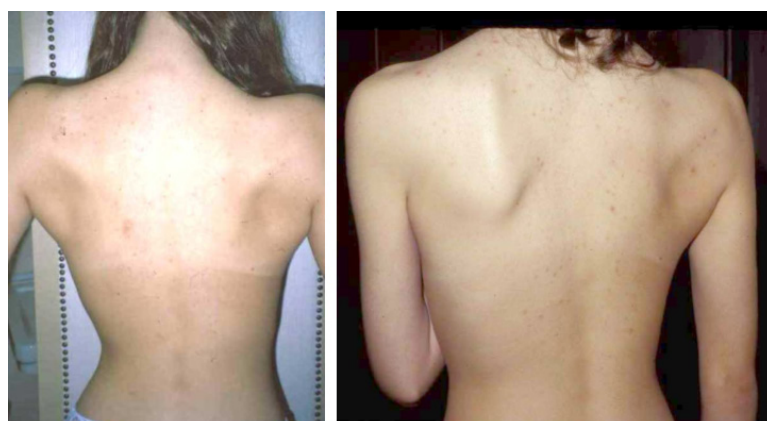Case Report

The case concerns a 16-year-old girl who came to our hospital with a history of recurrent episodes of bilateral scapular dislocation that had taken place over the previous few months.

The patient had a history of hyperlaxity, with sporadic episodes of subluxation of her hand joints and temporomandibular dislocation. When she was 14 years old, she underwent surgery for snapping hip syndrome. We suspected Ehlers Danlos disease.

No abnormalities were found by general examination. The patient's cardiovascular and ophthalmologic examination were normal. Osteoarticular physical examination was also normal except for an ability to do a voluntary lateral dislocation of her scapulae, which, from behind, gave the appearance of a swimmer's back, without altering the function of her upper limbs. (Fig. 1-2)

Figure 1 / Macroscopic aspect preoperative



Research paper

In January 1997, surgery was performed because the patient could no longer do normal daily activities or sports as a result of the high recurrence of the scapular dislocation.

Fixation of the scapula was by means of a Dacron ligament prosthesis to the contralateral transverse process, associating a plication of the muscles of the inner edge of both scapulae. (Fig.3)

The patient progressed satisfactorily until August 1997, when she presented a left winged scapula that needed a new muscle plication. Later, in November 1997, she suffered an episode of lateral displacement of her right scapula; this was treated by anchoring the scapula to the ribs with Dacron. (Fig.4)

No alterations were found in the histological study of muscle, skin, fat and fibrous tissue.

Biochemical studies revealed a decrease in type III collagen. Genetic studies, however, revealed no mutations, and consequently we could not confirm a diagnosis of Ehlers Danlos disease.

At present, after a 12-year follow-up, results remain satisfactory: there is no shoulder movement limitation and there have been no new episodes of scapula dislocation. (Fig. 5)

Figure 3 / Scheme of the surgery

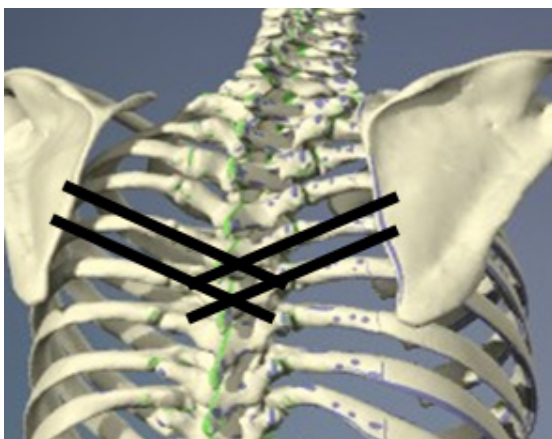


Figure 2 / A. Preoperative x-ray B. Preoperative CT scan

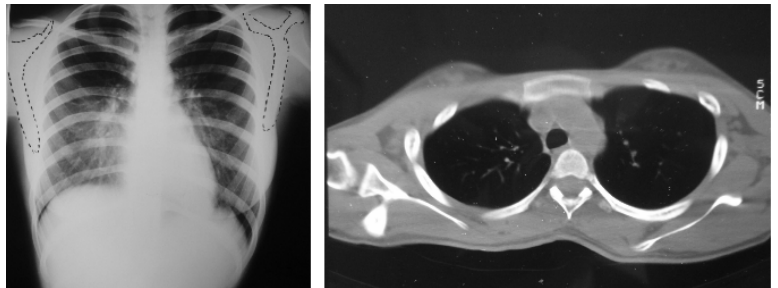
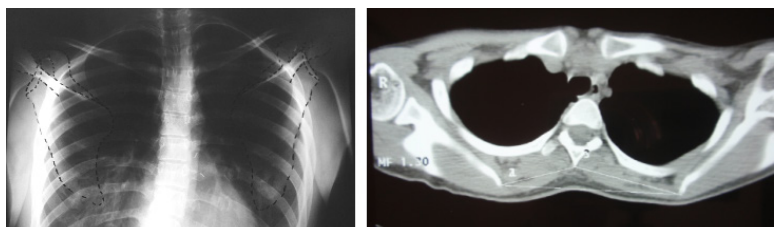


Figure 4 / Final aspect

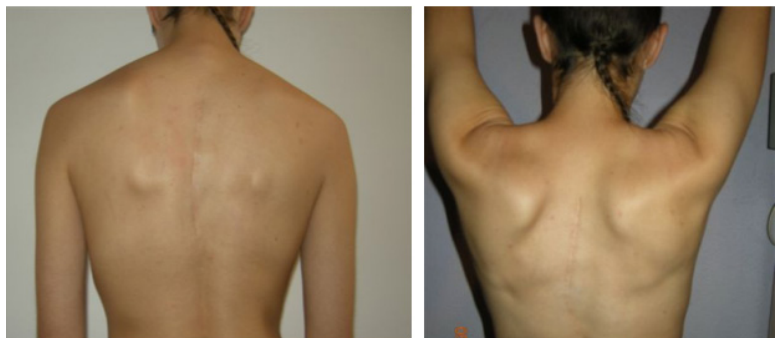

Figure 5 / A. Final x-ray B. Final CT scan



Research paper

Discussion

Scapulothoracic dissociation is usually a result of a high-energy trauma or a violent traction of the upper limb. Neurovascular injuries such as brachial plexus injury, or subclavian artery lesion and shoulder girdle fractures are frequently associated.^{4,7, 8}

Only a few cases of non-traumatic scapula dissociation, dislocations, or subluxations have been described in the literature. Hollinshead⁹ reported a case of scapula subluxation in a male patient with an osteochondroma in the ventral surface of his scapula resulting in snapping and blockage of the joint. The patient was treated by resection of the tumor.

Ward¹⁰ presented a case of non-traumatic scapulothoracic dislocation secondary to a Pancoast tumor resection. Walker¹¹ described the case of a 19-year-old girl with a unilateral scapulothoracic dislocation after a small fall; treatment was by closed reduction.

In the literature, we have found only one other case of dislocation that had no associated pathology

or related trauma: Kushwaha¹² reported the case of a woman who suffered a dislocation when changing gears in her car; closed reduction was the treatment.

What distinguishes the case reported here, is that our patient was able to dislocate and relocate both her scapula voluntarily. Studies were conducted to investigate the a possible diagnosis of Ehlers Danlos Syndrome, as this is characterized by joint hyperlaxity that is associated with joint subluxation and dislocation¹³. The results of these genetic and histological studies were negative for Ehlers Danlos Syndrome.

The surgical treatment was conceived to anchor the scapulae without sacrificing joint movement. To this end, we used Dacron grafts (used in occasions for ACL reconstruction) and then, to increase stability of the shoulder joint we carried out plication in associated muscles.

Research paper

References

1. Veeger HE, FC van der Helm. Shoulder function: the perfect compromise between mobility and stability. *J Biomech*, 2007. 40(10): p. 2119-29.
2. Pearl ML, Sidles JA, Lippitt SB, Harryman DT, Masten FA. Codman's paradox: sixty years later, *Journal of Shoulder and Elbow Surgery* 1992 (2), pp. 219-225.
3. Rouvière H, Delmas V, Anatomie humaine, descriptive, topographique et fonctionnelle. Paris. Elsevier, Vol. 3. 2005
4. An HS, Vonderbrink JP, Ebraheim NA, Shiple F, Jackson WT. Open scapulothoracic dissociation with intact neurovascular status in a child. *J Orthop Trauma*, 1988. 2(1): p. 36-8.
5. Brucker PU, Gruen GS, Kaufmann RA. Scapulothoracic dissociation: evaluation and management. *Injury*, 2005. 36(10): p. 1147-55.
6. Ebraheim NA, Pearlstein SR, Savolaine ER, Gordon SL, Jackson WT, Corray T. Scapulothoracic dissociation (closed avulsion of the scapula, subclavian artery, and brachial plexus): a newly recognized variant, a new classification, and a review of the literature and treatment options. *J Orthop Trauma*, 1987. 1(1): p. 18-23.
7. Ebraheim NA, An HS, Jackson WT, Pearlstein SR, Burgess A, Tscherne H, Hass N, Kellam J, Wiperman BU. Scapulothoracic dissociation. *J Bone Joint Surg Am*, 1988. 70(3): p. 428-32.
8. Butters KP, Fracture of the scapula. In. Rockwood CA, Green DP, Bucholz RW, Heckman JD, eds. *Fractures in Adults 5^o ed.* Philadelphia: Lippincot Williams & Wilkins Publishers. Vol. 1. 2001:615-6
9. Hollinshead R, James KW. Scapulothoracic dislocation (locked scapula). A case report. *J Bone Joint Surg Am*, 1979. 61(7): p. 1102-3.
10. Ward WG, Weaver JP, Garrett WE Jr. Locked scapula. A case report. *J Bone Joint Surg Am*, 1989. 71(10): p. 1558-9.
11. Walker JS, Walker BB. Scapular dislocation (locked scapula). *Ann Emerg Med*, 1990. 19(11): p. 1329-31.
12. Kushwaha VP, Shapiro MS. Voluntary scapulothoracic subluxation: a case report. *Am J Orthop*, 1997. 26(7): p. 499-501.
13. Parapia LA, Jackson C. Ehlers-Danlos syndrome a historical review. *Br J Haematol*, 2008. 141(1): p. 32-5.