

Research paper

Cobalt chloride allergy. Diagnosis and treatment of a rare cause of early hip prosthesis mobilization

Rafael Llombart Blanco¹, Pablo Díaz de Rada², Leyre Muñoa³, Miguel Idoate⁴

¹ Department of Orthopaedic Surgery, University Clinic of Navarra
rllombartb@gmail.com

² Department of Orthopaedic Surgery, University Clinic of Navarra

³ Department of Orthopaedic Surgery, University Clinic of Navarra

⁴ Department of Anatomic Pathology, University Clinic of Navarra

ABSTRACT / Purpose: Discovering the cause of early hip prosthesis mobilization is a challenge for the orthopedic surgeon. Infection is one possible cause of early prosthesis failure, but there are other causes that orthopedic surgeons should also consider.

Case report: We present the case of a 61-year-old male patient with early hip failure due to cobalt allergy and describe the different diagnosis steps that led to this diagnosis.

Discussion: Collaboration between departments was fundamental in order to reach the diagnosis. Revision surgery using components without the allergenic metal and using different surface bearing materials (ceramic-ceramic) gave satisfactory results.

Key words: hip prosthesis, cobalt, and hypersensitivity.

Case Report

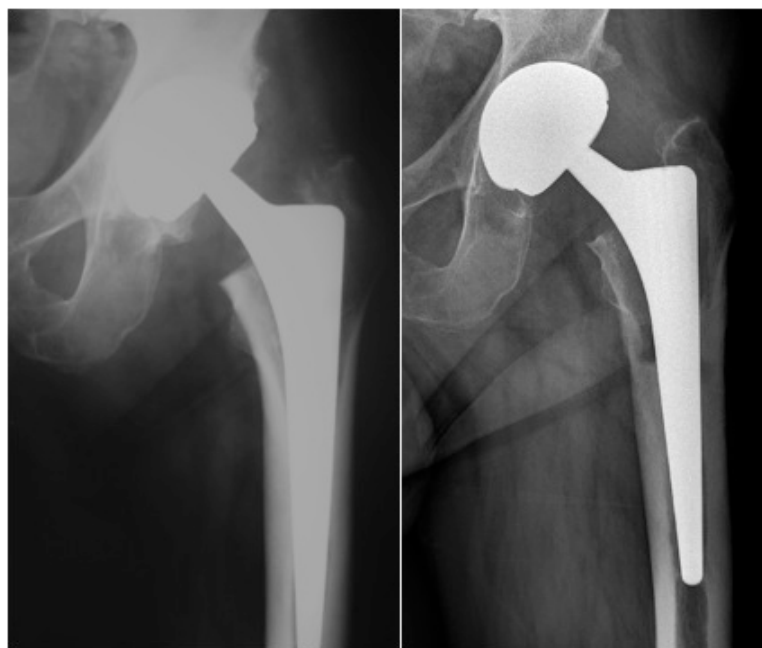
A 61-year-old male patient presented to our clinic complaining of left hip pain. He was diagnosed with hip arthritis and a total hip arthroplasty was performed using a metal-metal bear couple with a Metasul Durom® acetabular component, a Metasul Durom® femoral head and CLS Spotorno® femoral stem. The surgery and postoperative period passed without complications. In the evaluative clinical controls two and six months after surgery, the clinical, radiological and functional status of the patient was satisfactory.

Fifteen months after surgery, the patient presented with progressive and increasing left groin pain and difficulty in walking. He had pain with external rotation of the hip; there was no redness, swelling or other signs of infection. A plain radiograph showed osteolysis around the femoral component in Gruen zones 1 and 7 (Fig. 1). The cup anteversion angle was 13.5° (measured on plain radiograph by the method reported by Bachhal *et al.*) and the acetabular angle was 46°.

To rule out septic loosening, ultrasound guided fine needle aspiration was performed to obtaining a few drops of serohematic liquid. Culture was negative. Laboratory data revealed normal C-reactive protein values (0.29 mg/dL) and normal erythrocyte sedimentation rate (32 mm/h), but high values of eosinophil (0.34 10E9/L). A triphasic bone scan and a labelled leukocytes scintigraphy study were compatible with aseptic prosthetic loosening (Fig. 2).

After consulting with the allergy department, a skin patch test with the European Standard Battery of allergens was performed. After 48 hours all tested

Figure 1 / A. AP radiograph 6 months after surgery B. AP radiograph 15 months after surgery revealed osteolysis around the femoral component in Gruen zones 1 and 7.



allergens were negative, but after 96 hours the test was positive for cobalt chloride.

In the revision surgery, loosening of acetabular and femoral components was confirmed, and consequently both components were removed. A fibrinous necrotic tissue surrounded the femoral component. (Fig. 3) Some samples of this tissue were sent for culture, and others for histological study. Cultures of samples obtained from the removed

Research paper

prosthesis by sonication were also performed. Components used for revision were a ceramic-ceramic bear couple (BIOLOX® ceramic standard insert and BIOLOX® femoral head) and cobalt-free inserts (Ti-Plasma multiholes shell EP-FIT PLUS®, and a Wagner SL Revision® uncemented femoral stem).

The histological study of the fibrinous necrotic tissue revealed an inflammatory cell infiltration and vascularization without signs of metal debris and a necrotic zone, which was in close relation to the prosthesis. Immunohistochemical analysis revealed numerous CD20 positive B-lymphocytes and a few CD3 positive T lymphocytes, which mostly were CD4 positive (T-helper type). The lymphocytic infiltrate showed a highly HLA-DR positivity (Fig. 4)

After surgery and in accordance with our hospital's protocol, the patient received antibiotic treatment with linezolid and ceftriaxone until definitive culture results were obtained, All cultures were negative for acid-alcohol resistant bacilli, mycobacterium, and bacteria in general, and so the antibiotic treatment was stopped, after six weeks. Despite the absence of positive culture, preventive antibiotic treatment was administered.

At the most recent follow up visit, five years after revision surgery, the patient was asymptomatic, and hip mobility was restored and painless. X-rays showed no changes since the postoperative control.

Discussion

Higher revision rates have been seen after metal-on-metal hip arthroplasty when small components were used (in female patients) with abnormal anatomy of the hip and bad positioning of the acetabular component^{1,2}. Our patient presented with typical osteoarthritis symptoms. The radiologic study did not show any anatomic variation or dysplasia of the hip (Fig. 1). The components used in the hip replacement surgery could not be considered as small. Given the cup anteversion³, 13.5°, and the acetabular angle, 46°, we assumed that the loosening was not caused by a technical problem.

The patient had not referred any symptoms suggestive of septic failure of the prosthesis. The laboratory tests showed normal C-reactive protein and erythrocyte sedimentation rate values. A fine needle aspiration sample was cultured and was negative for bacteria. As published by Battaglia *et al.*⁴, the above tests, in combination, represent the best

Figure 2 / Triphasic bone scan images show increased uptake around the prosthesis, located in the greater and lesser trochanter.

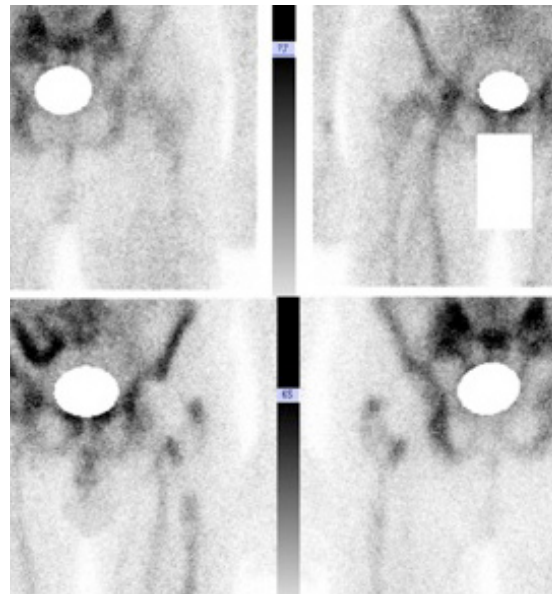
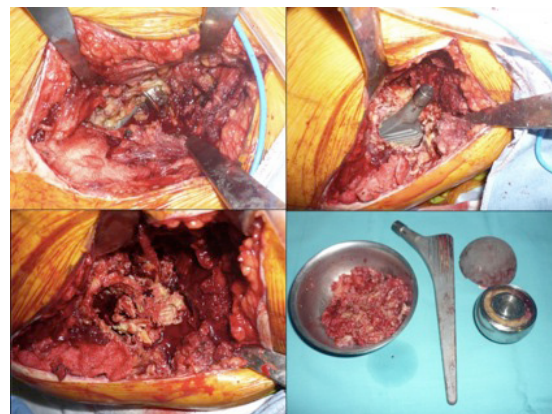


Figure 3 / A fibrinous necrotic tissue surrounded the femoral component.



tools to evaluate septic loosening of hip prostheses.

The differential diagnosis between a low-grade infection and a hypersensitivity reaction is initially reached by exclusion, on the basis of aspiration cultures. The final diagnosis can be made on the basis of histological studies⁵, which have been reported as most accurate indication of infection: presence of neutrophils in periprosthetic tissue is correlated with a diagnosis of infection with high specificity and sensitivity⁶.

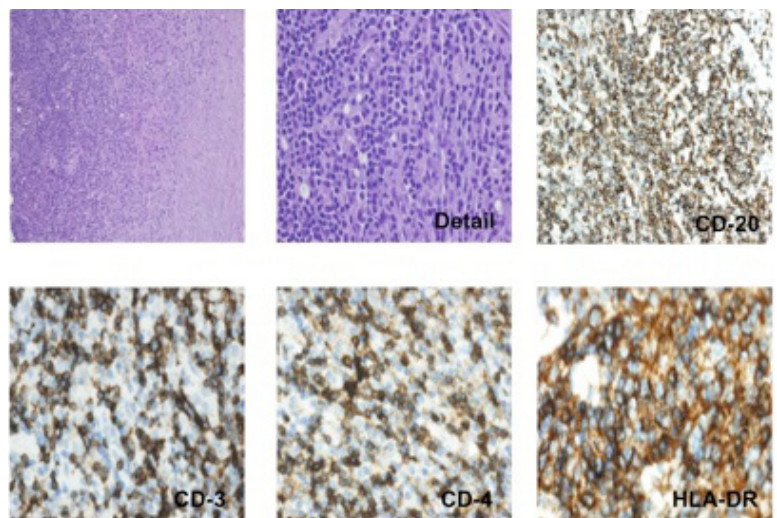
Research paper

As metal hypersensitivity is found with increasing frequency to be the cause of early osteolysis after metal-on-metal hip arthroplasty, the department of allergy advised us to perform a skin patch test with the European Standard Battery of allergens. This test was positive for cobalt chloride in our patient. There is debate in the literature as to whether there is an association between contact allergy to selected metals and total joint arthroplasty. Thyssen *et al.*⁷ concluded that the risk of surgical revision was not increased in patch-tested dermatitis patients with metal allergies compared to non-dermatitis patients. Also, they found no differences in the prevalence of metal allergy in patients who underwent surgery and non-operated patients. Later, Hallab *et al.*⁷, Thomas *et al.*⁹ and Eben *et al.*¹⁰ found that contact allergy rates to metals are higher in arthroplasty patients with complications than in the general population.

Evans first described metal hypersensitivity as a cause of prosthesis loosening in 1974¹¹. The loosening is associated with a tissue reaction known as *aseptic lymphocyte-dominated vasculitis (ALVAL)*, which has been described by Willert¹² as an immunological response characterized as a lymphocytic infiltration accompanied by plasma cells and eosinophilic granulocytes, high endothelial venules, fibrin, necrosis and macrophages. The histological study for our patient revealed an immune infiltration compatible with a type IV hypersensitivity reaction similar to that described by Willert. The ALVAL tissue reaction is more and more recognized as a cause of early hip prosthesis failure, but the reaction is quite unspecific, and there is not a clear cause-effect relationship between metal hypersensitivity and ALVAL¹³. Note that diagnosis is always postoperative. Recently, a study has been published that evaluates the sensitivity and specificity of magnetic resonance imaging in the preoperative prediction of occurrence of ALVAL¹⁴.

In the case reported, having established the diagnosis of contact allergy to cobalt chloride, we performed revision surgery using cobalt free components and a ceramic-on-ceramic bearing couple.

Figure 4 / A. Chronic immune inflammation. In the right zone, necrosis is observed. No signs of metallosis are observed.
B. Detail. Chronic lymphoplasmocytic infiltration with well-developed vascularization.
C. CD20+ marker. There is a prominent component of B type lymphocytes.
D. CD3+ marker. There is a lesser component of T type lymphocytes.
E. CD4+ marker. The T-lymphocytes are of the T-helper type.
F. HLA-DR marker. The infiltrate expresses HLA-DR (MHC class II). It is an activated cell infiltrate, and the expression of HLA-DR indicates that it is an immune process.



Conclusion

Metal hypersensitivity should be considered as a possible cause of early hip prosthesis osteolysis. Correct differential diagnosis involves ruling out other possible causes and collaboration between hospital departments is essential. In the case discussed, revision surgery using components without the allergenic metal and using a ceramic-on-ceramic bearing couple gave satisfactory results.

Research paper

References

1. Graves SE, Rothwell A, Tucker K, Jacobs JJ, Sedrakyan A. A Multinational Assessment of Metal-on-Metal Bearings in Hip Replacement. *J Bone Joint Surg Am*. 2011 Dec 21;93 Suppl 3:43-7
2. Haddad FS, Thakrar RR, Hart AJ, Skinner JA, Nargol AV, Nolan JF, Gill HS, Murray DW, Blom AW, Case CP. Metal-on-metal bearings: the evidence so far. *J Bone Joint Surg Br*. 2011 May; 93(5):572-9.
3. Bachhal V, Jindal N, Saini G, et al. A new method of measuring acetabular cup anteversion on simulated radiographs. *International Orthopaedics*. 2012;36(9):1813-1818. doi:10.1007/s00264-012-1583-9.
4. Battaglia M, Vannini F, Guaraldi F, Rossi G, Biondi F, Sudanese A. Validity of preoperative ultrasound-guided aspiration in the revision of hip prosthesis. *Ultrasound Med Biol*. 2011 Dec;37(12):1977-83.
5. Meyer H, Krüger A, Roessner A, Lohmann CH. Allergic reactions as differential diagnosis for periprosthetic infection. *Orthopade*. 2012 Jan;41(1):26-31.
6. Pandey R, Drakoulakis E, Athanasou NA. An assessment of the histological criteria used to diagnose infection in hip revision arthroplasty tissues. *J Clin Pathol* 1999 ; 52 : 118-123.
7. Thyssen JP, Jakobsen SS, Engkilde K, Johansen JD, Søballe K, Menné T. The association between metal allergy, total hip arthroplasty, and revision. *Acta Orthop*. 2009 Dec;80(6):646-52.
8. Hallab N, Merritt K, Jacobs JJ. Metal sensitivity in patients with orthopaedic implants. *J Bone Joint Surg Am*. 2001 Mar;83-A(3):428-36.
9. Thomas P, Braathen LR, Dörig M, Auböck J, Nestle F, Werfel T, Willert HG Increased metal allergy in patients with failed metal-on-metal hip arthroplast and peri-implant T-lymphocytic inflammation. *Allergy*. 2009 Aug;64(8):1157-65.
10. Eben R, Dietrich KA, Nerz C, Schneider S, Schuh A, Banke JJ, Mazoochian F, Thomas P. [Contact allergy to metals and bone cement components in patients with intolerance of arthroplasty]. *Dtsch Med Wochenschr*. 2010 Jul;135(28-29):1418-22.
11. Metal sensitivity as a cause of bone necrosis and loosening of the prosthesis in total joint replacement. Evans EM, Freeman MA, Miller AJ, Vernon-Roberts B. *J Bone Joint Surg Br*. 1974 Nov;56-B(4):626-42.
12. Willert HG, Buchhorn GH, Fayyazi A *et al*. Metal-on- metal bearings and hypersensitivity in patients with artificial hip joints. A clinical and histomorphological study. *J Bone Joint Surg* 2005 ; 87-A : 28-36.
13. Thomas P, Braathen LR, Dörig M, Auböck J, Nestle F, Werfel T, Willert HG Increased metal allergy in patients with failed metal-on-metal hip arthroplast and peri-implant T-lymphocytic inflammation. *Allergy*. 2009 Aug;64(8):1157-65.
14. Nawabi DH, Gold S, Lyman S, Fields K, Padgett DE, Potter HG. MRI Predicts ALVAL and Tissue Damage in Metal-on-Metal Hip Arthroplasty. *Clin Orthop Relat Res*. 2014 Feb;472(2):471-81.